

Novel anal sphincter saving procedure with partial excision of levator-ani muscle in rectal cancer invading ipsilateral pelvic floor

Gyoung Tae Noh, Jeonghee Han, Chinock Cheong, Yoon Dae Han, Nam Kyu Kim

Department of Surgery, Yonsei University College of Medicine, Seoul, Korea

Purpose: Tumors at the level of the anorectal junction had required total levator-ani muscle excision to achieve an adequate resection margin. However, in the cases of tumor invading ipsilateral levator-ani muscle and intact external sphincter, *en bloc* resection of rectum with levator-ani muscle including tumor would be possible. This hemilevator excision (HLE) technique enables preserving the anal sphincter function while obtaining oncologic clearance and avoiding permanent colostomy in those patients. This study aimed to evaluate the surgical outcomes and feasibility of HLE.

Methods: Data on 13 consecutive patients who underwent HLE for pathologically proven low rectal cancer were retrospectively collected. All 13 patients presented low rectal cancer at the anorectal ring level that was suspected to invade or abut to the ipsilateral side of the levator-ani muscle.

Results: A secure resection margin was achieved in all cases, and anastomotic leakage occurred in 2 patients. During follow-up, 3 patients experienced tumor recurrence (2 systemic and 1 local). Among 6 patients who underwent diverting ileostomy closure after the index operation, 2 complained of fecal incontinence. The other 4 patients without fecal incontinence showed <10 times of bowel movement per day. Accessing their incontinence scale, mean Wexner score was 9.4.

Conclusion: HLE is a novel sphincter-preserving technique that can be a treatment option for low rectal cancer invading ipsilateral levator-ani muscle, which has been an indication for abdominoperineal resection (APR) or extralevator APR. However, the long-term oncologic and functional outcomes of this procedure still need to be assessed to confirm its validity.

[Ann Surg Treat Res 2017;93(4):195-202]

Key Words: Sphincter preservation, Rectal cancer, Levator ani

INTRODUCTION

Surgical resection has been the cornerstone of curative treatment despite major advances in the multidisciplinary management of rectal cancer. For low rectal cancer, abdominoperineal resection (APR) had been considered the gold standard since Miles reported the technique in 1908. However, patients are left with a permanent stoma after APR, which could compromise their quality of life. Additionally, some reports have suggested that the rate of a positive circumferential resection margin

(CRM) after APR is high, leading to higher local recurrence rates than with low anterior resection (LAR) [1-3]. Extralevator APR, which adopts Miles' original principles, avoids "waisting" of the specimen with a consequent risk of CRM involvement [4,5]. This enhanced radical approach involves dissecting the levator-ani muscles at their origin, and removing them *en bloc* with the rectum and anus. However, this technique was associated with high perineal morbidities and presented a higher rate of CRM positivity than LAR [6,7].

With incremental understanding of tumor biology and the

Received February 7, 2017, Revised April 17, 2017, Accepted April 21, 2017

Corresponding Author: Nam Kyu Kim

Department of Surgery, Severance Hospital, Yonsei University College of Medicine, 50-1 Yonsei-ro, Seodaemun-gu, Seoul 03722, Korea

Tel: +82-2-2228-2100, Fax: +82-2-313-8289

E-mail: namkyuk@yuhs.ac

Copyright © 2017, the Korean Surgical Society

© Annals of Surgical Treatment and Research is an Open Access Journal. All articles are distributed under the terms of the Creative Commons Attribution Non-Commercial License (<http://creativecommons.org/licenses/by-nc/4.0/>) which permits unrestricted non-commercial use, distribution, and reproduction in any medium, provided the original work is properly cited.

anatomy of the anal sphincter complex and more prevalent preoperative chemoradiation, sphincter-preserving procedures have been proposed and adopted—consisting of 2 procedures: ultra-LAR followed by coloanal anastomosis (CAA) with or without intersphincteric resection (ISR)—since Schiessel et al. reported the first ISR with CAA for low rectal cancers in the early 1990s [8,9]. This procedure is believed to afford an adequate oncological resection margin while preserving sphincter function, and has been adopted as an alternative to APR.

Despite this surgical improvement, tumors at the level of the anorectal junction had required total levator-ani muscle excision to achieve an adequate CRM. However, in the cases of tumor invading limited to ipsilateral levator-ani muscle and intact external sphincter, *en bloc* resection of rectum with levator-ani muscle including tumor without compromising anal function would be possible. Previously, Fucini et al. [10] showed the existence of a functional and anatomic separation between levator-ani muscle and external anal sphincter. Additionally, investigating rectal cancer patients underwent levator-ani muscle excision and sphincter preservation, they suggested that selected patients with tumor infiltration limited to the levator-ani muscle can be treated by this advanced sphincter-sparing procedure with satisfactory oncologic and functional results [11].

Recent advances in diagnostic modalities and surgical techniques permitted accurate preoperative diagnosis and meticulous surgery. Preoperative MRI shows detailed relation between tumor in rectum and surrounding anal sphincter complex, which helps to select patients for a specific surgical modality. Also, minimally invasive surgeries such as robotic surgery have enabled meticulous and precise dissection of the mesorectum in a previously irradiated rectum down to the pelvic floor. Furthermore, these techniques permit the manipulation of pelvic floor muscles, even their sharp excision. For tumors at the level of the levator-ani muscle, excision of the levator-ani and achieving a wide resection margin has become possible.

With this hemilevator excision (HLE) technique followed by ISR and CAA, preservation of anal sphincter function while obtaining oncologic clearance and avoiding permanent colostomy are achievable for the patients with low rectal cancer of which infiltration is limited to the ipsilateral levator-ani muscle. The proportion of patients in this category might be limited, but the possibility of sphincter preservation would be important in this challenging field. This study aimed to evaluate the surgical outcomes and feasibility of HLE.

METHODS

Between January 2011 and January 2017, we retrospectively collected data on 13 consecutive patients who underwent HLE for pathologically proven low rectal cancer (within 4 cm from the anal verge), performed by a single surgeon. The inclusion

criteria for this technique were rectal cancer which located at the level of anorectal ring and invaded or abutted to the ipsilateral levator-ani muscle. The exclusion criteria ruled out patients with additional invasion beyond the levator-ani muscle to the external anal sphincter, those with recurrent tumor, or those with anal cancer. This technique was used to potentially avoid permanent colostomy while maintaining oncologic safety and anal function. All 13 patients presented low rectal cancer at the anorectal ring level that was suspected to invade or abut to the ipsilateral side of the levator-ani muscle and/or pelvic floor muscles on pelvic MRI, even after preoperative chemoradiation. Preoperative chemoradiation was performed for all enrolled patients as a long-course radiotherapy: 50.4-Gy radiation in 28 fractions for 6 weeks concurrent with infusion of 2 cycles of 5-fluorouracil- or capecitabine-based chemotherapy (Fig. 1). The definitive surgery was performed 4–8 weeks after the termination of chemoradiation and patients were followed up every 3 months after surgery. Postoperative defecation function could be assessed for patients who had undergone reversal of diverting ileostomy after the index operation and the results on last follow-up visit were analyzed. Incontinence was assessed by using the patient-reported Cleveland Clinic Florida fecal incontinence grading scale, proposed by Jorge and Wexner [12]. Patients were informed about the procedure, and all relevant preoperative, perioperative, and postoperative data were collected. The study was reviewed and approved by Institutional Review Board (IRB) of Severance Hospital (approval number: 4-2016-0683). Given the retrospective nature of the study, the

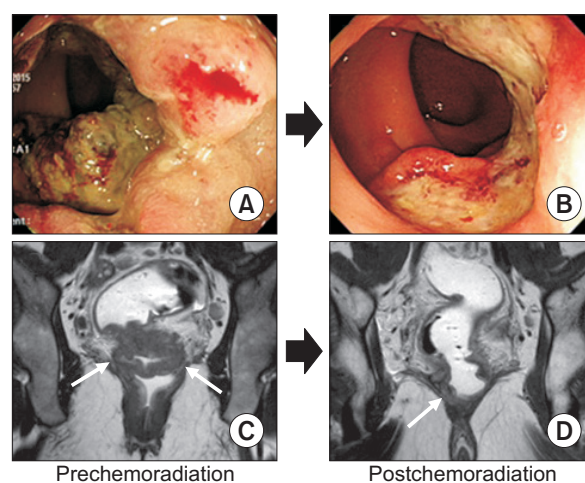


Fig. 1. Comparison of colonoscopic and magnetic resonance imaging before and after chemoradiation. (A) Huge ulcerofungating lesion in the low rectum. (B) Partial regression of the tumor after chemoradiation. (C) Annular mass involving the low rectum with a positive circumferential resection margin at the left and right levator-ani muscle (white arrows). (D) Decreased extent of tumor with a still threatening circumferential resection margin at the right levator-ani muscle (white arrow).

IRB waived the requirement for written informed consent.

Operative technique

All patients underwent standard bowel preparation the day before surgery and received prophylactic antibiotics before the incision. They were placed in the Lloyd-Davies with a steep Trendelenburg position. The operation included an abdominal and a perineal phase. The abdominal phase included ligation of central vessels, mobilization of the splenic flexure, complete dissection of the mesorectum, and excision of the levator-ani muscle. ISR and CAA were performed during the perineal phase. Laparoscopic surgery was performed for one patient, and others underwent robotic surgery with the da Vinci Surgical System (Intuitive Surgical, Sunnyvale, CA, USA).

We started the surgery with colonic mobilization until splenic flexure and central vessel ligation. Then, we performed dissection of the rectum following the principle of total mesorectal excision. Dissection was then continued to the pelvic floor consisting of the levator-ani muscles. We exposed the puborectalis muscle at the contralateral side of the tumor. Then, dissection and excision of the levator-ani on the same side of the tumor were performed with a wide margin. After the completion of pelvic dissection and HLE, the perineal phase was started. The patient's hips were flexed to allow better access to the perineum. The incision started at the line of Hilton on the side of the tumor, from where the intersphincteric space can be accessed. The dissection then continued between the

internal and external anal sphincter to the level about 0.5–1 cm below the tumor, where the direction of the dissection turned transversally to include the deep part of the external sphincter until the ischiorectal fossa fat could be visualized. The dissection continued in a cephalic direction to include the levator-ani muscle, from where the pelvic cavity is entered. In cases of a difficult intersphincteric approach to reach the levator-ani muscle attachment, an extrasphincteric approach with separate perianal incision parallel to the intersphincteric groove was performed to enter the ischiorectal fossa and dissect the attachment of the levator-ani muscle. On the contralateral side of the tumor, the incision was made just above the dentate line and the dissection was in a plane medial to the internal sphincter, which allowed entering the pelvic cavity medially to the puborectalis muscle (Fig. 2). After total excision of the rectum, the rectum and sigmoid colon were delivered through the anus and transected as described by Watanabe et al. [13]. The distal rectum was divided in a sleeve fashion. Reconstruction of bowel continuity was performed with hand-sewn CAA with absorbable interrupted sutures. The level of anastomosis between the tumor site and the contralateral side was different owing to the sleeve-fashioned resection; on the tumor side, the rectum was divided below the sphincter complex, whereas division of the rectum on the contralateral side of the tumor was done at the level of the anorectal ring. A diverting loop ileostomy was created for all patients who underwent this technique.

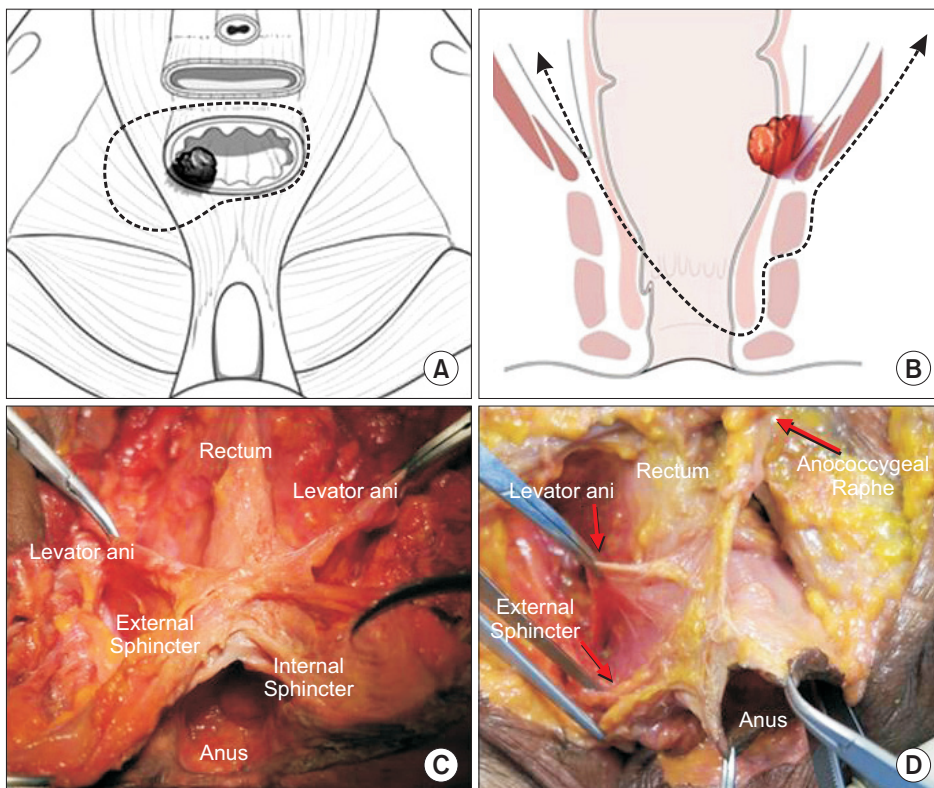


Fig. 2. Schematic of hemilevator excision. (A) Axial view of the extent of resection for hemilevator excision including the rectum and the invaded levator-ani muscle. (B) Coronal view of the extent of resection for hemilevator excision through the intersphincteric plane and sleeve-fashioned distal rectum resection. (C, D) Cadaveric model showing dissection plane for hemilevator excision between levator-ani muscle and external anal sphincter (posterior view after sacrum excision).

RESULTS

Patient characteristics

Thirteen consecutive patients underwent HLE and CAA for low rectal cancer. Their characteristics are detailed in Table 1. They had a median age of 53.0 years (interquartile range [IQR], 41.5–65.0 years) and comprised 9 men and 4 women. Their median body mass index was 24.0 kg/m² (IQR, 21.0–27.5 kg/m²), and the American Society of Anesthesiologists physical status classification was I for 2 patients, II for 9 patients, and III for 2 patients. The median distance of the primary tumor from the anal verge was 3.0 cm (IQR, 2.0–4.0 cm). On preoperative imaging such as abdominopelvic CT and pelvic MRI, 8 patients showed serosal infiltration of the primary tumor (cT3) and the other 5 showed invasion of the tumor into the adjacent levator-ani muscle (cT4). In all 8 patients with cT3 disease, the primary tumor was seen to abut the CRM. Lymph node metastasis was suspected on CT and MRI in 11 patients. No patient had evidence of distant metastasis on preoperative evaluation. Of

the 13 patients, 1 underwent laparoscopic surgery, which was the initial experience of HLE, and the other 12 underwent robotic surgery. All enrolled patients underwent unilateral excision of the levator-ani muscle (right side for 4 and left side for 9) and 3 patients underwent resection of adjacent organs (e.g., vagina and uterus) owing to direct invasion of the tumor. Of 3 patients with adjacent organ resection, 1 patient required local flap transposition to reconstruct the soft tissue defect after extensive perineal excision. The median duration of operation and amount of blood loss were 321.0 minutes (IQR, 295.5–486.5 minutes) and 100.0 mL (IQR, 75.0–325.0 mL), respectively.

Pathologic results

The pathologic results of patients are summarized in Table 2. According to the tumor regression grade after preoperative chemoradiation based on the classification by Mandard et al. [14], 2 patients were grade 1 (complete pathologic response), 4 patients were grade 2, 4 patients were grade 3, and 3 patients were grade 4. In 3 patients, lymph node metastases were identified (ypIII). The median tumor size was 1.2 cm (IQR, 0.4–2.8 cm). For all cases, a secure resection margin from the tumor was achieved, especially the CRM, which was the primary intention of HLE. The definite median distance from the tumor to the proximal, distal, and circumferential margin was 20.0, 1.0,

Table 1. Patient characteristics

Characteristic	Value
Age (yr)	53.0 (41.5–65.0)
Sex	
Male	9
Female	4
Body mass index (kg/m ²)	24.0 (21.0–27.5)
ASA PS classification	
I	2
II	9
III	2
Tumor location from the anal verge (cm)	3.0 (2.0–4.0)
Preoperative stage	
Tumor infiltration	
cT3	7
cT4	6
Lymph node metastasis	
cN0	3
cN1	8
cN2	2
Distant metastasis	
cM0	13
cM1	0
Surgical method	
Laparoscopic surgery	1
Robotic surgery	12
Excised side of levator-ani muscle	
Right	4
Left	9
Duration of operation (min)	321.0 (295.5–486.5)
Intraoperative blood loss (mL)	100 (75.0–325.0)

Values are presented as median (interquartile range) or number. ASA PS, American Society of Anesthesiologists physical status.

Table 2. Pathologic results

Variable	Value
Tumor regression grade (Mandard et al. [14])	
1 ^{a)}	2
2	4
3	4
4	3
Pathologic stage (ypTNM)	
yp0	2
ypI	6
ypII	2
ypIII	3
Tumor size ^{b)} (cm)	1.2 (0.5–2.5)
Positive resection margin	0
Distance of resection margin ^{b)} (cm)	
Proximal margin	20.0 (15.0–22.0)
Distal margin	1.0 (0.5–2.0)
Circumferential margin	0.4 (0.3–1.1)
Lymphovascular invasion	0
Histologic subtype	
Well differentiated	1
Moderately differentiated	8
Poorly differentiated type	3
Mucinous type	1

Values are presented as median (interquartile range) or number.

^{a)}Mandard grade I means complete pathologic response (pCR).

^{b)}Data for pCR were excluded because of the absence of residual tumor.

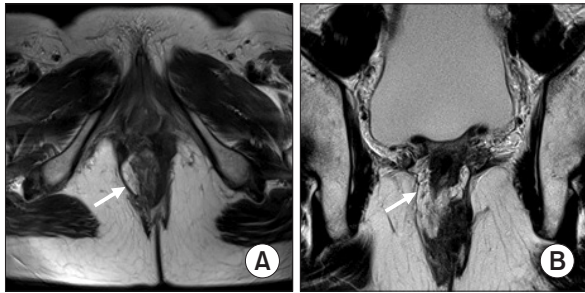


Fig. 3. Pelvic magnetic resonance imaging after hemilevator excision: obliterated defect of excised right levator-ani muscle by fibrotic tissue (white arrow). Axial (A) and coronal (B) view.

and 0.4 cm, respectively. No patient showed lymphovascular invasion. Histologically, 1 patient was categorized to have the well-differentiated type, 8 moderately differentiated, 3 poorly differentiated, and 1 patient had the mucinous type.

Postoperative results

The median duration of postoperative hospital stay was 8.0 days (IQR, 8.0–14.5 days). For nine patients, postoperative pelvic MRI was performed and excised levator-ani muscle obliterated by fibrotic tissue was identified (Fig. 3). Postoperative morbidities are listed in Table 3. Anastomotic leakage requiring percutaneous drainage occurred in 2 patients. Parastomal hernia for diverting ileostomy occurred in 1 patient, followed by revision of the stoma. One patient presented acute urinary retention, which was treated with short-term urinary catheter indwelling and medication. The median duration of postoperative follow-up was 11.0 months (IQR, 8.5–27.0 months). During follow-up, 3 patients experienced tumor recurrence. Two patients showed systemic recurrence in the lung and liver at 25 and 6 months after surgery, respectively. In 1 patient, local recurrence at the anastomotic site was identified at 4 months after surgery. After the index operation, 6 patients underwent reversal of diverting ileostomy and others were scheduled for the procedure. Among patients who had undergone stomal closure, 2 complained of fecal incontinence. One patient showed 2 to 3 times of bowel movement per day and required a pad for incontinence. The other patient showed frequent bowel movements of >10 times per day but did not require a pad. The other four patients without fecal incontinence showed <10 times of bowel movement in a day, which indicated an improving state. Of the patients with stomal closure, 5 patients' Wexner score could be assessed. Their mean score was 9.4 ± 5.7 .

DISCUSSION

APR had been a primary option for the management of low rectal cancer to achieve oncologic clearance. Nowadays, with

Table 3. Postoperative morbidities

	No. of incidence
Anastomotic leakage	2
Parastomal hernia	1
Acute urinary retention	1
Fecal incontinence ^{a)}	2

^{a)}Fecal incontinence was assessed in patients underwent stoma closure.

advances in the multimodal treatment of locally advanced rectal cancer, anal sphincter preservation has emerged as another issue in the management of low rectal cancer. Preoperative chemoradiation and ISR with CAA increased the opportunity to preserve the anal sphincter for patients who would otherwise be candidates for APR and permanent colostomy. Nevertheless, APR is still recommended for patients with rectal cancer infiltrates in the levator-ani muscle, and managing tumors at this level is challenging with a high rate of local recurrence and the possibility of combined resection of adjacent structures, which might compromise the quality of life. In this study, we described our experience of HLE and CAA for selected cases of rectal cancer that had invaded the ipsilateral side of the levator-ani muscle.

Securing a clear resection margin is a major end-point of surgical modalities for low rectal cancer. Recent systemic reviews reported the rates of positive CRM after APR and extralevator APR to be 13.1%–33.1% and 14.7%–33.1%, respectively [15,16]. In this study, although the number of cases was limited, there was no patient with positive CRM including the resection margin of the levator-ani muscle. Additionally, there was no patient with a positive distal resection margin, which suggests the oncologic safety of HLE. Another concern in performing such a low anastomosis is anastomotic leakage. Two patients (15.4%) in the present study experienced anastomotic leakage, and both were treated conservatively with percutaneous drainage and antibiotics. This result is similar to that of previous studies on CAA after resection of low rectal cancer, which reported the leakage rate within a range from 5.0% to 21.5% [17-20]. In this study, the overall rate of postoperative morbidity was 30.8% and there were no mortalities, which was similar to the results in other studies on laparoscopic or robotic ISR and CAA [13,21,22]. In APR and extralevator APR, a high rate of perineal wound complication has been reported (10.7%–59.3%) [16]. HLE did not result in a huge perineal defect and the defect of excised levator-ani muscle was obliterated by fibrotic tissue, as identified on pelvic MRI performed after surgery in selected cases. The durations of operation and postoperative hospital stay in this study were similar or slightly longer than those in other reported series on laparoscopic or robotic ISR, which might be attributable to the proportion of more advanced disease in this

patient group and a wider extent of resection [23,24]. However, compared with APR or extralevator APR, the durations of operation and postoperative hospital stay were similar or relatively shorter after HLE [16,25]. A reason for this result could be an absence of a wide perineal wound and its complication in patients after HLE.

With technical developments in diagnosis, including imaging modalities, preoperative evaluation has become more accurate, allowing the establishment of concrete treatment strategies in the multimodal treatment era. Furthermore, selection of patients for a specific surgical modality has become more detailed. The patients in the present study were best diagnosed with coronal-axial MRI, which was helpful in determining the exact tumor site at the level of the levator-ani muscle. Previously, such patients were not well defined, and they typically undergo the extensive surgery of APR. For those patients, preservation of the anal sphincter might have been possible if they had received a multimodal treatment approach, including HLE. Likewise, technical developments in surgical instrumentation have enabled more delicate operations in pelvic cavity and made it possible to achieve HLE with adequate resection margin. With the open technique for rectal cancer surgery, exploring the pelvic floor for excision of levator-ani muscle is almost impossible. Laparoscopic surgery has offered an optimal pelvic dissection while keeping the visceral pelvic fascia intact, and an enhanced view deeper within the pelvis than with the open technique. However, the use of nonarticulated forceps, camera tremor, and surgeon fatigue make laparoscopic dissection

down to the pelvic floor technically challenging, particularly in the presence of a narrow pelvis in a male patient, visceral obesity, and previous irradiation [21,26,27]. With these technical obstacles, laparoscopic surgery was restricted to only one case of HLE. The recent introduction of robotic systems revolutionized the field of minimally invasive surgery [28]. With robotic systems, an excellent stereoscopic view may be obtained with high illumination, and adequate traction and counter-traction can be performed readily in a narrow pelvis through the endo-wrist function. The adoption of robotic systems, which has been used in CAA and ISR as well as in APR, allowed overcoming the technical limitations of laparoscopic surgery during dissection of the levator-ani muscle [19,23]. In a recent study comparing surgical outcome between laparoscopic and robotic ultra-LAR followed by CAA, there was no significant difference in terms of short- and long-term prognosis and robotic surgery showed superior result in terms of conversion to open surgery and length of hospital stay [29]. With these advantages, robotic surgery gave us the chance to perform the technically challenging surgery of HLE which had not be done by its technical obstacles.

According to the tumor location and penetration depth to adjacent structures such as the sphincter complex and levator-ani muscle in advanced low rectal cancer, we can suggest surgical options if the validity of HLE is confirmed (Fig. 4). For rectal cancer around the level of the dentate line, which invades only the internal anal sphincter or beyond, ISR through the intersphincteric space or APR would be appropriate, re-

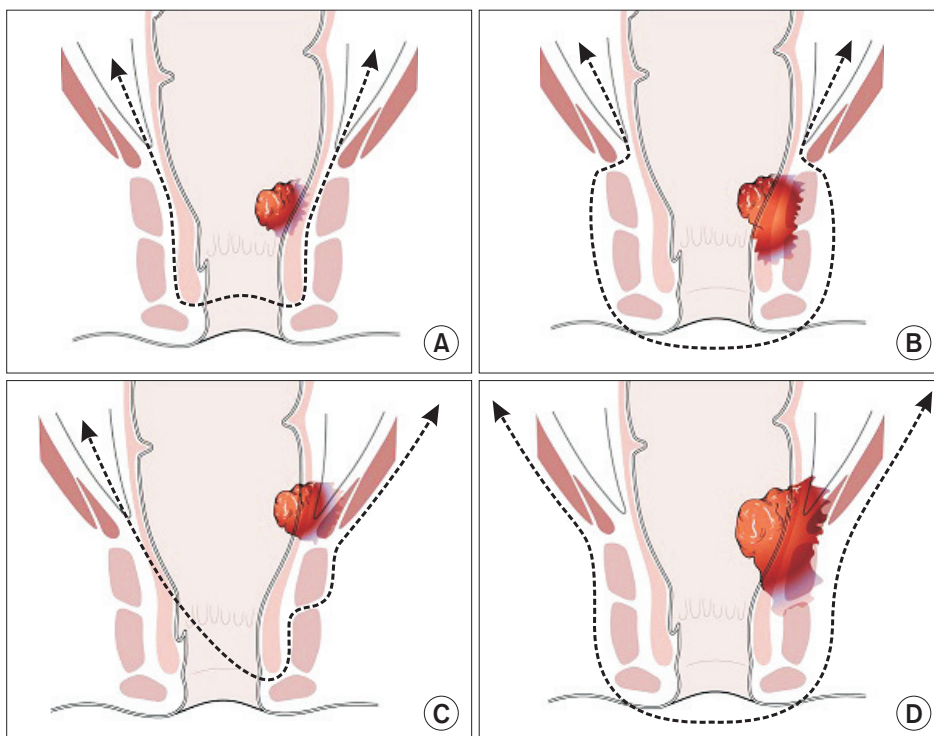


Fig. 4. Schematic of surgical options for advanced rectal cancer. (A) Intersphincteric resection for a tumor invading only the internal sphincter. (B) Abdominoperineal resection for a tumor invading beyond the internal sphincter. (C) Hemilevator excision for a tumor invading the levatorani muscle without external sphincter invasion. (D) Extralevator abdominoperineal resection for a tumor invading both the levator-ani muscle and external sphincter muscle.

spectively. For low rectal cancer at the level of the anorectal ring, which invades the levator-ani muscle, extralevator APR is considered an appropriate option. We can subdivide the patients according to the presence of invasion into the external anal sphincter, and for patients without external sphincter invasion, HLE would be feasible to avoid permanent colostomy and maintain anal function.

This study has some limitations. First, this was a retrospective study with a small population from a single surgeon at a single center. A prospective randomized study with a large population is needed to confirm that HLE is feasible for low rectal cancer invading the levator-ani muscle, instead of APR or extralevator APR. Second, long-term oncologic and objective functional outcomes need to be elucidated to confirm the validity of HLE. The value of results from a short-term follow-up and small population size would be restrictive. Nevertheless, in this study, oncologic safety was assessed with the status of the resection margin, and no patient had a positive resection margin. Furthermore, although the follow-up period and study population were limited, only 1 patient showed local recurrence (rate, 7.7%). In a previous systemic review, the local recurrence rate was reported as 10.7% after APR and extralevator APR [16]. In the context of functional outcome for the six patients who had undergone reversal of diverting ileostomy, 2 patients complained of fecal incontinence. Despite the limited number of patients and the short-term follow-up, the rate of continence of 66.7% and mean Wexner score of 9.4 was remarkable. According to the previous functional results after ISR, perfect continence was observed in 51.2% and mean Wexner score was 10.8 [25,30]. Furthermore, in the previous report investigating the functional outcome of levator-ani excision for rectal cancer,

comparing the clinical and laboratory function between patients with preserved and excised levator-ani muscle, there were no significant differences including their manometric results [11].

This study is the first attempt to present surgical method to preserve anal sphincter in low rectal cancer invading anorectal ring. Despite the limitations of this study as a preliminary report after HLE, the surgical feasibility and oncologic safety described here favor the adoption of HLE as an alternative option instead of APR or extralevator APR for low rectal cancer invading the levator-ani muscle. On the basis of anatomical evidence of existing the possible dissecting plane between levator-ani muscle and external anal sphincter, recent advances in pelvic MRI and robotic technology enabled to perform HLE by identifying detailed preoperative disease status and conducting meticulous excision. Certainly, long-term and functional outcomes should be investigated, and further studies will be required to validate the procedure of HLE, to better help in the management of such patients.

In conclusion, HLE is a novel sphincter-preserving technique that can be an alternative treatment for low rectal cancer invading the ipsilateral side of the levator-ani muscle, which has been an indication for APR or extralevator APR. To confirm the validity of this procedure, long-term oncologic and functional outcomes need to be assessed.

CONFLICTS OF INTEREST

No potential conflict of interest relevant to this article was reported.

REFERENCES

- Marr R, Birbeck K, Garvican J, Macklin CP, Tiffin NJ, Parsons WJ, et al. The modern abdominoperineal excision: the next challenge after total mesorectal excision. *Ann Surg* 2005;242:74-82.
- Heald RJ, Smedh RK, Kald A, Sexton R, Moran BJ. Abdominoperineal excision of the rectum--an endangered operation. *Norman Nigro Lectureship. Dis Colon Rectum* 1997;40:747-51.
- Nagtegaal ID, van de Velde CJ, Marijnen CA, van Krieken JH, Quirke P; Dutch Colorectal Cancer Group, et al. Low rectal cancer: a call for a change of approach in abdominoperineal resection. *J Clin Oncol* 2005;23:9257-64.
- Holm T, Ljung A, Häggmark T, Jurell G, Lagergren J. Extended abdominoperineal resection with gluteus maximus flap reconstruction of the pelvic floor for rectal cancer. *Br J Surg* 2007;94:232-8.
- West NP, Finan PJ, Anderin C, Lindholm J, Holm T, Quirke P. Evidence of the oncologic superiority of cylindrical abdominoperineal excision for low rectal cancer. *J Clin Oncol* 2008;26:3517-22.
- West NP, Anderin C, Smith KJ, Holm T, Quirke P; European Extralevator Abdominoperineal Excision Study Group. Multicentre experience with extralevator abdominoperineal excision for low rectal cancer. *Br J Surg* 2010;97:588-99.
- Williams NS, Dixon MF, Johnston D. Reappraisal of the 5 centimetre rule of distal excision for carcinoma of the rectum: a study of distal intramural spread and of patients' survival. *Br J Surg* 1983;70:150-4.
- Schiessel R, Karner-Hanusch J, Herbst F, Teleky B, Wunderlich M. Intersphincteric resection for low rectal tumours. *Br J Surg* 1994;81:1376-8.
- Camilleri-Brennan J, Steele RJ. Quality of

- life after treatment for rectal cancer. *Br J Surg* 1998;85:1036-43.
10. Fucini C, Elbetti C, Messerini L. Anatomic plane of separation between external anal sphincter and puborectalis muscle: clinical implications. *Dis Colon Rectum* 1999;42:374-9.
 11. Fucini C, Elbetti C, Petrolo A, Casella D. Excision of the levator muscles with external sphincter preservation in the treatment of selected low T4 rectal cancers. *Dis Colon Rectum* 2002;45:1697-705.
 12. Jorge JM, Wexner SD. Etiology and management of fecal incontinence. *Dis Colon Rectum* 1993;36:77-97.
 13. Watanabe M, Teramoto T, Hasegawa H, Kitajima M. Laparoscopic ultralow anterior resection combined with per anum intersphincteric rectal dissection for lower rectal cancer. *Dis Colon Rectum* 2000;43(10 Suppl):S94-7.
 14. Mandard AM, Dalibard F, Mandard JC, Marnay J, Henry-Amar M, Petiot JF, et al. Pathologic assessment of tumor regression after preoperative chemoradiotherapy of esophageal carcinoma. Clinicopathologic correlations. *Cancer* 1994;73:2680-6.
 15. Zhou X, Sun T, Xie H, Zhang Y, Zeng H, Fu W. Extralevator abdominoperineal excision for low rectal cancer: a systematic review and meta-analysis of the short-term outcome. *Colorectal Dis* 2015;17:474-81.
 16. De Nardi P, Summo V, Vignali A, Capretti G. Standard versus extralevator abdominoperineal low rectal cancer excision outcomes: a systematic review and meta-analysis. *Ann Surg Oncol* 2015;22:2997-3006.
 17. Akasu T, Takawa M, Yamamoto S, Ishiguro S, Yamaguchi T, Fujita S, et al. Intersphincteric resection for very low rectal adenocarcinoma: univariate and multivariate analyses of risk factors for recurrence. *Ann Surg Oncol* 2008;15:2668-76.
 18. Cong JC, Chen CS, Ma MX, Xia ZX, Liu DS, Zhang FY. Laparoscopic intersphincteric resection for low rectal cancer: comparison of stapled and manual coloanal anastomosis. *Colorectal Dis* 2014;16:353-8.
 19. Kang J, Hur H, Min BS, Lee KY, Kim NK. Robotic coloanal anastomosis with or without intersphincteric resection for low rectal cancer: starting with the perianal approach followed by robotic procedure. *Ann Surg Oncol* 2012;19:154-5.
 20. Weiser MR, Quah HM, Shia J, Guillem JG, Paty PB, Temple LK, et al. Sphincter preservation in low rectal cancer is facilitated by preoperative chemoradiation and intersphincteric dissection. *Ann Surg* 2009;249:236-42.
 21. Rullier E, Sa Cunha A, Couderc P, Rullier A, Gontier R, Saric J. Laparoscopic intersphincteric resection with coloplasty and coloanal anastomosis for mid and low rectal cancer. *Br J Surg* 2003;90:445-51.
 22. Bretagnol F, Rullier E, Couderc P, Rullier A, Saric J. Technical and oncological feasibility of laparoscopic total mesorectal excision with pouch coloanal anastomosis for rectal cancer. *Colorectal Dis* 2003;5:451-3.
 23. Leong QM, Son DN, Cho JS, Baek SJ, Kwak JM, Amar AH, et al. Robot-assisted intersphincteric resection for low rectal cancer: technique and short-term outcome for 29 consecutive patients. *Surg Endosc* 2011;25:2987-92.
 24. Park JS, Kim NK, Kim SH, Lee KY, Lee KY, Shin JY, et al. Multicentre study of robotic intersphincteric resection for low rectal cancer. *Br J Surg* 2015;102:1567-73.
 25. Martin ST, Heneghan HM, Winter DC. Systematic review of outcomes after intersphincteric resection for low rectal cancer. *Br J Surg* 2012;99:603-12.
 26. Laurent C, Paumet T, Leblanc F, Denost Q, Rullier E. Intersphincteric resection for low rectal cancer: laparoscopic vs open surgery approach. *Colorectal Dis* 2012;14:35-41.
 27. Hamada M, Matsumura T, Matsumoto T, Teraishi F, Ozaki K, Nakamura T, et al. Video. Advantages of the laparoscopic approach for intersphincteric resection. *Surg Endosc* 2011;25:1661-3.
 28. Lee SH, Lim S, Kim JH, Lee KY. Robotic versus conventional laparoscopic surgery for rectal cancer: systematic review and meta-analysis. *Ann Surg Treat Res* 2015;89:190-201.
 29. Baek SJ, Al-Asari S, Jeong DH, Hur H, Min BS, Baik SH, et al. Robotic versus laparoscopic coloanal anastomosis with or without intersphincteric resection for rectal cancer. *Surg Endosc* 2013;27:4157-63.
 30. Bretagnol F, Rullier E, Laurent C, Zerbib F, Gontier R, Saric J. Comparison of functional results and quality of life between intersphincteric resection and conventional coloanal anastomosis for low rectal cancer. *Dis Colon Rectum* 2004;47:832-8.