

Received: 2015.02.21
Accepted: 2015.06.24
Published: 2015.10.30

ISSN 1941-5923
© Am J Case Rep, 2015; 16: 774-777
DOI: 10.12659/AJCR.893919

Epstein-Barr Virus-Associated Atraumatic Spleen Laceration Presenting with Neck and Shoulder Pain

Authors' Contribution:
Study Design A
Data Collection B
Statistical Analysis C
Data Interpretation D
Manuscript Preparation E
Literature Search F
Funds Collection G

ABF 1,2 **Shane R. Sergent**
DEF 1 **Sophia M. Johnson**
ACDE 1 **John Ashurst**
ABCDE 1 **Greg Johnston**

1 Department of Emergency Medicine, Conemaugh Memorial Hospital, Johnstown, PA, U.S.A.
2 Clinical Faculty, Michigan State University College of Osteopathic Medicine, Michigan State University, East Lansing, MI, U.S.A.

Corresponding Author: Shane R. Sergent, e-mail: sergent2@msu.edu
Conflict of interest: None declared

Patient: Male, 15
Final Diagnosis: Infectious Mononucleosis induced spleen laceratio
Symptoms: Fever • headache • neck pain and upper shoulder pain which was worse with flexion and extension
Medication: —
Clinical Procedure: Splenic angiogram and proximal splenic artery embolization technique
Specialty: Critical Care Medicine

Objective: Unusual clinical course

Background: Infectious mononucleosis, caused by the Epstein-Barr virus (EBV), is a common infection with worldwide distribution; more than 90% of people have been infected by adulthood. One of the most feared, albeit rare, complications, occurring in less than 0.5% of those infected, is splenic injury or rupture.

Case Report: A febrile 15-year-old male presented to the emergency department with the chief complaint of headache, neck pain, and upper shoulder pain. He did not recall any specific traumatic injury. His abdomen was soft, nondistended, and was tender in the right and left lower quadrants. Right lower quadrant ultrasound demonstrated non-visualization of the appendix, moderate right lower quadrant free fluid, and positive McBurney's sign. CT of the abdomen and pelvis was ordered, which demonstrated moderate splenomegaly, with findings compatible with laceration through the anterior aspect of the spleen, with moderate hemoperitoneum. Monospot was negative and EBV panel demonstrated IGG negative, IGM positive, and, IGG negative.

The patient was transferred to interventional radiology for a splenic angiogram and proximal splenic artery embolization. The angiogram demonstrated grade 3 laceration with moderate hemoperitoneum and no active extravasation or evidence of pseudoaneurysm. The patient was admitted and made a prompt recovery without any other sequelae.

Conclusions: The presentation of splenic injury or rupture can vary; the patient may complain of abdominal pain or left upper quadrant pain, may exhibit referred left shoulder pain when the LUQ is palpated (Kehr's Sign), or may exhibit hemodynamic instability. Given the spectrum of non-specific symptoms, diagnosing EBV-induced splenic laceration can be difficult.

MeSH Keywords: Epstein-Barr Virus Infections • Spleen • Spleen Focus-Forming Viruses

Abbreviations: **AAST** – American Association for the Surgery of Trauma; **AG** – antigen; **CT** – computer aided tomography; **EBV** – Epstein-Barr virus; **FAST** – focused assessment with sonography in trauma; **IGG** – immunoglobulin G; **IGM** – immunoglobulin M; **IV** – intravenous; **LUQ** – left upper quadrant; **VCA** – viral-capsid antigen

Full-text PDF: <http://www.amjcaserep.com/abstract/index/idArt/893919>



1336 — 1 11

Background

Infectious Mononucleosis, caused by the Epstein-Barr virus (EBV), is a common infection with worldwide distribution and more than 90% of people have been infected by adulthood [1]. One of the most feared, albeit rare, complications, occurring in less than 0.5% of those infected, is splenic injury or rupture, which occurs more commonly in male patients [1]. EBV causes splenic enlargement, which can result in splenic rupture with even mild trauma [2]. Patients diagnosed with EBV are cautioned to avoid contact sports for at least 4 weeks or until documented resolution of splenomegaly [3]. The presentation of splenic injury or rupture can vary, but the patient may complain of abdominal pain or left upper quadrant pain, may exhibit referred left shoulder pain when the LUQ is palpated, which is known as Kehr's sign, or may exhibit hemodynamic instability [1,4]. Computer-aided tomography (CT) of the abdomen and pelvis with intravenous (IV) contrast is the preferred imaging modality for stable patients with suspected splenic injury, while focused assessment with sonography in trauma (FAST) should be used for unstable patients [3,5]. There has been a shift away from operative treatment of splenic injury, with a preference toward non-operative management or angiography with arterial embolization, which is performed at some institutions if the grade of injury is amenable to it [5].

Case Report

A febrile 15-year-old male presented to the emergency department with the chief complaint of headache, neck pain, and upper shoulder pain. He reported increased neck pain with flexion and extension. He also reported having a mild sore throat but was tolerating oral intake without difficulty, and initially did not complain of abdominal pain. He did report participating in a recent hockey tournament but did not recall any specific traumatic injury. Past medical history consisted only of sports-induced asthma, for which he used an inhaler.

Vitals at time of presentation consisted of a temperature of 38.2°C, pulse 105, respiratory rate 18, blood pressure 121/53 mmHG, and O₂ sat 99% on room air. Physical exam findings included an alert 15-year-old male who appeared uncomfortable but was not in acute distress. His head was normocephalic, atraumatic, with negative Brudzinski's test and no nuchal rigidity. The patient did have mild midline cervical tenderness with flexion and extension. His tonsils were noted to be enlarged but without exudates. Anterior cervical lymphadenopathy with associated tenderness to palpation was noted. Lungs were clear to auscultation and the cardiac exam demonstrated tachycardia without a murmur. His abdomen was soft, non-distended, and was noted for tenderness in the right lower

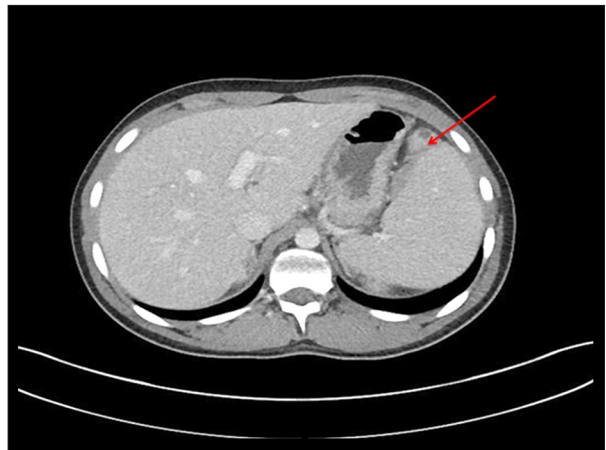


Figure 1. Demonstrates splenomegaly with associated grade 3 laceration (a depth of laceration greater than 3 cm). A grade 3 laceration can also be defined by one of the following additional criteria: subcapsular hematoma greater than 50% surface area or expanding, an intracapsular hematoma greater than 5 cm or expanded, or a ruptured subcapsular or parenchymal hematoma.

and left lower quadrants. No splenomegaly was appreciated, but the examination was limited due to voluntary guarding.

Initial diagnostic testing consisted of right lower quadrant ultrasound to assess for appendicitis or, alternatively, mesenteric adenitis, chest radiograph, blood culture, urine analysis and culture, complete blood count with differential, complete metabolic panel, and lactic acid. Pertinent results included a white blood cell count of 6.5 thou/cum (5.5–15.5) hemoglobin 14.5 gm/dl (10.0–15.5) hematocrit 43% (31–43), and sodium 130 meq/l (136–145). His automatic differential showed a decreased level of lymphocytes at 23%. He had increased neutrophils at 61 and his monocytes were significantly increased at 14. Ultrasound demonstrated non-visualization of the appendix, moderate right lower quadrant free fluid, and positive McBurney's sign. A rapid strep was negative.

A CT of the abdomen and pelvis was ordered with IV contrast and demonstrated moderate splenomegaly, with findings compatible with laceration through the anterior aspect of the spleen, with moderate hemoperitoneum (Figure 1). Monospot and Epstein-Barr virus panels were added to rule out possible infectious process. Monospot was negative and Epstein-Barr virus (IGG, IGM) panel demonstrated EBV VCA IGG negative, EBV VCA IGM positive, and EBV NUCLEAR AG, IGG negative. The surgical service was consulted, and after initial stabilization, the patient was transferred to interventional radiology for a splenic angiogram and proximal splenic artery embolization technique. The angiogram demonstrated no active extravasation or evidence of pseudoaneurysm, but a grade 3 laceration with moderate hemoperitoneum was confirmed.

Following embolization, the patient made a prompt recovery and was subsequently discharged to home without any other sequelae from his infectious process.

Discussion

Infectious mononucleosis is a self-limited viral illness caused by the Epstein-Barr virus, which often presents in children and young adults. EBV infection is characterized by a triad consisting of fever, pharyngitis (often with exudates), and symmetric posterior cervical lymphadenopathy [6]. Other symptoms may include headache, vomiting, nausea, and anorexia, which may be manifestations of mild hepatitis that can accompany EBV. Less common findings include palatal petechiae, periorbital or palpebral edema, and maculopapular or morbilliform rashes [6].

Potentially serious complications from EBV infection are often delayed. As the EBV infection progresses, a proliferation of mononuclear cells results, which collect within the lymphoid tissue. This includes the spleen, and as the spleen enlarges, the splenic capsule thins, which is seen in about 50% of patients [7]. A secondary complication from the reversible splenomegaly is rupture, as was noted in this case [7,8]. This relatively rare complication often presents with left upper quadrant abdominal pain, but this expected manifestation was not observed in the patient, perhaps secondary to his other distracting symptoms, the foremost being headache and neck pain, nor was any splenomegaly found on physical exam. It is important to note that splenomegaly alone does not present with pain.

Infectious mononucleosis is associated with splenic laceration or rupture in approximately 0.1–0.5% of patients [9,10]. Clinical findings for this complication may include Kehr's sign, which presents as left shoulder pain from the irritation of diaphragmatic nerves caused by the presence of hemoperitoneum (in retrospect, the patient's initial complaint was likely caused by this phenomena) [9]. Additional symptoms may include those associated with shock, such as tachycardia, hypotension, oliguria, and pallor from the acute blood loss. Therefore, in addition to possible leukocytosis, which was not observed in this case, it is important to trend hemoglobin and hematocrit. In severe cases, it would also be prudent to be prepared to administer blood products. Additional possible lab values abnormalities include elevated liver function studies, which are elevated in

up to 90% of patients [7]. If clinical suspicion points toward a possible spleen injury, a bedside ultrasound serves as a rapid and sensitive modality for detection of free fluid, and is the test of choice in hemodynamically unstable patients. CT scan is the recommended confirmatory test since it permits the clinician to grade the severity of splenic damage. Contrast-enhanced CT findings can include hemoperitoneum or contrast extravasation, lacerations, subcapsular or intraparenchymal hematomas, splenic hypodensity, and splenomegaly [7].

According to the American Association for the Surgery of Trauma (AAST), the spleen injury grading scale is based upon the anatomic injury identified on CT scan and can predict success of nonoperative management [11]. Management depends on hemodynamic status, resource availability, splenic injury grade, and presence of comorbidities. Initial management may include observation, angiographic embolization, or surgery, depending on these factors. In low-grade injuries (I to III) in hemodynamically stable patients, nonoperative management is suggested. These patients should be admitted to a monitored floor with serial abdominal examination and hemoglobin tests. Splenic embolization is suggested for hemodynamically stable patients with CT findings of active contrast extravasation. In cases of treatment failure and hemodynamic instability, surgical exploration is recommended. If possible, spleen preservation should be the ultimate goal if clinically feasible, given the long-term sequelae of asplenia [7,8]. Additional treatment should include discharge instructions to avoid exertional physical activities and contact sports until splenomegaly has resolved.

Conclusions

Spontaneous splenic rupture is a rare and life-threatening complication if not promptly recognized and treated. As demonstrated in this case, there is a wide range of clinical signs and symptoms, many of which are self-limited, associated with infectious mononucleosis, but the potential for life-threatening sequelae exists. It is therefore prudent that healthcare providers remain vigilant for potential complications of EBV, as well as typical manifestations of serious complications and other similar self-limited infectious agents, especially when the patient's presenting complaint and subjective findings markedly differ from the objective findings noted on physical examination.

References:

1. Longo DL, Fauci AS, Kasper DL et al: Epstein-Barr virus infections, including infectious mononucleosis. *Harrison's Principles of Internal Medicine*, 18th ed. New York (NY): McGraw-Hill; 2012
2. Strange GR, Ahrens WR, Schafermeyer RW et al: Abdominal trauma. *Pediatric Emergency Medicine*, 3rd ed. New York (NY): McGraw-Hill, 2009
3. Tintinalli JE, Stapczynski J, Ma O et al: Disseminated Viral Infections. *Tintinalli's Emergency Medicine: A Comprehensive Study Guide*. New York (NY); McGraw-Hill, 2011
4. Shah BR, Lucchesi M, Amodio J et al: Trauma. *Atlas of Pediatric Emergency Medicine*, 2nd ed. New York (NY): McGraw-Hill, 2013

5. Stone C, Humphries RL, Stone C, Humphries RL: Abdominal Trauma. Diagnosis & Treatment Emergency Medicine, 7th ed. New York (NY): McGraw-Hill, 2011
6. Luzuriaga K, Sullivan JL: Infectious mononucleosis. *N Engl J Med*, 2010; 362: 1993–2000
7. Brichkov I, Cummings L, Fazylov R et al: Nonoperative management of spontaneous splenic rupture in infectious mononucleosis: the role of emerging diagnostic and treatment modalities. *Am Surg*, 2006; 72: 401–4
8. Rothwell S, McAuley D: Case report: Spontaneous splenic rupture in infectious mononucleosis. *Emerg Med*, 2001; 13: 364–66
9. Auwaerter PG: Infectious mononucleosis: return to play. *Clin Sports Med*, 2004; 23: 485–97
10. Farley DR, Zietlow SP, Bannon MP et al: Spontaneous rupture of the spleen due to infectious mononucleosis. *Mayo Clin Proc*, 1992; 67: 846–53
11. Tinkoff G, Esposito TJ, Reed J et al: American Association for the Surgery of Trauma Organ Injury Scale I: spleen, liver, and kidney, validation based on the National Trauma Data Bank. *J Am Coll Surg*, 2008; 207: 646–55