



Since January 2020 Elsevier has created a COVID-19 resource centre with free information in English and Mandarin on the novel coronavirus COVID-19. The COVID-19 resource centre is hosted on Elsevier Connect, the company's public news and information website.

Elsevier hereby grants permission to make all its COVID-19-related research that is available on the COVID-19 resource centre - including this research content - immediately available in PubMed Central and other publicly funded repositories, such as the WHO COVID database with rights for unrestricted research re-use and analyses in any form or by any means with acknowledgement of the original source. These permissions are granted for free by Elsevier for as long as the COVID-19 resource centre remains active.



Autoimmune and autoinflammatory conditions after COVID-19 vaccination. New case reports and updated literature review

Yhojan Rodríguez^{a,b,1}, Manuel Rojas^{b,1}, Santiago Beltrán^b, Fernando Polo^c,
Laura Camacho-Domínguez^b, Samuel David Morales^c, M. Eric Gershwin^d,
Juan-Manuel Anaya^{a,e,*}

^a Clínica del Occidente, Bogota, Colombia

^b Center for Autoimmune Diseases Research (CREA), School of Medicine and Health Sciences, Universidad del Rosario, Bogota, Colombia

^c Hospital Infantil de San José, Fundación Universitaria de Ciencias de la Salud. Department of Pathology, Bogota, Colombia

^d Division of Rheumatology, Allergy and Clinical Immunology, University of California, Davis, CA, United States

^e LifeFactors, Rionegro, Colombia

ARTICLE INFO

Keywords:
Autoimmunity
COVID-19
SARS-CoV-2
Vaccines

ABSTRACT

Autoimmunity linked to COVID-19 immunization has been recorded throughout the pandemic. Herein we present six new patients who experienced relapses of previous autoimmune disease (AD) or developed a new autoimmune or autoinflammatory condition following vaccination. In addition, we documented additional cases through a systematic review of the literature up to August 1st, 2022, in which 464 studies (928 cases) were included. The majority of patients (53.6%) were women, with a median age of 48 years (IQR: 34 to 66). The median period between immunization and the start of symptoms was eight days (IQR: 3 to 14). New-onset conditions were observed in 81.5% (n: 756) of the cases. The most common diseases associated with new-onset events following vaccination were immune thrombocytopenia, myocarditis, and Guillain-Barré syndrome. In contrast, immune thrombocytopenia, psoriasis, IgA nephropathy, and systemic lupus erythematosus were the most common illnesses associated with relapsing episodes (18.5%, n: 172). The first dosage was linked with new-onset events (69.8% vs. 59.3%, $P = 0.0100$), whereas the second dose was related to relapsing disease (29.5% vs. 59.3%, $P = 0.0159$). New-onset conditions and relapsing diseases were more common in women (51.5% and 62.9%, respectively; $P = 0.0081$). The groups were evenly balanced in age. No deaths were recorded after the disease relapsed, while 4.7% of patients with new-onset conditions died ($P = 0.0013$). In conclusion, there may be an association between COVID-19 vaccination and autoimmune and inflammatory diseases. Some ADs seem to be more common than others. Vaccines and SARS-CoV-2 may induce autoimmunity through similar mechanisms. Large, well-controlled studies are warranted to validate this relationship and assess additional variables such as genetic and other environmental factors.

1. Introduction

The world witnessed a major infectious disease that first emerged in the Chinese city of Wuhan in 2019, an illness known as Coronavirus disease 2019 (COVID-19), which is caused by severe acute respiratory syndrome coronavirus 2 (SARS-CoV-2). It quickly spread worldwide and was declared a pandemic within a few months. On August 6, 2022, the Johns Hopkins University Center for Systems Science and Engineering reported 583,840,223 cases, with 6,417,401 deaths [1].

The clinical spectrum of COVID-19 ranges from the absence of symptoms to the presence of severe pneumonia, associated with a hyperinflammatory state, which causes multiorgan failure [2,3]. The most severe disease cases are related to an increase in the production of inflammatory cytokines (i.e., cytokine storm) [4,5]. Because of the disease's fast spread and the lack of effective therapies, attempts were made worldwide to find vaccines to reduce the disease's severity and mortality. To date, 12,002,790,796 dosages have been administered [1].

* Corresponding author. LifeFactors, Rionegro, Colombia.

E-mail address: janaya@lifefactors.co (J.-M. Anaya).

¹ These authors contributed equally and should be considered as first authors.

Table 1

Characteristics of six new cases of post-COVID vaccine autoimmune or inflammatory diseases.

Disease	Age (years)	Sex	Type of vaccine	Clinical manifestations of autoimmune disease	Diagnostic tests	Symptoms onset after vaccination (days)	Comment and outcome
Autoimmune Disease flare post-COVID vaccine							
Optic neuritis flare	56	F	Pfizer	Loss of visual acuity of the left eye	Ocular ultrasound: left eye retrobulbar optic neuritis	6 days after 1st dose	In 2004, she was diagnosed with optic neuritis and received treatment with methylprednisolone. Since, she continued with progressive loss of vision, 6 cycles of cyclophosphamide were administered, and subsequently received mycophenolate for 2 years with adequate control of the disease. After the first dose of the vaccine, she once again developed loss of visual acuity. A month later she was diagnosed with an optic neuritis flare. At this instance, she received methylprednisolone (1 g/d) for 5 days, but since the symptoms persisted, plasmapheresis therapy was given for 5 days. Ambulatory management with prednisolone (10 mg/d) was prescribed. Since then, the patient's visual disturbances have improved slowly.
Rheumatoid arthritis flare	47	F	Jansen	Arthralgia and arthritis in 2, 3 and 4 bilateral metacarpophalangeal and proximal interphalangeal joints Right knee synovitis	C-reactive protein 6.74 mg/L Erythrocyte sedimentation rate 40 mm/h	8 days after vaccination	Since 2017, patient presents with bilateral symmetrical arthralgias in hands associated with morning stiffness, but never consulted neither received immunomodulatory therapy. After vaccination, the pain was sharply increased so she went to the emergency room where therapy with methylprednisolone (250 mg/d) for 3 days was initiated and ambulatory management with methotrexate (25 mg weekly), chloroquine (150 mg) and prednisolone was given. In a follow up consult, the patient presented modulation of her symptoms.
Autoimmune Disease post-COVID vaccine							
Autoimmune hepatitis	69	F	Pfizer	Jaundice Abdominal pain Choluria	Hyperbilirubinemia (6.49 mg/dl) with direct bilirubin predominance (5.71 mg/dl) Elevated transaminases GOT: 559 U/L GPT: 339 U/L Anti-smooth muscle antibodies 57.4 (Positive) Elevated IgG (3342 mg/dl)	150 days after 2nd dose	After diagnosis, treatment with methylprednisolone (500 mg/d) for 5 days was initiated, and ambulatory treatment with azathioprine (50 mg twice a day) and tapering prednisolone of 10 mg per week was prescribed. In a follow up control in January 2022, patient clinical condition had resolved.
Other disease post-COVID vaccine							
Sweet Syndrome	53	F	Pfizer	Erythematous painful plaques of different sizes scattered on 4 extremities (See Fig. 1) Fever Malaise	Skin biopsy (See Fig. 1) C-reactive protein 89.77 mg/L White cells count 10.690/L Neutrophils 93.4% Peripheral blood smear without alterations Chest and abdominal CT scan within normal ranges. No visceral masses	72 days after 2nd dose	After diagnosis, treatment with methylprednisolone (500 mg/d) for 3 days was initiated for 3 days which caused resolution of the skin lesions
Urticarial Vasculitis	56	F	Sinovac	Erythematous lesions, with a pale center, pruritic, distributed on trunk and extremities (See Fig. 2)	Skin biopsy. (See Fig. 2)	1 day after 2nd dose	After the appearance of the skin lesions treatment with loratadine and methylprednisolone (500 mg/d) was initiated for 3 days which caused improvement of the symptoms
Leukocytoclastic vasculitis	54	F	Pfizer	Erythematous macular lesions with irregular borders in lower extremities (See Fig. 3)	Skin biopsy (See Fig. 3)	8 days after 2nd dose	At first treatment with topical betamethasone and loratadine was initiated. Since there was no clinical improvement, methylprednisolone (500 mg/d) for 3 days, was established with which she presented resolution of her symptoms

GOT: Glutamic-oxaloacetic transaminase, GPT: Glutamic-pyruvate-transaminase, IgG: Immunoglobulin G, M: Male, F: Female.

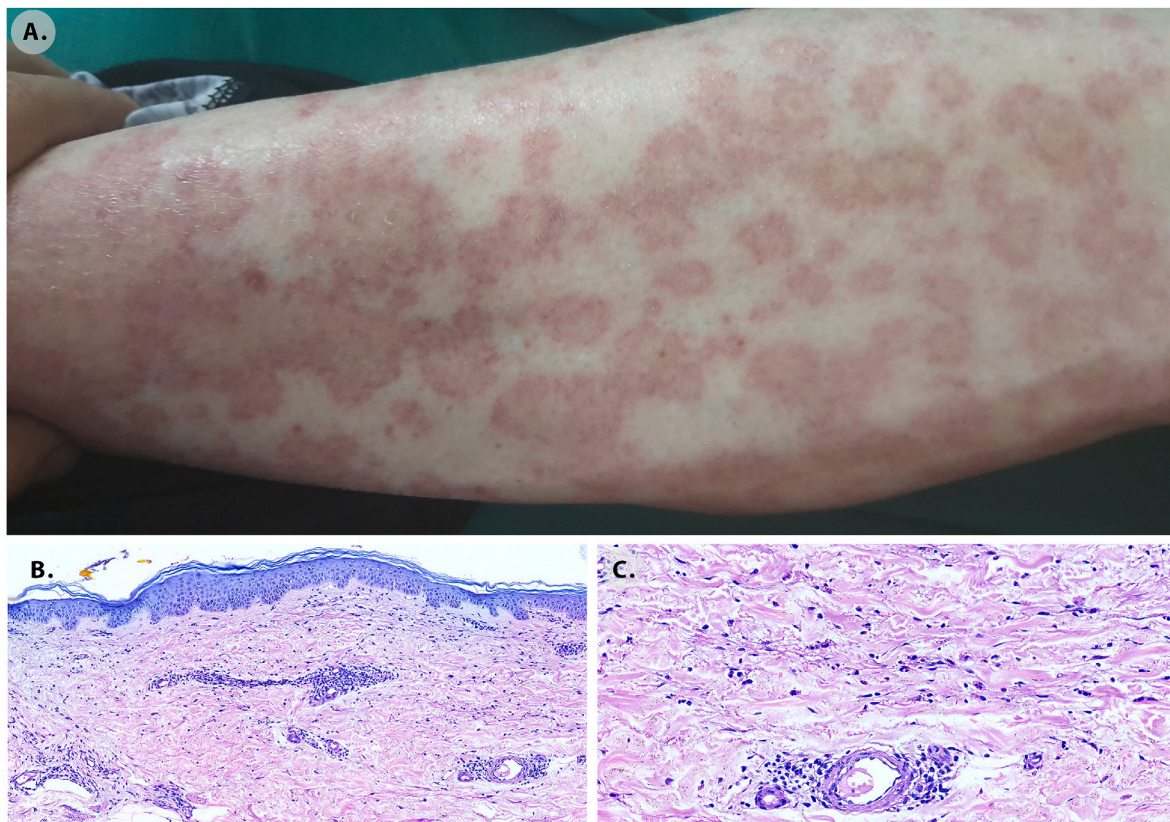


Fig. 2. Urticarial vasculitis. A. Skin lesions seven days after the vaccination. Erythematous lesions, with a pale center, pruritic, distributed on the trunk and extremities. Skin biopsy histological findings. B. Dermis with oedema X10. C. Superficial and deep perivascular infiltrates of predominantly lymphocytes and histiocytes with prominent extravasated erythrocytes that suggest a late vasculitis consistent with chronic urticarial rash X40.

biliary cholangitis" OR "Vasculitis"[Mesh] OR "Anti-Neutrophil Cytoplasmic Antibody-Associated Vasculitis"[Mesh] OR "Systemic Vasculitis"[Mesh] OR "Vasculitis, Leukocytoclastic, Cutaneous"[Mesh] OR "Granulomatosis with Polyangiitis"[Mesh] OR "Takayasu Arteritis"[Mesh] OR "Giant Cell Arteritis"[Mesh] OR "Thromboangiitis Obliterans"[Mesh] OR "Mucocutaneous Lymph Node Syndrome"[Mesh] OR "Polyarteritis Nodosa"[Mesh] OR "Churg-Strauss Syndrome"[Mesh] OR "IgA Vasculitis"[Mesh] OR "Microscopic Polyangiitis"[Mesh] OR "Antiphospholipid Syndrome"[Mesh] AND "COVID-19 Vaccines"[Mesh] OR "ChAdOx1 nCoV-19"[Mesh] OR "2019-nCoV Vaccine mRNA-1273"[Mesh] OR "BNT162 Vaccine"[Mesh] OR "Ad26COVS1"[Mesh] OR SARS-CoV-2 vaccines). Additionally, a manual search was carried out through the articles referenced in the included studies to expand the number of articles.

2.2. Eligibility criteria

The articles included in this study described patients with autoimmunity, or inflammatory diseases, associated with a history of vaccination against COVID-19. Case reports and case series were included. Only articles in English or Spanish were included. Cases that did not report the population of interest and those reports that did not specify the type of vaccine were excluded.

2.3. Study selection and data extraction process

The eligibility assessment was made by two reviewers, who independently reviewed all the articles selected in the initial search. The two reviewers extracted information related to sociodemographic data, type of disease, clinical characteristics, laboratory data, histopathological data, type of vaccine received, treatment received, and response to treatment. Any differences were resolved by consensus. The PRISMA guidelines for reporting in systematic reviews were used during the selection and data analysis phases [16].

2.4. Statistical analysis

Studies reporting individual data of patients were included in the analysis. Univariate descriptive statistics were performed. Categorical variables were analyzed using frequencies, and continuous quantitative variables were expressed in the median and interquartile range (IQR). Fisher's exact or Mann-Whitney U tests were used to explore differences between new-onset and relapsing autoimmune/autoinflammatory conditions. The significance level of the study was set to 0.05. Statistical analyses were done using R software version 4.0.2.

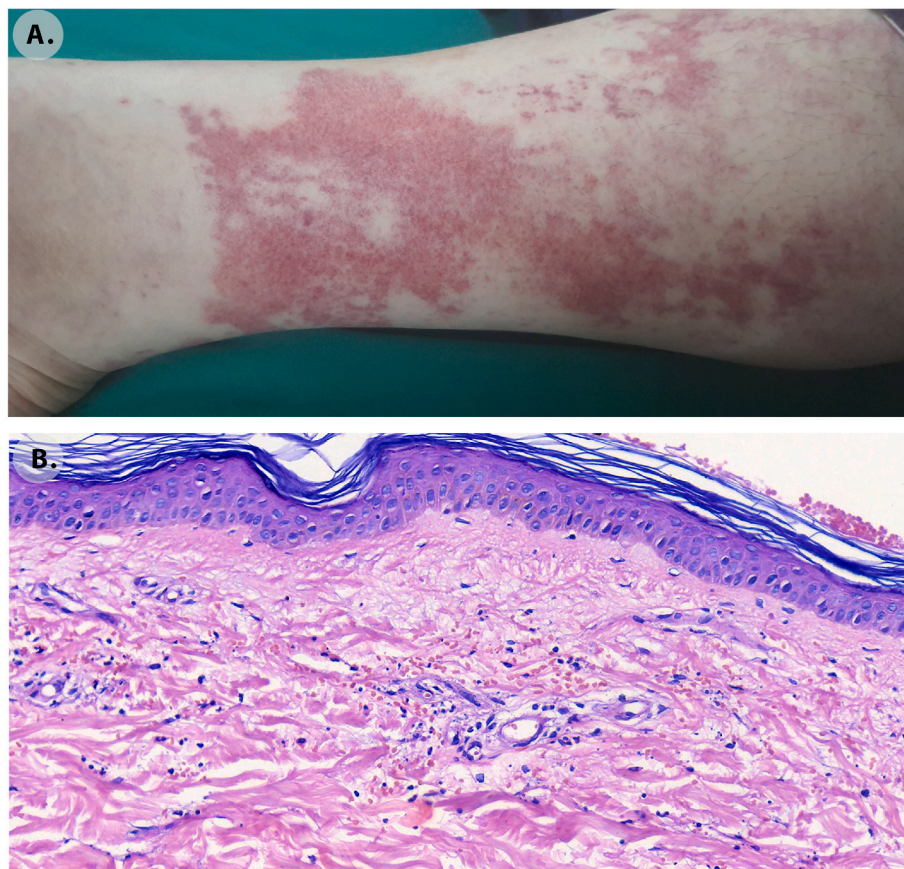


Fig. 3. Leukocytoclastic vasculitis. A. Skin lesions appeared 19 days after the vaccination. Erythematous macular lesions with irregular borders in the lower extremities. B. Skin biopsy histological findings. In the superficial and deep dermis perivascular infiltration of neutrophils with leukocytoclasia, extravasated erythrocytes and capillary wall damage with some oedema X40.

3. Results

3.1. Case reports

Six patients attending the post-COVID unit at the Clínica del Occidente in Bogota, Colombia, who presented autoimmunity or auto-inflammatory disease after receiving the SARS-CoV-2 vaccine are described in Table 1. Two patients showed disease relapse after vaccination (none of them were on immunomodulatory management at the moment for vaccination since they were on disease remission). One patient debuted with the disease after vaccination, and three developed other inflammatory manifestations. The images of the clinical findings and histopathological findings of these three cases are shown in Figs. 1–3.

3.2. Search results

A total of 16,949 manuscripts were found through the main search. After duplication, 15,968 were obtained. Then, 421 articles remained after the title and abstract review. In the selection phase, 46 studies were excluded. After that, additional 85 articles were identified from other

resources. Finally, 464 studies were included for qualitative and quantitative analysis [11], [17–467] (Fig. 4).

3.3. Systematic review of case reports

A total of 928 reports were obtained, each with its own data set. Most of them were women (488/910, 53.6%), with a median age of 48 (IQR: 34 to 66). The median period between immunization and the start of symptoms was eight days (IQR: 3 to 14). After immunization, the most common side effect was a new onset condition (756/928, or 81.5%). About 22.5% of new-onset and 21.5% of relapsing illness cases were reported in the United States (Fig. 5).

Following vaccination, the most commonly reported diseases associated with new-onset events were immune thrombocytopenia, GBS, and myocarditis (Fig. 6) (Table 2). Immune thrombocytopenia, psoriasis, IgA nephropathy, and SLE, on the other hand, were the most commonly reported illnesses associated with relapsing episodes (Fig. 6). Both occurrences were widely linked to the mRNA-1273 SARS-CoV-2 vaccine, which was followed by Sinovac-CoronaVac and ChAdOx1 nCoV-19 vaccine (AZD1222) (Fig. 7). The first dosage was linked with new-onset events (69.8% vs. 59.3%, $P = 0.0100$). In contrast, the second

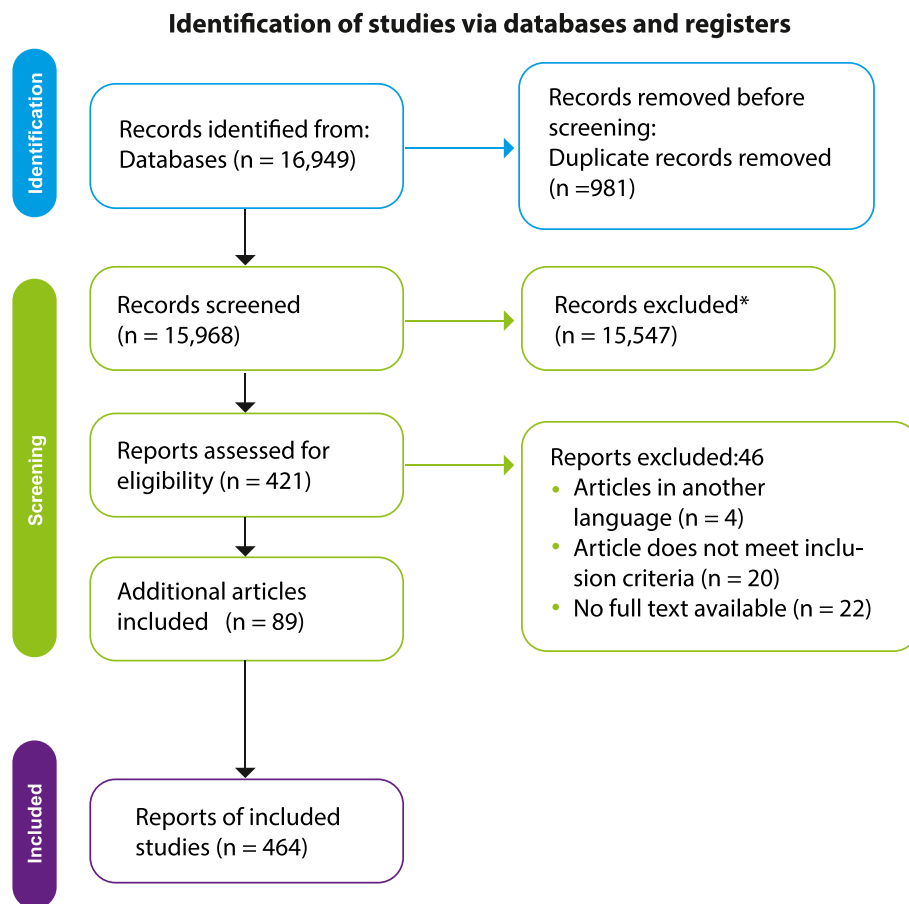


Fig. 4. Preferred Reporting Items for Systematic Reviews and Meta-analyses (PRISMA) flow chart.

dose was associated with relapsing disease (29.5% vs. 39.5%, $P = 0.0159$). Few new-onset or relapsing events were reported after booster dose (0.7% vs. 1.2% respectively, $P = 0.6216$). New-onset conditions and relapsing disease were more common in women (51.5% and 62.9%, respectively; $P = 0.0081$). The groups were evenly balanced in age ($P = 0.7851$). No deaths were recorded after the disease relapsed, while 4.7% (35/920) of patients with new-onset conditions died ($P = 0.0013$).

4. Discussion

The pandemic's influence has boosted vaccine development, allowing them to be manufactured in record time. As a result, many vaccines with unique and promising modes of action have been developed. However, the quick deployment has raised several issues, including their safety, which could be linked to the dose given and the age of the patients (occurring before 55 years of age in most cases) [468].

We report six new patients who had autoimmune and auto-inflammatory diseases, either for the first time or as a relapse. As revealed in the systematic review, these adverse effects have been previously reported in the literature. The most common diseases linked to immunization were thrombocytopenia, myocarditis, GBS, nephropathy, and thyroid disorders. It is remarkable since some of these diseases are

usually triggered by infections and other vaccines [469–471]. It suggests similar immunopathogenic mechanisms between vaccines and infectious agents as triggering factors of ADs. This hypothesis could be supported through the *anti*-idiotype immune response, which shows that antibodies against a specific antigen can trigger the production of second particular antibodies against the first ones [472]. Surprisingly, the second antibodies may be capable of binding to receptors that the initial antigen may attach to. This is significant since many autoimmune or autoinflammatory reactions elicited by COVID-19 vaccinations have previously been reported with vaccines whose principal immunopathogenic mechanism is the *anti*-idiotype immune response [473,474].

SARS-CoV-2 might trigger ADs [475] through different mechanisms, including molecular mimicry [476,477]. Several studies have demonstrated that the history of past infections can alter the reactivity of mRNA vaccines through a cross-reactivity mechanism [468]. However, greater reactivity may confer higher protection but could generate more adverse events. Remarkably, patients with ADs are not at increased risk of adverse events associated with vaccination [478], possibly due to the effect of immunomodulatory drugs on vaccine immunogenicity.

Although RNA-based vaccines focus on synthesizing antigens that facilitate immunogenicity [479], the mRNA may bind to pattern recognition receptors (PRRs) in the cytosol or on the endosomes before

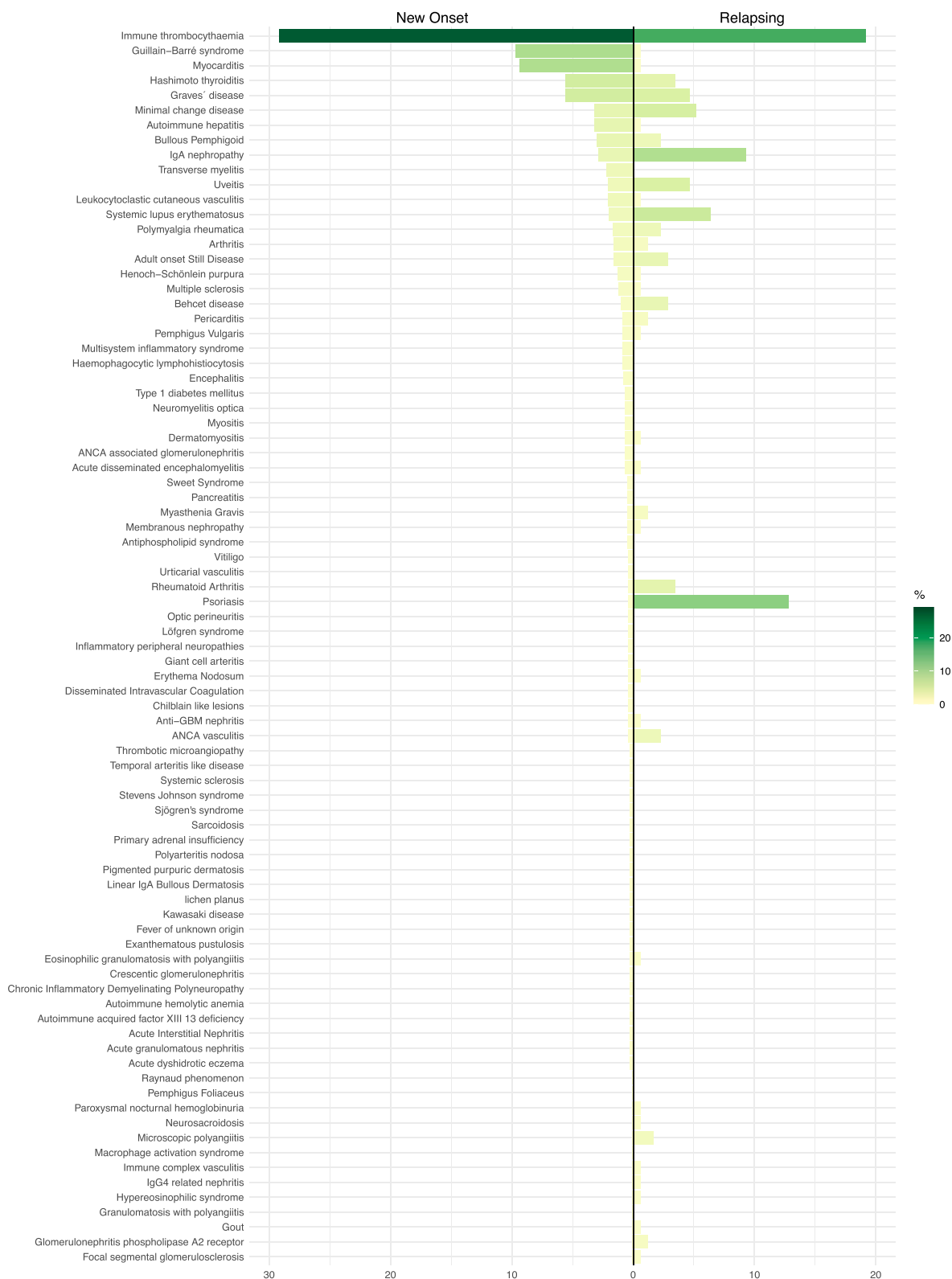

Fig. 6. Distribution of the main documented diseases after COVID-19 vaccination.

Table 2

Demographic, laboratory, clinical characteristics, treatment, and clinical outcomes of the systematic review of patients.

	New onset (n: 756)	Relapsing (n: 172)	<i>P</i> value
Demographic characteristics			
Age (IQR)	48 (33–66)	46 (34–66)	0.7851
Days of onset of symptoms since vaccination (IQR)	8 (3–14)	7 (2–13.25)	0.0094
Gender			0.0081
Male	359/740 (48.5%)	63/170 (37.1%)	
Female	381/740 (51.5%)	107/170 (62.9%)	
Systemic lupus erythematosus	15 (2.0%)	11 (6.4%)	0.0038
Antiphospholipid syndrome	4 (0.5%)	0 (0.0%)	1.0000
Immune thrombocytopenia	221 (29.2%)	33 (19.2%)	0.0079
Disseminated intravascular coagulation	3 (0.4%)	0 (0.0%)	1.0000
Thrombotic microangiopathy	2 (0.3%)	0 (0.0%)	1.0000
Autoimmune acquired factor XIII/13	2 (0.3%)	0 (0.0%)	1.0000
Autoimmune hemolytic anemia	2 (0.3%)	0 (0.0%)	1.0000
Acute disseminated encephalomyelitis	5 (0.7%)	1 (0.6%)	1.0000
Encephalitis	6 (0.8%)	0 (0.0%)	0.5998
Guillain-Barré syndrome	73 (9.7%)	1 (0.6%)	< 1e-04
Chronic inflammatory demyelinating polyneuropathy	2 (0.3%)	0 (0.0%)	1.0000
Multiple sclerosis	9 (1.2%)	1 (0.6%)	0.6984
Transverse myelitis	17 (2.2%)	0 (0.0%)	0.0541
Optic perineuritis	3 (0.4%)	0 (0.0%)	1.0000
Neuromyelitis optica	5 (0.7%)	0 (0.0%)	0.5907
Inflammatory peripheral neuropathies	3 (0.4%)	0 (0.0%)	1.0000
Myasthenia Gravis	4 (0.5%)	2 (1.2%)	0.3086
Uveitis	16 (2.1%)	8 (4.7%)	0.0658
Graves' disease	42 (5.6%)	8 (4.7%)	0.8513
Hashimoto thyroiditis	42 (5.6%)	6 (3.5%)	0.3415
Type 1 diabetes mellitus	5 (0.7%)	0 (0.0%)	0.5907
Primary adrenal insufficiency	2 (0.3%)	0 (0.0%)	1.0000
Autoimmune hepatitis	24 (3.2%)	1 (0.6%)	0.0662
Pancreatitis	4 (0.5%)	0 (0.0%)	1.0000
Acute granulomatous nephritis	2 (0.3%)	0 (0.0%)	1.0000
Acute interstitial nephritis	2 (0.3%)	0 (0.0%)	1.0000
ANCA associated glomerulonephritis	5 (0.7%)	0 (0.0%)	0.5907
Anti-GBM nephritis	3 (0.4%)	1 (0.6%)	0.5602
Minimal change disease	24 (3.2%)	9 (5.2%)	0.1781
IgG4 related nephritis	1 (0.1%)	1 (0.6%)	0.3365
Membranous nephropathy	4 (0.5%)	1 (0.6%)	1.0000
Crescentic glomerulonephritis	2 (0.3%)	0 (0.0%)	1.0000
IgA nephropathy	22 (2.9%)	16 (9.3%)	0.0008
Focal segmental glomerulosclerosis	1 (0.1%)	1 (0.6%)	0.3365
Glomerulonephritis phospholipase A2 receptor	1 (0.1%)	2 (1.2%)	0.0900
Paroxysmal nocturnal hemoglobinuria	1 (0.1%)	1 (0.6%)	0.3365
Myocarditis	71 (9.4%)	1 (0.6%)	< 1e-04
Pericarditis	7 (0.9%)	2 (1.2%)	0.6758
Sjogren's syndrome	2 (0.3%)	0 (0.0%)	1.0000
Rheumatoid arthritis	3 (0.4%)	6 (3.5%)	0.0019
Arthritis	12 (1.6%)	2 (1.2%)	1.0000
Polymyalgia Rheumatica	13 (1.7%)	4 (2.3%)	0.5361
Myositis	5 (0.7%)	0 (0.0%)	0.5907
Gout	1 (0.1%)	1 (0.6%)	0.3365
Adult onset Still Disease	12 (1.6%)	5 (2.9%)	0.2218
Behcet disease	1 (0.1%)	5 (2.9%)	0.0011
ANCA vasculitis	3 (0.4%)	4 (2.3%)	0.0251
Granulomatosis with polyangiitis	1 (0.1%)	0 (0.0%)	1.0000
Raynaud phenomenon	1 (0.1%)	0 (0.0%)	1.0000
Giant cell arteritis	3 (0.4%)	0 (0.0%)	1.0000
Henoch-Schönlein purpura	10 (1.3%)	1 (0.6%)	0.6996
Leukocytoclastic vasculitis	16 (2.1%)	1 (0.6%)	0.3389
Urticarial vasculitis	3 (0.4%)	0 (0.0%)	1.0000
Microscopic polyangiitis	1 (0.1%)	3 (1.7%)	0.0217
Eosinophilic granulomatosis with polyangiitis	2 (0.3%)	1 (0.6%)	0.4597

Table 2 (continued)

Demographic characteristics	New onset (n: 756)	Relapsing (n: 172)	<i>P</i> value
Demographic characteristics			
Polyarteritis nodosa	2 (0.3%)	0 (0.0%)	1.0000
Immune complex vasculitis	1 (0.1%)	1 (0.6%)	0.3365
Kawasaki Disease	2 (0.3%)	0 (0.0%)	1.0000
Temporal arteritis like disease	2 (0.3%)	0 (0.0%)	1.0000
Löfgren syndrome	3 (0.4%)	0 (0.0%)	1.0000
Erythema nodosum	3 (0.4%)	1 (0.6%)	0.5602
Neurosacroïdosis	1 (0.1%)	1 (0.6%)	0.3365
Macrophage activation syndrome	1 (0.1%)	0 (0.0%)	1.0000
Hypereosinophilic syndrome	1 (0.1%)	1 (0.6%)	0.3365
Hemophagocytic lymphohistiocytosis	7 (0.9%)	0 (0.0%)	0.3599
Fever of unknown origin	2 (0.3%)	0 (0.0%)	1.0000
Multisystem inflammatory syndrome	7 (0.9%)	0 (0.0%)	0.3599
Systemic sclerosis	2 (0.3%)	0 (0.0%)	1.0000
Vitiligo	3 (0.4%)	0 (0.0%)	1.0000
Dermatomyositis	5 (0.7%)	1 (0.6%)	1.0000
Psoriasis	3 (0.4%)	22 (12.8%)	< 1e-04
Bullous pemphigoid	23 (3.0%)	4 (2.3%)	0.8029
Pemphigus vulgaris	7 (0.9%)	1 (0.6%)	1.0000
Pemphigus foliaceus	1 (0.1%)	0 (0.0%)	1.0000
Acute dyshidrotic eczema	2 (0.3%)	0 (0.0%)	1.0000
Stevens Johnson syndrome	2 (0.3%)	0 (0.0%)	1.0000
Linear IgA bullous dermatosis	2 (0.3%)	0 (0.0%)	1.0000
Chilblain like lesions	3 (0.4%)	0 (0.0%)	1.0000
Sweet syndrome	4 (0.5%)	0 (0.0%)	1.0000
Lichen planus	2 (0.3%)	0 (0.0%)	1.0000
Pigmented purpuric dermatosis	2 (0.3%)	0 (0.0%)	1.0000
Exanthematous pustulosis	2 (0.3%)	0 (0.0%)	1.0000
Sarcoidosis	2 (0.3%)	0 (0.0%)	1.0000
Laboratory characteristics			
Elevated D Dimer	95 (15.5%)	1 (0.7%)	< 1e-04
CSF albuminocytological dissociation	48 (7.8%)	1 (0.7%)	0.0003
Thrombocytopenia	225 (35.5%)	36 (23.2%)	0.0032
Proteinuria	53 (8.7%)	24 (16.1%)	0.0098
Haematuria	40 (6.5%)	20 (13.4%)	0.0098
Gadolinium enhancement of the myocardium pericardium	35 (5.7%)	0 (0.0%)	0.0007
Diffuse ST elevations	28 (4.6%)	1 (0.7%)	0.0285
Elevated troponin	69 (11.3%)	1 (0.7%)	< 1e-04
Subepicardial enhancement	21 (3.4%)	0 (0.0%)	0.0212
Clinical characteristics			
Arthralgia arthritis	32 (5.2%)	17 (11.3%)	0.0092
Headache	39 (6.4%)	3 (2.0%)	0.0432
Praesthesia	33 (5.3%)	1 (0.7%)	0.0075
Weakness	70 (11.1%)	5 (3.3%)	0.0020
Pleurisy	6 (1.0%)	7 (4.6%)	0.0062
Treatment			
Corticosteroids	400 (52.9%)	112 (65.1%)	0.0039
Anticoagulants/antiaggregants	77 (10.2%)	0 (0.0%)	< 1e-04
IV immunoglobulins	160 (21.2%)	18 (10.5%)	0.0009
Transfusion of blood products: platelet	56 (7.4%)	5 (2.9%)	0.0389
NSAIDs	61 (8.1%)	6 (3.5%)	0.0341
Cyclosporine	3 (0.4%)	4 (2.3%)	0.0251
Diuretics/ACE inhibitor/calcium channel blocker/beta blocker/angiotensin II receptor antagonist	49 (6.5%)	3 (1.7%)	0.0153
Tacrolimus	2 (0.3%)	3 (1.7%)	0.0468
Ixekizumab	0 (0.0%)	2 (1.2%)	0.0342
Clinical outcomes			
Good response	342 (45.7%)	81 (47.4%)	0.7339
Resistance	236 (31.5%)	57 (33.3%)	0.6500
Relapse	20 (2.7%)	1 (0.6%)	0.1515
Death	35 (4.7%)	0 (0.0%)	0.0013

IQR: Interquartile range, ANCA: Antineutrophil cytoplasmic antibody, CSF: cerebrospinal fluid, PF4: Platelet factor 4, NSAIDs: Non-steroidal anti-inflammatory drugs, ACE: Angiotensin-converting enzyme.

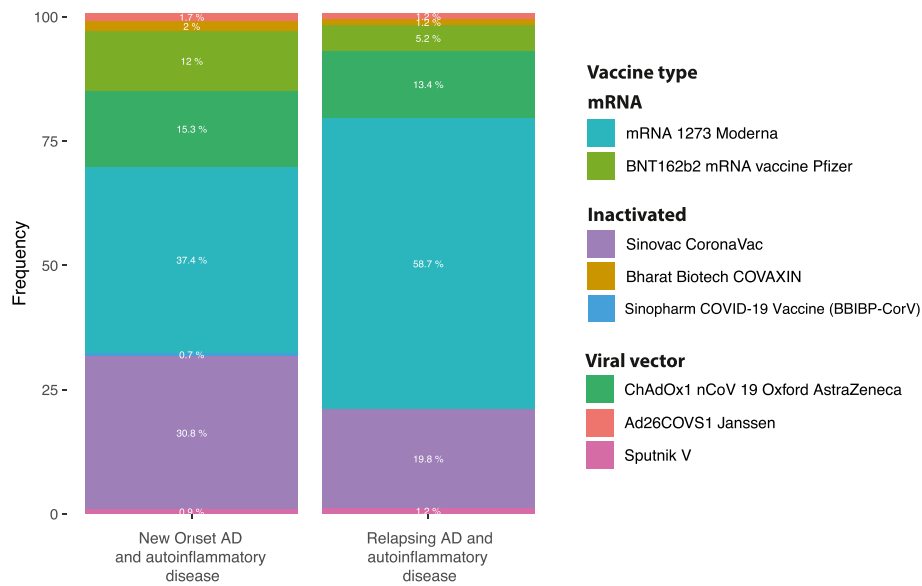


Fig. 7. Autoimmune and autoinflammatory conditions after COVID-19 vaccine according to vaccine type.

complex is taken up by antigen-presenting cells, later facilitating the production of antibodies against PF4 [489]. A recent study showed the structure of ChAdOx1/AZD-1222, evidencing a strong electronegative potential in the ChAdOx1 viral capsid, facilitating its binding with proteins such as PF4 [490].

Recently, the association between VITT and neutrophil activation was studied. It can occur through different signaling pathways and could be facilitated by NETosis and platelet activation [491]. Another mechanism that could explain the presence of VITT may be related to the activation of the NF- κ B pathway. Plasminogen activator inhibitor-1 (PAI-1) plays a relevant role in thrombotic events. It has been described that the presence of TNF alpha can promote an increase in serum concentrations of PAI 1 in sepsis. In addition, nuclear translocation of NF- κ B in monocytes has been described, increasing the expression of tissue factor (TF) and increasing the expression of thrombin expression [492]. Besides being produced in monocytes, it is also expressed in the endothelium [493]. Due to the direct effect of NF- κ B on monocytes, the production of cytokines, such as interleukin 1 β , can generate procoagulant states [494,495].

5. Conclusions

There is likely an association between COVID-19 vaccination and autoimmune and inflammatory diseases. Some ADs seem to be more common than others. The mechanisms of autoimmunity induction by COVID-19 vaccines and SARS-CoV-2 infection may be similar. Large, well-controlled studies are warranted to validate this relationship and assess additional variables such as genetic and environmental influences. Further detailed studies focusing on mechanisms, including molecular mimicry and bystander activation, will be essential to explain these rare events. Noteworthy, these rare events should not deter the use of this and other necessary vaccinations.

Funding

This study was supported by Universidad del Rosario (grant ABN011) and LifeFactors.

Declaration of competing interest

The authors declare that they have no known competing financial

interests or personal relationships that could have appeared to influence the work reported in this paper.

Data availability

Data will be made available on request.

Acknowledgments

None.

References

- [1] COVID-19 Dashboard 2022, Cent. Syst. Sci. Eng. Johns Hopkins Univ. (2022). <https://coronavirus.jhu.edu/map.html> (accessed June 1, 2022).
- [2] Q. Zhang, Z. Wang, Y. Lv, J. Zhao, Q. Dang, D. Xu, D. Zhao, H. Liu, Z. Wang, X. Zhao, Z. Xu, X. Zhang, Clinical features and prognostic factors of patients with COVID-19 in Henan Province, China, Hum. Cell 34 (2021) 419–435, <https://doi.org/10.1007/s13577-021-00499-y>.
- [3] W.-J. Guan, Z.-Y. Ni, Y. Hu, W.-H. Liang, C.-Q. Ou, J.-X. He, L. Liu, H. Shan, C.-L. Lei, D.S.C. Hui, B. Du, L.-J. Li, G. Zeng, K.-Y. Yuen, R.-C. Chen, C.-L. Tang, T. Wang, P.-Y. Chen, J. Xiang, S.-Y. Li, J.-L. Wang, Z.-J. Liang, Y.-X. Peng, L. Wei, Y. Liu, Y.-H. Hu, P. Peng, J.-M. Wang, J.-Y. Liu, Z. Chen, G. Li, Z.-J. Zheng, S.-Q. Qiu, J. Luo, C.-J. Ye, S.-Y. Zhu, N.-S. Zhong, China medical treatment expert group for covid-19, clinical characteristics of coronavirus disease 2019 in China., N. Engl. J. Med. 382 (2020) 1708–1720, <https://doi.org/10.1056/NEJMoa2002032>.
- [4] S. Hojyo, M. Uchida, K. Tanaka, R. Hasebe, Y. Tanaka, M. Murakami, T. Hirano, How COVID-19 induces cytokine storm with high mortality, Inflamm. Regen. 40 (2020) 37, <https://doi.org/10.1186/s41232-020-00146-3>.
- [5] Q. Huang, X. Wu, X. Zheng, S. Luo, S. Xu, J. Weng, Targeting inflammation and cytokine storm in COVID-19, Pharmacol. Res. 159 (2020) 105051, <https://doi.org/10.1016/j.phrs.2020.105051>.
- [6] J. Mellet, M.S. Pepper, A COVID-19 vaccine: big strides come with big challenges., Vaccines 9 (2021), <https://doi.org/10.3390/vaccines9010039>.
- [7] D.C. Wraith, M. Goldman, P.-H. Lambert, Vaccination and autoimmune disease: what is the evidence? Lancet (London, England) 362 (2003) 1659–1666, [https://doi.org/10.1016/S0140-6736\(03\)14802-7](https://doi.org/10.1016/S0140-6736(03)14802-7).
- [8] Y. Segal, Y. Shoenfeld, Vaccine-induced autoimmunity: the role of molecular mimicry and immune crossreaction, Cell. Mol. Immunol. 15 (2018) 586–594, <https://doi.org/10.1038/cmi.2017.151>.
- [9] Y. Chen, Z. Xu, P. Wang, X.-M. Li, Z.-W. Shuai, D.-Q. Ye, H.-F. Pan, New-onset autoimmune phenomena post-COVID-19 vaccination, Immunology 165 (2022) 386–401, <https://doi.org/10.1111/imm.13443>.
- [10] S. Abu, A. Roguin, E. Hellou, A. Ishai, U. Shoshan, L. Mahamid, Since January 2020 Elsevier has created a COVID-19 resource centre with free information in English and Mandarin on the novel coronavirus COVID-19. The COVID-19 resource centre is hosted on Elsevier Connect, the company's public news and information (2020).

- [11] C. Baumkhaledov, S. Makhmudov, A. Botabekova, Seropositive rheumatoid arthritis after vaccination against SARS-CoV-2 infection, *Int. J. Rheum. Dis* 24 (2021) 1440–1441, <https://doi.org/10.1111/1756-185X.14220>.
- [12] Y. Gi, W. Ju, Y. Ha, J. Ban, S. Ah, J. Sung, Sensory Guillain-Barre syndrome following the ChAdOx1 nCov-19 vaccine: Report of two cases and review of literature (2020).
- [13] M. Jawed, A. Khalid, M. Rubin, R. Shafiq, N. Cemalovic, Acute immune thrombocytopenia (ITP) following COVID-19 vaccination in a patient with previously stable ITP, *open forum infect. Dis* 8 (2021) 2018–2020, <https://doi.org/10.1093/ofid/ofab343>.
- [14] I. Kaur, S. Zafar, E. Capite, R. Khaney, COVID-19 vaccination as a potential trigger for new-onset systemic lupus erythematosus, *Cureus* 14 (2022) 1–7, <https://doi.org/10.7759/cureus.21917>.
- [15] K. Toljan, M. Amin, A. Kunchook, D. Ontaneda, New diagnosis of multiple sclerosis in the setting of mRNA COVID-19 vaccine exposure, *J. Neuroimmunol.* 362 (2022), <https://doi.org/10.1016/j.jneuroim.2021.577785>.
- [16] D. Moher, A. Liberati, J. Tetzlaff, D.G. Altman, Preferred reporting Items for systematic reviews and meta-analyses: the PRISMA statement., *PLoS Med.* 6 (2009), e1000097, <https://doi.org/10.1371/journal.pmed.1000097>.
- [17] S. Chen, X.-R. Fan, S. He, J.-W. Zhang, S.-J. Li, Watch out for neuromyelitis optica spectrum disorder after inactivated virus vaccination for COVID-19, *Neurol. Sci. Off. J. Ital. Neurol. Soc. Ital. Soc. Clin. Neurophysiol* 42 (2021) 3537–3539, <https://doi.org/10.1007/s10072-021-05427-4>.
- [18] C. Rodríguez, A. Pérez-Nieva, L. Máiz, M.D.M. Meijón, P. Llamas, M. Monreal, B. Bikkdeli, D. Jiménez, Vaccine-induced immune thrombotic thrombocytopenia after the BNT162b2 mRNA Covid-19 vaccine: a case study., *Thromb. Res.* 208 (2021) 1–3, <https://doi.org/10.1016/j.thromres.2021.10.002>.
- [19] P. Kulsirichawaroj, O. Sanmaneechai, O. Wittawatmongkol, K. Choekhaibulkit, Polyneuritis cranialis associated with BNT162b2 mRNA COVID-19 vaccine in a healthy adolescent, *Vaccines* 10 (2022), <https://doi.org/10.3390/vaccines10010134>.
- [20] C. Manzo, M. Natale, A. Castagna, Polymyalgia rheumatica as uncommon adverse event following immunization with COVID-19 vaccine: a case report and review of literature, *Aging Med. (Milt.)* 4 (2021) 234–238, <https://doi.org/10.1002/agsm.2.12171>.
- [21] H. Hyun, J.Y. Song, H. Seong, J.G. Yoon, J.Y. Noh, H.J. Cheong, W.J. Kim, Polyarthralgia, Myalgia Syndrome, After ChAdOx1 nCoV-19 vaccination, *J. Kor. Med. Sci.* 36 (2021), <https://doi.org/10.3346/jkms.2021.36.e245>.
- [22] M.F. Atak, B. Farabi, M.B. Kalelioglu, B.K. Rao, Pigmented purpuric dermatosis after BNT162B2 mRNA COVID-19 vaccine administration, *J. Cosmet. Dermatol.* 21 (2022) 435–437, <https://doi.org/10.1111/jocd.14607>.
- [23] E. Tano, S. San Martin, S. Girgis, Y. Martinez-Fernandez, C. Sanchez Vegas, Perimyocarditis in adolescents after pfizer-BioNTech COVID-19 vaccine., *J. Pediatric Infect. Disabil. Soc.* 10 (2021) 962–966, <https://doi.org/10.1093/jpids/piab060>.
- [24] A.A. Hasnie, U.A. Hasnie, N. Patel, M.U. Aziz, M. Xie, S.G. Lloyd, S.D. Prabhu, Perimyocarditis following first dose of the mRNA-1273 SARS-CoV-2 (Moderna) vaccine in a healthy young male: a case report., *BMC Cardiovasc. Disord* 21 (2021) 375, <https://doi.org/10.1186/s12872-021-02183-3>.
- [25] H.W. Kim, E.R. Jenista, D.C. Wendell, C.F. Azevedo, M.J. Campbell, S.N. Darty, M.A. Parker, R.J. Kim, Patients with acute myocarditis following mRNA COVID-19 vaccination, *JAMA Cardiol* 6 (2021) 1196–1201, <https://doi.org/10.1001/jamacardio.2021.2828>.
- [26] M. Scully, D. Singh, R. Lown, A. Poles, T. Solomon, M. Levi, D. Goldblatt, P. Kotoucek, W. Thomas, W. Lester, Pathologic antibodies to platelet factor 4 after ChAdOx1 nCoV-19 vaccination., *N. Engl. J. Med.* 384 (2021) 2202–2211, <https://doi.org/10.1056/NEJMoa2105385>.
- [27] L.I. Mudie, J.D. Zick, M.S. Dacey, A.G. Palestine, Panuveitis following vaccination for COVID-19, *Ocul. Immunol. Inflamm.* 29 (2021) 741–742, <https://doi.org/10.1080/09273948.2021.1949478>.
- [28] C. García-Estrada, E. Gómez-Figueroa, L. Alban, A. Arias-Cárdenas, Optic neuritis after COVID-19 vaccine application., *Clin. Exp. Neuroimmunol* (2021), <https://doi.org/10.1111/cen3.12682>.
- [29] M. Lavin, P.T. Elder, D. O’Keeffe, H. Enright, E. Ryan, A. Kelly, E. El Hassadi, F. P. McNicholl, G. Benson, G.N. Le, M. Byrne, K. Ryan, N.M. O’Connell, J. S. O’Donnell, Vaccine-induced immune thrombotic thrombocytopenia (VITT) - a novel clinico-pathological entity with heterogeneous clinical presentations, *Br. J. Haematol.* 195 (2021) 76–84, <https://doi.org/10.1111/bjh.17613>.
- [30] J. Kaminetsky, D. Rudikoff, New-onset vitiligo following mRNA-1273 (Moderna) COVID-19 vaccination, *Clin. Case Reports* 9 (2021), e04865, <https://doi.org/10.1002/ccr3.4865>.
- [31] M.F. Zavala-Miranda, S.G. González-Ibarra, A.A. Pérez-Arias, N.O. Uribe-Uribe, J. M. Mejía-Vilet, New-onset systemic lupus erythematosus beginning as class V lupus nephritis after COVID-19 vaccination, *Kidney Int.* 100 (2021) 1340–1341, <https://doi.org/10.1016/j.kint.2021.09.009>.
- [32] L. Báez-Negrón, L.M. Vilá, New-onset systemic lupus erythematosus after mRNA SARS-CoV-2 vaccination., *case rep. Rheumatol* 2022 (2022) 6436839, <https://doi.org/10.1155/2022/6436839>.
- [33] J.H. Lim, M.H. Han, Y.J. Kim, M.S. Kim, H.Y. Jung, J.Y. Choi, J.H. Cho, C.D. Kim, Y.L. Kim, S.H. Park, New-onset nephrotic syndrome after janssen COVID-19 vaccination: a case report and literature review, *J. Kor. Med. Sci.* 36 (2021), <https://doi.org/10.3346/jkms.2021.36.e218>.
- [34] E. Bostan, D. Gulseren, O. Gokoz, New-onset leukocytoclastic vasculitis after COVID-19 vaccine, *Int. J. Dermatol.* 60 (2021) 1305–1306, <https://doi.org/10.1111/ijd.15777>.
- [35] S. Nakatani, K. Mori, F. Morioka, C. Hirata, A. Tsuda, H. Uedono, E. Ishimura, D. Tsuruta, M. Emoto, New-onset kidney biopsy-proven IgA vasculitis after receiving mRNA-1273 COVID-19 vaccine: case report., *CEN Case Reports* (2022) 1–5, <https://doi.org/10.1007/s13730-021-00677-9>.
- [36] D. Hidaka, R. Ogasawara, S. Sugimura, F. Fujii, K. Kojima, J. Nagai, K. Ebata, K. Okada, N. Kobayashi, M. Ogasawara, M. Imamura, S. Ota, New-onset Evans syndrome associated with systemic lupus erythematosus after BNT162b2 mRNA COVID-19 vaccination, *Int. J. Hematol.* 115 (2022) 424–427, <https://doi.org/10.1007/s12185-021-03243-2>.
- [37] R. Merhy, A.-S. Sarkis, J. Kaikati, L. El Khoury, S. Ghosn, F. Stephan, New-onset cutaneous lichen planus triggered by COVID-19 vaccination, *J. Eur. Acad. Dermatol. Venereol.* 35 (2021) e729–e730, <https://doi.org/10.1111/jdv.17504>.
- [38] T. Zhou, F. Fronhoffs, L. Dold, C.P. Strassburg, T.J. Weismüller, New-onset autoimmune hepatitis following mRNA COVID-19 vaccination in a 36-year-old woman with primary sclerosing cholangitis - should we be more vigilant? *J. Hepatol.* 76 (2022) 218–220, <https://doi.org/10.1016/j.jhep.2021.08.006>.
- [39] H.J. Kim, M. Jung, B.J. Lim, S.H. Han, New-onset class III lupus nephritis with multi-organ involvement after COVID-19 vaccination, *Kidney Int.* 101 (2022) 826–828, <https://doi.org/10.1016/j.kint.2022.01.013>.
- [40] T. Rabinovitch, Y. Ben-Arie-Weintrob, T. Hareuveni-Blum, B. Shaer, V. Vishnevskia-Dai, S. Shulman, H. Newman, M. Biadsy, D. Masarwa, N. Fischer, O. Yovel, S. Goldfeather-Ben Zaken, Z. Habot-Wilner, UVEITIS after the BNT162b2 mRNA vaccination against SARS-CoV-2 infection: a possible association., *Retina* 41 (2021) 2462–2471, <https://doi.org/10.1097/IAE.0000000000003277>.
- [41] S. Padiyar, N. Kamath, J. Mathew, A.S. Chandu, D. Deodhar, B.A. Shastry, T. Shashikala, A. Ganapati, New-onset Adult-onset Still’s disease-like syndrome after ChAdOx1 nCoV-19 vaccination - a case series with review of literature., *Clin. Rheumatol* (2022) 1–7, <https://doi.org/10.1007/s10067-022-06065-7>.
- [42] C. Bennett, L.M. Chambers, J. Son, O. Goje, Newly diagnosed immune thrombocytopenia in a pregnant patient after coronavirus disease 2019 vaccination, *J. Obstet. Gynaecol. Res.* 47 (2021) 4077–4080, <https://doi.org/10.1111/jog.14978>.
- [43] T. Horino, D. Sawamura, S. Inotani, M. Ishihara, M. Komori, O. Ichii, Newly diagnosed IgA Nephropathy with gross haematuria following COVID-19 vaccination, *QJM* 115 (2022) 28–29, <https://doi.org/10.1093/qjmed/hcab305>.
- [44] K. Toljan, M. Amin, A. Kunchook, D. Ontaneda, New diagnosis of multiple sclerosis in the setting of mRNA COVID-19 vaccine exposure, *J. Neuroimmunol.* 362 (2022) 577785, <https://doi.org/10.1016/j.jneuroim.2021.577785>.
- [45] P. Fujikawa, F.A. Shah, M. Braford, K. Patel, J. Madey, Neuromyelitis optica in a healthy female after severe acute respiratory syndrome coronavirus 2 mRNA-1273 vaccine, *Cureus* 13 (2021), e17961, <https://doi.org/10.7759/cureus.17961>.
- [46] S. Waheed, A. Bayas, F. Hindi, Z. Rizvi, P.S. Espinosa, Neurological complications of COVID-19: guillain-barre syndrome following pfizer COVID-19 vaccine, *Cureus* 13 (2021), e13426, <https://doi.org/10.7759/cureus.13426>.
- [47] Y.J. Anupama, R.G.N. Patel, M. Vankalakunti, Nephrotic syndrome following ChAdOx1 nCoV-19 vaccine against SARS-CoV-2., *kidney int, Report* 6 (2021) 2248, <https://doi.org/10.1016/j.ekir.2021.06.024>.
- [48] S. Unver, A. Haholu, S. Yildirim, Nephrotic syndrome and acute kidney injury following CoronaVac anti-SARS-CoV-2 vaccine, *Clin. Kidney J* 14 (2021) 2608–2611, <https://doi.org/10.1093/ckj/sfab155>.
- [49] I.R.B. Godoy, T.C. Rodrigues, A. Skaif, Myositis ossificans following COVID-19 vaccination, *QJM* 114 (2021) 659–660, <https://doi.org/10.1093/qjmed/hcab161>.
- [50] S. Al-Rasbi, J.S. Al-Maqbali, R. Al-Farsi, M.A. Al Shukaili, M.H. Al-Riyami, Z. Al Falah, H. Al Farhan, A.M. Al Alawi, Myocarditis, Pulmonary Hemorrhage, Extensive Myositis, With rhabdomyolysis 12 Days after first dose of pfizer-BioNTech BNT162b2 mRNA COVID-19 vaccine: a case report., *Am. J. Case Rep* 23 (2022), e934399, <https://doi.org/10.12659/AJCR.934399>.
- [51] G. Zetting, M. Krebs, Two further cases of Graves’ disease following SARS-Cov-2 vaccination, *J. Endocrinol. Invest.* 45 (2022) 227–228, <https://doi.org/10.1007/s40618-021-01650-0>.
- [52] C.M. Rosner, L. Genovese, B.N. Tehrani, M. Atkins, H. Bakhshi, S. Chaudhri, A. A. Damluji, J.A. de Lemos, S.S. Desai, A. Emaminia, M.C. Flanagan, A. Kherra, A. Maghsoudi, G. Mekonnen, A. Muthukumar, I.M. Saeed, M.W. Sherwood, S. S. Sinha, C.M. O’Connor, C.R. deFilippi, myocarditis temporally associated with COVID-19 vaccination, *Circulation* 144 (2021) 502–505, <https://doi.org/10.1161/CIRCULATIONAHA.121.055891>.
- [53] D. Levin, G. Shimon, M. Fadlon-Derai, L. Gershovitz, A. Shovali, A. Sebbag, S. Bader, N. Fink, B. Gordon, Myocarditis following COVID-19 vaccination - a case series, *Vaccine* 39 (2021) 6195–6200, <https://doi.org/10.1016/j.vaccine.2021.09.004>.
- [54] E. Albert, G. Aurigemma, J. Saucedo, D.S. Gerson, Myocarditis following COVID-19 vaccination, *Radiol. Case Reports* 16 (2021) 2142–2145, <https://doi.org/10.1016/j.radcr.2021.05.033>.
- [55] S. Abu Mouch, A. Roguin, E. Hellou, A. Ishai, U. Shoshan, L. Mahamid, M. Zoabi, M. Aisman, N. Goldschmid, N. erar Yanay, Myocarditis following COVID-19 mRNA vaccination, *Vaccine.* 39 (2021) 3790–3793, <https://doi.org/10.1016/j.vaccine.2021.05.087>.
- [56] J. Starekova, D.A. Bluemke, W.S. Bradham, T.M. Grist, M.L. Schiebler, S. B. Reeder, Myocarditis associated with mRNA COVID-19 vaccination, *Radiology* 301 (2021) E409–E411, <https://doi.org/10.1148/radiol.202111430>.
- [57] T. D’Angelo, A. Cattafi, M.L. Carej, C. Booz, G. Ascenti, G. Cicero, A. Blandino, S. Mazziotti, Myocarditis after SARS-CoV-2 vaccination: a vaccine-induced reaction?, *Can. J. Cardiol.* 37 (2021) 1665–1667, <https://doi.org/10.1016/j.cjca.2021.05.010>.

- [58] T. Takenaka, M. Matsuzaki, S. Fujiwara, M. Hayashida, H. Suyama, M. Kawamoto, Myeloperoxidase anti-neutrophil cytoplasmic antibody positive optic perineuritis after mRNA coronavirus disease-19 vaccine, *QJM* 114 (2021) 737–738, <https://doi.org/10.1093/qjmed/hcab227>.
- [59] A. Nune, K.P. Iyengar, C. Goddard, A.E. Ahmed, Multisystem inflammatory syndrome in an adult following the SARS-CoV-2 vaccine (MIS-V), *BMJ Case Rep.* 14 (2021), <https://doi.org/10.1136/bcr-2021-243888>.
- [60] E.D. Belay, S. Godfred Cato, A.K. Rao, J. Abrams, W.W. Wilson, S. Lim, C. Newton-Cheh, M. Melgar, J. DeCuir, B. Webb, P. Marquez, J.R. Su, L. Meng, H. N. Grome, E. Schlaudecker, K. Talaat, K. Edwards, E. Barnett, A.P. Campbell, K. R. Broder, S. Bamrah Morris, Multisystem Inflammatory Syndrome in Adults after SARS-CoV-2 infection and COVID-19 vaccination., *Clin. Infect. Dis. an Off. Publ. Infect. Dis. Soc. Am* (2021), <https://doi.org/10.1093/cid/ciab936>.
- [61] S. Leclerc, V. Royal, C. Lamarche, L.-P. Laurin, Minimal change disease with severe acute kidney injury following the oxford-AstraZeneca COVID-19 vaccine: a case report., *Am. J. Kidney Dis. Off. J. Natl. Kidney Found* 78 (2021) 607–610, <https://doi.org/10.1053/j.ajkd.2021.06.008>.
- [62] A. Psyllaki, I. Stavrakaki, A. Androvitsanea, H. Gakiopoulou, I. Petrakis, K. Stylianou, Two cases of glomerular involvement after vaccination against COVID-19: epiphenomenon or causality? *Clin. Kidney J* 15 (2022) 574–575, <https://doi.org/10.1093/ckj/sfab252>.
- [63] S. Kobayashi, K. Fugo, K. Yamazaki, H. Terawaki, Minimal change disease soon after Pfizer-BioNTech COVID-19 vaccination, *Clin. Kidney J* 14 (2021) 2606–2607, <https://doi.org/10.1093/ckj/sfab156>.
- [64] D. Kervella, L. Jacquemont, A. Chapelet-Debout, C. Deltombe, S. Ville, Minimal change disease relapse following SARS-CoV-2 mRNA vaccine, *Kidney Int.* 100 (2021) 457–458, <https://doi.org/10.1016/j.kint.2021.04.033>.
- [65] A.B. Dirim, S. Safak, B. Andac, N. Garayeva, E. Demir, A.S. Artan, Y. Ozluk, I. Kilicaslan, O.A. Oto, S. Ozturk, H. Yazici, Minimal change disease following vaccination with CoronaVac, *Clin. Kidney J* 14 (2021) 2268–2269, <https://doi.org/10.1093/ckj/sfab123>.
- [66] N. Mancianti, A. Guarneri, S. Tripodi, D.P. Salvo, G. Garosi, Minimal change disease following vaccination for SARS-CoV-2, *J. Nephrol.* 34 (2021) 1039–1040, <https://doi.org/10.1007/s40620-021-01091-1>.
- [67] L. Lebedev, M. Sapojnikov, A. Wechsler, R. Varadi-Levi, D. Zamir, A. Tobar, N. Levin-Iaina, S. Fytlovich, Y. Yagil, Minimal change disease following the pfizer-BioNTech COVID-19 vaccine., *Am. J. Kidney Dis. Off. J. Natl. Kidney Found* 78 (2021) 142–145, <https://doi.org/10.1053/j.ajkd.2021.03.010>.
- [68] A. Holzworth, P. Couchot, W. Cruz-Knight, M. Brucculeri, Minimal change disease following the Moderna mRNA-1273 SARS-CoV-2 vaccine, *Kidney Int.* 100 (2021) 463–464, <https://doi.org/10.1016/j.kint.2021.05.007>.
- [69] S. Thappy, S.R. Thalappil, S. Abbarh, A. Al-Mashdali, M. Akhtar, M.M. Alkadi, Minimal change disease following the Moderna COVID-19 vaccine: first case report, *BMC Nephrol.* 22 (2021) 376, <https://doi.org/10.1186/s12882-021-02583-9>.
- [70] V.D. D'Agati, S. Kudose, A.S. Bombback, A. Adamidis, A. Tartini, Minimal change disease and acute kidney injury following the Pfizer-BioNTech COVID-19 vaccine, *Kidney Int.* 100 (2021) 461–463, <https://doi.org/10.1016/j.kint.2021.04.035>.
- [71] P. Jongvilakasem, P. Rianthavorn, Minimal change disease and acute interstitial nephritis following SARS-CoV-2 BNT162b2 vaccination, *Pediatr. Nephrol.* 37 (2022) 1419–1421, <https://doi.org/10.1007/s00467-022-05470-z>.
- [72] J. Hanna, A. Ingram, T. Shao, Minimal change disease after first dose of pfizer-BioNTech COVID-19 vaccine: a case report and review of minimal change disease related to COVID-19 vaccine, *Can. J. Kidney Heal. Dis* 8 (2021), <https://doi.org/10.1177/20543581211058271>, 20543581211058270.
- [73] J. Kenda, D. Lovrić, M. Škerget, N. Milivojević, Treatment of ChAdOx1 nCoV-19 vaccine-induced immune thrombotic thrombocytopenia related acute ischemic stroke, *J. Stroke Cerebrovasc. Dis. Off. J. Natl. Stroke Assoc.* 30 (2021) 106072, <https://doi.org/10.1016/j.jstrokecerebrovasdis.2021.106072>.
- [74] Y.L. Dang, A. Bryson, Miller-Fisher Syndrome, Guillain-Barre, Syndrome overlap syndrome in a patient post Oxford-AstraZeneca SARS-CoV-2 vaccination, *BMJ Case Rep.* 14 (2021), <https://doi.org/10.1136/bcr-2021-246701>.
- [75] Y. Nishiguchi, H. Matsuyama, K. Maeda, A. Shindo, H. Tomimoto, Miller Fisher syndrome following BNT162b2 mRNA coronavirus 2019 vaccination, *BMC Neurol.* 21 (2021) 452, <https://doi.org/10.1186/s12883-021-02489-x>.
- [76] L. Gueguen, C. Loheac, N. Saidani, L. Khatchaturian, Membranous nephropathy following anti-COVID-19 mRNA vaccination, *Kidney Int.* 100 (2021) 1140–1141, <https://doi.org/10.1016/j.kint.2021.08.006>.
- [77] M. De Michele, M. Iacobucci, A. Chistolini, E. Nicolini, F. Pulcinelli, B. Cerbelli, E. Merenda, O.G. Schiavo, E. Sbardella, I. Berto, L. Petraglia, N. Caracciolo, M. Chiara, S. Truglia, D. Toni, Malignant cerebral infarction after ChAdOx1 nCoV-19 vaccination: a catastrophic variant of vaccine-induced immune thrombotic thrombocytopenia, *Nat. Commun.* 12 (2021) 4663, <https://doi.org/10.1038/s41467-021-25010-x>.
- [78] F. Muench, M. Krusche, L.E. Sander, T. Rose, G.-R. Burmester, U. Schneider, Macrophage activation syndrome in a patient with adult-onset Still's disease following first COVID-19 vaccination with BNT162b2, *BMC Rheumatol* 5 (2021) 60, <https://doi.org/10.1186/s41927-021-00237-9>.
- [79] A. Sekar, Lupus nephritis flare post Moderna mRNA-1273 coronavirus vaccine, *QJM* 114 (2022) 882–883, <https://doi.org/10.1093/qjmed/hcab284>.
- [80] S.R. Cohen, L. Prussick, J.S. Kahn, D.X. Gao, A. Radfar, D. Rosmarin, Leukocytoclastic vasculitis flare following the COVID-19 vaccine, *Int. J. Dermatol.* 60 (2021) 1032–1033, <https://doi.org/10.1111/ijd.15623>.
- [81] S. Sandhu, A. Bhatnagar, H. Kumar, P.K. Dixit, G. Paliwal, D.K. Suhag, C. Patil, D. Mitra, Leukocytoclastic vasculitis as a cutaneous manifestation of ChAdOx1 nCoV-19 corona virus vaccine (recombinant), *Dermatol. Ther.* 34 (2021), e15141, <https://doi.org/10.1111/dth.15141>.
- [82] A. Erler, J. Fiedler, A. Koch, F. Heldmann, A. Schütz, Leukocytoclastic vasculitis after vaccination with a SARS-CoV-2 vaccine, *Arthritis Rheumatol.* 73 (2021) 2188, <https://doi.org/10.1002/art.41910>.
- [83] W.J. Jin, S.W. Ahn, S.H. Jang, S.M. Hong, J.E. Seol, H. Kim, Leukocytoclastic vasculitis after coronavirus disease 2019 vaccination, *J. Dermatol.* 49 (2022) e34–e35, <https://doi.org/10.1111/1346-8138.16212>.
- [84] A. Kreuter, S.-N. Burmann, B. Burkert, F. Oellig, A.-L. Michalowitz, Transition of cutaneous into systemic lupus erythematosus following adenoviral vector-based SARS-CoV-2 vaccination, *J. Eur. Acad. Dermatol. Venereol.* 35 (2021) e733–e735, <https://doi.org/10.1111/jdv.17514>.
- [85] G. Fiorillo, S. Pancetti, A. Cortese, F. Toso, S. Manara, A. Costanzo, R.G. Borroni, Leukocytoclastic vasculitis (cutaneous small-vessel vasculitis) after COVID-19 vaccination, *J. Autoimmun.* 127 (2022) 102783, <https://doi.org/10.1016/j.jaut.2021.102783>.
- [86] P. Palla, C. Vergadis, S. Sakellariou, T. Androutsakos, Letter to the editor: autoimmune hepatitis after COVID-19 vaccination, *Hepatology* vol. 75 (2022) 489–490, <https://doi.org/10.1002/hep.32156>. A Rare Adverse Effect?.,
- [87] K. Park, S. Miyake, C. Tai, M. Tseng, N.K. Andeen, V.L. Kung, Letter regarding: "A case of gross hematuria and IgA nephropathy flare-up following SARS-CoV-2 vaccination", *kidney int, Report* 6 (2021) 2246–2247, <https://doi.org/10.1016/j.ekir.2021.06.007>.
- [88] N. Schwotzer, S. Kissling, F. Fakhouri, Letter regarding "Minimal change disease relapse following SARS-CoV-2 mRNA vaccine", *Kidney Int.* 100 (2021) 458–459, <https://doi.org/10.1016/j.kint.2021.05.006>.
- [89] P. Cory, H. Lawrence, H. Abdulrahim, H. Mahmood-Rao, A. Hussein, J. Gane, Lessons of the month 3: haemophagocytic lymphohistiocytosis following COVID-19 vaccination (ChAdOx1 nCoV-19), *Clin. Med.* 21 (2021) e677–e679, <https://doi.org/10.7861/clinmed.2021-0564>.
- [90] A.A. Notghi, J. Atley, M. Silva, Lessons of the month 1: longitudinal extensive transverse myelitis following AstraZeneca COVID-19 vaccination, *Clin. Med.* 21 (2021) e535–e538, <https://doi.org/10.7861/clinmed.2021-0470>.
- [91] H.Z. Tan, R.Y. Tan, J.C.J. Choo, C.C. Lim, C.S. Tan, A.H.L. Loh, C.S.-Y. Tien, P. H. Tan, K.T. Woo, Is COVID-19 vaccination unmasking glomerulonephritis? *Kidney Int.* 100 (2021) 469–471, <https://doi.org/10.1016/j.kint.2021.05.009>.
- [92] A. Kreuter, M.J. Licciardi-Fernandez, S.-N. Burmann, B. Burkert, F. Oellig, A.-L. Michalowitz, Induction and exacerbation of subacute cutaneous lupus erythematosus following mRNA-based or adenoviral vector-based SARS-CoV-2 vaccination, *Clin. Exp. Dermatol.* 47 (2022) 161–163, <https://doi.org/10.1111/ced.14858>.
- [93] J. Alabkal, A.D. Rebchuk, D. Lyndon, N. Randhawa, Incomplete subacute transverse myelitis following vaccination with pfizer-BioNTech COVID-19 mRNA vaccine: a case report., *Cureus* 13 (2021), e20460, <https://doi.org/10.7759/cureus.20460>.
- [94] T. Güneş, F. Can, S. Akıncı, Ö. Soyer Kösemehmetoğlu, İ. Dilek, Immune-Mediated thrombotic thrombocytopenic purpura after BNT162b2 vaccine, *Turkish J. Haematol. Off. J. Turkish Soc. Haematol* 39 (2022) 74–75, <https://doi.org/10.4274/tjh.galenos.2021.2021.0537>.
- [95] K.A. Lee, Y.J. Kim, H.Y. Jin, Thyrotoxicosis after COVID-19 vaccination: seven case reports and a literature review, *Endocrine* 74 (2021) 470–472, <https://doi.org/10.1007/s12020-021-02898-5>.
- [96] S. Banerjee, M. Sandhu, E. Tonzi, A. Tambe, H.S. Gambhir, Immune-Mediated thrombocytopenia associated with Ad26.COV2.S (janssen; johnson & johnson) vaccine, *Am. J. Therapeut.* 28 (2021) e604–e606, <https://doi.org/10.1097/MJT.0000000000001431>.
- [97] A. Watad, G. De Marco, H. Mahajna, A. Druyan, M. Elitzy, N. Hijazi, A. Haddad, M. Elias, D. Zisman, M.E. Naffaa, M. Brodavka, Y. Cohen, A. Abu-Much, M. A. Elhija, C. Bridgewood, P. Langevitz, J. McLorinan, N.L. Bragazzi, H. Marzo-Ortega, M. Lidar, C. Calabrese, L. Calabrese, E. Vital, Y. Shoenfeld, H. Amital, D. McGonagle, Immune-mediated disease flares or new-onset disease in 27 subjects following mrna/dna sars-cov-2 vaccination, *Vaccines* 9 (2021), <https://doi.org/10.3390/VACCINES9050435>.
- [98] R.B. Jasaraj, D.B. Shrestha, S. Gaire, M. Kassem, Immune thrombocytopenic purpura following pfizer-BioNTech COVID-19 vaccine in an elderly female, *Cureus* 13 (2021), <https://doi.org/10.7759/cureus.16871> e16871.
- [99] P.K. Krajewski, J.C. Szepletowski, Immune thrombocytopenic purpura associated with COVID-19 Pfizer-BioNTech BNT162b2 mRNA vaccine, *J. Eur. Acad. Dermatol. Venereol.* 35 (2021) e626–e627, <https://doi.org/10.1111/jdv.17444>.
- [100] A. Hines, J.G. Shen, C. Olazagasti, S. Shams, Immune thrombocytopenic purpura and acute liver injury after COVID-19 vaccine, *BMJ Case Rep.* 14 (2021), <https://doi.org/10.1136/bcr-2021-242678>.
- [101] F.-O. Paulsen, C. Schaefer, F. Langer, C. Frenzel, U. Wenzel, F.E. Hengel, C. Bokemeyer, C. Seidel, Immune thrombocytopenic purpura after vaccination with COVID-19 vaccine (ChAdOx1 nCoV-19), *Blood* 138 (2021) 996–999, <https://doi.org/10.1182/blood.2021012790>.
- [102] M. Candelli, E. Rossi, F. Valletta, V. De Stefano, F. Franceschi, Immune thrombocytopenic purpura after SARS-CoV-2 vaccine, *Br. J. Haematol.* 194 (2021) 547–549, <https://doi.org/10.1111/bjh.17508>.
- [103] H. Qasim, E. Ali, M.A. Yassin, Immune thrombocytopenia relapse post covid-19 vaccine in young male patient, *IDCases* 26 (2021), <https://doi.org/10.1016/j.idcr.2021.e01344> e01344.
- [104] E. A. Ali, Q. Al-Maharmeh, W.M. Rozi, M.B. Habib, M. Yassin, Immune thrombocytopenia purpura flare post COVID-19 vaccine, *Ann. Med. Surg* 75 (2022) 103164, <https://doi.org/10.1016/j.amsu.2021.103164>.

- [105] O. Tarawneh, H. Tarawneh, Immune thrombocytopenia in a 22-year-old post Covid-19 vaccine, *Am. J. Hematol.* 96 (2021) E133–E134, <https://doi.org/10.1002/ajh.26106>.
- [106] M. Pandya, G. Thota, X. Wang, H. Luo, Thyroiditis after COVID-19 mRNA vaccine: a case series., *aace Clin. Case Reports* 8 (2022) 116–118, <https://doi.org/10.1016/j.aace.2021.12.002>.
- [107] C. Ganzel, E. Ben-Chetrit, Immune thrombocytopenia following the pfizer-BioNTech BNT162b2 mRNA COVID-19 vaccine, *Isr. Med. Assoc. J.* 23 (2021) 341.
- [108] M. Fujita, H. Ureshino, A. Sugihara, A. Nishioka, S. Kimura, Immune thrombocytopenia exacerbation after COVID-19 vaccination in a young woman, *Cureus* 13 (2021), <https://doi.org/10.7759/cureus.17942> e17942.
- [109] H. Akiyama, S. Kakiuchi, J. Rikitake, H. Matsuba, D. Sekinada, Y. Kozuki, N. Iwata, Immune thrombocytopenia associated with Pfizer-BioNTech's BNT162b2 mRNA COVID-19 vaccine, *IDCases* 25 (2021), <https://doi.org/10.1016/j.idcr.2021.e01245> e01245.
- [110] R. Battegay, I. Istampoulouoglou, A. Holbro, A. Buser, J.R. Hirsiger, J. Eckstein, C. T. Berger, S. Koehlin, A.B. Leuppi-Taegtmeyer, Immune thrombocytopenia associated with COVID-19 mRNA vaccine tozinameran - a clinical case and global pharmacovigilance data., *Swiss Med. Wkly. Times* 151 (2021), <https://doi.org/10.4414/smw.2021.w30084> w30084.
- [111] M. Al-Ahmad, M. Al Rasheed, N. Shalaby, T. Rodriguez-Bouza, L. Altourah, Immune Thrombocytopenia (ITP): relapse Versus de novo After COVID-19 Vaccination., *Clin. Appl. Thromb. Off. J. Int. Acad. Clin. Appl. Thromb* 28 (2022), <https://doi.org/10.1177/10760296211073920>, 10760296211073920.
- [112] L. Badier, A. Toledano, T. Porel, S. Dumond, J. Jouglan, L. Sailler, H. Bagheri, G. Moulis, M. Lafaurie, IgA vasculitis in adult patient following vaccination by ChAdOx1 nCoV-19, *Autoimmun. Rev.* 20 (2021) 102951, <https://doi.org/10.1016/j.autrev.2021.102951>.
- [113] O. Niel, C. Florescu, IgA nephropathy presenting as rapidly progressive glomerulonephritis following first dose of COVID-19 vaccine, *Pediatr. Nephrol.* 37 (2022) 461–462, <https://doi.org/10.1007/s00467-021-05351-x>.
- [114] C. Hanna, L.P. Herrera Hernandez, L. Bu, S. Kizilbash, L. Najera, M.N. Rheault, J. Czyzyk, A.M. Kouri, IgA nephropathy presenting as macroscopic hematuria in 2 pediatric patients after receiving the Pfizer COVID-19 vaccine, *Kidney Int.* 100 (2021) 705–706, <https://doi.org/10.1016/j.kint.2021.06.032>.
- [115] T. Horino, IgA nephropathy flare-up following SARS-CoV-2 vaccination, *QJM* 114 (2021) 735–736, <https://doi.org/10.1093/qjmed/hcab223>.
- [116] M. Abramson, S. Mon-Wei Yu, K.N. Campbell, M. Chung, F. Salem, IgA nephropathy after SARS-CoV-2 vaccination, *Kidney Med* 3 (2021) 860–863, <https://doi.org/10.1016/j.xkme.2021.05.002>.
- [117] T.J. Rubinstein, Thyroid eye disease following COVID-19 vaccine in a patient with a history graves' disease: a case report., *ophthal. Plast. Reconstr. Surgery* 37 (2021) e221–e223, <https://doi.org/10.1097/IOP.0000000000002059>.
- [118] J.A. Julian, D.R. Mathern, D. Fernando, Idiopathic thrombocytopenic purpura and the moderna covid-19 vaccine, *Ann. Emerg. Med.* 77 (2021) 654–656, <https://doi.org/10.1016/j.annemergmed.2021.02.011>.
- [119] S. Kudose, P. Friedmann, O. Albajrami, V.D. D'Agati, Histologic correlates of gross hematuria following Moderna COVID-19 vaccine in patients with IgA nephropathy, *Kidney Int.* 100 (2021) 468–469, <https://doi.org/10.1016/j.kint.2021.06.011>.
- [120] E. Lindhoff-Last, L. Schoenborn, M. Piorkowski, J. Herold, A. Greinacher, J.-A. Sheppard, T.E. Warkentin, Heterogeneity of vaccine-induced immune thrombotic thrombocytopenia after ChAdOx1 nCoV-19 vaccination and safety of second vaccination with BNT162b2, *Thromb. Haemostasis* 122 (2022) 304–307, <https://doi.org/10.1055/a-1701-2926>.
- [121] A.M. Hines, N. Murphy, C. Mullin, J. Barillas, J.C. Barrientos, Henoch-Schönlein purpura presenting post COVID-19 vaccination, *Vaccine* 39 (2021) 4571–4572, <https://doi.org/10.1016/j.vaccine.2021.06.079>.
- [122] M.M. Sirufo, M. Raggiunti, L.M. Magnanini, L. Ginaldi, M. De Martinis, Henochschönlein purpura following the first dose of covid-19 viral vector vaccine: a case report., *Vaccines* 9 (2021), <https://doi.org/10.3390/VACCINES9101078>.
- [123] S. Ai, A. Awford, F. Roncolato, Hemophagocytic lymphohistiocytosis following ChAdOx1 nCoV-19 vaccination, *J. Med. Virol.* 94 (2022) 14–16, <https://doi.org/10.1002/jmv.27279>.
- [124] L.V. Tang, Y. Hu, Hemophagocytic lymphohistiocytosis after COVID-19 vaccination, *J. Hematol. Oncol.* 14 (2021) 87, <https://doi.org/10.1186/s13045-021-01100-7>.
- [125] L. Attwell, T. Zaw, J. McCormick, J. Marks, H. McCarthy, Haemophagocytic lymphohistiocytosis after ChAdOx1 nCoV-19 vaccination, *J. Clin. Pathol.* 75 (2022) 282–284, <https://doi.org/10.1136/jclinpath-2021-207760>.
- [126] D. Čensčák, L. Ungermaier, I. Stětárová, E. Ehler, Guillain-Barré Syndrome after First Vaccination Dose against COVID-19: Case Report., *Acta Medica (Hradec Kral.)* 64 (2021) 183–186, <https://doi.org/10.14712/18059694.2021.31>.
- [127] C.M. Allen, S. Ramsamy, A.W. Tarr, P.J. Tighe, W.L. Irving, R. Tanasescu, J. R. Evans, Guillain-barré syndrome variant occurring after SARS-CoV-2 vaccination, *Ann. Neurol.* 90 (2021) 315–318, <https://doi.org/10.1002/ana.26144>.
- [128] H. Aktas, G. Ertugrul, Vitiligo in a COVID-19-vaccinated patient with ulcerative colitis: coincidence? *Clin. Exp. Dermatol.* 47 (2022) 143–144, <https://doi.org/10.1111/ced.14842>.
- [129] A. Pujol, L.-A. Gómez, C. Gallegos, J. Nicolau, P. Sanchís, M. González-Freire, Á.A. López-González, K. Dotres, L. Masmiquel, Thyroid as a target of adjuvant autoimmunity/inflammatory syndrome due to mRNA-based SARS-CoV-2 vaccination: from Graves' disease to silent thyroiditis, *J. Endocrinol. Invest.* 45 (2022) 875–882, <https://doi.org/10.1007/s40618-021-01707-0>.
- [130] G. Kanabar, P. Wilkinson, Guillain-Barré syndrome presenting with facial diplegia following COVID-19 vaccination in two patients, *BMJ Case Rep.* 14 (2021), <https://doi.org/10.1136/bcr-2021-244527>.
- [131] A. Rossetti, G. Gheihman, M. O'Hare, J.M. Kosowsky, Guillain-barré syndrome presenting as facial diplegia after COVID-19 vaccination: a case report., *J. Emerg. Med.* 61 (2021) e141–e145, <https://doi.org/10.1016/j.jemermed.2021.07.062>.
- [132] J. Osowicki, H. Morgan, A. Harris, N.W. Crawford, J.P. Buttery, L. Kiers, Guillain-barré syndrome in an Australian state using both mRNA and adenovirus-vector SARS-CoV-2 vaccines, *Ann. Neurol.* 90 (2021) 856–858, <https://doi.org/10.1002/ana.26218>.
- [133] S. Azam, A. Khalil, A. Taha, Guillain-barré-syndrome in a 67-year-old male post COVID-19 vaccination (astra zeneca), *Am. J. Med. Case Rep.* 9 (2021) 424–427, <http://pubs.sciepub.com/>.
- [134] S.U. Patel, R. Khurram, A. Lakhani, B. Quirk, Guillain-Barre syndrome following the first dose of the chimpanzee adenovirus-vectored COVID-19 vaccine, *ChAdOx1*, *BMJ Case Rep.* 14 (2021), <https://doi.org/10.1136/bcr-2021-242956>.
- [135] J. Theuriat, C. Richard, J. Becker, A. Pegat, E. Bernard, S. Vukusic, Guillain-Barré syndrome following first injection of ChAdOx1 nCoV-19 vaccine: first report, *Rev. Neurol. (Paris)* 177 (2021) 1305–1307, <https://doi.org/10.1016/j.neuro.2021.04.005>.
- [136] B. V Maramattom, P. Krishnan, R. Paul, S. Padmanabhan, S. Cherukudal Vishnu Nampoothiri, A.A. Syed, H.S. Mangat, Guillain-barré syndrome following ChAdOx1-S/nCoV-19 vaccine, *Ann. Neurol.* 90 (2021) 312–314, <https://doi.org/10.1002/ana.26143>.
- [137] M. Trimboli, P. Zoleo, G. Arabia, A. Gambardella, Guillain-Barré syndrome following BNT162b2 COVID-19 vaccine, *Neurol. Sci. Off. J. Ital. Neurol. Soc. Ital. Soc. Clin. Neurophysiol* 42 (2021) 4401–4402, <https://doi.org/10.1007/s10072-021-05523-5>.
- [138] L. Ling, S.M. Bagshaw, P.-M. Villeneuve, Guillain-Barré syndrome after SARS-CoV-2 vaccination in a patient with previous vaccine-associated Guillain-Barré syndrome, *C. Can. Med. Assoc. J.* = *J. l'Association Médicale Can.* 193 (2021) E1766–E1769, <https://doi.org/10.1503/cmaj.210947>.
- [139] E. Malamud, J.B. Caress, D.J. Lapid, S.I. Otallah, "Guillain-Barré Syndrome After COVID-19 Vaccination in an Adolescent" [*Pediatric Neurology* 126 (2022) 77], <https://doi.org/10.1016/j.pediatrneuro.2021.11.001>. January 2022, Pages 9–10], *Pediatr. Neurol.* 128.
- [140] S.H. Bin Waqar, A.A. Khan, S. Memon, Thrombotic thrombocytopenic purpura: a new menace after COVID bnt162b2 vaccine, *Int. J. Hematol.* 114 (2021) 626–629, <https://doi.org/10.1007/s12185-021-03190-y>.
- [141] N. McKean, C. Chircop, Guillain-Barré syndrome after COVID-19 vaccination, *BMJ Case Rep.* 14 (2021), <https://doi.org/10.1136/bcr-2021-244125>.
- [142] G.F. da Silva, C.F. da Silva, R.E.N. da N. Oliveira, F. Romancini, R.M. Mendes, A. Locks, M.F.M. Longo, C.H.C. Moro, A.L. Longo, V.L. Braatz, Guillain-Barré syndrome after coronavirus disease 2019 vaccine: a temporal association., *Clin. Exp. Neuroimmunol* (2021), <https://doi.org/10.1111/cen3.12678>.
- [143] A. Introna, F. Caputo, C. Santoro, T. Guerra, M. Ucci, D.M. Mezzapesa, M. Trojano, Guillain-Barré syndrome after AstraZeneca COVID-19-vaccination: a causal or casual association?, *Clin. Neurol. Neurosurgery* 208 (2021) 106887, <https://doi.org/10.1016/j.clineuro.2021.106887>.
- [144] L. Negrea, B.H. Rovin, Gross hematuria following vaccination for severe acute respiratory syndrome coronavirus 2 in 2 patients with IgA nephropathy, *Kidney Int.* 99 (2021) 1487, <https://doi.org/10.1016/j.kint.2021.03.002>.
- [145] P. Perrin, X. Bassand, I. Benotmane, N. Bouvier, Gross hematuria following SARS-CoV-2 vaccination in patients with IgA nephropathy, *Kidney Int.* 100 (2021) 466–468, <https://doi.org/10.1016/j.kint.2021.05.022>.
- [146] W.K. Lo, K.W. Chan, Gross haematuria after mRNA COVID-19 vaccination in two patients with histological and clinical diagnosis of IgA nephropathy, *Nephrology* 27 (2022) 110–111, <https://doi.org/10.1111/nep.13992>.
- [147] M.A. Weintraub, B. Ameer, N. Sinha Gregory, Graves disease following the SARS-CoV-2 vaccine: case series, *J. Invest. Med. High Impact Case Reports* 9 (2021), <https://doi.org/10.1177/23247096211063356>, 23247096211063356.
- [148] C. Sriprapradang, P.C. Shantavasinkul, Graves' disease following SARS-CoV-2 vaccination, *Endocrine* 74 (2021) 473–474, <https://doi.org/10.1007/s12020-021-02902-y>.
- [149] T.J. Goblirsch, A.E. Paulson, G. Tashko, A.J. Mekonnen, Graves' disease following administration of second dose of SARS-CoV-2 vaccine, *BMJ Case Rep.* 14 (2021), <https://doi.org/10.1136/bcr-2021-246432>.
- [150] V. Gillion, M. Jadoul, N. Demoulin, S. Aydin, A. Devresse, Granulomatous vasculitis after the AstraZeneca anti-SARS-CoV-2 vaccine, *Kidney Int.* 100 (2021) 706–707, <https://doi.org/10.1016/j.kint.2021.06.033>.
- [151] H.P. Lee, V. Selvaratnam, J.S. Rajasuriar, Thrombotic thrombocytopenic purpura after ChAdOx1 nCoV-19 vaccine, *BMJ Case Rep.* 14 (2021), <https://doi.org/10.1136/bcr-2021-246049>.
- [152] S. Yamamoto, K. Nishimura, K. Yo, D. Waki, H. Murabe, T. Yokota, Flare-up of adult-onset Still's disease after receiving a second dose of BNT162b2 COVID-19 mRNA vaccine, *Clin. Exp. Rheumatol* 39 (Suppl 1) (2021) 139–140.
- [153] K.A. Terracina, F.K. Tan, Flare of rheumatoid arthritis after COVID-19 vaccination, *Lancet. Rheumatol* 3 (2021) e469–e470, [https://doi.org/10.1016/S2665-9913\(21\)00108-9](https://doi.org/10.1016/S2665-9913(21)00108-9).
- [154] J.-W. Kim, J.-Y. Jung, C.-H. Suh, H.-A. Kim, Flare of adult-onset Still's disease following mRNA COVID-19 vaccination: a case report and review of literature, *Clin. Rheumatol.* 41 (2022) 1583–1589, <https://doi.org/10.1007/s10067-022-06106-1>.
- [155] J.-G. Rademacher, B. Tampe, P. Korsten, First report of two cases of löfgren's syndrome after SARS-CoV-2 vaccination-coincidence or causality? *Vaccines* 9 (2021) <https://doi.org/10.3390/vaccines9111313>.

- [156] S. de Bruijn, M.-B. Maes, L. De Waele, K. Vanhoorelbeke, A. Gadisseur, First report of a de novo iTTP episode associated with an mRNA-based anti-COVID-19 vaccination, *J. Thromb. Haemostasis* 19 (2021) 2014–2018, <https://doi.org/10.1111/jth.15418>.
- [157] J. Havla, Y. Schultz, H. Zimmermann, R. Hohlfeld, A. Danek, T. Kümpfel, First manifestation of multiple sclerosis after immunization with the Pfizer-BioNTech COVID-19 vaccine, *J. Neurol.* 269 (2022) 55–58, <https://doi.org/10.1007/s00415-021-10648-w>.
- [158] B. Osmanodja, A. Schreiber, E. Schrezenmeier, E. Seelow, First diagnosis of thrombotic thrombocytopenic purpura after SARS-CoV-2 vaccine - case report, *BMC Nephrol.* 22 (2021) 411, <https://doi.org/10.1186/s12882-021-02616-3>.
- [159] M.H. Aly, A.A. Alshehri, A. Mohammed, A.M. Almalki, W.A. Ahmed, A. Almuflihi, A.A. Alwafi, First case of erythema nodosum associated with pfizer vaccine, *Cureus* 13 (2021), <https://doi.org/10.7759/cureus.19529> e19529.
- [160] S. Shimoyama, Y. Kanisawa, K. Ono, M. Souri, A. Ichinose, First and fatal case of autoimmune acquired factor XIII/13 deficiency after COVID-19/SARS-CoV-2 vaccination, *Am. J. Hematol.* 97 (2022) 243–245, <https://doi.org/10.1002/ajh.26426>.
- [161] E.V.C. Rodríguez, F.-Z. Bouazza, N. Dauby, F. Mullier, S. d'Otreppe, P. Jissendi Tchofo, M. Bartiaux, C. Sirjacques, A. Roman, C. Hermans, M. Cliquennois, Fatal vaccine-induced immune thrombotic thrombocytopenia (VITT) post Ad26.COVID.2. S: first documented case outside US, *Infection* 50 (2022) 531–536, <https://doi.org/10.1007/s15010-021-01712-8>.
- [162] A. Yocum, E.L. Simon, Thrombotic thrombocytopenic purpura after Ad26.COVID-2 vaccination., *Am. J. Emerg. Med.* 49 (2021) 441, <https://doi.org/10.1016/j.ajem.2021.05.001>, e3-441.e4.
- [163] M. Jamme, E. Mosnino, J. Hayon, G. Franchineau, Fatal cerebral venous sinus thrombosis after COVID-19 vaccination, *Intensive Care Med.* 47 (2021) 790–791, <https://doi.org/10.1007/s00134-021-06425-y>.
- [164] S. Toom, B. Wolf, A. Avula, S. Peeke, K. Becker, Familial thrombocytopenia flare-up following the first dose of mRNA-1273 Covid-19 vaccine, *Am. J. Hematol.* 96 (2021) E134–E135, <https://doi.org/10.1002/ajh.26128>.
- [165] D. Niebel, V. Ralsler-Isselstein, K. Jaschke, C. Braegelmann, T. Bieber, J. Wenzel, Exacerbation of subacute cutaneous lupus erythematosus following vaccination with BNT162b2 mRNA vaccine, *Dermatol. Ther.* 34 (2021), <https://doi.org/10.1111/dth.15017> e15017.
- [166] K. Mieczkowska, A. Kaubisch, B.N. McLellan, Exacerbation of psoriasis following COVID-19 vaccination in a patient previously treated with PD-1 inhibitor, *Dermatol. Ther.* 34 (2021), <https://doi.org/10.1111/dth.15055> e15055.
- [167] J. Finsterer, Exacerbating guillain-barré syndrome eight days after vector-based COVID-19 vaccination, *Case Rep. Infect. Dis* 2021 (2021) 3619131, <https://doi.org/10.1155/2021/3619131>.
- [168] G. Costanzo, A.G. Ledda, A. Ghisu, M. Vacca, D. Firinu, S. Del Giacco, Eosinophilic granulomatosis with polyangiitis relapse after COVID-19 vaccination: a case report., *Vaccines* 10 (2021), <https://doi.org/10.3390/vaccines10010013>.
- [169] C. Chan-Chung, C.S. Ong, L.L. Chan, E.K. Tan, Eosinophilic granulomatosis with polyangiitis after COVID-19 vaccination, *QJM* 114 (2022) 807–809, <https://doi.org/10.1093/qjmed/hcab273>.
- [170] G. Maraziti, C. Becattini, Eltrombopag for refractory vaccine-induced immune thrombotic thrombocytopenia, *J. Thromb. Thrombolysis* 53 (2022) 954–958, <https://doi.org/10.1007/s11239-021-02604-2>.
- [171] A. Cole, R. Thomas, N. Goldman, K. Howell, K. Chakravarty, C.P. Denton, V. H. Ong, Diffuse cutaneous systemic sclerosis following SARS-Co V-2 vaccination, *J. Autoimmun.* 128 (2022), <https://doi.org/10.1016/j.jaut.2022.102812>, 102812.
- [172] F. Solimani, Y. Mansour, D. Didona, A. Dilling, K. Ghoreschi, K. Meier, Development of severe pemphigus vulgaris following SARS-CoV-2 vaccination with BNT162b2, *J. Eur. Acad. Dermatol. Venereol.* 35 (2021) e649–e651, <https://doi.org/10.1111/jdv.17480>.
- [173] A. Jafri, A. Prieto, H. Gashau, J.D. Bartlett, Thrombotic thrombocytopenia following ChAdOx1 nCov-19 vaccination, *Acute Med.* 20 (2021) 223–226.
- [174] K. Sugita, S. Kaneko, R. Hisada, M. Harano, E. Anno, S. Hagiwara, E. Imai, M. Nagata, Y. Tsukamoto, Development of IgA vasculitis with severe glomerulonephritis after COVID-19 vaccination: a case report and literature review, *CEN Case Reports* (2022) 1–6, <https://doi.org/10.1007/s13730-022-00695-1>.
- [175] D.T.W. Lui, K.K. Lee, C.H. Lee, A.C.H. Lee, I.F.N. Hung, K.C.B. Tan, Development of graves' disease after SARS-CoV-2 mRNA vaccination: a case report and literature review., *front. Publ. Health* 9 (2021), 778964, <https://doi.org/10.3389/fpubh.2021.778964>.
- [176] A.Y.S. Lee, C. Lee, D.A. Brown, D. Suan, Development of anti-NXP2 dermatomyositis following Comirnaty COVID-19 vaccination, *Postgrad. Med. J.* (2022), 2022–141510, <https://doi.org/10.1136/postgradmedj-2022-141510> postgradmedj-.
- [177] A. Camargo Coronel, F.J. Jiménez Balderas, H. Quiñones Moya, M.R. Hernández Zavala, P. Mandinabeitia Rodríguez, J.R. Hernández Vázquez, S. Zamora Zarco, S. D.J. Aguilar Castillo, Dermatomyositis post vaccine against SARS-CoV-2, *BMC Rheumatol* 6 (2022) 20, <https://doi.org/10.1186/s41927-022-00250-6>.
- [178] K. Venkateswaran, D.C.-W. Aw, J. Huang, S. Angkodjojo, Dermatomyositis following COVID-19 vaccination, *Dermatol. Ther.* (2022), <https://doi.org/10.1111/dth.15479> e15479.
- [179] W. Gouda, A. Albasri, F. Alsaqabi, H.Y. Al Sabah, M. Alkandari, H. Abdelnaby, Dermatomyositis following BNT162b2 mRNA COVID-19 vaccination, *J. Kor. Med. Sci.* 37 (2022), <https://doi.org/10.3346/jkms.2022.37.e32> e32.
- [180] G. Carli, I. Nichele, M. Ruggeri, S. Barra, A. Tosetto, Deep vein thrombosis (DVT) occurring shortly after the second dose of mRNA SARS-CoV-2 vaccine, *Intern. Emerg. Med* 16 (2021) 803–804, <https://doi.org/10.1007/s11739-021-02685-0>.
- [181] A. Fillon, B. Sautenet, C. Barbet, L. Moret, E.M. Thillard, A.P. Jonville-Béra, J. M. Halimi, De novo and relapsing necrotizing vasculitis after COVID-19 vaccination, *Clin. Kidney J* 15 (2022) 560–563, <https://doi.org/10.1093/cjk/sfab285>.
- [182] M.A. Anderegg, M. Liu, C. Saganas, M. Montani, B. Vogt, U. Huynh-Do, D. G. Fuster, De novo vasculitis after mRNA-1273 (Moderna) vaccination, *Kidney Int.* 100 (2021) 474–476, <https://doi.org/10.1016/j.kint.2021.05.016>.
- [183] S. Marinaki, K. Kolovou, G. Liapis, C. Skalioti, S. Tsiakas, I. Boletis, De novo minimal change disease following vaccination with the pfizer/BioNTech SARS-CoV-2 vaccine in a living kidney donor, *Medicina* 58 (2021), <https://doi.org/10.3390/medicina58010037>.
- [184] K.-L. Muir, A. Kallam, S.A. Koepsell, K. Gundabolu, Thrombotic thrombocytopenia after Ad26.COVID.2.S vaccination., *N. Engl. J. Med.* 384 (2021) 1964–1965, <https://doi.org/10.1056/NEJM2105869>.
- [185] M.M.B. Mohamed, T.J. Wickman, A.B. Fogo, J.C.Q. Velez, De novo immunoglobulin A vasculitis following exposure to SARS-CoV-2 immunization, *Ochsner J.* 21 (2021) 395–401, <https://doi.org/10.31486/toj.21.0083>.
- [186] R. Ramessur, N. Saffar, B. Czako, A. Agarwal, K. Batta, Cutaneous thrombosis associated with skin necrosis following Oxford-AstraZeneca COVID-19 vaccination, *Clin. Exp. Dermatol.* 46 (2021) 1610–1612, <https://doi.org/10.1111/ced.14819>.
- [187] B.R. Kar, B.S. Singh, L. Mohapatra, I. Agrawal, Cutaneous small-vessel vasculitis following COVID-19 vaccine, *J. Cosmet. Dermatol.* 20 (2021) 3382–3383, <https://doi.org/10.1111/jocd.14452>.
- [188] M. Ungari, E. Pezzarossa, Cutaneous lymphocytic vasculitis after administration of the second dose of AZD1222 (Oxford-AstraZeneca) severe acute respiratory syndrome coronavirus 2 vaccination: causality or causality? *Am. J. Dermatopathol.* 44 (2022) 80–82, <https://doi.org/10.1097/DAD.0000000000002104>.
- [189] C. Vassallo, E. Boveri, V. Brazzelli, T. Rampino, R. Bruno, A. Bonometti, M. Gregorini, Cutaneous lymphocytic vasculitis after administration of COVID-19 mRNA vaccine, *Dermatol. Ther.* 34 (2021), <https://doi.org/10.1111/dth.15076> e15076.
- [190] D.J. Theodorou, S.J. Theodorou, A. Axiotis, M. Gianniki, N. Tsfetaki, COVID-19 vaccine-related myositis, *QJM* 114 (2021) 424–425, <https://doi.org/10.1093/qjmed/hcab043>.
- [191] S. Dash, B. Behera, M. Sethy, J. Mishra, S. Garg, COVID-19 vaccine-induced urticarial vasculitis, *Dermatol. Ther.* 34 (2021), <https://doi.org/10.1111/dth.15093> e15093.
- [192] M. Farooq, Y. Mohammed, M. Zafar, D. Dharmasena, U.I. Rana, O. Kankam, COVID-19 vaccine-induced pneumonitis, myositis and myopericarditis, *Cureus* 14 (2022), <https://doi.org/10.7759/cureus.20979> e20979.
- [193] S. Ramalingam, H. Arora, S. Lewis, K. Gunasekaran, M. Muruganandam, S. Nagaraju, P. Padmanabhan, COVID-19 vaccine-induced cellulitis and myositis, *Cleve. Clin. J. Med.* 88 (2021) 648–650, <https://doi.org/10.3949/ccjm.88a.21038>.
- [194] M. Wu, M. Karim, R. Ashinoff, COVID-19 vaccine-associated dermatomyositis, *JAAD Case Reports* 23 (2022) 58–60, <https://doi.org/10.1016/j.jidcr.2022.02.023>.
- [195] S. Sangli, A. Virani, N. Cheronis, B. Vannatter, C. Minich, S. Noronha, R. Bhagavatlal, D. Speredelozzi, M. Sauer, R.B. Kaplan, Thrombosis with thrombocytopenia after the messenger RNA-1273 vaccine, *Ann. Intern. Med.* 174 (2021) 1480–1482, <https://doi.org/10.7326/L21-0244>.
- [196] L. Camacho-Domínguez, Y. Rodríguez, F. Polo, J.C. Restrepo Gutierrez, E. Zapata, M. Rojas, J.-M. Anaya, COVID-19 vaccine and autoimmunity. A new case of autoimmune hepatitis and review of the literature., *J. Transl. Autoimmun* 5 (2022) 100140, <https://doi.org/10.1016/j.JTAUTO.2022.100140>.
- [197] H.S. Malhotra, P. Gupta, V. Prabhu, R. Kumar Garg, H. Dandu, V. Agarwal, COVID-19 vaccination-associated myelitis, *QJM* 114 (2021) 591–593, <https://doi.org/10.1093/qjmed/hcab069>.
- [198] K. Gupta, G.S. Sharma, A. Kumar, COVID-19 vaccination-associated anti-Jo-1 syndrome, *Reumatologia* 59 (2021) 420–422, <https://doi.org/10.5114/reum.2021.111836>.
- [199] M. Ramos-Casals, M. Sainz-de-la-Maza, A. Muxí, COVID-19 vaccination unveiling subclinical Sjögren's syndrome, *Clin. Exp. Rheumatol.* 39 (Suppl 1) (2021) 228–229.
- [200] S.R.A. Shah, S. Dolkar, J. Mathew, P. Vishnu, COVID-19 vaccination associated severe immune thrombocytopenia, *Exp. Hematol. Oncol.* 10 (2021) 42, <https://doi.org/10.1186/s40164-021-00235-0>.
- [201] I. Kaur, S. Zafar, E. Capitle, R. Khianey, COVID-19 vaccination as a potential trigger for new-onset systemic lupus erythematosus, *Cureus* 14 (2022), <https://doi.org/10.7759/cureus.21917> e21917.
- [202] N. Klomjit, M.P. Alexander, F.C. Fervenza, Z. Zoghby, A. Garg, M.C. Hogan, S. H. Nasr, M.A. Minshar, L. Zand, COVID-19 vaccination and glomerulonephritis., *kidney int, Report* 6 (2021) 2969–2978, <https://doi.org/10.1016/j.ekir.2021.09.008>.
- [203] B. Singh, P. Kaur, L. Cedeno, T. Brahimi, P. Patel, H. Virk, F. Shamoon, M. Bikina, COVID-19 mRNA vaccine and myocarditis., *eur. J. Case reports intern, Med* 8 (2021) 2681, https://doi.org/10.12890/2021_002681.
- [204] A. Badoiu, O. Moranne, S. Coudray, I.M. Ion, Clinical variant of guillain-barré syndrome with prominent facial diplegia after AstraZeneca coronavirus disease 2019 vaccine, *J. Clin. Neuromuscul. Dis.* 23 (2021) 115–116, <https://doi.org/10.1097/CND.0000000000000383>.

- [205] W. Deucher, S. Sukumar, S.R. Cataland, Clinical relapse of immune-mediated thrombotic thrombocytopenic purpura following COVID-19 vaccination., *Res. Pract. Thromb. Haemostasis* 6 (2022), <https://doi.org/10.1002/rth2.12658> e12658.
- [206] N.H. Schultz, I.H. Sørvoll, A.E. Michelsen, L.A. Munthe, F. Lund-Johansen, M. T. Ahlen, M. Wiedmann, A.-H. Aamodt, T.H. Skattør, G.E. Tjønnfjord, P.A. Holme, Thrombosis and thrombocytopenia after ChAdOx1 nCoV-19 vaccination., *N. Engl. J. Med.* 384 (2021) 2124–2130, <https://doi.org/10.1056/NEJMoa2104882>.
- [207] V. Larson, R. Seidenberg, A. Caplan, N.K. Brinster, S.A. Meehan, R.H. Kim, Clinical and histopathological spectrum of delayed adverse cutaneous reactions following COVID-19 vaccination., *J. Cutan. Pathol.* 49 (2022) 34–41, <https://doi.org/10.1111/cup.14104>.
- [208] C.F. Bagella, D.G. Corda, P. Zara, A.E. Elia, E. Ruiu, E. Sechi, P. Solla, Chronic inflammatory demyelinating polyneuropathy after ChAdOx1 nCoV-19 vaccination., *Vaccines* 9 (2021), <https://doi.org/10.3390/vaccines9121502>.
- [209] C. Lesort, J. Kaniakakis, L. Donzier, D. Jullien, Chills-like lesions after BNT162b2 mRNA COVID-19 vaccine: a case report suggesting that “COVID toes” are due to the immune reaction to SARS-CoV-2., *J. Eur. Acad. Dermatol. Venereol.* 35 (2021) e630–e632, <https://doi.org/10.1111/jdv.17451>.
- [210] P. Suresh, W. Petchey, ChAdOx1 nCoV-19 vaccine-induced immune thrombotic thrombocytopenia and cerebral venous sinus thrombosis (CVST), *BMJ Case Rep.* 14 (2021), <https://doi.org/10.1136/bcr-2021-243931>.
- [211] N. Uaprasert, K. Panrong, S. Tungjitviboonkun, K. Dussadee, P. Decharatanachart, P. Kaveevorayan, R. Shoosanglertwijit, P. Watanaboonyongcharoen, U. Bunworasate, P. Rojnuckarin, ChAdOx1 nCoV-19 vaccine-associated thrombocytopenia: three cases of immune thrombocytopenia after 107 720 doses of ChAdOx1 vaccination in Thailand., *Blood Coagul. Fibrinolysis an Int. J. Haemost. Thromb* 33 (2022) 67–70, <https://doi.org/10.1097/MBC.0000000000001082>.
- [212] Y.-H. Wang, L.-Y. Huang, Y.-L. Chen, J.-S. Chan, W.-F. Chiang, C.-Y. Lin, M.-H. Chen, H.-Y. Shyu, P.-J. Hsiao, ChAdOx1 COVID-19 vaccine-induced thrombocytopenia syndrome., *QJM* 114 (2021) 733–734, <https://doi.org/10.1093/qjmed/hcab221>.
- [213] L. Dias, R. Soares-Dos-Reis, J. Meira, D. Ferrão, P.R. Soares, A. Pastor, G. Gama, L. Fonseca, V. Fagundes, M. Carvalho, Cerebral venous thrombosis after BNT162b2 mRNA SARS-CoV-2 vaccine., *J. Stroke Cerebrovasc. Dis. Off. J. Natl. Stroke Assoc.* 30 (2021) 105906, <https://doi.org/10.1016/j.jstrokecerebrovasdis.2021.105906>.
- [214] S.N. Atta, N. Othman, M. Babar, Cerebral venous sinus thrombosis secondary to ChAdOx1 nCoV-19 vaccine., *BMJ Case Rep.* 14 (2021), <https://doi.org/10.1136/bcr-2021-246200>.
- [215] P.R. Mehta, S. Apap Mangion, M. Bengler, B.R. Stanton, J. Czuprynska, R. Arya, L. K. Sztrihá, Cerebral venous sinus thrombosis and thrombocytopenia after COVID-19 vaccination - a report of two UK cases., *Brain Behav. Immun.* 95 (2021) 514–517, <https://doi.org/10.1016/j.bbi.2021.04.006>.
- [216] S. Jinno, I. Naka, T. Nakazawa, Catastrophic antiphospholipid syndrome complicated with essential thrombocythaemia after COVID-19 vaccination: in search of the underlying mechanism., *Rheumatol. Adv. Pract* 5 (2021), <https://doi.org/10.1093/rap/rkab096>.
- [217] F. Bano, B. Badugama, D. Chandra, Thrombosis and thrombocytopenia after ChAdOx1 nCoV-19 vaccination: a single UK centre experience., *BMJ Case Rep.* 14 (2021), <https://doi.org/10.1136/bcr-2021-243894>.
- [218] A. Saleh, J. Collins, Case study of thrombosis and thrombocytopenia syndrome following administration of the AstraZeneca COVID-19 vaccine., *Aust. J. Gen. Pract* 50 (2021).
- [219] H. Eom, S.W. Kim, M. Kim, Y.E. Kim, J.H. Kim, H.Y. Shin, H.L. Lee, Case reports of acute transverse myelitis associated with mRNA vaccine for COVID-19., *J. Kor. Med. Sci.* 37 (2022), <https://doi.org/10.3346/jkms.2022.37.e52> e52.
- [220] A. Costello, A. Pandita, J. Devitt, Case report: thrombotic thrombocytopenia after COVID-19 janssen vaccination., *Am. Fam. Physician* 103 (2021) 646–647.
- [221] S. Hakroush, B. Tampe, Case report: ANCA-associated vasculitis presenting with rhabdomyolysis and pauci-immune crescentic glomerulonephritis after pfizer-BioNTech COVID-19 mRNA vaccination., *Front. Immunol.* 12 (2021) 762006, <https://doi.org/10.3389/fimmu.2021.762006>.
- [222] P.D. Tailor, A.M. Feighery, B. El-Sabawi, A. Prasad, Case report: acute myocarditis following the second dose of mRNA-1273 SARS-CoV-2 vaccine., *Eur. Hear. Journal, Case Reports* 5 (2021), <https://doi.org/10.1093/ehjcr/ytab319> ytab319.
- [223] A. Razok, A. Shams, A. Almeer, M. Zahid, Post-COVID-19 vaccine Guillain-Barré syndrome; first reported case from Qatar., *Ann. Med. Surg* 67 (2021) 102540, <https://doi.org/10.1016/j.amsu.2021.102540>.
- [224] T. Hasan, M. Khan, F. Khan, G. Hamza, Case of Guillain-Barré syndrome following COVID-19 vaccine., *BMJ Case Rep.* 14 (2021), <https://doi.org/10.1136/bcr-2021-243629>.
- [225] A. Sauret, J. Stievenart, P. Smets, L. Olagne, B. Guelon, O. Aumaitre, M. André, L. Trefond, Case of giant cell arteritis after SARS-CoV-2 vaccination: a particular phenotype?, *J. Rheumatol.* 49 (2022) 120, <https://doi.org/10.3899/jrheum.210724>.
- [226] K. Nakamura, M. Kosano, Y. Sakai, N. Saito, Y. Takazawa, T. Omodaka, Y. Kuniwa, R. Okuyama, Case of bullous pemphigoid following coronavirus disease 2019 vaccination., *J. Dermatol.* 48 (2021) e606–e607, <https://doi.org/10.1111/1346-8138.16170>.
- [227] M. Dell’Antonia, S. Anedda, F. Usai, L. Atzori, C. Ferrelì, Bullous pemphigoid triggered by COVID-19 vaccine: rapid resolution with corticosteroid therapy., *Dermatol. Ther.* 35 (2022), <https://doi.org/10.1111/dth.15208> e15208.
- [228] A. Mauriello, M. Scimeca, I. Amelio, R. Massoud, A. Novelli, F. Di Lorenzo, S. Finocchiaro, C. Cimino, R. Telesca, M. Chiochi, Q. Sun, Y. Wang, Y. Shi, G. Novelli, G. Melino, Thromboembolism after COVID-19 vaccine in patients with preexisting thrombocytopenia., *Cell Death Dis.* 12 (2021) 762, <https://doi.org/10.1038/s41419-021-04058-z>.
- [229] I. Pérez-López, D. Moyano-Bueno, R. Ruiz-Villaverde, Bullous pemphigoid and COVID-19 vaccine., *Med. Clin.* 157 (2021) e333–e334, <https://doi.org/10.1016/j.medcli.2021.05.005>.
- [230] V. Schmidt, R. Blum, M. Möhrenschrager, Biphasic bullous pemphigoid starting after first dose and boosted by second dose of mRNA-1273 vaccine in an 84-year-old female with polymorbidity and polypharmacy., *J. Eur. Acad. Dermatol. Venereol.* 36 (2022) e88–e90, <https://doi.org/10.1111/jdv.17722>.
- [231] A. Bayas, M. Menacher, M. Christ, L. Behrens, A. Rank, M. Naumann, Bilateral superior ophthalmic vein thrombosis, ischaemic stroke, and immune thrombocytopenia after ChAdOx1 nCoV-19 vaccination., *Lancet (London, England)* 397 (2021), [https://doi.org/10.1016/S0140-6736\(21\)00872-2](https://doi.org/10.1016/S0140-6736(21)00872-2) e11.
- [232] G.B. Bonifacio, D. Patel, S. Cook, E. Purcaru, M. Couzins, J. Domjan, S. Ryan, A. Alareed, O. Tuohy, S. Slaght, J. Furby, D. Allen, H.A. Katifi, L. Kinton, Bilateral facial weakness with paraesthesia variant of Guillain-Barré syndrome following Vaxzevria COVID-19 vaccine., *J. Neurol. Neurosurg. Psychiatry* 93 (2022) 341–342, <https://doi.org/10.1136/jnnp-2021-327027>.
- [233] E. Ryan, D. Benjamin, I. McDonald, A. Barrett, J. McHugh, K. Ryan, H. Enright, AZD1222 vaccine-related coagulopathy and thrombocytopenia without thrombosis in a young female., *Br. J. Haematol.* 194 (2021) 553–556, <https://doi.org/10.1111/bjh.17530>.
- [234] V. Dalwadi, D. Hancock, A.A. Ballout, A. Geraci, Axonal-Variant guillain-barre syndrome temporally associated with mRNA-based moderna SARS-CoV-2 vaccine., *Cureus* 13 (2021), <https://doi.org/10.7759/cureus.18291> e18291.
- [235] Y. Ishay, A. Kenig, T. Tsemach-Toren, R. Amer, L. Rubin, Y. Hershkovitz, F. Kharouf, Autoimmune phenomena following SARS-CoV-2 vaccination., *Int. Immunopharm.* 99 (2021) 107970, <https://doi.org/10.1016/j.intimp.2021.107970>.
- [236] E. Calabria, F. Canfora, M. Mascolo, S. Varricchio, M.D. Mignogna, D. Adamo, Autoimmune mucocutaneous blistering diseases after SARS-Cov-2 vaccination: a Case report of Pemphigus Vulgaris and a literature review., *Pathol. Res. Pract.* 232 (2022) 153834, <https://doi.org/10.1016/j.prp.2022.153834>.
- [237] É. Vuille-Lessard, M. Montani, J. Bosch, N. Semmo, Autoimmune hepatitis triggered by SARS-CoV-2 vaccination., *J. Autoimmun.* 123 (2021) 102710, <https://doi.org/10.1016/j.jaut.2021.102710>.
- [238] A. Rocco, C. Sgamato, D. Compare, G. Nardone, Autoimmune hepatitis following SARS-CoV-2 vaccine: may not be a casuality., *J. Hepatol.* 75 (2021) 728–729, <https://doi.org/10.1016/j.jhep.2021.05.038>.
- [239] P. Coto-Segura, M. Fernández-Prada, M. Mir-Bonafé, B. García-García, I. González-Iglesias, P. Alonso-Penanes, M. González-Guerrero, A. Gutiérrez-Palacios, E. Miranda-Martínez, F. Martín-Torres, Vesiculobullous skin reactions induced by COVID-19 mRNA vaccine: report of four cases and review of the literature., *Clin. Exp. Dermatol.* 47 (2022) 141–143, <https://doi.org/10.1111/ced.14835>.
- [240] R.A. Blauenfeldt, S.R. Kristensen, S.L. Ernstsén, C.C.H. Kristensen, C.Z. Simonsen, A.-M. Hvas, Thrombocytopenia with acute ischemic stroke and bleeding in a patient newly vaccinated with an adenoviral vector-based COVID-19 vaccine., *J. Thromb. Haemostasis* 19 (2021) 1771–1775, <https://doi.org/10.1111/jth.15347>.
- [241] C.K. Tan, Y.J. Wong, L.M. Wang, T.L. Ang, R. Kumar, Autoimmune hepatitis following COVID-19 vaccination: true causality or mere association?., *J. Hepatol.* 75 (2021) 1250–1252, <https://doi.org/10.1016/j.jhep.2021.06.009>.
- [242] M. Rela, D. Jothimani, M. Vij, A. Rajakumar, A. Rammohan, Auto-immune hepatitis following COVID vaccination., *J. Autoimmun.* 123 (2021) 102688, <https://doi.org/10.1016/j.jaut.2021.102688>.
- [243] D. Clayton-Chubb, D. Schneider, E. Freeman, W. Kemp, S.K. Roberts, Autoimmune hepatitis developing after the ChAdOx1 nCoV-19 (Oxford-AstraZeneca) vaccine., *J. Hepatol.* 75 (2021) 1249–1250, <https://doi.org/10.1016/j.jhep.2021.06.014>.
- [244] F. Bril, S. Al Diffalha, M. Dean, D.M. Fettig, Autoimmune hepatitis developing after coronavirus disease 2019 (COVID-19) vaccine: causality or casuality?., *J. Hepatol.* 75 (2021) 222–224, <https://doi.org/10.1016/j.jhep.2021.04.003>.
- [245] E. Avci, F. Abasiyanik, Autoimmune hepatitis after SARS-CoV-2 vaccine: new-onset or flare-up?., *J. Autoimmun.* 125 (2021) 102745, <https://doi.org/10.1016/j.jaut.2021.102745>.
- [246] I. Garrido, S. Lopes, M.S. Simões, R. Liberal, J. Lopes, F. Carneiro, G. Macedo, Autoimmune hepatitis after COVID-19 vaccine - more than a coincidence., *J. Autoimmun.* 125 (2021) 102741, <https://doi.org/10.1016/j.jaut.2021.102741>.
- [247] A.J. Portuguese, C. Sunga, R. Kruse-Jarres, T. Gernsheimer, J. Abkowitz, Autoimmune- and complement-mediated hematologic condition recrudescence following SARS-CoV-2 vaccination., *Blood Adv* 5 (2021) 2794–2798, <https://doi.org/10.1182/bloodadvances.2021004957>.
- [248] A.L. Peralta-Amaro, M.I. Tejada-Ruiz, K.L. Rivera-Alvarado, O. de J. Cobos-Quevedo, P. Romero-Hernández, W. Macías-Arroyo, A. Avendaño-Ponce, J. Hurtado-Díaz, O. Vera-Lastra, A. Lucas-Hernández, Atypical kawasaki disease after COVID-19 vaccination: a new form of adverse event following immunization., *Vaccines* 10 (2022), <https://doi.org/10.3390/vaccines10010126>.
- [249] V. Kharkar, T. Vishwanath, S. Mahajan, R. Joshi, P. Gole, Asymmetrical cutaneous vasculitis following COVID-19 vaccination with unusual eosinophil preponderance., *Clin. Exp. Dermatol.* 46 (2021) 1596–1597, <https://doi.org/10.1111/ced.14797>.

- [250] W.M. Oo, P. Giri, A. de Souza, AstraZeneca COVID-19 vaccine and Guillain-barré syndrome in tasmania: a causal link?, *J. Neuroimmunol.* 360 (2021) 577719, <https://doi.org/10.1016/j.jneuroim.2021.577719>.
- [251] K.J. Welsh, J. Baumbatt, W. Chege, R. Goud, N. Nair, Thrombocytopenia including immune thrombocytopenia after receipt of mRNA COVID-19 vaccines reported to the Vaccine Adverse Event Reporting System (VAERS), *Vaccine* 39 (2021) 3329–3332, <https://doi.org/10.1016/j.vaccine.2021.04.054>.
- [252] C. Baimukhamedov, Arthritis of the left elbow joint after vaccination against SARS-CoV-2 infection, *Int. J. Rheum. Dis* 24 (2021) 1218–1220, <https://doi.org/10.1111/1756-185X.14202>.
- [253] A. Unal Enginar, Arthritis following COVID-19 vaccination: report of two cases, *Int. Immunopharm.* 101 (2021) 108256, <https://doi.org/10.1016/j.intimp.2021.108256>.
- [254] A. Dutta, R. Ghosh, D. Bhattacharya, S. Bhat, A. Ray, A. Pandit, S. Das, S. Dubey, Anti-Pf4 antibody negative cerebral venous sinus thrombosis without thrombocytopenia following immunization with COVID-19 vaccine in an elderly non-comorbid Indian male, managed with conventional heparin-warfarin based anticoagulation., *Diabetes Metab. Syndr* 15 (2021) 102184, <https://doi.org/10.1016/j.dsx.2021.06.021>.
- [255] G.K. Dube, L.J. Benvenuto, I. Batal, Antineutrophil cytoplasmic autoantibody-associated glomerulonephritis following the pfizer-BioNTech COVID-19 vaccine., *kidney int, Report* 6 (2021) 3087–3089, <https://doi.org/10.1016/j.kid.2021.08.012>.
- [256] A. Sacker, V. Kung, N. Andeen, Anti-GBM nephritis with mesangial IgA deposits after SARS-CoV-2 mRNA vaccination, *Kidney Int.* 100 (2021) 471–472, <https://doi.org/10.1016/j.kint.2021.06.006>.
- [257] G. Renisi, A. Lombardi, M. Stanzione, A. Invernizzi, A. Bandera, A. Gori, Anterior uveitis onset after bnt162b2 vaccination: is this just a coincidence? *Int. J. Infect. Dis. IJID Off. Publ. Int. Soc. Infect. Dis* 110 (2021) 95–97, <https://doi.org/10.1016/j.ijid.2021.07.035>.
- [258] M.-C. Londoño, J. Gratacós-Ginès, J. Sáez-Penataro, Another case of autoimmune hepatitis after SARS-CoV-2 vaccination - still casualty? *J. Hepatol.* 75 (2021) 1248–1249, <https://doi.org/10.1016/j.jhep.2021.06.004>.
- [259] M.T. Shakoor, M.P. Birkenbach, M. Lynch, ANCA-associated vasculitis following pfizer-BioNTech COVID-19 vaccine., *Am. J. Kidney Dis. Off. J. Natl. Kidney Found* 78 (2021) 611–613, <https://doi.org/10.1053/j.ajkd.2021.06.016>.
- [260] A. Sekar, R. Campbell, J. Tabbara, P. Rastogi, ANCA glomerulonephritis after the Moderna COVID-19 vaccination, *Kidney Int.* 100 (2021) 473–474, <https://doi.org/10.1016/j.kint.2021.05.017>.
- [261] C. Bhan, N. Bheesham, F. Shakuntulla, M. Sharma, C. Sun, M. Weinstein, An unusual presentation of acute deep vein thrombosis after the Moderna COVID-19 vaccine-a case report, *Ann. Transl. Med.* 9 (2021) 1605, <https://doi.org/10.21037/atm-21-2772>.
- [262] E.-J. Lee, D.B. Cines, T. Gernsheimer, C. Kessler, M. Michel, M.D. Tarantino, J. W. Semple, D.M. Arnold, B. Godeau, M.P. Lambert, J.B. Bussel, Thrombocytopenia following pfizer and moderna SARS-CoV-2 vaccination, *Am. J. Hematol.* 96 (2021) 534–537, <https://doi.org/10.1002/ajh.26132>.
- [263] W. Jin, Y. Tang, C. Wen, An ocular adverse event in temporal association with COVID-19 vaccination in a patient with systemic lupus erythematosus: a case report, *Hum. Vaccines Immunother.* 17 (2021) 4102–4104, <https://doi.org/10.1080/21645515.2021.1976036>.
- [264] M. Okada, E. Kikuchi, M. Nagasawa, A. Oshiba, M. Shimoda, An adolescent girl diagnosed with IgA nephropathy following the first dose of the COVID-19 vaccine, *CEN Case Reports* (2022) 1–4, <https://doi.org/10.1007/s13730-021-00679-7>.
- [265] R.J. Maas, S. Gianotten, W.A.G. van der Meijden, An additional case of minimal change disease following the pfizer-BioNTech COVID-19 vaccine., *Am. J. Kidney Dis. Off. J. Natl. Kidney Found* 78 (2021) 312, <https://doi.org/10.1053/j.ajkd.2021.05.003>.
- [266] C. Sriprapradang, Aggravation of hyperthyroidism after heterologous prime-boost immunization with inactivated and adenovirus-vectored SARS-CoV-2 vaccine in a patient with Graves' disease, *Endocrine* 74 (2021) 226–227, <https://doi.org/10.1007/s12020-021-02879-8>.
- [267] A. Sharabi, S. Shiber, Y. Molad, Adult-onset Still's disease following mRNA COVID-19 vaccination, *Clin. Immunol.* 233 (2021) 108878, <https://doi.org/10.1016/j.clim.2021.108878>.
- [268] S.Y. Park, K.-H. Lee, Adult-onset Still's disease after BNT162b2 mRNA COVID-19 vaccine, *J. Kor. Med. Sci.* 36 (2021), <https://doi.org/10.3346/jkms.2021.36.e344>.
- [269] F. Leone, P.G. Cerasuolo, S.L. Bosello, L. Verardi, E. Fiori, F. Coccillillo, B. Merlino, A. Zoli, M.A. D'Agostino, Adult-onset Still's disease following COVID-19 vaccination, *Lancet. Rheumatol* 3 (2021) e678–e680, [https://doi.org/10.1016/S2665-9913\(21\)00218-6](https://doi.org/10.1016/S2665-9913(21)00218-6).
- [270] A. Sweeney, G. Tracey, K. Garnham, Adult-onset Still disease post-adenovirus vector COVID-19 vaccine, *Intern. Med. J.* 51 (2021) 2144–2145, <https://doi.org/10.1111/imj.15563>.
- [271] V. Biradar, A. Konnur, S. Gang, U. Hegde, M. Rajapurkar, H. Patel, S.N. Pandey, S. Soni, Adult-onset nephrotic syndrome following coronavirus disease vaccination, *Clin. Kidney J* 15 (2022) 168–170, <https://doi.org/10.1093/ckj/sfab153>.
- [272] V. Suri, S. Pandey, J. Singh, A. Jena, Acute-onset chronic inflammatory demyelinating polyneuropathy after COVID-19 infection and subsequent ChAdOx1 nCoV-19 vaccination, *BMJ Case Rep.* 14 (2021), <https://doi.org/10.1136/bcr-2021-245816>.
- [273] M.E. Wolf, B. Luz, L. Niehaus, P. Bhogal, H. Bänzner, H. Henkes, Thrombocytopenia, Intracranial Venous, Sinus thrombosis after "COVID-19 vaccine AstraZeneca" exposure, *J. Clin. Med.* 10 (2021), <https://doi.org/10.3390/jcm10081599>.
- [274] J.-J. Gao, H.-P. Tseng, C.-L. Lin, J.-S. Shiu, M.-H. Lee, C.-H. Liu, Acute transverse myelitis following COVID-19 vaccination, *Vaccines* 9 (2021), <https://doi.org/10.3390/vaccines9091008>.
- [275] Y.-T. Hsiao, M.-J. Tsai, Y.-H. Chen, C.-F. Hsu, Acute transverse myelitis after COVID-19 vaccination, *Medicina* 57 (2021), <https://doi.org/10.3390/medicina57101010>.
- [276] L. Flower, Z. Bares, G. Santiapillai, S. Harris, Acute ST-segment elevation myocardial infarction secondary to vaccine-induced immune thrombosis with thrombocytopenia (VITT), *BMJ Case Rep.* 14 (2021), <https://doi.org/10.1136/bcr-2021-245218>.
- [277] O. Parkash, A. Sharko, A. Farooqi, G.W. Ying, P. Sura, Acute pancreatitis: a possible side effect of COVID-19 vaccine., *Cureus* 13 (2021), <https://doi.org/10.7759/cureus.14741>.
- [278] A. Simone, J. Herald, A. Chen, N. Gulati, A.Y.-J. Shen, B. Lewin, M.-S. Lee, Acute myocarditis following COVID-19 mRNA vaccination in adults aged 18 Years or older., *JAMA intern, Med* 181 (2021) 1668–1670, <https://doi.org/10.1001/jamainternmed.2021.5511>.
- [279] M.B. Habib, T. Hamamlyh, A. Elyas, M. Altermanini, M. Elhassan, Acute myocarditis following administration of BNT162b2 vaccine, *IDCases* 25 (2021), <https://doi.org/10.1016/j.idcr.2021.e01197>.
- [280] A. Nevet, Acute myocarditis associated with anti-COVID-19 vaccination, *Clin. Exp. Vaccine Res.* 10 (2021) 196–197, <https://doi.org/10.7774/cevr.2021.10.2.196>.
- [281] A. Cereda, C. Conca, L. Barbieri, G. Ferrante, G. Tumminello, S. Lucreziotti, M. Guazzi, A. Mafri, Acute myocarditis after the second dose of SARS-CoV-2 vaccine: serendipity or atypical causal relationship? *Anatol. J. Cardiol.* 25 (2021) 522–523, <https://doi.org/10.5152/AnatolJCardiol>, 2021.99.
- [282] P. Schmitt, R. Demoulin, R. Poyet, E. Capilla, G. Rohel, F. Pons, C. Jégo, S. Sidibe, A. Druelle, F.-X. Brocq, F. Dutasta, G.R. Cellarier, Acute Myocarditis after COVID-19 vaccination: a case report., *Rev. Med. Interne* 42 (2021) 797–800, <https://doi.org/10.1016/j.revmed.2021.10.003>.
- [283] T.D. Nguyen, G. Mall, J.G. Westphal, O. Weingärtner, S. Möbius-Winkler, P. C. Schulze, Acute myocarditis after COVID-19 vaccination with mRNA-1273 in a patient with former SARS-CoV-2 infection, *ESC Hear. Fail.* 8 (2021) 4710–4714, <https://doi.org/10.1002/ehf2.13613>.
- [284] L. Juay, N.S. Chandran, Three cases of vesiculobullous non-IgE-mediated cutaneous reactions to tozinameran (Pfizer-BioNTech COVID-19 vaccine), *J. Eur. Acad. Dermatol. Venereol.* 35 (2021) e855–e857, <https://doi.org/10.1111/jdv.17581>.
- [285] J. Bautista García, P. Peña Ortega, J.A. Bonilla Fernández, A. Cárdenes León, L. Ramírez Burgos, E. Caballero Dorta, Acute myocarditis after administration of the BNT162b2 vaccine against COVID-19, *Rev. Esp. Cardiol.* 74 (2021) 812–814, <https://doi.org/10.1016/j.rec.2021.04.005>.
- [286] J. Mansour, R.G. Short, S. Bhalla, P.K. Woodard, A. Verma, X. Robinson, D. A. Raptis, Acute myocarditis after a second dose of the mRNA COVID-19 vaccine: a report of two cases, *Clin. Imag.* 78 (2021) 247–249, <https://doi.org/10.1016/j.clinimag.2021.06.019>.
- [287] E. Vegezzi, S. Ravaglia, G. Buongarzone, P. Bini, L. Diamanti, M. Gastaldi, P. Prunetti, E. Rognone, E. Marchioni, Acute myelitis and ChAdOx1 nCoV-19 vaccine: casual or causal association? *J. Neuroimmunol.* 359 (2021) 577686, <https://doi.org/10.1016/j.jneuroim.2021.577686>.
- [288] R. Plasse, R. Nee, S. Gao, S. Olson, Acute kidney injury with gross hematuria and IgA nephropathy after COVID-19 vaccination, *Kidney Int.* 100 (2021) 944–945, <https://doi.org/10.1016/j.kint.2021.07.020>.
- [289] G. Costentin, O. Ozkul-Wermester, A. Triquenot, V. Le Cam-Duchez, N. Massy, Y. Benhamou, E. Massardier, Acute ischemic stroke revealing ChAdOx1 nCoV-19 vaccine-induced immune thrombotic thrombocytopenia: impact on recanalization strategy, *J. Stroke Cerebrovasc. Dis. Off. J. Natl. Stroke Assoc.* 30 (2021) 105942, <https://doi.org/10.1016/j.jstrokecerebrovasdis.2021.105942>.
- [290] M. Jawed, A. Khalid, M. Rubin, R. Shafiq, N. Cemalovic, Acute immune thrombocytopenia (ITP) following COVID-19 vaccination in a patient with previously stable ITP., *open forum infect, Dis* 8 (2021), <https://doi.org/10.1093/ofid/ofab343>.
- [291] G. Ozgen Kenangil, B.C. Ari, C. Guler, M.K. Demir, Acute disseminated encephalomyelitis-like presentation after an inactivated coronavirus vaccine., *Acta Neurol, Belgel* 121 (2021) 1089–1091, <https://doi.org/10.1007/s13760-021-01699-x>.
- [292] A. Vogrig, F. Janes, G.L. Gigli, F. Curcio, I. Del Negro, S. D'Agostini, M. Fabris, M. Valente, Acute disseminated encephalomyelitis after SARS-CoV-2 vaccination, *Clin. Neurol. Neurosurg.* 208 (2021) 106839, <https://doi.org/10.1016/j.clineuro.2021.106839>.
- [293] M. Ghilmetti, H.D. Schaufelberger, G. Mieli-Vergani, A. Cerny, E. Dayer, D. Vergani, B. Terziroli Beretta-Piccoli, Acute autoimmune-like hepatitis with atypical anti-mitochondrial antibody after mRNA COVID-19 vaccination: a novel clinical entity?, *J. Autoimmun.* 123 (2021) 102706, <https://doi.org/10.1016/j.jaut.2021.102706>.
- [294] H. Maayan, I. Kirgner, O. Gutwein, K. Herzog-Tzarfati, N. Rahimi-Levene, M. Koren-Michowitz, D. Blickstein, Acquired thrombotic thrombocytopenic purpura: a rare disease associated with BNT162b2 vaccine., *J. Thromb. Haemostasis* 19 (2021) 2314–2317, <https://doi.org/10.1111/jth.15420>.
- [295] B.G. İremli, S.N. Şendur, U. Ünlütürk, Three cases of subacute thyroiditis following SARS-CoV-2 vaccine: postvaccination ASIA syndrome, *J. Clin. Endocrinol. Metab.* 106 (2021) 2600–2605, <https://doi.org/10.1210/clinem/dgab373>.

- [296] M. Al-Ahmad, M. Al-Rasheed, N.A.B. Shalaby, Acquired thrombotic thrombocytopenic purpura with possible association with AstraZeneca-Oxford COVID-19 vaccine, *EJH* (2021), <https://doi.org/10.1002/jha.2.219>.
- [297] Y. Fujita, K. Yoshida, D. Ichikawa, Y. Shibagaki, M. Yazawa, Abrupt worsening of occult IgA nephropathy after the first dose of SARS-CoV-2 vaccination, *CEN Case Reports* (2022) 1–7, <https://doi.org/10.1007/s13730-021-00670-2>.
- [298] A.R. Tagliaferri, G. Horani, K. Stephens, P. Michael, A rare presentation of undiagnosed multiple sclerosis after the COVID-19 vaccine., *J. Community Hosp. Intern. Med. Perspecta* 11 (2021) 772–775, <https://doi.org/10.1080/20009666.2021.1979745>.
- [299] R. Kotal, I. Jacob, P. Rangappa, K. Rao, G. Hosurkar, S.K. Anumula, A. M. Kuberappa, A rare case of vaccine-induced immune thrombosis and thrombocytopenia and approach to management., *Surg. Neurol. Bar Int.* 12 (2021) 408, <https://doi.org/10.25259/SNI.689.2021>.
- [300] A. Naitlho, W. Lahlou, A. Bourial, H. Rais, N. Ismaili, I. Abousahfa, L. Belyamani, A rare case of henoch-schönlein purpura following a COVID-19 vaccine-case report, *SN Compr. Clin. Med.* (2021) 1–4, <https://doi.org/10.1007/s42399-021-01025-9>.
- [301] Y. Kripalani, V. Lakkappan, L. Parulekar, A. Shaikh, R. Singh, P. Vyas, A rare case of guillain-barré syndrome following COVID-19 vaccination., *eur. J. Case reports intern. Med* 8 (2021) 2707, https://doi.org/10.12890/2021_002797.
- [302] V. D'Agostino, F. Caranci, A. Negro, V. Piscitelli, B. Tuccillo, F. Fasano, G. Sirabella, I. Marano, V. Granata, R. Grassi, D. Pupo, R. Grassi, A rare case of cerebral venous thrombosis and disseminated intravascular coagulation temporally associated to the COVID-19 vaccine administration., *J. Personalized Med.* 11 (2021), <https://doi.org/10.3390/jpm11040285>.
- [303] A. Abobaker, M.A. Idris, O. Ogunjimi, A localised vasculitic-like skin rash following the second dose of COVID-19 vaccine., *Int. J. Infect. Dis. IJID Off. Publ. Int. Soc. Infect. Dis* 114 (2022) 29–30, <https://doi.org/10.1016/j.ijid.2021.11.001>.
- [304] Y.H. Jeon, D.-H. Lim, S.W. Choi, S.J. Choi, A flare of Still's disease following COVID-19 vaccination in a 34-year-old patient., *Rheumatol. Bar Int.* 42 (2022) 743–748, <https://doi.org/10.1007/s00296-021-05052-6>.
- [305] O. Shazley, M. Alshazley, A COVID-positive 52-year-old man presented with venous thromboembolism and disseminated intravascular coagulation following johnson & johnson vaccination: a case-study., *Cureus* 13 (2021), <https://doi.org/10.7759/cureus.16383> e16383.
- [306] J. Hocking, S.D. Chunilal, V.M. Chen, T. Brighton, J. Nguyen, J. Tan, S.B. Ting, H. Tran, The first known case of vaccine-induced thrombotic thrombocytopenia in Australia., *Med. J. Aust* 215 (2021) 19–20, <https://doi.org/10.5694/mja.2.51135>, e1.
- [307] Y.-B. Son, T.-B. Kim, H.-J. Min, J. Lee, J. Yang, M.-G. Kim, S.K. Jo, W.Y. Cho, S. W. Oh, A case report of thrombotic thrombocytopenia after ChAdOx1 nCoV-19 vaccination and heparin use during hemodialysis., *J. Korean Med. Sci.* 37 (2022), <https://doi.org/10.3346/jkms.2022.37.e75>.
- [308] W. Hamouche, Y. El Soufi, S. Alzarq, B.V. Okafor, F. Zhang, C. Paras, A case report of new onset graves' disease induced by SARS-CoV-2 infection or vaccine?., *J. Clin. Transl. Endocrinol. Case Reports* 23 (2022) 100104, <https://doi.org/10.1016/j.jecr.2021.100104>.
- [309] G. Kim, E.-J. Choi, H.-S. Park, J.-H. Lee, J.-H. Lee, K.-H. Lee, A case report of immune thrombocytopenia after ChAdOx1 nCoV-19 vaccination, *J. Kor. Med. Sci.* 36 (2021), <https://doi.org/10.3346/jkms.2021.36.e306> e306.
- [310] B. Bailly-Caillé, F. Jouen, A. DompMartin, C. Morice, A case report of anti-P200 pemphigoid following COVID-19 vaccination., *JAAD Case Reports* 23 (2022) 83–86, <https://doi.org/10.1016/j.jidcr.2022.03.011>.
- [311] D. Kim, J.H. Choi, J.Y. Jang, O. So, E. Cho, H. Choi, K.S. Hong, K.T. Park, A case report for myopericarditis after BNT162b2 COVID-19 mRNA vaccination in a Korean young male, *J. Kor. Med. Sci.* 36 (2021), <https://doi.org/10.3346/jkms.2021.36.e277>.
- [312] A.L. Tøllbøll Sørensen, M. Rolland, J. Hartmann, Z.B. Harboe, C. Roed, T. Ø. Jensen, L. Kolte, D. El Fassi, J. Hillingsø, A. Radziwon-Balicka, R.S. Soyka, K. Hansen, N. Kirkby, J.P. Goetze, M. Gybel-Brask, E.B. Leinøe, A.-M. Hvas, P. Kampmann, J. Stensballe, A case of thrombocytopenia and multiple thromboses after vaccination with ChAdOx1 nCoV-19 against SARS-CoV-2., *Blood Adv* 5 (2021) 2569–2574, <https://doi.org/10.1182/bloodadvances.2021004904>.
- [313] N. Miyae, A. Yoshida, Y. Yamanishi, S. Tada, R. Ando, Y. Hosokawa, H. Yabe, M. Nagai, Refractory longitudinally extensive transverse myelitis after severe acute respiratory syndrome coronavirus 2 vaccination in a Japanese man, *Intern. Med.* 61 (2022) 739–742, <https://doi.org/10.2169/internalmedicine.8747-21>.
- [314] Y.-P. Hung, K.-S. Sun, A case of myopericarditis with pleuritis following AstraZeneca Covid-19 vaccination., *QJM* 114 (2022) 879–881, <https://doi.org/10.1093/qjmed/hcab278>.
- [315] Y. Da, G.H. Goh, P. Khatri, A case of membranous nephropathy following Pfizer-BioNTech mRNA vaccination against COVID-19., *Kidney Int.* 100 (2021) 938–939, <https://doi.org/10.1016/j.kint.2021.07.016>.
- [316] C. Pagenkopf, M. Südmeyer, A case of longitudinally extensive transverse myelitis following vaccination against Covid-19., *J. Neuroimmunol.* 358 (2021) 577606, <https://doi.org/10.1016/j.jneuroim.2021.577606>.
- [317] S.-C. Su, R.-K. Lyu, C.-W. Chang, W.-E.J. Tseng, The first guillain-barré? Syndrome after SARS-CoV-2 vaccination in taiwan., *acta neurol. Taiwan* 31 (1) (2022) 46–51.
- [318] E.R. King, E. Towner, A case of immune thrombocytopenia after BNT162b2 mRNA COVID-19 vaccination, *Am. J. Case Rep* 22 (2021), <https://doi.org/10.12659/AJCR.931478> e931478.
- [319] S. V. Malayala, B.N. Papudesi, R. Sharma, U.T. Vusqa, A. Raza, A case of idiopathic thrombocytopenic purpura after booster dose of BNT162b2 (Pfizer-Biontech) COVID-19 vaccine., *Cureus* 13 (2021), <https://doi.org/10.7759/cureus.18985> e18985.
- [320] S.J. Rao, S. Khurana, G. Murthy, E.T. Dawson, N. Jazebi, C.J. Haas, A case of Guillain-Barre syndrome following Pfizer COVID-19 vaccine., *J. Community Hosp. Intern. Med. Perspecta* 11 (2021) 597–600, <https://doi.org/10.1080/20009666.2021.1954284>.
- [321] S.E.G. Rahim, J.T. Lin, J.C. Wang, A case of gross hematuria and IgA nephropathy flare-up following SARS-CoV-2 vaccination., *Kidney Int.* 100 (2021) 238, <https://doi.org/10.1016/j.kint.2021.04.024>.
- [322] A. Patrizio, S.M. Ferrari, A. Antonelli, P. Fallahi, A case of Graves' disease and type 1 diabetes mellitus following SARS-CoV-2 vaccination., *J. Autoimmun.* 125 (2021) 102738, <https://doi.org/10.1016/j.jaut.2021.102738>.
- [323] K. Yamamoto, T. Mashiba, K. Takano, T. Suzuki, M. Kami, M. Takita, E. Kusumi, Y. Mizuno, T. Hamaki, A case of exacerbation of subclinical hyperthyroidism after first administration of BNT162b2 mRNA COVID-19 vaccine., *Vaccines* 9 (2021), <https://doi.org/10.3390/vaccines9101108>.
- [324] S. Elamin, F. Hinds, J. Tolland, De novo generalized pustular psoriasis following Oxford-AstraZeneca COVID-19 vaccine, *Clin. Exp. Dermatol.* 47 (2022) 153–155, <https://doi.org/10.1111/ced.14895>.
- [325] A. Chittal, S. Rao, P. Lakra, N. Nacu, C. Haas, A case of COVID-19 vaccine-induced thrombotic thrombocytopenia., *J. Community Hosp. Intern. Med. Perspecta* 11 (2021) 776–778, <https://doi.org/10.1080/20009666.2021.1980966>.
- [326] A.R. Tagliaferri, S. Narvani, M.H. Azzam, W. Grist, A case of COVID-19 vaccine causing a myasthenia Gravis crisis, *Cureus* (2021), <https://doi.org/10.7759/cureus.15581>.
- [327] A. Chavez, C. Pougner, A case of COVID-19 vaccine associated new diagnosis myasthenia Gravis., *J. Prim. Care Community Health* 12 (2021), <https://doi.org/10.1177/21501327211051933>, 21501327211051932.
- [328] E. Ammirati, C. Cavalotti, A. Milazzo, P. Pedrotti, F. Soriano, J.W. Schroeder, N. Morici, C. Giannattasio, M. Frigerio, M. Metra, P.G. Camici, F. Oliva, Temporal relation between second dose BNT162b2 mRNA Covid-19 vaccine and cardiac involvement in a patient with previous SARS-COV-2 infection, *Int. J. Cardiol. Hear. Vasc* 34 (2021) 100774, <https://doi.org/10.1016/j.ijcha.2021.100774>.
- [329] J. Young, L. Mercieca, M. Ceci, D. Pisani, A. Betts, M.J. Boffa, A case of bullous pemphigoid after the SARS-CoV-2 mRNA vaccine., *J. Eur. Acad. Dermatol. Venereol.* 36 (2022) e13–e16, <https://doi.org/10.1111/jdv.17676>.
- [330] M. Villa, F. Díaz-Crespo, A. Pérez de José, Ú. Verdalles, E. Verde, F. Almeida Ruiz, A. Acosta, A. Mijaylova, M. Goicoechea, A case of ANCA-associated vasculitis after AZD1222 (Oxford-AstraZeneca) SARS-CoV-2 vaccination: casualty or causality?., *Kidney Int.* 100 (2021) 937–938, <https://doi.org/10.1016/j.kint.2021.07.026>.
- [331] N.E. Wiest, G.S. Johns, E. Edwards, A case of acute pulmonary embolus after mRNA SARS-CoV-2 immunization., *Vaccines* 9 (2021), <https://doi.org/10.3390/vaccines9080903>.
- [332] T. Walter, S. Connor, C. Stedman, M. Doogue, A case of acute necrotising pancreatitis following the second dose of Pfizer-BioNTech COVID-19 mRNA vaccine., *Br. J. Clin. Pharmacol.* 88 (2022) 1385–1386, <https://doi.org/10.1111/bcp.15039>.
- [333] F.S. Mira, J. Costa Carvalho, P.A. de Almeida, A.C. Pimenta, I. Alen Coutinho, C. Figueiredo, L. Rodrigues, V. Sousa, E. Ferreira, H. Pinto, L. Escada, A. Galvão, R. Alves, A case of acute interstitial nephritis after two doses of the BNT162b2 SARS-CoV-2 vaccine., *int. J. Nephrol. Renovasc. Dis* 14 (2021) 421–426, <https://doi.org/10.2147/IJNRD.S345898>.
- [334] N.A. Nasuelli, F. De Marchi, M. Cecchin, I. De Paoli, S. Onorato, R. Pettinaroli, G. Savoini, L. Godi, A case of acute demyelinating polyradiculoneuropathy with bilateral facial palsy after ChAdOx1 nCoV-19 vaccine., *Neurol. Sci. Off. J. Ital. Neurol. Soc. Ital. Soc. Clin. Neurophysiol* 42 (2021) 4747–4749, <https://doi.org/10.1007/s10072-021-05467-w>.
- [335] J.S. Al-Maqbali, S. Al Rasbi, M.S. Kashoub, A.M. Al Hinaai, H. Farhan, B. Al Rawahi, A.M. Al Alawi, A 59-year-old woman with extensive deep vein thrombosis and pulmonary thromboembolism 7 Days following a first dose of the pfizer-BioNTech BNT162b2 mRNA COVID-19 vaccine., *Am. J. Case Rep* 22 (2021), <https://doi.org/10.12659/AJCR.932946> e932946.
- [336] A. Greinacher, T. Thiele, T.E. Warkentin, K. Weisser, P.A. Kyrle, S. Eichinger, Thrombotic thrombocytopenia after ChAdOx1 nCoV-19 vaccination., *N. Engl. J. Med.* 384 (2021) 2092–2101, <https://doi.org/10.1056/NEJMoa2104840>.
- [337] C. McShane, C. Kiat, J. Rigby, Ó. Crosbie, the mRNA COVID-19 vaccine - a rare trigger of autoimmune hepatitis?., *J. Hepatol.* 75 (2021) 1252–1254, <https://doi.org/10.1016/j.jhep.2021.06.044>.
- [338] P.O. Idogun, M.C. Ward, Y. Teklie, W. Wiese-Rometsch, J. Baker, Newly diagnosed idiopathic thrombocytopenia post COVID-19 vaccine administration, *Cureus* 13 (2021), <https://doi.org/10.7759/cureus.14853> e14853.
- [339] A.M. N. A.M. Saleh, A. Khalid, A.K. Alshaya, S.M.M. Alanazi, Systemic lupus erythematosus with acute pancreatitis and vasculitic rash following COVID-19 vaccine: a case report and literature review, *Clin. Rheumatol.* 41 (2022) 1577–1582, <https://doi.org/10.1007/s10067-022-06097-z>.
- [340] D. Magliulo, S. Narayan, F. Ue, A. Boulougoura, F. Badlissi, Adult-onset Still's disease after mRNA COVID-19 vaccine, *Lancet. Rheumatol* 3 (2021) e680–e682, [https://doi.org/10.1016/S2665-9913\(21\)00219-8](https://doi.org/10.1016/S2665-9913(21)00219-8).
- [341] J.E.D. Brubaker, C.L. Casaccio, M.J. Brazeau, Recurrence of autoimmune hepatitis after COVID-19 vaccination, *Cureus* 14 (2022), <https://doi.org/10.7759/cureus.25339> e25339.
- [342] K. Mekrithikrai, P. Jaru-Ampornpan, P. Komolmit, K. Thanapirom, Autoimmune hepatitis triggered by COVID-19 vaccine: the first case from inactivated vaccine.,

- ACG Case Reports J 9 (2022), <https://doi.org/10.14309/crj.0000000000000811> e00811.
- [343] B.C. Kim, H.S. Kim, K.H. Han, S.Y. Han, H.A. Jo, A case report of MPO-ANCA-associated vasculitis following heterologous mRNA1273 COVID-19 booster vaccination, *J. Kor. Med. Sci.* 37 (2022), <https://doi.org/10.3346/jkms.2022.37.e204> e204.
- [344] J. Finsterer, Letter to the editor: pre-existing neuropathy favours SARS-CoV-2 vaccination associated guillain-barre syndrome, *J. Kor. Med. Sci.* 37 (2022), <https://doi.org/10.3346/jkms.2022.37.e217>.
- [345] H. Kanamori, Gross hematuria can be an impact of severe acute respiratory syndrome coronavirus 2 vaccination on immunoglobulin A nephropathy: a case report, *J. Med. Case Rep.* 16 (2022) 273, <https://doi.org/10.1186/s13256-022-03514-4>.
- [346] R.M. Ruggeri, L. Giovanella, A. Campenni, SARS-CoV-2 vaccine may trigger thyroid autoimmunity: real-life experience and review of the literature, *J. Endocrinol. Invest.* (2022) 1–7, <https://doi.org/10.1007/s40618-022-01863-x>.
- [347] E. Khan, A.K. Shrestha, M.A. Colantonio, R.N. Liberio, S. Sriwastava, Acute transverse myelitis following SARS-CoV-2 vaccination: a case report and review of literature, *J. Neurol.* 269 (2022) 1121–1132, <https://doi.org/10.1007/s00415-021-10785-2>.
- [348] C. Baicus, C. Delcea, L. Pinte, G.A. Dan, Hyper-inflammation after COVID-19 mRNA vaccination: at the crossroads of multisystem inflammatory disease and adult-onset Still's disease. Does terminology matter? *Rom. J. Intern. Med.* 60 (2022) 3–5, <https://doi.org/10.2478/rjim-2021-0035>.
- [349] K. Nagai, M. Iwase, A. Ueda, A case of anti-GBM nephritis following centipede bites and COVID-19 vaccination., *CEN Case Reports* 11 (2022) 166–170, <https://doi.org/10.1007/s13730-021-00646-2>.
- [350] M.Y. Abou-Ismael, K.A. Moser, K.J. Smock, M.Y. Lim, Vaccine-induced thrombotic thrombocytopenia following Ad26.COVID.S vaccine in a man presenting as acute venous thromboembolism, *Am. J. Hematol.* 96 (2021) E346–E349, <https://doi.org/10.1002/ajh.26265>.
- [351] S. Molina Rios, R. Rojas Martinez, G.M. Estévez Ramirez, Y.F. Medina, Systemic Lupus Erythematosus, Antiphospholipid Syndrome, After COVID-19 vaccination, *A Case Report., Mod. Rheumatol. Case Reports* (2022), <https://doi.org/10.1093/mrcr/rxac018>.
- [352] A. Mejren, C.M. Sørensen, L.C. Gormsen, R.S. Tougaard, B.D. Nielsen, Large-vessel giant cell arteritis after COVID-19 vaccine, *Scand. J. Rheumatol.* 51 (2022) 154–155, <https://doi.org/10.1080/03009742.2021.1961401>.
- [353] V. Rinaldi, G. Bellucci, A. Romano, A. Bozzao, M. Salvetti, ADEM after ChAdOx1 nCoV-19 vaccine: a case report., *Mult. Scler* 28 (2022) 1151–1154, <https://doi.org/10.1177/13524585211040222>.
- [354] K. Saito, S. Ichikawa, S. Hatta, Y. Katsuoka, H. Harigae, T. Izumi, Vincristine therapy for severe and refractory immune thrombocytopenia following COVID-19 vaccination, *Ann. Hematol.* 101 (2022) 885–887, <https://doi.org/10.1007/s00277-021-04666-x>.
- [355] G.S. Zin Tun, D. Gleeson, A. Al-Joudeh, A. Dube, Immune-mediated hepatitis with the Moderna vaccine, no longer a coincidence but confirmed, *J. Hepatol.* 76 (2022) 747–749, <https://doi.org/10.1016/j.jhep.2021.09.031>.
- [356] F.-Z. Agharbi, M. Eljzouly, G. Basri, M. Faik, A. Benkirane, A. Albouzi, S. Chiheb, Bullous pemphigoid induced by the AstraZeneca COVID-19 vaccine, *Ann. Dermatol. Venereol.* 149 (2022) 56–57, <https://doi.org/10.1016/j.annder.2021.07.008>.
- [357] F. Permezel, B. Borojevic, S. Lau, H.H. de Boer, Acute disseminated encephalomyelitis (ADEM) following recent Oxford/AstraZeneca COVID-19 vaccination, *Forensic Sci. Med. Pathol.* 18 (2022) 74–79, <https://doi.org/10.1007/s12024-021-00440-7>.
- [358] S. Torrente, A. Castiella, M. Garmendia, E. Zapata, Probable autoimmune hepatitis reactivated after COVID-19 vaccination, *Gastroenterol. Hepatol.* 45 (Suppl 1) (2022) 115–116, <https://doi.org/10.1016/j.gastrohep.2021.10.002>.
- [359] F. Hali, A. Kerouach, H. Alatawna, S. Chiheb, H. Lakhdar, Linear IgA bullous dermatosis following Oxford AstraZeneca COVID-19 vaccine, *Clin. Exp. Dermatol.* 47 (2022) 611–613, <https://doi.org/10.1111/ced.15007>.
- [360] T. Gambichler, N. Hamdani, H. Budde, M. Sieme, M. Skrygan, L. Scholl, H. Dickel, B. Behle, N. Ganjuur, C. Scheel, N. Abu Rached, L. Ocker, R. Stranzenbach, M. Doerler, L. Pfeiffer, J.C. Becker, Bullous pemphigoid after SARS-CoV-2 vaccination: spike-protein-directed immunofluorescence confocal microscopy and T-cell-receptor studies, *Br. J. Dermatol.* 186 (2022) 728–731, <https://doi.org/10.1111/bjd.20890>.
- [361] C. Zengarin, A. Pileri, F.P. Salamone, B.M. Piraccini, G. Vitale, M. La Placa, Subacute cutaneous lupus erythematosus induction after SARS-CoV-2 vaccine in a patient with primary biliary cholangitis, *J. Eur. Acad. Dermatol. Venereol.* 36 (2022) e179–e180, <https://doi.org/10.1111/jdv.17827>.
- [362] S. Patil, A. Patil, Systemic lupus erythematosus after COVID-19 vaccination: a case report., *J. Cosmet. Dermatol.* 20 (2021) 3103–3104, <https://doi.org/10.1111/jocd.14386>.
- [363] M. Mokos, N. Bašić-Jukić, IgA nephropathy following SARS-CoV-2 vaccination in a renal transplant recipient with a history of aristolochic acid nephropathy., *Ther. Apher. Dial. Off. Peer-Reviewed J, Int. Soc. Apher. Japanese Soc. Apher. Japanese Soc. Dial. Ther* 26 (2022) 667–668, <https://doi.org/10.1111/1744-9987.13765>.
- [364] A. Abicić, I. Adamec, M. Habek, Miller Fisher syndrome following Pfizer COVID-19 vaccine, *Neurol. Sci. Off. J. Ital. Neurol. Soc. Ital. Soc. Clin. Neurophysiol* 43 (2022) 1495–1497, <https://doi.org/10.1007/s10072-021-05776-0>.
- [365] V. Moreno-Torres, Á. Gutiérrez, M. Valdenebro, A. Ortega, M.-J. Ciferos, E. Montero, Catastrophic antiphospholipid syndrome triggered by mRNA COVID-19 vaccine, *Clin. Exp. Rheumatol.* 40 (2022) 1054–1055, <https://doi.org/10.55563/clinexprheumatol/s3sbgv>.
- [366] G. V. Knecht, S.M. Seyed Jafari, T. Berger, A. Rammlair, L. Feldmeyer, L. Borradori, Development of pemphigus vulgaris following mRNA SARS-CoV-19 BNT162b2 vaccination in an 89-year-old patient, *J. Eur. Acad. Dermatol. Venereol.* 36 (2022) e251–e253, <https://doi.org/10.1111/jdv.17868>.
- [367] D. Erard, F. Villeret, P.-M. Lavrut, J. Dumortier, Autoimmune hepatitis developing after COVID 19 vaccine: presumed guilty? *Clin. Res. Hepatol. Gastroenterol* 46 (2022) 101841, <https://doi.org/10.1016/j.clinre.2021.101841>.
- [368] M. Pauluzzi, G. Stinco, E. Errichetti, Bullous pemphigoid in a young male after COVID-19 mRNA vaccine: a report and brief literature review, *J. Eur. Acad. Dermatol. Venereol.* 36 (2022) e257–e259, <https://doi.org/10.1111/jdv.17891>.
- [369] L. Dams, M. Kraemer, J. Becker, MOG-antibody-associated longitudinal extensive myelitis after ChAdOx1 nCoV-19 vaccination, *Mult. Scler.* 28 (2022) 1159–1162, <https://doi.org/10.1177/13524585211057512>.
- [370] H. Nakano, K. Yamaguchi, K. Kawabata, M. Asakawa, Y. Matsumoto, Acute transverse myelitis after BNT162b2 vaccination against COVID-19: report of a fatal case and review of the literature, *J. Neurol. Sci.* 434 (2022) 120102, <https://doi.org/10.1016/j.jns.2021.120102>.
- [371] S. Ottaviani, P.-A. Juge, M. Forien, E. Ebstein, E. Palazzo, P. Dieudé, Polymyalgia rheumatica following COVID-19 vaccination: a case-series of ten patients., *Jt, Bone Spine* 89 (2022) 105334, <https://doi.org/10.1016/j.jbspin.2021.105334>.
- [372] N. Abu Rached, R. Mansour, L. Susok, S. Fried, N. Abolmaali, Y.-P. Lee, T. Gambichler, Sarcoid immune reaction following SARS-CoV-2 vaccination, *Clin. Exp. Dermatol.* 47 (2022) 970–972, <https://doi.org/10.1111/ced.15082>.
- [373] J. Finsterer, Z. Redzic, Symptomatic peduncular, cavernous bleeding following SARS-CoV-2 vaccination induced immune thrombocytopenia, *Brain Hemorrhages* 2 (2021) 169–171, <https://doi.org/10.1016/j.jhest.2021.09.001>.
- [374] N. Kim, J.-H. Kim, J.-S. Park, Guillain-Barré syndrome associated with BNT162b2 COVID vaccination: a first case report from South Korea, *Neurol. Sci. Off. J. Ital. Neurol. Soc. Ital. Soc. Clin. Neurophysiol* 43 (2022) 1491–1493, <https://doi.org/10.1007/s10072-021-05849-0>.
- [375] B. Pla Peris, A.Á. Merchante Alfaro, F.J. Maravall Royo, P. Abellán Galiana, S. Pérez Naranjo, M. González Boillos, Thyrotoxicosis following SARS-COV-2 vaccination: a case series and discussion, *J. Endocrinol. Invest.* 45 (2022) 1071–1077, <https://doi.org/10.1007/s40618-022-01739-0>.
- [376] M. Capezzone, M. Tosti-Balducci, E.M. Morabito, G.P. Caldarelli, A. Sagnella, S. Cantara, M. Alessandri, M.G. Castagna, Silent thyroiditis following vaccination against COVID-19: report of two cases, *J. Endocrinol. Invest.* 45 (2022) 1079–1083, <https://doi.org/10.1007/s40618-021-01725-y>.
- [377] W.-K. Hung, C.-C. Chi, Incident bullous pemphigoid in a psoriatic patient following mRNA-1273 SARS-CoV-2 vaccination, *J. Eur. Acad. Dermatol. Venereol.* 36 (2022) e407–e409, <https://doi.org/10.1111/jdv.17955>.
- [378] E. Afacan, Y.C. Edek, N. İlter, A. Gülekon, Can Covid-19 vaccines cause or exacerbate bullous pemphigoid? A report of seven cases from one center., *Int. J. Dermatol.* 61 (2022) 626–627, <https://doi.org/10.1111/ijd.16086>.
- [379] H. Sasaki, A. Itoh, Y. Watanabe, Y. Nakajima, Y. Saisho, J. Irie, S. Meguro, H. Itoh, Newly developed type 1 diabetes after coronavirus disease 2019 vaccination: a case report, *J. Diabetes Investig* 13 (2022) 1105–1108, <https://doi.org/10.1111/jdi.13757>.
- [380] X. Tang, B. He, Z. Liu, Z. Zhou, X. Li, Fulminant type 1 diabetes after COVID-19 vaccination, *Diabetes Metab.* 48 (2022) 101324, <https://doi.org/10.1016/j.diabet.2022.101324>.
- [381] S.H. Oğuz, S.N. Şendur, B.G. İremli, A. Gürlek, T. Erbas, U. Ünlütürk, SARS-CoV-2 vaccine-induced thyroiditis: safety of revaccinations and clinical follow-up, *J. Clin. Endocrinol. Metab.* 107 (2022) e1823–e1834, <https://doi.org/10.1210/clinem/dgac049>.
- [382] E.A. AlQudari, L.I. Alabdian, A.A. Alkhatami, M.D. Alotaibi, H.A. Alhamzi, Adult-onset Still's disease after the ChAdOx1 nCoV-19 vaccine, *Cureus* 14 (2022), <https://doi.org/10.7759/cureus.21279>.
- [383] G. Akoglu, Pemphigus vulgaris after SARS-CoV-2 vaccination: a case with new-onset and two cases with severe aggravation., *Dermatol. Ther* 35 (2022), <https://doi.org/10.1111/dth.15396> e15396.
- [384] A.-S. Darrigade, H. Théophile, P. Sanchez-Pena, B. Milpied, M. Colbert, S. Pedeboscq, T. Pistone, M.-L. Jullié, J. Seneschal, Sweet syndrome induced by SARS-CoV-2 Pfizer-BioNTech mRNA vaccine, *Allergy* 76 (2021) 3194–3196, <https://doi.org/10.1111/all.14981>.
- [385] J.W. Kim, Y.G. Kim, Y.C. Park, S. Choi, S. Lee, H.J. Min, M.J. Kim, Guillain-barre syndrome after two COVID-19 vaccinations: two case reports with follow-up electrodiagnostic study, *J. Kor. Med. Sci.* 37 (2022), <https://doi.org/10.3346/jkms.2022.37.e58> e58.
- [386] T. Sugimoto, A. Yorishima, N. Oka, S. Masuda, Y. Yoshida, S. Hirata, Exacerbation of systemic lupus erythematosus after receiving mRNA-1273-based coronavirus disease 2019 vaccine, *J. Dermatol.* 49 (2022) e199–e200, <https://doi.org/10.1111/1346-8138.16327>.
- [387] S.-C. Chou, Y.-C. Chang, C.-K. Liao, T.-C. Chen, K.-J. Sun, W.-H. Huang, Y.-F. Wu, New presentations and exacerbations of immune thrombocytopenia after coronavirus disease 2019 vaccinations: the Taiwan experience, *Platelets* 33 (2022) 531–535, <https://doi.org/10.1080/09537104.2022.2042237>.
- [388] M. Stasiak, K. Zawadzka-Starzczyńska, A. Lewiński, Significance of HLA haplotypes in two patients with subacute thyroiditis triggered by mRNA-based COVID-19 vaccine, *Vaccines* 10 (2022), <https://doi.org/10.3390/vaccines10020280>.
- [389] C. Anamnart, N. Tisavipat, W. Owattanapanich, M. Apiwattanakul, P. Savangned, N. Prayoonwiwat, S. Siritho, N. Rattanathamskul, J. Jitprapaikulsan, Newly diagnosed neuromyelitis optica spectrum disorders following vaccination: case report and systematic review, *Mult. Scler. Relat. Disord* 58 (2022) 103414, <https://doi.org/10.1016/j.msard.2021.103414>.

- [390] H. Bostan, B. Ucan, M. Kizilgul, M. Calapkulu, S. Hepsen, U. Gul, I. Ozturk Unsal, E. Cakal, Relapsed and newly diagnosed Graves' disease due to immunization against COVID-19: a case series and review of the literature., *J. Autoimmun.* 128 (2022) 102809, <https://doi.org/10.1016/j.jaut.2022.102809>.
- [391] K. Sakurai, D. Narita, N. Saito, T. Ueno, R. Sato, S. Niitsuma, K. Takahashi, Z. Arihara, Type 1 diabetes mellitus following COVID-19 RNA-based vaccine, *J. Diabetes Investig* 13 (2022) 1290–1292, <https://doi.org/10.1111/jdi.13781>.
- [392] K. Al-Quliti, A. Qureshi, M. Quadri, B. Abdulhameed, A. Alanazi, R. Alhujeli, Acute demyelinating encephalomyelitis post-COVID-19 vaccination: a case report and literature review., *dis, (Basel, Switzerland)* 10 (2022), <https://doi.org/10.3390/diseases10010013>.
- [393] P. Dharmasaroja, Early flare-ups of myasthenia Gravis after thoracoscopic thymectomy in a patient recently receiving BNT162b2 mRNA COVID-19 vaccination, *Cureus* 14 (2022), <https://doi.org/10.7759/cureus.21571> e21571.
- [394] H. Hashizume, S. Ajima, Y. Ishikawa, Immunoglobulin A vasculitis post-severe acute respiratory syndrome coronavirus 2 vaccination and review of reported cases, *J. Dermatol.* 49 (2022) 560–563, <https://doi.org/10.1111/1346-8138.16326>.
- [395] M.E. Baffa, R. Maglie, N. Giovannozzi, F. Montefusco, S. Senatore, D. Massi, E. Antiga, Sweet syndrome following SARS-CoV2 vaccination, *Vaccines* 9 (2021), <https://doi.org/10.3390/vaccines9112121>.
- [396] F. Fimiano, D. D'Amato, A. Gambella, A. Marzano, G.M. Saracco, A. Morgando, Autoimmune hepatitis or drug-induced autoimmune hepatitis following Covid-19 vaccination? *Liver Int. Off. J. Int. Assoc. Study Liver* 42 (2022) 1204–1205, <https://doi.org/10.1111/liv.15224>.
- [397] J.S.Y. Wong, J.H.-E. Kang, K.Z. Maw, Acute immune thrombocytopenic purpura post first dose of COVID-19 vaccination, *Postgrad. Med. J.* 98 (2022) e129–e130, <https://doi.org/10.1136/postgradmedj-2021-140947>.
- [398] Y.J. Chee, H. Liew, W.H. Hoi, Y. Lee, B. Lim, H.X. Chin, R.T.R. Lai, Y. Koh, M. Tham, C.J. Seow, Z.H. Quek, A.W. Chen, T.P.L. Quek, A.W.K. Tan, R. Dalan, SARS-CoV-2 mRNA vaccination and graves' disease: a report of 12 cases and review of the literature., *J. Clin. Endocrinol. Metab.* 107 (2022) e2324–e2330, <https://doi.org/10.1210/clinem/dgac119>.
- [399] M. Etemadifar, H. Nouri, M. Salari, N. Sedaghat, Detection of anti-NMDA receptor antibodies following BBIBP-CorV COVID-19 vaccination in a rituximab-treated person with multiple sclerosis presenting with manifestations of an acute relapse, *Hum. Vaccines Immunother.* 18 (2022) 2033540, <https://doi.org/10.1080/21645515.2022.2033540>.
- [400] S. Tabatabaee, F. Rezaia, S.M.J. Alwedaie, E. Malekdar, Z. Badi, S. M. Tabatabaee, Z. Mirzaasgari, Post COVID-19 vaccination Guillain-Barre syndrome: three cases, *Hum. Vaccines Immunother.* 18 (2022) 2045153, <https://doi.org/10.1080/21645515.2022.2045153>.
- [401] R. Roongta, S. Mondal, S. Haldar, M.S. Kumar, A. Ghosh, Two flares of Still's disease after two doses of the ChAdOx1 vaccine, *Clin. Rheumatol.* 41 (2022) 1591–1596, <https://doi.org/10.1007/s10067-022-06124-z>.
- [402] F. Alshammari, Y. Abuzied, A. Korairi, M. Alajlan, M. Alzomia, M. AlSheef, Bullous pemphigoid after second dose of mRNA- (Pfizer-BioNTech) Covid-19 vaccine: a case report., *Ann. Med. Surg.* 75 (2022) 103420, <https://doi.org/10.1016/j.amsu.2022.103420>.
- [403] M. Kishimoto, T. Ishikawa, M. Odawara, Subacute thyroiditis with liver dysfunction following coronavirus disease 2019 (COVID-19) vaccination: report of two cases and a literature review, *Endocr. J.* (2022), <https://doi.org/10.1507/endocrj.EJ21-0629>.
- [404] S. De Bruyne, S. Van Landeghem, A. Schauwvlieghe, L. Noens, Life-threatening autoimmune hemolytic anemia following mRNA COVID-19 vaccination: don't be too prudent with the red gold, *Clin. Chem. Lab. Med.* 60 (2022) e125–e128, <https://doi.org/10.1515/cclm-2022-0118>.
- [405] J. Senda, R. Ashida, K. Sugawara, K. Kawaguchi, Acute meningoencephalitis after COVID-19 vaccination in an adult patient with rheumatoid vasculitis, *Intern. Med.* 61 (2022) 1609–1612, <https://doi.org/10.2169/INTERNALMEDICINE.8815-21>.
- [406] I. Majid, S. Mearaj, Sweet syndrome after Oxford-AstraZeneca COVID-19 vaccine (AZD1222) in an elderly female, *Dermatol. Ther.* 34 (2021), <https://doi.org/10.1111/dth.15146> e15146.
- [407] H. Ghorbani, T. Rouhi, Z. Vosough, J. Shokri-Shirvani, Drug-induced hepatitis after Sinopharm COVID-19 vaccination: a case study of a 62-year-old patient., *Int. J. Surg. Case Rep.* 93 (2022) 106926, <https://doi.org/10.1016/j.ijscr.2022.106926>.
- [408] Z. Saffarian, R. Samii, A. Ghanadan, H. Vahidnezhad, De novo severe pemphigus vulgaris following SARS-CoV-2 vaccination with BBIBP-CorV, *Dermatol. Ther.* 35 (2022), <https://doi.org/10.1111/dth.15448> e15448.
- [409] J. Thaler, C. Ay, K. V. Gleixner, A.W. Hauswirth, F. Cacioppo, J. Grafeneder, P. Quehenberger, I. Pabinger, P. Knöbl, Successful treatment of vaccine-induced prothrombotic immune thrombocytopenia (VIPIT), *J. Thromb. Haemostasis* 19 (2021) 1819–1822, <https://doi.org/10.1111/jth.15346>.
- [410] M. Chanut, R. Jaidi, M. Kohn, T. Grange, C. Brones, N. Lombion, P. Rousselot, T. Longval, Successful mRNA SARS-Cov-2 vaccine rechallenge after a first episode of immune thrombocytopenic purpura, *Platelets* 33 (2022) 652–653, <https://doi.org/10.1080/09537104.2022.2044463>.
- [411] P. Soltanpoor, G. Norouzi, Subacute thyroiditis following COVID-19 vaccination, *Clin. Case Reports* 9 (2021), <https://doi.org/10.1002/ccr3.4812> e04812.
- [412] M. Şahin Tekin, S. Şaylısoy, G. Yorulmaz, Subacute thyroiditis following COVID-19 vaccination in a 67-year-old male patient: a case report, *Hum. Vaccines Immunother.* 17 (2021) 4090–4092, <https://doi.org/10.1080/21645515.2021.1947102>.
- [413] D. Fanni, L. Saba, R. Demontis, C. Gerosa, A. Chighine, M. Nioi, J.S. Suri, A. Ravarino, F. Cau, D. Barcellona, M.C. Botta, M. Porcu, A. Scano, F. Coghe, G. Orrù, P. Van Eyken, Y. Gibo, G. La Nasa, E. D'aloja, F. Marongiu, G. Faa, Vaccine-induced severe thrombotic thrombocytopenia following COVID-19 vaccination: a report of an autoptic case and review of the literature., *Eur. Rev. Med. Pharmacol. Sci.* 25 (2021) 5063–5069, https://doi.org/10.26355/eurrev_202108_26464.
- [414] E. Sigstad, K.K. Grøholt, O. Westerheim, Subacute thyroiditis after vaccination against SARS-CoV-2, *Tidsskr. Nor. Lægeforen* 141 (2021), <https://doi.org/10.4045/tidsskr.21.0554>.
- [415] M. Borges Canha, J.S. Neves, A.I. Oliveira, A. Sarmiento, D. Carvalho, Subacute thyroiditis after severe acute respiratory syndrome coronavirus 2 vaxzevria vaccination in a patient with thyroid autoimmunity, *Cureus* 14 (2022), <https://doi.org/10.7759/cureus.22353> e22353.
- [416] M. Jhon, S.-H. Lee, T.-H. Oh, H.-C. Kang, Subacute thyroiditis after receiving the mRNA COVID-19 vaccine (moderna): the first case report and literature review in Korea., *J. Korean Med. Sci.* 37 (2022), <https://doi.org/10.3346/jkms.2022.37.e39> e39.
- [417] S.O. Oyibo, Subacute thyroiditis after receiving the adenovirus-vectored vaccine for coronavirus disease (COVID-19), *Cureus* 13 (2021), <https://doi.org/10.7759/cureus.16045> e16045.
- [418] E.S. Saygili, E. Karakilic, Subacute thyroiditis after inactive SARS-CoV-2 vaccine, *BMJ Case Rep.* 14 (2021), <https://doi.org/10.1136/bcr-2021-244711>.
- [419] S. Nagalli, N. Shankar Kikkeri, Sub-acute onset of guillain-barré syndrome post-mRNA-1273 vaccination: a case report., *SN Compr. Clin. Med.* 4 (2022) 41, <https://doi.org/10.1007/s42399-022-01124-1>.
- [420] A.K. Joseph, B.F. Chong, Subacute cutaneous lupus erythematosus flare triggered by COVID-19 vaccine, *Dermatol. Ther.* 34 (2021), <https://doi.org/10.1111/dth.15114> e15114.
- [421] M.O. Elborae, E.E.S.F. Essa, Stevens-Johnson syndrome post second dose of Pfizer COVID-19 vaccine: a case report., *Oral Surg. Oral Med. Oral Pathol. Oral Radiol.* 132 (2021) e139–e142, <https://doi.org/10.1016/j.oooo.2021.06.019>.
- [422] R. Bencharattaphakhi, P. Rerknimitr, Sinovac COVID-19 vaccine-induced cutaneous leukocytoclastic vasculitis, *JAAD Case Reports* 18 (2021) 1–3, <https://doi.org/10.1016/j.jder.2021.10.002>.
- [423] D. Niebel, J. Wenzel, D. Wilsmann-Theis, J. Ziob, J. Wilhelm, C. Braegelmann, Single-Center clinico-pathological case study of 19 patients with cutaneous adverse reactions following COVID-19 vaccines, *Dermatopathol. (Basel, Switzerland)* 8 (2021) 463–476, <https://doi.org/10.3390/dermatopathology8040049>.
- [424] Y. Aladdin, H. Algahtani, B. Shirah, Vaccine-induced immune thrombotic thrombocytopenia with disseminated intravascular coagulation and death following the ChAdOx1 nCoV-19 vaccine, *J. Stroke Cerebrovasc. Dis. Off. J. Natl. Stroke Assoc.* 30 (2021) 105938, <https://doi.org/10.1016/j.jstrokecerebrovasdis.2021.105938>.
- [425] J.M. Helms, K.T. Ansteatt, J.C. Roberts, S. Kamatam, K.S. Foong, J.-M.S. Labayog, M.D. Tarantino, Severe, refractory immune thrombocytopenia occurring after SARS-CoV-2 vaccine, *Hematol. Res. Rev.* 12 (2021) 221–224, <https://doi.org/10.2147/JBM.S307047>.
- [426] G.T. Maniscalco, V. Manzo, M.E. Di Battista, S. Salvatore, O. Moreggia, C. Scavano, A. Capuano, Severe multiple sclerosis relapse after COVID-19 vaccination: a case report., *front. Neurol.* 12 (2021) 721502, <https://doi.org/10.3389/fneur.2021.721502>.
- [427] K.M. Cooper, B. Switzer, Severe immune thrombocytopenic purpura after SARS-CoV-2 vaccine, *Arch. Clin. Cases* 8 (2021) 31–36, <https://doi.org/10.22551/2021.31.0802.10182>.
- [428] A. Gardellini, F. Guidotti, E. Maino, S. Steffanoni, M. Zancanella, M. Turrini, Severe immune thrombocytopenia after COVID-19 vaccination: report of four cases and review of the literature, *Blood Cells Mol. Dis.* 92 (2021) 102615, <https://doi.org/10.1016/j.bcmd.2021.102615>.
- [429] S. Bianchi, A. Angi, M. Passucci, G. Palumbo, E. Baldacci, A.M. Testi, Severe immune thrombocytopenia (ITP) following SARS-CoV-2 mRNA vaccine in a girl on immunosuppressive treatment and in prolonged stable phase of ITP, *e2022011, Mediterr. J. Hematol. Infect. Dis* 14 (2022), <https://doi.org/10.4084/MJHID.2022.011>.
- [430] S.R. V Gadi, P.A.R. Brunker, H. Al-Samkari, D.B. Sykes, R.R. Saff, J. Lo, P. Bendapudi, D.E. Leaf, R.K. Leaf, Severe autoimmune hemolytic anemia following receipt of SARS-CoV-2 mRNA vaccine, *Transfusion* 61 (2021) 3267–3271, <https://doi.org/10.1111/trf.16672>.
- [431] Y.G. Min, W. Ju, Y.-E. Ha, J.-J. Ban, S.A. Lee, J.-J. Sung, J.-Y. Shin, Sensory Guillain-Barre syndrome following the ChAdOx1 nCoV-19 vaccine: report of two cases and review of literature, *J. Neuroimmunol.* 359 (2021) 577691, <https://doi.org/10.1016/j.jneuroim.2021.577691>.
- [432] O. Fuego-Rodríguez, B. Valente-Acosta, R. Jimenez-Soto, Y. Neme-Yunes, S. I. Inclán-Alarcón, R. Trejo-Gonzalez, M.Á. García-Salcido, Secondary immune thrombocytopenia supposedly attributable to COVID-19 vaccination, *BMJ Case Rep.* 14 (2021), <https://doi.org/10.1136/bcr-2021-242220>.
- [433] S. Cadiou, A. Perdriger, S. Ardois, J.-D. Albert, O. Berthoud, A. Lescoat, P. Guggenbuhl, F. Robin, SARS-CoV-2, polymyalgia rheumatica and giant cell arteritis: COVID-19 vaccine shot as a trigger? Comment on: "Can SARS-CoV-2 trigger relapse of polymyalgia rheumatica?" by Manzo et al, *Joint Bone Spine* 2021 (88) (2022) 105282, <https://doi.org/10.1016/j.jbspin.2021.105282>, 105150., *Jt. Bone Spine.* 89.
- [434] K.R. Patel, M.E. Cunnane, D.G. Deschler, SARS-CoV-2 vaccine-induced subacute thyroiditis, *Am. J. Otolaryngol.* 43 (2022) 103211, <https://doi.org/10.1016/j.amjoto.2021.103211>.
- [435] A. Charidimou, S. Samudrala, A.M. Cervantes-Arslanian, J.M. Sloan, H. H. Dasenbrock, A. Daneshmand, Vaccine-induced immune thrombotic

- thrombocytopenia with concurrent arterial and venous thrombi following Ad26. COV2.S vaccination, *J. Stroke Cerebrovasc. Dis. Off. J. Natl. Stroke Assoc.* 30 (2021) 106113, <https://doi.org/10.1016/j.jstrokecerebrovasdis.2021.106113>.
- [436] K. Baskaran, A.W.S. Cohen, N. Weerasinghe, E. Vilayur, Report of two cases of minimal change disease following vaccination for COVID-19, *Nephrology* 27 (2022) 111–112, <https://doi.org/10.1111/nep.13995>.
- [437] F. Salem, J.L. Rein, S.M.-W. Yu, M. Abramson, P. Cravedi, M. Chung, Report of three cases of minimal change disease following the second dose of mRNA SARS-CoV-2 COVID-19 vaccine., *kidney int, Report 6* (2021) 2523–2524, <https://doi.org/10.1016/j.ekir.2021.07.017>.
- [438] M. De Fabritiis, M.L. Angelini, B. Fabbriozzi, G. Cenacchi, C. Americo, S. Cristino, M.F. Liferi, M. Cappuccilli, A. Spazzoli, L. Zambianchi, G. Mosconi, Renal thrombotic microangiopathy in concurrent COVID-19 vaccination and infection, *Pathogens* 10 (2021), <https://doi.org/10.3390/pathogens10081045>.
- [439] K. Parperis, M. Constantinou, Remitting seronegative symmetrical synovitis with pitting oedema following BNT162b2 mRNA COVID-19 vaccination, *BMJ Case Rep.* 14 (2021), <https://doi.org/10.1136/bcr-2021-244479>.
- [440] R. David, P. Hanna, K. Lee, A. Ritchie, Relapsed ANCA associated vasculitis following Oxford AstraZeneca ChAdOx1-S COVID-19 vaccination: a case series of two patients., *Nephrology* 27 (2022) 109–110, <https://doi.org/10.1111/nep.13993>.
- [441] C. Sissa, A. Al-Khaffaf, F. Frattini, R. Gaiardoni, E. Mimiola, P. Montorsi, B. Melara, M. Amato, F. Peyvandi, M. Franchini, Relapse of thrombotic thrombocytopenic purpura after COVID-19 vaccine., *Transfus. Apher. Sci. Off. J. World Apher. Assoc. Off. J. Eur. Soc. Haemapheresis* 60 (2021) 103145, <https://doi.org/10.1016/j.transci.2021.103145>.
- [442] M.F. Aydin, A. Yıldız, A. Oruç, M. Sezen, K. Dilek, M. Güllülü, M. Yavuz, A. Ersoy, Relapse of primary membranous nephropathy after inactivated SARS-CoV-2 virus vaccination, *Kidney Int.* 100 (2021) 464–465, <https://doi.org/10.1016/j.kint.2021.05.001>.
- [443] H. Komaba, T. Wada, M. Fukagawa, Relapse of minimal change disease following the pfizer-BioNTech COVID-19 vaccine., *Am. J. Kidney Dis. Off. J. Natl. Kidney Found* 78 (2021) 469–470, <https://doi.org/10.1053/j.ajkd.2021.05.006>.
- [444] C. Morlidge, S. El-Kateb, P. Jeevaratnam, B. Thompson, Relapse of minimal change disease following the AstraZeneca COVID-19 vaccine, *Kidney Int.* 100 (2021) 459, <https://doi.org/10.1016/j.kint.2021.06.005>.
- [445] E. Conticini, M. d'Alessandro, L. Bergantini, E. Bargagli, F. Gentili, M.A. Mazzei, L. Cantarini, B. Frediani, Relapse of microscopic polyangiitis after vaccination against COVID-19: a case report., *J. Med. Virol.* 93 (2021) 6439–6441, <https://doi.org/10.1002/jmv.27192>.
- [446] K. Boonyawat, P. Angchaisuksiri, Vaccine-induced immune thrombotic thrombocytopenia with ChAdOx1 nCoV-19 is rare in Asia., *Res. Pract. Thromb. Haemostasis* 6 (2022), <https://doi.org/10.1002/rth2.12644> e12644.
- [447] C. Masset, D. Kervella, C. Kandel-Aznar, A. Fantou, G. Blancho, M. Hamidou, Relapse of IgG4-related nephritis following mRNA COVID-19 vaccine, *Kidney Int.* 100 (2021) 465–466, <https://doi.org/10.1016/j.kint.2021.06.002>.
- [448] K. Tuschen, J.H. Bräsen, J. Schmitz, M. Vischedyk, A. Weidemann, Relapse of class V lupus nephritis after vaccination with COVID-19 mRNA vaccine, *Kidney Int.* 100 (2021) 941–944, <https://doi.org/10.1016/j.kint.2021.07.019>.
- [449] A. Major, T. Carll, C.W. Chan, C. Christenson, F. Aldarweesh, G.D. Wool, K. S. Cohen, Refractory vaccine-induced immune thrombotic thrombocytopenia (VITT) managed with delayed therapeutic plasma exchange (TPE), *J. Clin. Apher.* 37 (2022) 117–121, <https://doi.org/10.1002/jca.21945>.
- [450] X. Wu, J.H.L. Lim, J.S.S. Lee, M.T.-W. Chio, Recurrent erythema nodosum after the second dose of the Pfizer-BioNTech BNT162b2 COVID-19 messenger RNA vaccine, *JAAD Int* 6 (2022) 107–108, <https://doi.org/10.1016/j.jdin.2021.12.009>.
- [451] Q.-J. An, D.-A. Qin, J.-X. Pei, Reactive arthritis after COVID-19 vaccination, *Hum. Vaccines Immunother.* 17 (2021) 2954–2956, <https://doi.org/10.1080/21645515.2021.1920274>.
- [452] J.A. Maye, H.P. Chong, V. Rajagopal, W. Petchey, Reactivation of IgA vasculitis following COVID-19 vaccination, *BMJ Case Rep.* 14 (2021), <https://doi.org/10.1136/bcr-2021-247188>.
- [453] P.K. Krajewski, Ł. Matusiak, J.C. Szepietowski, Psoriasis flare-up associated with second dose of Pfizer-BioNTech BNT162b2 COVID-19 mRNA vaccine, *J. Eur. Acad. Dermatol. Venereol.* 35 (2021) e632–e634, <https://doi.org/10.1111/jdv.17449>.
- [454] J.-P. Chao, T.-F. Tsai, Psoriasis flare following ChAdOx1-S/nCoV-19 vaccination in patients with psoriasis under biologic treatment, *Dermatol. Sin.* 39 (2021) 208–209, <https://doi.org/10.4103/ds.ds.45.21>.
- [455] W.-C. Fang, L.-W. Chiu, S.C.-S. Hu, Psoriasis exacerbation after first dose of AstraZeneca coronavirus disease 2019 vaccine, *J. Dermatol.* 48 (2021) e566–e567, <https://doi.org/10.1111/1346-8138.16137>.
- [456] E. Sotiriou, A. Tsentemidou, K. Bakirtzi, A. Lallas, D. Ioannides, E. Vakirlis, Psoriasis exacerbation after COVID-19 vaccination: a report of 14 cases from a single centre, *J. Eur. Acad. Dermatol. Venereol.* 35 (2021) e857–e859, <https://doi.org/10.1111/jdv.17582>.
- [457] D. Page, N. Zhu, D. Sawler, H.W. Sun, E. Turley, M. Pai, C. Wu, Vaccine-induced immune thrombotic thrombocytopenia presenting with normal platelet count., *Res. Pract. Thromb. Haemostasis* 5 (2021), <https://doi.org/10.1002/rth2.12596> e12596.
- [458] A. Tiede, U.J. Sachs, A. Czwalinna, S. Werwitzke, R. Bikker, J.K. Krauss, F. Donnerstag, K. Weißenborn, G. Höglinger, B. Maasoumy, H. Wedemeyer, A. Ganser, Prothrombotic immune thrombocytopenia after COVID-19 vaccination, *Blood* 138 (2021) 350–353, <https://doi.org/10.1182/blood.2021011958>.
- [459] T. Gambichler, L. Scholl, H. Dickel, L. Ocker, R. Stranzenbach, Prompt onset of Rowell's syndrome following the first BNT162b2 SARS-CoV-2 vaccination, *J. Eur. Acad. Dermatol. Venereol.* 35 (2021) e415–e416, <https://doi.org/10.1111/jdv.17225>.
- [460] J.F. Varona, M. García-Isidro, M. Moeinavaziri, M. Ramos-López, M. Fernández-Domínguez, Primary adrenal insufficiency associated with Oxford-AstraZeneca ChAdOx1 nCoV-19 vaccine-induced immune thrombotic thrombocytopenia (VITT), *Eur. J. Intern. Med.* 91 (2021) 90–92, <https://doi.org/10.1016/j.ejim.2021.06.025>.
- [461] J. Weijers, C. Alvarez, M.M.H. Hermans, Post-vaccinal minimal change disease, *Kidney Int.* 100 (2021) 459–461, <https://doi.org/10.1016/j.kint.2021.06.004>.
- [462] F. Zuhorn, T. Graf, R. Klingebiel, W.-R. Schäbitz, A. Rogalewski, Postvaccinal encephalitis after ChAdOx1 nCoV-19, *Ann. Neurol.* 90 (2021) 506–511, <https://doi.org/10.1002/ana.26182>.
- [463] A. Matta, R. Kallamadi, D. Matta, D. Bande, Post-mRNA COVID-19 vaccination myocarditis., *eur. J. Case Reports Intern. Med* 8 (2021) 2769, https://doi.org/10.12890/2021_002769.
- [464] M.E. Grossman, G. Appel, A.J. Little, C.J. Ko, Post-COVID-19 vaccination IgA vasculitis in an adult, *J. Cutan. Pathol.* 49 (2022) 385–387, <https://doi.org/10.1111/cup.14168>.
- [465] W. Waheed, M.E. Carey, S.R. Tandan, R. Tandan, Post COVID-19 vaccine small fiber neuropathy, *Muscle Nerve* 64 (2021) E1–E2, <https://doi.org/10.1002/mus.27251>.
- [466] N. Badrawi, N. Kumar, U. Albastaki, Post COVID-19 vaccination neuromyelitis optica spectrum disorder: case report & MRI findings, *Radiol. Case Reports* 16 (2021) 3864–3867, <https://doi.org/10.1016/j.radcr.2021.09.033>.
- [467] U. Nygaard, M. Holm, C. Bohnstedt, Q. Chai, L.S. Schmidt, U.B. Hartling, J.J. H. Petersen, J. Thaarup, J. Bjerre, N.G. Vejstrup, K. Juul, L.G. Stensballe, Population-based incidence of myopericarditis after COVID-19 vaccination in Danish adolescents, *Pediatr. Infect. Dis. J.* 41 (2022) e25–e28, <https://doi.org/10.1097/INF.0000000000003389>.
- [468] P. Vizcarra, J. Haemmerle, H. Velasco, T. Velasco, M. Fernández-Escribano, A. Vallejo, J.L. Casado, BNT162b2 mRNA COVID-19 vaccine Reactogenicity: the key role of immunity., *Vaccine* 39 (2021) 7367–7374, <https://doi.org/10.1016/j.vaccine.2021.10.074>.
- [469] A.W. Matthews, I.D. Griffiths, Post-vaccinal pericarditis and myocarditis, *Br. Heart J.* 36 (1974) 1043–1045, <https://doi.org/10.1136/hrt.36.10.1043>.
- [470] F.A. Klok, M. Pai, M. V. Huisman, M. Makris, Vaccine-induced immune thrombotic thrombocytopenia, *Lancet. Haematol* 9 (2022) e73–e80, [https://doi.org/10.1016/S2352-3026\(21\)00306-9](https://doi.org/10.1016/S2352-3026(21)00306-9).
- [471] P. Haber, J. Sejvar, Y. Mikaeloff, F. DeStefano, Vaccines and guillain-barré syndrome, *Drug Saf.* 32 (2009) 309–323, <https://doi.org/10.2165/00002018-200932040-00005>.
- [472] N.K. Jerne, Towards a network theory of the immune system, *Ann. Immunol. (Paris)* 125C (1974) 373–389.
- [473] R.E. Paque, R. Miller, Autoanti-idiotypes exhibit mimicry of myocyte antigens in virus-induced myocarditis, *J. Virol.* 65 (1991) 16–22, <https://doi.org/10.1128/JVI.65.1.16-22.1991>.
- [474] W.J. Murphy, D.L. Longo, A possible role for anti-idiotypic Antibodies in SARS-CoV-2 infection and vaccination, *N. Engl. J. Med.* 386 (2022) 394–396, <https://doi.org/10.1056/nejmeibr2113694>.
- [475] Y. Rodríguez, L. Novelli, M. Rojas, M. De Santis, Y. Acosta-Ampudia, D. M. Monsalve, C. Ramírez-Santana, A. Costanzo, W.M. Ridgway, A.A. Ansari, M. E. Gershwin, C. Selmi, J.-M. Anaya, Autoinflammatory and autoimmune conditions at the crossroad of COVID-19, *J. Autoimmun.* 114 (2020) 102506, <https://doi.org/10.1016/j.jaut.2020.102506>.
- [476] Y. Liu, A.H. Sawalha, Q. Lu, COVID-19 and autoimmune diseases, *Curr. Opin. Rheumatol.* 33 (2021) 155–162, <https://doi.org/10.1097/BOR.0000000000000776>.
- [477] J.-M. Anaya, M. Herrán, S. Beltrán, M. Rojas, Is post-COVID syndrome an autoimmune disease? *Expet Rev. Clin. Immunol.* (2022) <https://doi.org/10.1080/1744666X.2022.2085561>.
- [478] L. Wieske, L.Y.L. Kummer, K.P.J. van Dam, E.W. Stalman, A.J. van der Kooij, J. Raaphorst, M. Löwenberg, R.B. Takkenberg, A.G. Volkers, G.R.A.M. D'Haens, S. W. Tas, P.I. Spuls, M.W. Bekkenk, A.H. Musters, N.F. Post, A.L. Bosma, M. L. Hilhorst, Y. Vegting, F.J. Bemelman, J. Killestein, Z.L.E. van Kempen, A. E. Voskuyl, B. Broens, A.P. Sanchez, G. Wolbink, L. Boekel, A. Rutgers, K. de Leeuw, B. Horváth, J.J.G.M. Verschuuren, A.M. Ruiters, L. van Ouwerkerk, D. van der Woude, C.F. Allaart, Y.K.O. Teng, P. van Paassen, M.H. Busch, B.P. Jallah, E. Brusse, P.A. van Doorn, A.E. Baars, D. Hijnen, C.R.G. Schreurs, W.L. van der Pol, H.S. Goedee, M. Steenhuis, T. Rispena, A. Ten Brinke, N.J.M. Versteegen, K.A. H. Zwinderman, S.M. van Ham, T.W. Kuijpers, F. Eftimov, Risk factors associated with short-term adverse events after SARS-CoV-2 vaccination in patients with immune-mediated inflammatory diseases, *BMC Med.* 20 (2022) 100, <https://doi.org/10.1186/s12916-022-02310-7>.
- [479] M.A. Maré, E. Domínguez-Álvarez, C. Gamazo, Nucleic acid vaccination strategies against infectious diseases., *Expert Opin. Drug Deliv.* 12 (2015) 1851–1865, <https://doi.org/10.1517/17425247.2015.1077559>.
- [480] S. Reikine, J.B. Nguyen, Y. Modis, Pattern Recognition, Signaling Mechanisms, Of RIG-I and MDA5, *Front. Immunol.* 5 (2014) 342, <https://doi.org/10.3389/fimmu.2014.00342>.
- [481] H. Schurz, M. Salie, G. Tromp, E.G. Hoal, C.J. Kinnear, M. Möller, The X chromosome and sex-specific effects in infectious disease susceptibility., *Hum. Genomics* 13 (2019) 2, <https://doi.org/10.1186/s40246-018-0185-z>.

- [482] K. Pelka, T. Shibata, K. Miyake, E. Latz, Nucleic acid-sensing TLRs and autoimmunity: novel insights from structural and cell biology, *Immunol. Rev.* 269 (2016) 60–75, <https://doi.org/10.1111/imr.12375>.
- [483] S. D'haese, C. Lacroix, F. Garcia, M. Plana, S. Ruta, G. Vanham, B. Verrier, J. L. Aerts, Off the beaten path: novel mRNA-nanof formulations for therapeutic vaccination against HIV, *J. Control. Release Off. J. Control. Release Soc.* 330 (2021) 1016–1033, <https://doi.org/10.1016/j.jconrel.2020.11.009>.
- [484] E. Kowarz, L. Krutzke, J. Reis, S. Bracharz, S. Kochanek, R. Marschalek, "Vaccine-Induced Covid-19 Mimicry" Syndrome: Splice reactions within the SARS-CoV-2 Spike open reading frame result in Spike protein variants that may cause thromboembolic events in patients immunized with vector-based vaccines (2021), <https://doi.org/10.21203/rs.3.rs-558954/>, v1.
- [485] Z. Cai, M.I. Greene, Z. Zhu, H. Zhang, Structural Features, P.F.4 Functions, That occur in heparin-induced thrombocytopenia (HIT) complicated by COVID-19, *Antibodies* 9 (2020), <https://doi.org/10.3390/antib9040052>.
- [486] A. Greinacher, K. Selleng, T.E. Warkentin, Autoimmune heparin-induced thrombocytopenia, *J. Thromb. Haemostasis* 15 (2017) 2099–2114, <https://doi.org/10.1111/jth.13813>.
- [487] A. Greinacher, CLINICAL PRACTICE. Heparin-induced thrombocytopenia, *N. Engl. J. Med.* 373 (2015) 252–261, <https://doi.org/10.1056/NEJMcp1411910>.
- [488] S. Handtke, M. Wolff, C. Zaninetti, J. Wesche, L. Schönborn, K. Aurich, L. Ulm, N.-O. Hübner, K. Becker, T. Thiele, A. Greinacher, A flow cytometric assay to detect platelet-activating antibodies in VITT after ChAdOx1 nCov-19 vaccination, *Blood* 137 (2021) 3656–3659, <https://doi.org/10.1182/blood.2021012064>.
- [489] D. McGonagle, G. De Marco, C. Bridgewood, Mechanisms of immunothrombosis in vaccine-induced thrombotic thrombocytopenia (VITT) compared to natural SARS-CoV-2 infection, *J. Autoimmun.* 121 (2021) 102662, <https://doi.org/10.1016/j.jaut.2021.102662>.
- [490] A.T. Baker, R.J. Boyd, D. Sarkar, A. Teijeira-Crespo, C.K. Chan, E. Bates, K. Waraich, J. Vant, E. Wilson, C.D. Truong, M. Lipka-Lloyd, P. Fromme, J. Vermaas, D. Williams, L. Machiesky, M. Heurich, B.M. Nagalo, L. Coughlan, S. Umlauf, P.-L. Chiu, P.J. Rizkallah, T.S. Cohen, A.L. Parker, A. Singharoy, M. J. Borad, ChAdOx1 interacts with CAR and PF4 with implications for thrombosis with thrombocytopenia syndrome, *Sci. Adv.* 7 (2021), <https://doi.org/10.1126/sciadv.abl8213> eabl8213.
- [491] S. Holm, H. Kared, A.E. Michelsen, X.Y. Kong, T.B. Dahl, N.H. Schultz, T. A. Nyman, C. Fladeby, I. Seljeflot, T. Ueland, M. Stensland, S. Mjaaland, G.L. Goll, L.S. Nissen-Meyer, P. Aukrust, K. Skagen, I. Gregersen, M. Skjelland, P.A. Holme, L.A. Munthe, B. Halvorsen, Immune complexes, innate immunity, and NETosis in ChAdOx1 vaccine-induced thrombocytopenia, *Eur. Heart J.* 42 (2021) 4064–4072, <https://doi.org/10.1093/eurheartj/ehab506>.
- [492] E.N. Morgan, T.H. Pohlman, C. Vocelka, A. Farr, G. Lindley, W. Chandler, J. M. Griscavage-Ennis, E.D. Verrier, Nuclear factor kappaB mediates a procoagulant response in monocytes during extracorporeal circulation, *J. Thorac. Cardiovasc. Surg.* 125 (2003) 165–171, <https://doi.org/10.1067/mtc.2003.99>.
- [493] E.D. Hottz, I.G. Azevedo-Quintanilha, L. Palhinha, L. Teixeira, E.A. Barreto, C.R. R. Pão, C. Righy, S. Franco, T.M.L. Souza, P. Kurtz, F.A. Bozza, P.T. Bozza, Platelet activation and platelet-monocyte aggregate formation trigger tissue factor expression in patients with severe COVID-19, *Blood* 136 (2020) 1330–1341, <https://doi.org/10.1182/blood.2020007252>.
- [494] E. Mattsson, H. Herwald, A. Egesten, Superantigens from *Staphylococcus aureus* induce procoagulant activity and monocyte tissue factor expression in whole blood and mononuclear cells via IL-1 beta, *J. Thromb. Haemostasis* 1 (2003) 2569–2576, <https://doi.org/10.1111/j.1538-7836.2003.00498.x>.
- [495] T. Iba, Y. Umemura, H. Wada, J.H. Levy, Roles of coagulation abnormalities and microthrombosis in sepsis: pathophysiology, diagnosis, and treatment, *Arch. Med. Res.* 52 (2021) 788–797, <https://doi.org/10.1016/j.arcmed.2021.07.003>.