


Therapeutic Effects of Umbilical Cord Blood-Derived Mesenchymal Stem Cells Combined with Polydeoxyribonucleotides on Full-Thickness Rotator Cuff Tendon Tear in a Rabbit Model

Dong Rak Kwon¹, Gi-Young Park¹, Yong Suk Moon², and Sang Chul Lee³

Cell Transplantation
2018, Vol. 27(11) 1613–1622
© The Author(s) 2018
Article reuse guidelines:
sagepub.com/journals-permissions
DOI: 10.1177/0963689718799040
journals.sagepub.com/home/ctj


Abstract

While therapies using mesenchymal stem cells (MSCs) to treat rotator cuff tendon tear (RCTT) have yielded some promising preliminary results, MSCs therapy has not yet completely regenerated full-thickness RCTT (FTRCTT). It has recently been reported that polydeoxyribonucleotide (PDRN) is effective in the treatment of chronic rotator cuff disease. We hypothesized that local injection of human umbilical cord blood-derived (UCB)–MSCs with PDRN would be more effective in regenerating tendon tear than UCB–MSCs alone. The purpose of this study was to evaluate the effects of UCB–MSCs combined with different doses of PDRN on the regeneration of RCTT in a chronic RCTT model by using a rabbit model. New Zealand white rabbits ($n = 24$) with FTRCTT were allocated randomly into three groups (8 rabbits per group). Three different injectants (G1-S, 0.2 mL UCB–MSCs; G2-P1, 0.2 mL UCB–MSCs with one injection of 0.2 mL PDRN; G3-P4, 0.2 mL UCB–MSCs, and four injections of 0.2 mL PDRN per week) were injected into FTRCTT under US-guidance. After the rabbits were euthanized, we evaluated gross morphological and histological change. Motion analysis was also performed. There were significant differences in gross morphological changes between before, and at 4 weeks after injection, in all three groups, but no differences were found among the three groups. Masson's trichrome (MT) or anti-type I collagen antibody (COL-1)-positive cell densities in G2-P1 and G3-P4 were improved significantly compared with those in G1-S, but showed no significant difference between G2-P1 and G3-P4. On motion analysis, walking distance and fast walking time in G2-P1 and G3-P4 were significantly longer/higher than those in G1-S, but showed no significant differences between G2-P1 and G3-P4. These results demonstrated that there was no significant difference in the gross morphologic change of tendon tear between UCB–MSCs only and combination with PDRN injection in rabbit model of chronic traumatic FTRCTT. Furthermore, there were no significant differences in the regenerative effects between high and low doses of (0.8 and 0.2) mL of PDRN.

Keywords

Shoulder, rotator cuff, mesenchymal stem cells, polydeoxyribonucleotides, injections, ultrasonography

Introduction

Rotator cuff tendon tear (RCTT) is the most common tendon injury in adults. It affects about 30% of people over 60 years of age¹. Although surgical repair of a RCTT is one of the most common orthopedic procedures, the failure rate for rotator cuff tendon repair has been reported to be up to 90%². With the advent of arthroscopy, many procedures are becoming increasingly popular and widespread. However, none of these advances have significantly improved the quality of postoperative results in patients with recurrent RCTT.

¹ Department of Rehabilitation Medicine, Catholic University of Daegu School of Medicine, Daegu, South Korea

² Department of Anatomy, Catholic University of Daegu School of Medicine, Daegu, South Korea

³ Department and Research Institute of Rehabilitation Medicine, Yonsei University College of Medicine, Seoul, South Korea

Submitted: May 25, 2018. Revised: August 11, 2018. Accepted: August 14, 2018.

Corresponding Author:

Sang Chul Lee, Department and Research Institute of Rehabilitation Medicine, Yonsei University College of Medicine, 50 Yonsei-ro, Seodaemun-gu, Seoul 03722, South Korea.
Email: bettertomo@yuhs.ac



The unresolved disadvantage of current therapies has driven attempts to regenerate RCTT through the use of biological adjuvants. Mesenchymal stem cells (MSCs) have been proposed as an attractive alternative to overcome the limitations of current treatments³. While therapies using MSCs to treat RCTTs have yielded some promising preliminary results, a number of hurdles remain for clinical implementation of these therapies. First, it is difficult to quantify the therapeutic effect of MSCs alone, because previous study has only performed both surgical therapy and MSCs⁴. In studies of MSCs therapy with surgical repair, MSCs were only an adjuvant therapy, while the effect of surgical repair might overshadow the exact role of MSCs for the regeneration of injured tendon. Second, MSCs therapy has not yet completely regenerated full-thickness RCTTs (FTRCTT)^{5,6}.

Several factors might lead to the fact that MSCs therapies do not bring complete healing to rotator cuff tear. MSCs were first noticed due to their inherent ability to differentiate into a variety of cell phenotypes, thereby providing numerous potential cell therapies to treat an array of degenerative diseases and traumatic injuries. However, a recent paradigm shift has suggested that many functional improvements of MSCs might be due mainly to paracrine actions in the host tissue, rather than cell differentiation or repopulation⁷. Since the beneficial effects of MSCs transplantation are due mainly to the localized release of a number of trophic factors, not entirely due to stem cell differentiation, many researchers have focused on modulating the paracrine actions of MSCs to enhance their therapeutic efficacy. A number of different approaches, such as a combination of other therapies and the genetic manipulation of MSCs, have been considered to increase the total amount of secreted trophic factors and prolong the duration of secretion, to offer greater functional benefit with MSCs transplantation for tissue regeneration.

Another reason to consider MSCs combined with other therapies is that the effect of exogenous MSCs is not dose-dependent. A recent study in a porcine model of chronic myocardial infarction has found that cardiosphere-derived cells at escalating doses can equally enhance the preservation of cardiac function and tissue remodeling, without a dose–efficacy relationship⁸. If the effect of exogenous MSCs is not proportional to dose, it is better to combine that treatment with other therapies, rather than administering large amounts of MSCs, to improve their regenerative effect for RCTT.

Polydeoxyribonucleotide (PDRN) contains a mixture of deoxyribonucleotide polymers with chain lengths ranging from 50 to 2000 bp. It is a source of purine and pyrimidine deoxynucleosides/deoxyribonucleotides and bases⁹. PDRN is extracted from trout sperm, and purified as a preparation containing a high percentage of DNA. PDRN is a source of pyrimidines and purines. PDRN can stimulate nucleic acid synthesis through the salvage pathway¹⁰. It also induces angiogenesis and collagen synthesis. Moreover, it possesses anti-inflammatory activity¹¹. One recently published

study has reported that PDRN is effective in the treatment of chronic rotator cuff disease¹². It would be ideal if a combination of PDRN and MSCs has synergistic regenerative effects.

We hypothesized that the local injection of human umbilical cord blood-derived (UCB)–MSCs with PDRN would be more effective in regenerating tendon tear than UCB–MSCs alone. Therefore, the purpose of this study was to evaluate the effects of UCB–MSCs combined with different doses of PDRN on the regeneration of RCTT in a chronic RCTT model by using a rabbit subscapularis tendon model.

Materials and Methods

Animal Model

Twelve-week-old male New Zealand white rabbits ($n = 24$) were housed in separate metal cages at a temperature of $24 \pm 12^\circ\text{C}$, and a relative humidity of $45 \pm 10\%$. The animals had free access to tap water, and were fed a commercial rabbit diet. None of these rabbits received additional exercise. All were allowed to do normal activities in a ($65 \text{ cm} \times 45 \text{ cm} \times 30 \text{ cm}$) cage. Animal experiments were performed in accordance with internationally accredited guidelines, and were approved by the Institutional Animal Care and Use Committee (IACUC) of the University School of Medicine. Anesthesia was induced using isoflurane (JW Pharmaceutical, Goyang, South Korea) vaporized in oxygen, and delivered using a large animal cycling system. Under general anesthesia, ($5 \text{ mm} \times 5 \text{ mm}$) FTRCTTs were created just proximal to the insertion site on the left subscapularis tendon. Each excision wound was immediately covered with an unresorbable round silicone Penrose drainage tube (Sewoon Medical Co. Ltd, Cheonan, South Korea), to induce chronic rotator cuff tear¹³. The incision was closed using subcutaneous and skin sutures.

Preparation of MSCs

UCB was collected from the umbilical veins of pregnant women after neonatal delivery with informed consent. MSCs were isolated from UCB, and cultivated as described previously^{14,15}. These cells expressed cluster of differentiation 105 (CD105, 96.93%), CD90 (98.96%), CD29 (98.26%), CD166 (81.29%), CD73 (83.49%), CD45 (0.26%), CD14 (1.0%), and human leukocyte antigen D related (HLA-DR, 0.18%). They also expressed pluripotent markers, including octamer-binding transcription factor 4 (30.5%), and stage-specific embryonic antigen 4 (67.7%). UCB–MSCs can differentiate into various cell types, including respiratory epithelium, osteoblasts, chondrocytes, and adipocytes with specific *in vitro* induction stimuli^{16–18}. We confirmed the differentiation potential and karyotypic stability of UCB–MSCs up to passage 11. UCB–MSCs were mixed with viscous hyaluronic acid.

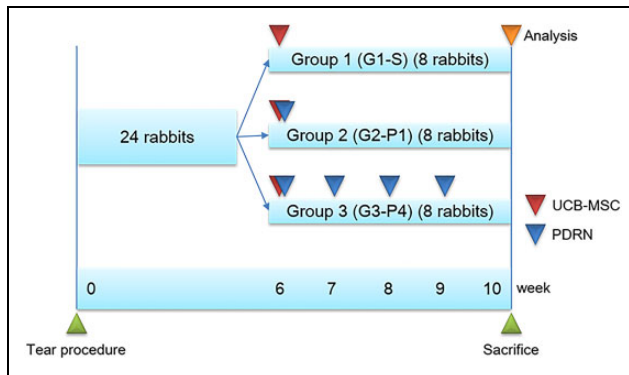


Fig. 1. Timeline of UCB-MSCs, UCB-MSCs with PDRN, and UCB-MSCs with PDRN injections four times per week. G1-S, 0.2 mL (1×10^6 cells) UCB-MSCs; G2-P1, 0.2 mL (1×10^6 cells) UCB-MSCs with one injection of 0.2 mL PDRN; G3-P4, 0.2 mL (1×10^6 cells) UCB-MSCs, and four injections of 0.2 mL PDRN per week were injected under ultrasound guidance into the left shoulder subscapularis full-thickness tears at 6 weeks after tears were created. All rabbits were euthanized by carbon monoxide inhalation 4 weeks after the first injection of different solutions, and gross morphology of the tear site, histologic examination, and motion analysis were performed. PDRN: Polydeoxyribonucleotide acid; UCB-MSCs: human umbilical cord blood-derived mesenchymal stem cell.

Animal Grouping and Injection

Six weeks after excisions, inserted tubes were removed, and the site of each FT subscapularis tendon tear was confirmed. After confirming the tube, the skin over the induced tendon rupture area was resealed for the injection of UCB-MSCs. Twenty-four rabbits were randomly allocated into three treatment groups ($n = 8$ per group) at 6 weeks after excision. Group 1 (G1-S) was injected with 0.2 mL (1×10^6 cells) UCB-MSCs. Group 2 (G2-P1) was injected with 0.2 mL (1×10^6 cells) UCB-MSCs with one injection of 0.2 mL of commercially obtained PDRN (Placentexingergro; Mastellisrl, San Remo, Italy), while group 3 (G3-P4) was injected with 0.2 mL UCB-MSCs and weekly four injections of 0.2 mL of PDRN. All 24 rabbits were euthanized at 4 weeks after the first injection (Fig. 1). All injections were performed under ultrasound (US) guidance by a physiatrist with 15 years of musculoskeletal US experience using a commercially available US system with an $\sim(18\text{--}5)\text{-MHz}$ multi-frequency linear transducer (EPIQ 5; Philips Healthcare, Andover, MA, USA). No medication was administered. All rabbits were immobilized in equinus position using an elastic bandage for 2 days after the injection.

Gross Morphology Examination

Gross morphologic examinations were conducted after each rabbit was euthanized. Each tendon tear was classified as partial thickness or FT (Figs. 2A1–A3). Gross morphologic tendon tears were photographed to the subscapularis tendon tear, using a clear plastic ruler near the center of the tear site, to permit calculation of size using ImageJ software (National

Institute of Health, Bethesda, MD, USA) by tracing the outlined tear edge pre-injection, and at 4 weeks post-injection (Figs. 2B1–B3).

Histological Examination

Tissue preparation. Rabbits were sacrificed under general anesthesia after all intra-muscular injections. The tear area of the subscapularis tendon was segmented, and fixed with neutral buffered formalin for 24 h. Each specimen was embedded in paraffin (Paraplast; Oxford, St. Louis, MO, USA), and sliced sagittally into 5 μm -thick serial sections. These specimens were stained with hematoxylin-eosin (H-E) (Figs. 3A1–A3) and Masson's Trichrome (MT) stain (Figs. 3B1–B3), and examined by light microscopy.

Immunohistochemistry. Tendon sections were immunohistochemically stained with marker of collagen fibers using mouse anti-collagen 1 monoclonal antibody (COL-1, Abcam, Cambridge, UK) (Figs. 3C1–C3), stained with proliferating cells using mouse anti-proliferating cell nuclear antigen monoclonal antibody (PCNA, PC10, Santa Cruz Biotechnology, Santa Cruz, CA, USA) (Figs. 3D1–D3), and stained with angiogenic markers using anti-vascular endothelial growth factor polyclonal antibody (VEGF, A-20, Santa Cruz Biotechnology) (Figs. 3E1–E3) and anti-platelet endothelial cell adhesion molecule-1 polyclonal antibody (PECAM-1, M-20, Santa Cruz Biotechnology) (Figs. 3F1–F3). Paraffin-embedded sections were then cleared, dehydrated, and washed with phosphate buffered saline (PBS). Antigen retrieval was performed using ethylenediaminetetraacetic acid (EDTA) buffer (1 mM EDTA, pH 8.0) for 30 minutes at 95°C , followed by cooling. Endogenous peroxidases were inhibited by preincubation with 0.3% hydrogen peroxide (H_2O_2) in PBS for 30 min. Non-specific protein binding was blocked in PBS containing 10% normal horse serum or normal goat serum or normal rabbit serum (Vector Laboratories, Burlingame, CA, USA) for 30 min. These sections were then incubated with primary antibodies (1:100–1:200) at room temperature for 2 h, and washed three times with PBS. Secondary antibody (1:100), biotinylated anti-mouse IgG or biotinylated anti-rabbit IgG or biotinylated anti-goat IgG (Vector Laboratories), was placed on sections, and incubated at room temperature for 1 hour. After washing with PBS three times, sections were exposed to avidin-biotin-peroxidase complex (ABC, Vector Laboratories) for 1 hour, washed three times with PBS, and subjected to a peroxidase reaction using 0.05 M Tris-HCl (pH 7.6) containing 0.01% H_2O_2 and 0.05% 3,3'-diaminobenzidine (DAB, Sigma-Aldrich, St. Louis, MO, USA). These sections were counterstained with hematoxylin, and then mounted. Slides were examined using an AxioPhot Photomicroscope (Carl Zeiss, Jena, Germany) equipped with an AxioCam MRc5 (Carl Zeiss). Each slide was evaluated according to the intensity of positive immunostaining.

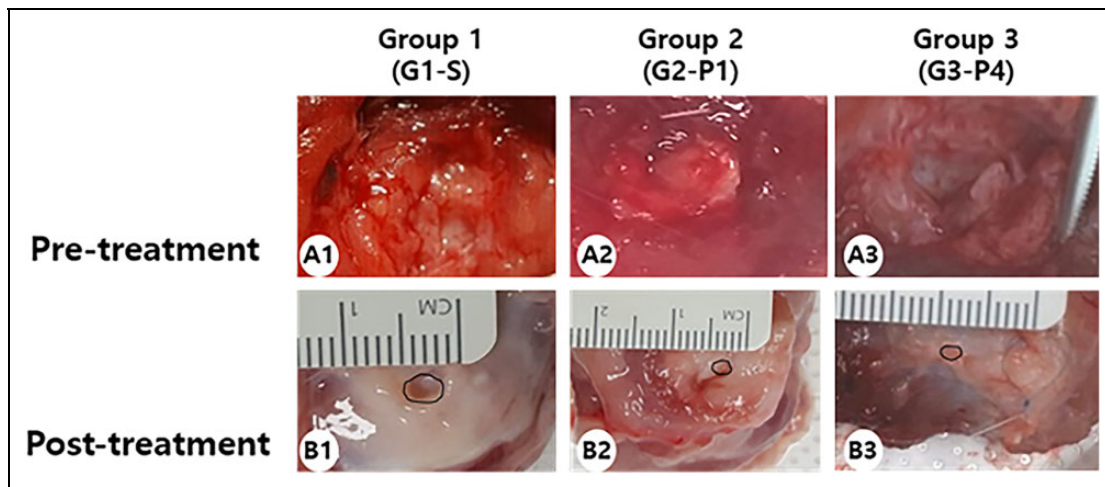


Fig. 2. Gross morphological (A1–B3) findings of subscapularis tendons in groups 1, 2, and 3. (A1–A3) Pre-treatment images. FTT is observed in all three groups. (B1–B3) Post-treatment images. There were significant differences in gross morphological changes between before injection, and at 4 weeks after injection, in all three groups. G1-S, 0.2 mL (1×10^6 cells) UCB-MSCs; G2-P1, 0.2 mL (1×10^6 cells) UCB-MSCs with one injection of 0.2 mL PDRN; G3-P4, 0.2 mL (1×10^6 cells) UCB-MSCs and four injections of 0.2 mL PDRN per week. PDRN: Polydeoxyribonucleotide acid; UCB-MSCs: human umbilical cord blood-derived mesenchymal stem cell; FTT: full thickness tear.

Evaluation of immunohistochemical staining. Thirty randomly selected fields from each group were photographed using AxioCam MRc5 interfaced with Axiophot Photomicroscope. AxioVision SE64 (Carl Zeiss) program was used for analysis. A semiquantitative scoring system was used for nuclear or cytoplasmic markers PCNA, VEGF, and PECAM-1, considering the staining intensity and extent of area. This approach is widely accepted, and has been used in previous studies^{19,20}. Briefly, the proportion of positive stained cells was scored as 0 (no cells stained positive), 1 (1–10% stain-positive cells), 2 (11–33% stain-positive cells), 3 (34–66% stain-positive cells), or 4 (67–100% stain-positive cells). The intensity of COL-1 immunostaining or MT staining was classified as 0 = negative staining, 1 = slight positive staining, 2 = moderately positive staining, or 3 = strongly positive staining.

Motion Analysis

Motion analysis of rabbit was conducted at pre-injection, and at 4 weeks post-injection. Rabbits were habituated for 30 min to the open field, before motion analysis was performed. They were placed on a (3 m \times 3 m) arena, and allowed to freely explore the field for 5 min. Their movements were assessed individually using a video-tracking system equipped with a camera (Smart; Panlab, Barcelona, Spain) that recorded the rabbit's horizontal activity; 5-min walking distance, fast walking time, and mean walking speed were measured.

Statistical Analyses

All statistical analyses were performed with SPSS program for Windows program, version 19.0 (SPSS Inc., Chicago, IL, USA). In addition to standard descriptive statistical calculations (means and standard deviation (SD)), analysis of variance

(ANOVA), and Kruskal-Wallis were used to determine statistical differences among intra- and inter-groups. When ANOVA and Kruskal-Wallis yielded significant results indicating that the group was significantly different from others, Tukey's test, and Mann-Whitney were also performed. Mean values were followed by 95% confidence intervals (CI). All data are expressed as mean \pm SD. Statistically significant levels were predetermined at $p < 0.05$ and $p < 0.016$, respectively.

Results

Gross Morphology

In G1-S, FT tendon tear in two (25%) rabbits, partial-thickness subscapularis tendon tear in four (50%) rabbits, and nearly complete healing in two (25%) rabbits were observed at 4 weeks post-injection. In G2-P1, FT tendon tear in one (12.5%) rabbit, partial-thickness subscapularis tendon tear in five (62.5%) rabbits, and nearly complete healing in two (25%) rabbits were observed. In G3-P4, partial-thickness subscapularis tendon tear in (62.5%) five rabbits and nearly complete healing in three (37.5%) rabbits were observed. There were significant differences in all three groups in gross morphologic changes between before injection, and at 4 weeks after injection. Gross morphologic mean tendon tear size at 4 weeks after the first injection was 3.84 mm² in G1-S, 3.35 mm² in G2-P1, and 3.81 mm² in G3-P4. There was no significant difference in tendon tear size among the three groups (Table 1, Fig. 2).

Histology and Immunohistochemistry

On H-E staining, a parallel arrangement of hypercellular fibroblastic bundles was observed in G1-S, G2-P1, and

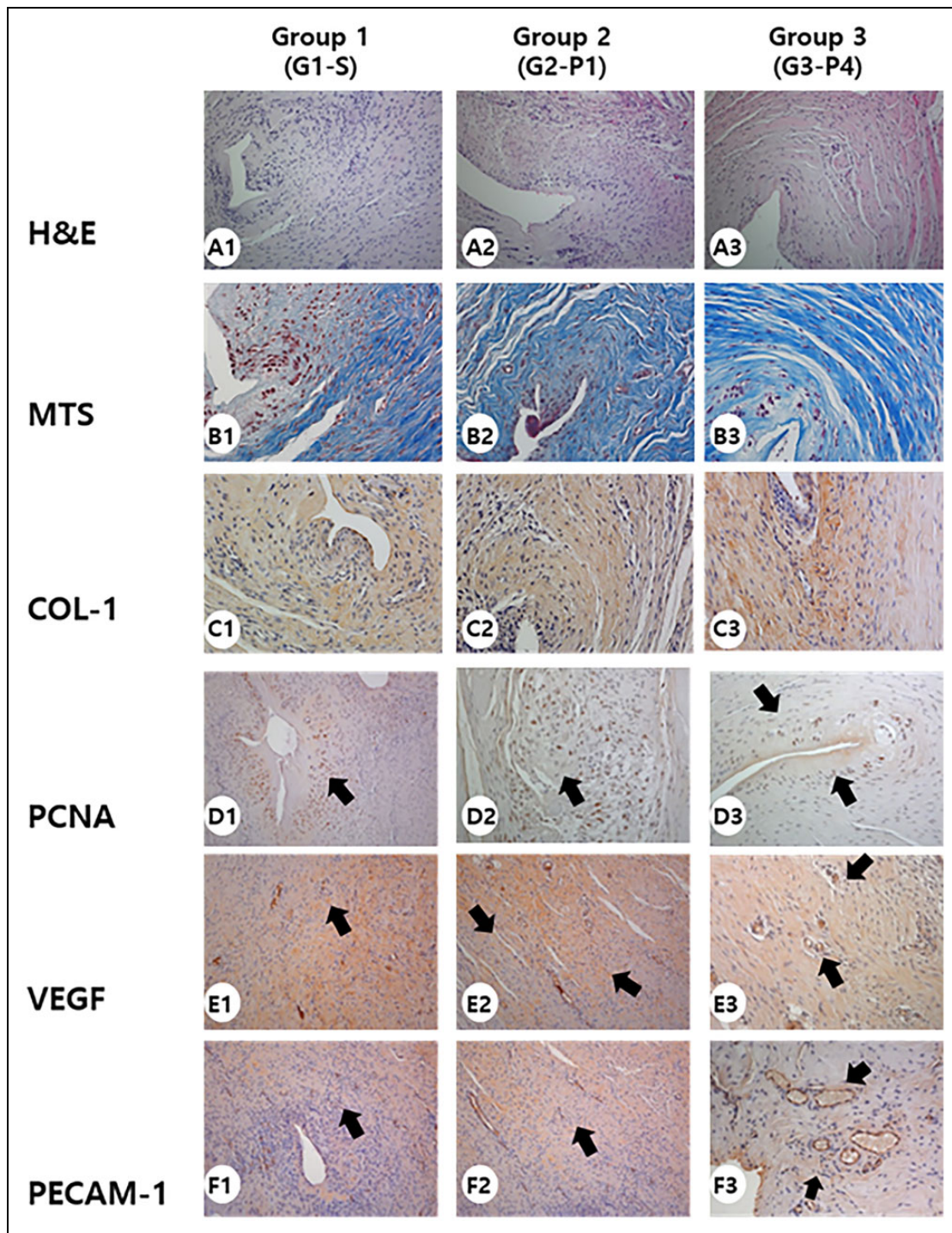


Fig. 3. Histologic (A1–F3) findings of subscapularis tendons in groups 1, 2, and 3. (A1–A3) Hematoxylin-eosin staining of subscapularis tendons in groups 1, 2, and 3. (B1–B3) Newly regenerated tendons are shown in blue-stained fibers (Masson's trichrome stain; X200) in groups 2 and 3. Few regenerative collagen fibers were seen in group 1. (C1–C3) Regenerated tendon fibers (X200) were stained with anti-type I collagen antibody in groups 2 and 3. Few regenerated tendon fibers were seen in group 1. (D1–D3) Numerous PCNA stained cells (black arrow, X200) were observed in regenerated tendon fibers in groups 1, 2, and 3. (E1–F3) Numerous VEGF-positive cells and PECAM-1 positive microvascular densities (black arrows, X200) were observed in groups 2 and 3. Few VEGF-positive cells and PECAM-1 positive microvascular densities were observed in group 1. G1-S, 0.2 mL (1×10^6 cells) UCB-MSCs; G2-P1, 0.2 mL (1×10^6 cells) UCB-MSCs with one injection of 0.2 mL PDRN; G3-P4, 0.2 mL (1×10^6 cells) UCB-MSCs and four injections of 0.2 mL PDRN per week. UCB-MSCs: Human umbilical cord blood-derived mesenchymal stem cell; PDRN: polydeoxyribonucleotide; MTS: Masson's trichrome stain; COL-1: anti-type I collagen antibody; PCNA: proliferating cell nuclear antigen; VEGF: vascular endothelial growth factor; PECAM-1: platelet endothelial cell adhesion molecule.

Table 1. Tear Size, Semiquantitative Score of Histological Findings, Immunoreactivity of Staining, and Motion Analysis According to Treatment Groups at 4 Weeks after the First Injection.

	Groups (injection regimens)		
	Group 1 (G1-S) (n = 8)	Group 2 (G2-P1) (n = 8)	Group 3 (G3-P4) (n = 8)
Gross			
Tear size	3.84 ± 4.09	3.35 ± 0.29	3.81 ± 1
Histological score			
MTS	1.88 ± 0.51	2.77 ± 0.43*	2.81 ± 0.4 [†]
COL-I	1.81 ± 0.49	2.62 ± 0.5*	2.85 ± 0.37 [†]
PCNA	2.62 ± 1.04	2.99 ± 0.97	2.92 ± 0.83
VEGF	2.61 ± 0.94	2.84 ± 0.86	3.05 ± 0.8 [†]
PECAM-I	2.54 ± 1.04	2.97 ± 0.74*	3.04 ± 0.73 [†]
Motion analysis			
Walking distance (cm)	6,343.63 ± 213.57	6,932.38 ± 115.18 [‡]	7,049.5 ± 187.78 [§]
Fast walking time (%)	10.03 ± 2.34	13.62 ± 1.1 [‡]	12.38 ± 0.96 [§]
Mean walking speed (cm/sec)	9.63 ± 1.78	12.3 ± 1.21 [‡]	14.68 ± 0.69 [§]

Values are mean ± SD. The intensity of MT staining or COL-I immunostaining was classified as 0 = negative staining, 1 = slight positive staining, 2 = moderately positive staining, or 3 = strongly positive staining. The proportion of positive cells of PCNA, VEGF, PECAM-I was scored as 0 = no cells stained positive, 1 = between 1 and 10%, 2 = between 11 and 33%, 3 = between 34 and 66%, and 4 = between 67 and 100%. G1-S, 0.2 mL (1×10^6 cells) UCB-MSCs; G2-P1, 0.2 mL (1×10^6 cells) UCB-MSCs with one injection of 0.2 mL PDRN; G3-P4, 0.2 mL (1×10^6 cells) UCB-MSCs, and four injections per week of 0.2 mL PDRN. UCB-MSCs: Human umbilical cord blood-derived mesenchymal stem cell; PDRN, Polydeoxyribonucleotide; MTS, Masson's trichrome stain; COL-I, Anti-type I collagen antibody; PCNA, Proliferating cell nuclear antigen; VEGF, Vascular endothelial growth factor; PECAM-I, Platelet endothelial cell adhesion molecule.

* $p < .016$ Kruskal-Wallis, Mann-Whitney test between groups 1 and 2.

[†] $p < .016$ Kruskal-Wallis, Mann-Whitney test between groups 1 and 3.

[‡] $p < .05$ one-way ANOVA, Tukey's post hoc test between groups 1 and 2.

[§] $p < .05$ one-way ANOVA, Tukey's post hoc test between groups 1 and 3.

^{||} $p < .05$ one-way ANOVA, Tukey's post hoc test between groups 2 and 3.

G3-P4 (Figs. 3A1–A3). On MT staining, regenerated collagen fibers were observed, and these regenerated tendon fibers were stained with COL-I in G1-S, G2-P1, and G3-P4 (Figs. 3B1–C3). Immunohistochemistry staining revealed numerous MT stained cells. COL-I-positive cell densities in G2-P1 and G3-P4 were significantly larger than those in G1-S (Table 1, Fig. 4). There were no significant differences in MT or COL-I staining results between G2-P1 and G3-P4 (Table 1, Fig. 4). Extensive PCNA staining was also observed in regenerated collagen fibers in G1-S, G2-P1, and G3-P4 (Figs. 3D1–D3). However, there were no significant differences in PCNA staining intensities among the three groups (Table 1, Fig. 4). Immunohistochemistry staining revealed numerous VEGF-positive cells. PECAM-1 positive microvascular densities in G2-P1 and G3-P4 were significantly higher than those in G1-S (Table 1, Figs. 3E1–F3 and 4). There were no significant differences in VEGF or PECAM-1 staining results between G2-P1 and G3-P4 (Table 1, Fig. 4).

Motion Analyses

On motion analysis, walking distance and fast walking time in G2-P1 and G3-P4 were significantly longer/higher than those in G1-S. There were no significant differences in

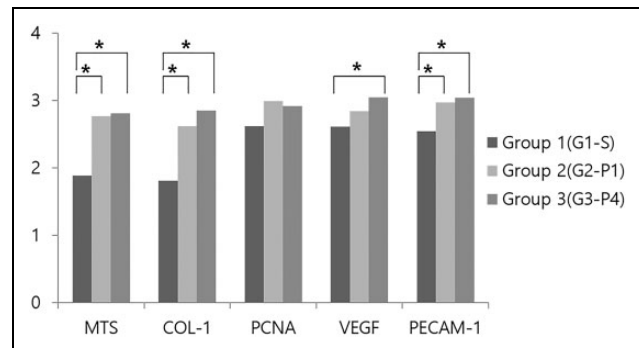


Fig. 4. Semiquantitative score of histological findings for immunoreactivity of stain. The intensity of MT staining or COL-I immunostaining and the proportion of PCNA-, VEGF-, or PECAM-1-positive cells were scored as detailed in the Materials and Methods. G1-S, 0.2 mL (1×10^6 cells) UCB-MSCs; G2-P1, 0.2 mL (1×10^6 cells) UCB-MSCs with one injection of 0.2 mL PDRN; G3-P4, 0.2 mL (1×10^6 cells) UCB-MSCs and four injections of 0.2 mL PDRN per week. UCB-MSCs: Human umbilical cord blood-derived mesenchymal stem cell; PDRN: polydeoxyribonucleotide; MTS: Masson's trichrome stain; COL-I: anti-type I collagen antibody; PCNA: proliferating cell nuclear antigen; VEGF: vascular endothelial growth factor; PECAM: platelet endothelial cell adhesion molecule. * $p < .016$ Kruskal-Wallis test for between-group comparisons, as well as the Mann-Whitney test for comparisons between pairs of groups, when appropriate.

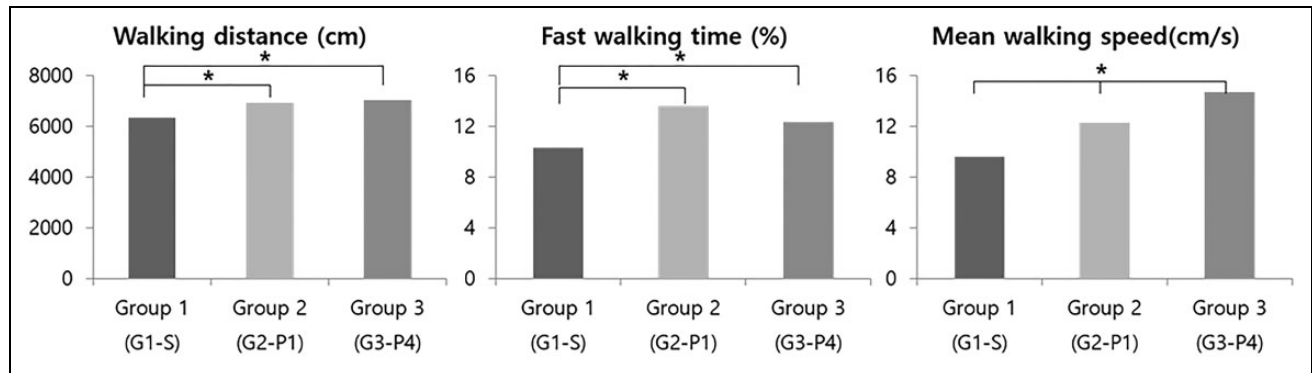


Fig. 5. Motion analysis of rabbits at 4 weeks after the first injection. Walking distance and fast walking time in groups 2 and 3 were significantly longer/higher than those in group 1. There were no significant differences in walking distance or fast walking time between groups 2 and 3. In group 3, mean walking speed was greater than that in the other two groups. * $p < .05$ one-way ANOVA, Tukey's post hoc test between groups. G1-S, 0.2 mL (1×10^6 cells) UCB-MSCs; G2-P1, 0.2 mL (1×10^6 cells) UCB-MSCs with one injection of 0.2 mL PDRN; G3-P4, 0.2 mL (1×10^6 cells) UCB-MSCs and four injections of 0.2 mL PDRN per week. UCB-MSCs: Human umbilical cord blood-derived mesenchymal stem cell; PDRN: polydeoxyribonucleotide.

walking distance or fast walking time between G2-P1 and G3-P4 (Table 1, Fig. 5). In G3-P4, mean walking speed was greater than that in the other two groups on motion analysis (Table 1, Fig. 5).

Discussion

At the design stage of this study, we hypothesized that local injection of UCB-MSCs with PDRN would be more effective in regenerating tendon tear than UCB-MSCs administration alone. In the UCB-MSCs with PDRN group, newly regenerated collagen type 1 fibers, cell proliferation, angiogenesis, walking distance, and fast walking time were greater than those in the USB-MSCs only group, based on histological and motion analyses. Since there were no significant differences in gross morphologic changes or tendon tear size between the PDRN-added and non-PDRN-treated groups, we were unable to demonstrate whether the combined therapy of PDRN with USB-MSCs was more effective than USB-MSCs alone. Moreover, this effect was not related to the dose of PDRN.

Since 2009, MSCs of different origins have been used for RCTT in various animal experiments. Oh et al. have verified the effect of adipose-derived MSCs on tendon healing and the reversal of fatty infiltration in a chronic RCTT model by using rabbit subscapularis²¹. They demonstrated that locally administered adipose-derived MSCs had positive effects on tendon-to-bone healing and fatty infiltration, as assessed by electrophysiological, biomechanical, and histological changes. However, the aim of their study was to reduce the fatty infiltration of subscapularis muscles by injecting MSCs into muscle with chronic repair, not to see the effect of MSCs on RCTT. Pelinkovic et al. have shown that the injection of muscle-derived MSCs into the supraspinatus tendon of athymic rats can result in the engraftment of transplanted cells in a pattern with a morphology comparable to resident tendon

fibers²². However, the authors suggest that more studies are necessary, before assuming that muscle-derived MSCs can improve rotator cuff healing. While therapies using MSCs to treat RCTTs have yielded some promising preliminary results, MSCs therapy has not yet completely regenerated full-thickness RCTTs.

Although MSCs of different origins have similar biological potential, UCB-MSCs have greater therapeutic potential than MSCs derived from other tissues, because of attributes such as non-invasive collection, the ability to hone in on injured tissue, low immunogenicity, multi-directional differentiation, and extensive secretion profiles^{23,24}. The function of autologous MSCs in patients with advanced age or significant comorbidities is impaired. Allogeneic UCB-MSCs may therefore be of particular benefit for the elderly, or those with multiple co-morbidities²⁵. In addition, UCB-MSCs can be produced commercially in larger quantities. Indeed, UCB-MSCs are now available as novel medicinal products (composite of allogeneic UCB-MSCs and hyaluronic acid hydrogel) for articular cartilage regeneration in patients with osteoarthritic knees²⁶. Low immunogenicity and safety are also characteristics of PDRN. PDRN is available as a pharmaceutical product for injection. The fact that the regenerative effect of UCB-MSCs is not dose-dependent, and increasing the volume of stem cells cannot be expected to result in better therapeutic effects, makes the rationale of combination with PDRN more compelling.

Currently, regeneration strategies for RCTT consist of therapies based on bioactive scaffolds with the use of cells and signaling molecules²⁷. During tissue regeneration, cell growth and differentiation, neovascularization, collagen synthesis, inflammatory response, and proteinase activity should be controlled²⁸. PDRNs and nucleotides and nucleosides resulting from its degradation can stimulate cell migration and growth, extracellular matrix protein production, and reduce inflammation²⁹. PDRN can penetrate inside the cell

via different transport mechanisms to provide purine and pyrimidine rings that can be utilized by enzymes of salvage pathways, thus stimulating the synthesis of nucleic acids with a significant energy saving mechanism³⁰. Purine nucleotides and nucleosides can bind to specific receptors, and trigger different signal transduction pathways. They can act as mitogens for fibroblasts, endothelial cells, and neuroglia^{31,32}. They also show synergistic effect with different growth factors^{33,34}. Given their safety, low production costs, the absence of systemic toxicity, and antigenicity signs, PDRNs are currently used in clinical practice for bone, cartilage, and tendon diseases³⁵.

The optimal dose of PDRN required for regenerating the rotator cuff has not yet been established. A half vial of PDRN (1.5 mL) has been injected each week for 3 weeks for the treatment of plantar fasciitis¹¹, while 5.625 mg in 3 mL of PDRN has been injected at weekly intervals for 3 weeks to treat chronic rotator cuff tendinopathy¹². We used 0.2 or 0.8 mL (four injections per week of 0.2 mL) of PDRN, because rabbit weight was about 5% of the weight of a typical adult. However, there were no significant differences in gross, histology, or motion analysis results, except mean walking speed, between the two groups administered with different doses of PDRN. PDRN increases vascular endothelial growth factor expression by stimulating adenosine A_{2A} receptor. Vascular endothelial growth factor is an angiogenic factor that can induce angiogenesis and collagen synthesis^{36,37}. VEGF is a major growth factor that accelerates the healing process by stimulating new vessel formation in poor circulatory areas, such as diabetic foot. Therefore, it could also help increase the healing process in degenerative tissue that involves poor circulation. Immunohistochemistry staining revealed numerous VEGF-positive cells, and that PECAM-1 positive microvascular densities in G2-P1 and G3-P4 were significantly larger than those in G1-S, although there was no significant difference in VEGF or PECAM-1 staining results between G2-P1 and G3-P4. Since there were no significant differences in gross morphologic changes or tendon tear size between PDRN-added and non-PDRN-treated groups in the current study, vascular endothelial growth factor expression increased by PDRN did not improve the regenerative effect of UCB-MSCs.

If the combination of PDRN and MSCs therapy does not show better effect over MSCs alone, how should the research on MSCs therapy for RCTT proceed in the future? Since regenerative effects of MSCs are due mainly to their paracrine actions, future studies regarding MSCs therapies for RCTT should focus on how to maximize paracrine action on target structures. Different researches primarily focusing on genetic manipulation and *in vitro* preconditioning have been conducted to increase the total amount of secreted trophic factors and prolong the duration of secretion, in order to increase functional benefit with transplanted MSCs for tissue regeneration. In addition, efforts to administer mechanical or thermal stimuli, exogenous cytokines, and other pharmacologic treatments, together with MSCs for the same purpose,

are also continuing⁷. It also seems to be necessary to use excellent scaffolds in order to attach MSCs to RCTT³⁸. It is known that transmembrane contacts between MSCs and different scaffolds are key factors for MSCs survival, proliferation, and differentiation³⁹. Physical and biochemical interactions between them may promote the regeneration of RCTT. Further studies on scaffolds in MSCs therapy are necessary.

In addition to evaluating the effect of UCB-MSCs combined with PDRN on FTRCTT, the current study has important features in the method. The first feature is the use of musculoskeletal US for US-guided injection. Musculoskeletal US can become a critical interventional tool for regenerative injection therapies, because US-guided injections allow stem cells to be selectively administered to the target area^{6,40}. Motion analysis of rabbit was also done to evaluate the improvement in functional ability, rather than the mechanical properties of a regenerated tendon⁶. Motion analysis is not yet proven to be superior to mechanical testing that is frequently used in animal models of rotator cuff tear^{21,41}. However, motion analysis is a potentially important tool to assess the therapeutic effect of rotator cuff tear, since functional tests have been demonstrated to be important tools to assess the effectiveness of treatments for FTRCTT in human studies⁴².

Chronic RCTTs adversely affect the surgical repair of lesions⁴³. Massive FTRCTTs are usually associated with myotendinous retraction, atrophy, and fatty infiltration of muscles that are poor prognostic factors for surgical outcomes. Therefore, a "chronic" FTRCTT model is needed to accurately assess the clinical utility of MSCs in humans. For this study, we used a rabbit model of a chronic traumatic RCTT after 6 weeks of trauma. Studies using rabbit supraspinatus muscle have shown fatty degeneration beginning as early as 4 weeks, with a peak at 6 weeks, and slow reversal by 12 weeks⁴⁴. FTRCTT becomes irreparable after approximately 6 weeks, due to excessive tendon retraction, and muscle atrophy and stiffening⁴⁵. Based on previous studies, we selected 6 weeks for chronic injury, although we did not confirm whether "chronic" findings were present in tendon injuries⁴⁴⁻⁴⁶.

There are some limitations to our study. First, we created (5 mm × 5 mm) FTRCTTs just proximal to the insertion site on the left subscapularis tendon. After each excision was made, each wound was immediately covered with a round silicone tube to induce chronic rotator cuff tear. Each wound was closed using subcutaneous and skin sutures. However, these tears were in the tendon body, not exactly at the insertion site. Second, complete regeneration did not occur. There would have been more "complete" rotator cuff healing, if outcomes were measured at 8 weeks or more, instead of at 4 weeks. Third, we did not perform biomechanical test of the regenerative tendon.

In conclusion, there was no significant difference in the gross morphologic change of tendon tear between UCB-MSCs only and combination with PDRN injection in rabbit

model of chronic traumatic FTRCTT. There were no differences in these regenerative effects between high and low (0.8 and 0.2 mL) dose groups of PDRN, either. However, co-injection of UCB-MSCs and PDRN was more effective than UCB-MSCs alone in histological and motion analyses. The results of this study regarding the combination of UCB-MSCs and PDRN warrant further investigation.

Acknowledgment

This study was financially supported by the “Dongwha Holdings” Faculty Research Assistance Program of the Yonsei University College of Medicine for (6-2015-0177).

Ethical Approval

The animal experimental protocol was approved by the University School of Medicine Animal Care and Use Committee.

Statement of Human and Animal Rights

Animal experiments were performed in accordance with internationally accredited guidelines, and were approved by the Institutional Animal Care and Use Committee (IACUC) of the University School of Medicine.

Statement of Informed Consent

There are no human subjects in this article, and informed consent is not applicable.

Declaration of Conflicting Interests

The author(s) declared no potential conflicts of interest with respect to the research, authorship, and/or publication of this article.

Funding

The author(s) disclosed receipt of the following financial support for the research and/or authorship of this article: “Dongwha Holdings” Faculty Research Assistance Program of the Yonsei University College of Medicine for (6-2015-0177).

References

1. Yamaguchi K, Ditsios K, Middleton WD, Hildebolt CF, Galatz LM, Teefey SA. The demographic and morphological features of rotator cuff disease. A comparison of asymptomatic and symptomatic shoulders. *J Bone Joint Surg Am.* 2006;88(8):1699–1704.
2. Castricini R, Longo UG, De Benedetto M, Panfoli N, Pirani P, Zini R, Maffulli N, Denaro V. Platelet-rich plasma augmentation for arthroscopic rotator cuff repair: a randomized controlled trial. *Am J Sports Med.* 2011;39(2):258–265.
3. Caplan AI. Mesenchymal stem cells. *J Orthop Res.* 1990;9(5):641–650.
4. Hernigou P, Flouzat Lachaniette CH, Delambre J, Zilber S, Duffiet P, Chevallier N, Rouard H. Biologic augmentation of rotator cuff repair with mesenchymal stem cells during arthroscopy improves healing and prevents further tears: a case-controlled study. *Int Orthop.* 2014;38(9):1811–1818.
5. Kim YS, Lee HJ, Ok JH, Park JS, Kim DW. Survivorship of implanted bone marrow-derived mesenchymal stem cells in acute rotator cuff tear. *J Shoulder Elbow Surg.* 2013;22(8):1037–1045.
6. Park GY, Kwon DR, Lee SC. Regeneration of full-thickness rotator cuff tendon tear after ultrasound-guided injection with umbilical cord blood-derived mesenchymal stem cells in a rabbit model. *Stem Cells Transl Med.* 2015;4(11):1344–1351.
7. Baraniak PR, McDevitt TC. Stem cell paracrine actions and tissue regeneration. *Regen Med.* 2010;5(1):121–143.
8. Tang XL, Rokosh G, Sanganalmath SK, Tokita Y, Keith MC, Shirik G, Stowers H, Hunt GN, Wu W, Dawn B, Bolli R. Effects of intracoronary infusion of escalating doses of cardiac stem cells in rats with acute myocardial infarction. *Circ Heart Fail.* 2015;8(4):757–765.
9. Yu M, Lee JY. Polydeoxyribonucleotide improves wound healing of fractional laser resurfacing in rat model. *J Cosmet Laser Ther.* 2017;19(1):43–48.
10. Galeano M, Bitto A, Altavilla D, Minutoli L, Polito F, Calò M, Lo Cascio P, Stagno d’Alcontres F, Squadrito F. Polydeoxyribonucleotide stimulates angiogenesis and wound healing in the genetically diabetic mouse. *Wound Repair Regen.* 2008;16(2):208–217.
11. Kim JK, Chung JY. Effectiveness of polydeoxyribonucleotide injection versus normal saline injection for treatment of chronic plantar fasciitis: a prospective randomised clinical trial. *Int Orthop.* 2015;39(7):1329–1334.
12. Yoon YC, Lee DH, Lee MY, Yoon SH. Polydeoxyribonucleotide injection in the treatment of chronic supraspinatus tendinopathy: a case-controlled, retrospective, comparative study with 6-month follow-up. *Arch Phys Med Rehabil.* 2017;98(5):874–880.
13. Coleman SH, Fealy S, Ehteshami JR, MacGillivray JD, Altchek DW, Warren RF, Turner AS. Chronic rotator cuff injury and repair model in sheep. *J Bone Joint Surg Am.* 2003;85-A(12):2391–2402.
14. Baydar M, Akalin E, El O, Gulbahar S, Bircan C, Akgul O, Manisali M, Torun Orhan B, Kizil R. The efficacy of conservative treatment in patients with full-thickness rotator cuff tears. *Rheumatol Int.* 2009;29(6):623–628.
15. Isaac C, Gharaibeh B, Witt M, Wright VJ, Huard J. Biologic approaches to enhance rotator cuff healing after injury. *J Shoulder Elbow Surg.* 2012;21(2):181–190.
16. Gerber C, Fuchs B, Hodler J. The results of repair of massive tears of the rotator cuff. *J Bone Joint Surg Am.* 2000;82(4):505–515.
17. Grumet RC, Hadley S, Diltz MV, Lee TQ, Gupta R. Development of a new model for rotator cuff pathology: the rabbit subscapularis muscle. *Acta Orthop.* 2009;80(1):97–103.
18. Lafosse L, Brzoska R, Toussaint B, Gobeze R. The outcome and structural integrity of arthroscopic rotator cuff repair with use of the double-row suture anchor technique. *Surgical technique. J Bone Joint Surg Am.* 2008;90(Suppl 2):S275–S286.
19. Han CP, Kok LF, Wang PH, Wu TS, Tyan YS, Cheng YW, Lee MY, Yang SF. Scoring of p16(INK4a) immunohistochemistry based on independent nuclear staining alone can sufficiently distinguish between endocervical and endometrial adenocarcinomas in a tissue microarray study. *Mod Pathol.* 2009;22(6):797–806.
20. Henriksen KL, Rasmussen BB, Lykkesfeldt AE, Møller S, Ejlersten B, Mouridsen HT. Semi-quantitative scoring of

- potentially predictive markers for endocrine treatment of breast cancer: a comparison between whole sections and tissue microarrays. *J Clin Pathol.* 2007;60(4):397–404.
21. Oh JH, Chung SW, Kim SH, Chung JY, Kim JY. 2013 Neer award: effect of the adipose-derived stem cell for the improvement of fatty degeneration and rotator cuff healing in rabbit model. *J Shoulder Elbow Surg.* 2014;23(4):445–455.
 22. Gharaibeh B, Lu A, Tebbets J, Zheng B, Feduska J, Crisan M, Péault B, Cummins J, Huard J. Isolation of a slowly adhering cell fraction containing stem cells from murine skeletal muscle by the preplate technique. *Nat Protoc.* 2008;3(9):1501–1509.
 23. Bai L, Li D, Li J, Luo Z, Yu S, Cao S, Shen L, Zuo Z, Ma X. Bioactive molecules derived from umbilical cord mesenchymal stem cells. *Acta Histochem.* 2016;118(8):761–769.
 24. Wang M, Yang Y, Yang D, Luo F, Liang W, Guo S, Xu J. The immunomodulatory activity of human umbilical cord blood-derived mesenchymal stem cells in vitro. *Immunology.* 2009;126(2):220–232.
 25. Kasper G, Mao L, Geissler S, Draycheva A, Trippens J, Kühnisch J, Tschirschmann M, Kaspar K, Perka C, Duda GN, Klose J. Insights into mesenchymal stem cell aging: involvement of antioxidant defense and actin cytoskeleton. *Stem Cells.* 2009;27(6):1288–1297.
 26. Park YB, Ha CW, Lee CH, Yoon YC, Park YG. Cartilage regeneration in osteoarthritic patients by a composite of allogeneic umbilical cord blood-derived mesenchymal stem cells and hyaluronate hydrogel: results from a clinical trial for safety and proof-of-concept with 7 years of extended follow-up. *Stem Cells Transl Med.* 2017;6(2):613–621.
 27. Amadori S, Torricelli P, Panzavolta S, Parrilli A, Fini M, Bigi A. Multi-layered scaffolds for osteochondral tissue engineering: in vitro response of co-cultured human mesenchymal stem cells. *Macromol Biosci.* 2015;15(11):1535–1545.
 28. Squadrito F, Bitto A, Altavilla D, Arcoraci V, De Caridi G, De Feo ME, Corrao S, Pallio G, Sterrantino C, Minutoli L, Saitta A, Vaccaro M, Cucinotta D. The effect of PDRN, an adenosine receptor A2A agonist, on the healing of chronic diabetic foot ulcers: results of a clinical trial. *J Clin Endocrinol Metab.* 2014;99(5):E746–E753.
 29. Veronesi F, Dallari D, Sabbioni G, Carubbi C, Martini L, Fini M. Polydeoxyribonucleotides (PDRNs) from skin to musculoskeletal tissue regeneration via adenosine A2A receptor involvement. *J Cell Physiol.* 2017;232(9):2299–2307.
 30. Altavilla D, Bitto A, Polito F, Marini H, Minutoli L, Di Stefano V, Irrera N, Cattarini G, Squadrito F. Polydeoxyribonucleotide (PDRN): a safe approach to induce therapeutic angiogenesis in peripheral artery occlusive disease and in diabetic foot ulcers. *Cardiovasc Hematol Agents Med Chem.* 2009;7(4):313–321.
 31. Sini P, Denti A, Cattarini G, Daglio M, Tira ME, Balduini C. Effect of polydeoxyribonucleotides on human fibroblasts in primary culture. *Cell Biochem Funct.* 1999;17(2):107–114.
 32. Rathbone MP, Middlemiss PJ, Gysbers JW, DeForge S, Costello P, Del Maestro RF. Purine nucleosides and nucleotides stimulate proliferation of a wide range of cell types. *In Vitro Cell Dev Biol.* 1992;28A(7–8):529–536.
 33. Rathbone MP, Deforge S, Deluca B, Gabel B, Laurensen C, Middlemiss P, Parkinson S. Purinergic stimulation of cell division and differentiation: mechanisms and pharmacological implications. *Med Hypotheses* 1992;37(4):213–219.
 34. Wang DJ, Huang NN, Heppel LA. Extracellular ATP shows synergistic enhancement of DNA synthesis when combined with agents that are active in wound healing or as neurotransmitters. *Biochem Biophys Res Commun.* 1990;166(1):251–258.
 35. Chung KI, Kim HK, Kim WS, Bae TH. The effects of polydeoxyribonucleotide on the survival of random pattern skin flaps in rats. *Arch Plast Surg.* 2013;40(3):181–186.
 36. Polito F, Bitto A, Galeano M, Irrera N, Marini H, Calò M, Squadrito F, Altavilla D. Polydeoxyribonucleotide restores blood flow in an experimental model of ischemic skin flaps. *J Vasc Surg.* 2012;55(2):479–488.
 37. Chavan AJ, Haley BE, Volkin DB, Marfia KE, Verticelli AM, Bruner MW, Draper JP, Burke CJ, Middaugh CR. Interaction of nucleotides with acidic fibroblast growth factor (FGF-1). *Biochemistry.* 1994;33(23):7193–7202.
 38. Valencia Mora M, Ruiz Ibán MA, Díaz Heredia J, Barco Laakso R, Cuéllar R, García Arranz M. Stem cell therapy in the management of shoulder rotator cuff disorders. *World J Stem Cells.* 2015;7(4):691–699.
 39. Beitzel K, McCarthy MB, Cote MP, Russell RP, Apostolakis J, Ramos DM, Kumbar SG, Imhoff AB, Arciero RA, Mazzocca AD. Properties of biologic scaffolds and their response to mesenchymal stem cells. *Arthroscopy.* 2014;30(3):289–298.
 40. Brown MN, Shiple BJ, Scarpone M. Regenerative approaches to tendon and ligament conditions. *Phys Med Rehabil Clin N Am.* 2016;27(4):941–984.
 41. Pan J, Liu GM, Ning LJ, Zhang Y, Luo JC, Huang FG, Qin TW. Rotator cuff repair using a decellularized tendon slices graft: an in vivo study in a rabbit model. *Knee Surg Sports Traumatol Arthrosc.* 2015;23(5):1524–1535.
 42. Keener JD, Galatz LM, Stobbs-Cucchi G, Patton R, Yamaguchi K. Rehabilitation following arthroscopic rotator cuff repair: a prospective randomized trial of immobilization compared with early motion. *J Bone Joint Surg Am.* 2014;96(1):11–19.
 43. Goutallier D, Postel JM, Gleyze P, Leguilloux P, Van Driessche S. Influence of cuff muscle fatty degeneration on anatomic and functional outcomes after simple suture of full-thickness tears. *J Shoulder Elbow Surg.* 2003;12(6):550–554.
 44. Rowshan K, Hadley S, Pham K, Caiozzo V, Lee TQ, Gupta R. Development of fatty atrophy after neurologic and rotator cuff injuries in an animal model of rotator cuff pathology. *J Bone Joint Surg Am.* 2010;92(13):2270–2278.
 45. Derwin KA, Baker AR, Iannotti JP, McCarron JA. Preclinical models for translating regenerative medicine therapies for rotator cuff repair. *Tissue Eng Part B Rev.* 2010;16(1):21–30.
 46. Quigley RJ, Gupta A, Oh JH, Chung KC, McGarry MH, Gupta R, Tibone JE, Lee TQ. Biomechanical comparison of single-row, double-row, and transosseous-equivalent repair techniques after healing in an animal rotator cuff tear model. *J Orthop Res.* 2013;31(8):1254–1260.