

## Unusual foreign object in a tooth: A case report and review of literature

Nawaf Mohammad Ashqar,<sup>1</sup>  
Fareedi Mukram Ali<sup>2</sup>

<sup>1</sup>Dental Intern, College of Dentistry;

<sup>2</sup>Department of Oral and Maxillofacial Surgery, College of Dentistry, Jazan University, Saudi Arabia

### Abstract

Foreign body impactions in the tooth are common findings in the oral cavity of children because of their frequent habits of placing various objects in their mouth. The present case describes an 11-year-old boy with a foreign object in the maxillary left first molar tooth of which he was unaware. Foreign objects can not only be a source of infection but also be aspirated or ingested by the child.

The discovery of foreign objects in the teeth is usually accidental. A detailed case history, consisting of a history of the ordinary placement of the object and clinical and radiographic examinations is necessary to determine the nature, size, and location of the foreign body, as well as the difficulty involved in its retrieval. The foreign object may sometimes fracture inside the tooth during exploration by the parent or child. Such an object may act as a potential source of infection and lead to complications.

### Introduction

Accidental ingestion of foreign bodies is an emergency condition in pediatric patients. Such accidents cause panic to both children and their parents. Children tend to ingest toys, marbles, coins, keys, and pins. However, insertion of a foreign body into the teeth by children is fairly uncommon.<sup>1</sup>

Open carious teeth in the oral cavity act as sites for insertion of foreign bodies, leading to pain, swelling, and abscess formation. Proper history, detailed clinical examination, and radiographs are necessary to detect the cause and give an appropriate diagnosis. A radiograph is also necessary to detect the correct size, type, and position of the foreign object.<sup>2</sup>

A foreign object is extremely dangerous to the patient due to the possibility of its ingestion and causing further complications. Herein, we present a case report of a foreign object inside a tooth.

### Case Report

An 11-year-old boy reported to the department with a main complaint of carious tooth in the upper left posterior region of jaw. On clinical examination, the permanent maxillary left first molar was found to be grossly carious. Surprisingly a foreign object was also embedded in the carious part of this tooth (Figure 1). The patient was completely unaware of this object. On thorough examination, the object was found to be a small screw that was tightly embedded in the grossly carious tooth. Orthopantomogram (Figure 2) and Intra-oral peri-apical radiographs (Figure 3) were taken to locate the exact position of the screw. After further examination, the foreign object was removed (Figure 4) from the carious tooth, and the tooth was subjected to further treatment, including root canal treatment (Figure 5). The consulted pedodontist confirmed that the tooth required apexification with Metapaste (calcium hydroxide + barium sulfate), which has shown a promising success rate in multiple reported similar cases.<sup>3</sup>

### Discussion

Children have a predisposition to put objects into their oral cavity. These objects can cause accidental ingestion or aspiration, resulting in difficulty for parents. If the objects are sharp or pointed, they may cause further danger even during their removal by

Correspondence: Nawaf Mohammad Ashqar, Dental Intern, College of Dentistry, Jazan University, Saudi Arabia.  
E-mail: nawaf6679@gmail.com

Key words: Foreign body; Tooth; Children; Permanent tooth.

Contributions: NMF: diagnosis and treatment of the case; FMA: guidance and supervision.

Conflict of interest: the authors declare no potential conflict of interest.

Funding: none.

Received for publication: 10 November 2018.

Revision received: 15 January 2019.

Accepted for publication: 19 January 2019.

This work is licensed under a Creative Commons Attribution NonCommercial 4.0 License (CC BY-NC 4.0).

©Copyright N.M.Ashqar and F.M. Ali, 2019  
Licensee PAGEPress, Italy  
Clinics and Practice 2019; 9:1114  
doi:10.4081/cp.2019.1114

endoscopic means. Rupture of the common carotid artery, esophageal tears and fistula, aortic pseudo-aneurysms, pericarditis and cardiac tamponade, all of which are very serious complications, have been reported.<sup>2,4</sup> Foreign bodies inside the tooth may act as a cause of infection and result in pain, bleeding, and swelling. Placement of jewelry into a maxillary central incisor resulting

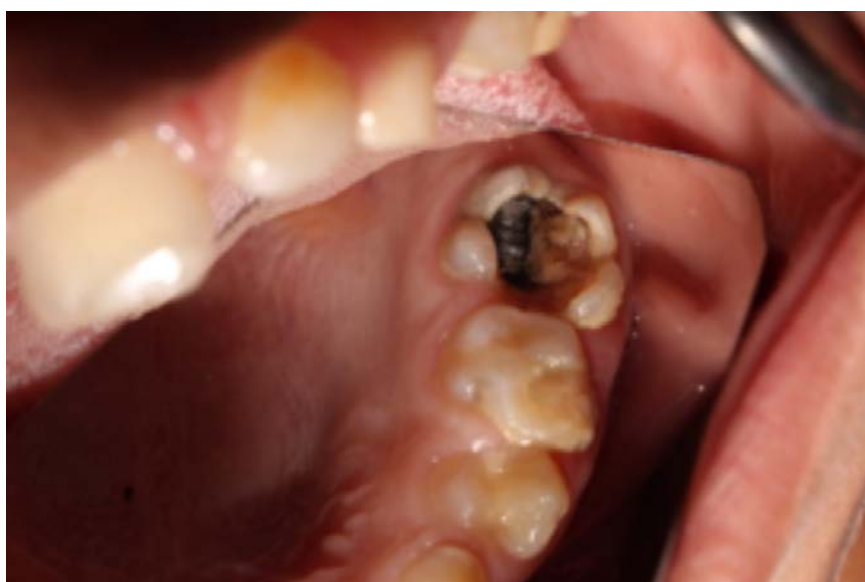

Figure 1. Clinical intraoral photograph of a patient showing an embedded foreign body in the permanent maxillary first molar.

in actinomycosis has been reported.<sup>5</sup> Grossman,<sup>6</sup> Gelfman,<sup>7</sup> and Harris<sup>8</sup> reported retrieval of indelible ink pencil tips, brads, a tooth pick, a pencil tip, adsorbent points, tomato seed, pins, wooden toothpick, plastic objects, toothbrush bristles and crayons from the root canals of anterior teeth left open for drainage.

McAuliffe *et al.*<sup>9</sup> reported five radiographic methods to localize a metallic foreign body in the oral cavity:

- i) Parallax views (either horizontal or vertical);
- ii) Vertex-occlusal views;
- iii) Triangulation techniques;
- iv) Stereo radiography;
- v) Tomography.

Various foreign objects have been reported to be lodged in teeth. Toida reported a plastic chopstick embedded in an unerupted supernumerary tooth in the premaxillary region of a 12-year-old Japanese

boy.<sup>10</sup> Zillich and Pickens and Turner cited cases where hat pins and dressmaker pins that were used to remove the food plugs from the root canals of maxillary and mandibular incisors undergoing endodontic treatment had eventually fractured inside the root canals of these teeth.<sup>7,12,13</sup>

Foreign bodies may be ingested, inserted into a body cavity, or deposited into the body by a traumatic or iatrogenic injury. Most foreign bodies cause abscess formation, septicemia, or lead to severe hemorrhage; they can also undergo distant embolization. Foreign bodies and tissue reactions to foreign materials are commonly encountered in the oral cavity. The more common iatrogenic lesions include apical deposition of endodontic materials, mucosal amalgam and graphite tattoos, myospherulosis, oil granulomas, and traumatically introduced dental materials and instruments.<sup>13,14</sup>

The likelihood of these foreign objects becoming impacted into the tooth is greater when the pulp chamber is open either because of traumatic injury or due to a large carious exposure. Retrieval of foreign objects from the teeth of children is a challenging aspect of pediatric dental practice. These objects can be easily retrieved if they are located within the pulp chamber; once the object has been pushed apically, however, their retrieval may be complicated.<sup>14</sup>

A conventional practice employed during emergency root canal treatment involves leaving the pulp chamber open where pus continues to discharge through the canal and cannot be dried within a reasonable period of time. Weine<sup>15</sup> recommends that the patient remain in the office with a draining tooth for at least an hour and finally ending the appointment by sealing the access cavity. With the access cavity closed, no new strains of microorganisms

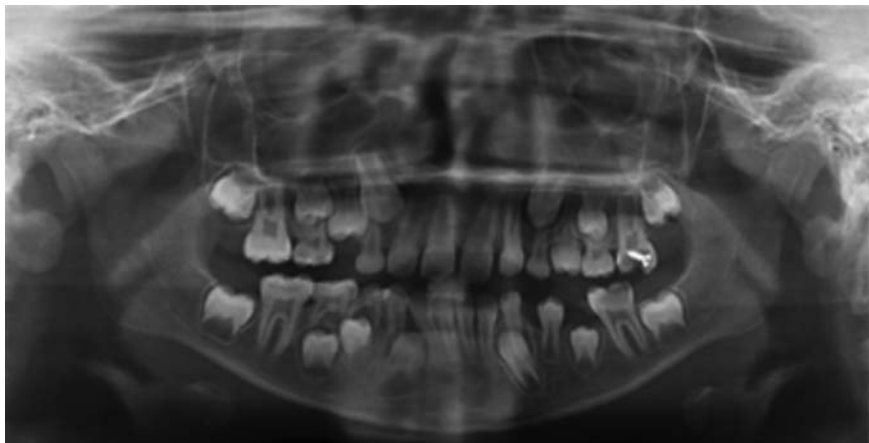


Figure 2. Orthopantomogram showing a well-defined radiopaque foreign object in the tooth.

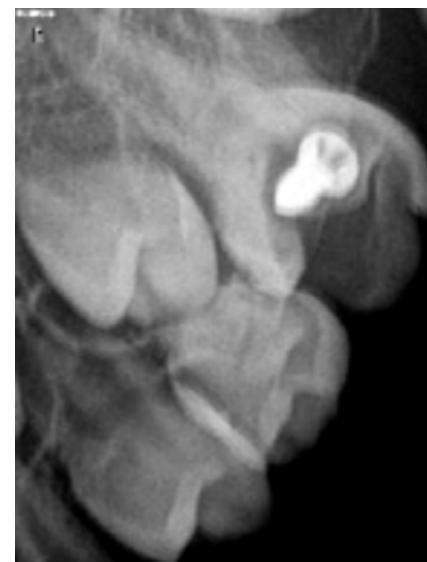

Figure 3. Intra-oral peri-apical radiograph showing a cylindrical foreign object packed tightly in the tooth.



Figure 4. Image showing that the retrieved foreign body is a small screw.

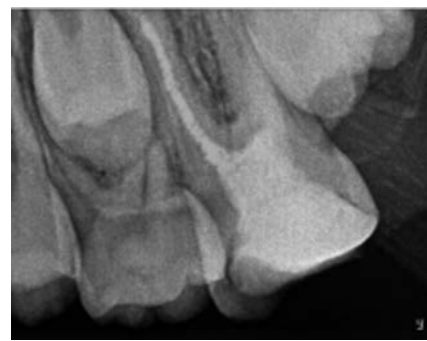

Figure 5. IOPA showing the tooth after treatment.

are introduced to the tooth, and food debris and foreign body lodgment within the tooth can be avoided. These foreign objects become a potent focus of infection. Actinomycosis following placement of a piece of jewelry into a maxillary central incisor has been reported. Foreign bodies pushed through a root canal into the sinus are one of the causes of chronic maxillary sinusitis of dental origin.<sup>16</sup>

Timely diagnosis and management of foreign objects embedded in the tooth should be done as early as possible to avoid complications. Advising parents to keep small objects out of reach of children can do prevent such emergencies. Pediatricians should also warn the parents that children may try to put small objects inside their open carious teeth. Thus, management of open carious lesions should be done as early as possible to avoid further complications. Parents should also be instructed to maintain a non-judgmental and non-authoritarian approach when handling children so that the latter will not be afraid to discuss their problems with their parents. Written warnings by manufacturing companies should repeat this message.<sup>2</sup>

Children present with foreign body in their teeth found frequently to be from 2 years to 20 years old. The deciduous and permanent teeth were found to be equally affected.

Maxillary central incisors were found to be the most commonly involved tooth, and the most commonly found foreign object is stapler pins. Screws as a foreign body have been reported in three cases.

The most important factor in retrieving foreign objectives and fracture instruments is the location of the fragment and its relationship with the curvature of the canal. When the fragment is positioned coronally

to the curvature of the canal, the possibility of removing the fragment increases. However, when the fragment is situated at or beyond the curvature of the canal, the possibility of removing the fragment fairly low or even impossible.<sup>16</sup>

## Conclusions

While the presence of foreign objects retrieved from the root canals and pulp chambers of permanent teeth have been reported, the presence of foreign objects found in permanent teeth is uncommon. Diagnosis of such cases should be based on thorough history recording, good clinical examination and proper imaging of suspected area.

## References

- Rathore K. Endodontic management of foreign body in root canal of 10 year child: a case report. *Saudi J Oral Dent Res* 2017;2:163-7.
- Palit MC, Agrawal J, Saha S. Radiographic revelation of foreign body in primary tooth: a rare case report. *J Dent App* 2015;2:251-3.
- Maggi Maia Silveira C, Cilene Nass Sebrão C, Soares Reis Vilanova L, Sánchez-Ayala A. Apexification of an immature permanent incisor with the use of calcium hydroxide: 16-year follow-up of a case. *Case Rep Dent* 2015;ID984590. Available from: <https://doi.org/10.1155/2015/984590>.
- Sharmin DD, Sistla S, Gunasekaran R. Unusual foreign objects in the teeth – a case report. *J Dent Oral Disorder Ther* 2017;5:1-2.
- Goldstein BH, Sciubba JJ, Laskin DM. Actinomycosis of the maxilla: Review of literature and report of case. *J Oral Surg* 1972;30:362-6.
- Grossman JL, Heaton JF. Endodontic case reports. *Dent Clin North Am* 1974;18:509-27.
- Zillich RM, Pickens TN. Patient-included blockage of the root canal. Report of a case. *Oral Surg Oral Med Oral Pathol* 1982;54:689-90.
- Harris WE. Foreign bodies in root canals: Report of two cases. *J Am Dent Assoc* 1972;85:906-11.
- MacAuliffe N, Drage NA, Hunter B. Staple diet: a foreign body in a tooth. *Int J Paediatr Dent* 2005;15:468-71.
- Toida M, Ichihara H, Okutomi T, et al. An unusual foreign body in an unerupted supernumerary tooth. *Br Dent J* 1992;173:345-6.
- Turner CH. An unusual foreign body. *Oral Surg Oral Med Oral Pathol* 1983;56:226.
- Johny J. Screw impacted in a deciduous tooth. research & reviews. *J Dent Sci* 2016;4:54-7.
- Kanumuri PK, Gantha SN, Animireddy D, Chinta M. Unusual foreign body in primary tooth. *BMJ Case Rep* 2016. pii: bcr2016216326. doi: 10.1136/bcr-2016-216326
- Passi S, Sharma N. Unusual foreign bodies in the orofacial region. *Case Rep Dent* 2012;1-4.
- Weine FS. *Endodontic therapy*. 6 th ed. Australia: Mosby; 2004.
- Alrahabi M, Gabban H. Management of foreign object in the root canal of central incisor tooth. *Saudi Endod J* 2014;4:154-7.