

## CLINICAL REVIEW

# Cytologic diagnosis of parotid gland Warthin tumor: Systematic review and meta-analysis

Roie Fisher BSc<sup>1</sup> | Ohad Ronen MD<sup>1,2</sup>

<sup>1</sup>Azrieli Faculty of Medicine, Bar-Ilan University, Safed, Israel

<sup>2</sup>Department of Otolaryngology – Head and Neck Surgery, Galilee Medical Center, Nahariya, Israel

**Correspondence**

Ohad Ronen, Department of Otolaryngology – Head and Neck Surgery, Galilee Medical Center, POB 21, Nahariya 2210001, Israel.  
Email: [ohadr@gmc.gov.il](mailto:ohadr@gmc.gov.il)

**Abstract**

It is important to define the accuracy of fine-needle aspiration cytology (FNAC) in the diagnosis of Warthin tumor (WT). This systematic review and meta-analysis evaluated the accuracy of FNAC in the diagnosis of WT in the parotid gland and WT growth rate. For determination of FNAC accuracy, 17 studies, encompassing 1710 cases, were included. Pooled random model estimates of sensitivity, specificity, PPV, and NPV were 93.7% (95%CI: 92.1, 95.3), 97.9% (95%CI: 97, 98.9), 93.3% (95%CI: 91.5, 95.1), and 97.4% (95%CI: 96.4, 98.4), respectively. FNAC is highly reliable for the diagnosis of WT of the parotid. The high PPV value suggests that patients with a cytological diagnosis of WT of the parotid may be assigned to active surveillance.

**KEYWORDS**

diagnosis, fine-needle aspiration, parotid gland, Warthin tumor

## 1 | INTRODUCTION

Warthin tumor (WT), also known as papillary cystadenoma lymphomatosum or adenolymphoma, is a benign neoplasm that arises almost exclusively in the parotid gland, which is the origin of most salivary gland tumors. It comprises 15% of all parotid tumors and is the second most frequent neoplasm in the parotid gland, after pleomorphic adenoma.<sup>1–3</sup> WT is more common in Caucasians in the 6th and 7th decades of life, smokers, and males, although a narrowing of the gender gap has recently been observed, likely due to increased smoking among women.<sup>3</sup> Several etiological factors have been suggested,

including Epstein Barr virus (EBV) infection, autoimmune diseases, radiation, chronic inflammation, and most importantly, cigarette smoking.<sup>1,2</sup> In the last few years, there has been an increased trend in the diagnosis of WT in comparison to other parotid tumors; in some studies, WT was found to be more common than pleomorphic adenoma. One study showed that this trend cannot be explained by changes in smoking patterns.<sup>4–6</sup> The same study suggested metabolic syndrome and obesity as two central risk factors.<sup>6</sup> The typical clinical manifestation of WT is a painless firm swelling in the upper neck, but some cases will be asymptomatic, and others will show symptoms of facial nerve branch irritation, ear pain, tinnitus, and hearing impairment.<sup>2</sup> In general, WT grows slowly, and malignant transformations are rare, occurring at a rate of less than 0.1%.<sup>3</sup> The malignant transformation can arise from the epithelial or lymphoid cells of WT.<sup>7,8</sup> Synchronous or metachronous tumors,

**Abbreviations:** FN, false negative; FNAC, fine-needle aspiration cytology; FP, false positive; NPV, negative predictive value; PPV, positive predictive value; TN, true negative; TP, true positives; WT, Warthin tumor.

This is an open access article under the terms of the [Creative Commons Attribution-NonCommercial-NoDerivs](https://creativecommons.org/licenses/by-nc-nd/4.0/) License, which permits use and distribution in any medium, provided the original work is properly cited, the use is non-commercial and no modifications or adaptations are made.

© 2022 The Authors. *Head & Neck* published by Wiley Periodicals LLC.

some of which are malignant, in proximity to WT of the parotid, occur rarely.<sup>9</sup> Preoperative assessment of WT with fine-needle aspiration (FNA) cytological analysis (FNAC) typically identifies a combination of necrotic debris, lymphocytes, and oncocytic epithelial clusters.<sup>10–12</sup>

Despite the reports of slow growth, some studies reported on cases in which WT doubled in size within 1 year.<sup>13–15</sup> It is therefore of prime importance to identify the patients at risk of rapid WT growth. However, the literature is scarce and does not include important demographics and clinical data.<sup>13–15</sup> Several studies evaluated the performance of FNA for the diagnosis of WT but showed considerably conflicting results. So et al. reported on 95.8% sensitivity and 97.2% positive predictive value (PPV), and Viguer et al. reported on 90.4% and 98.1%, respectively, whereas other studies demonstrated a rate of false diagnosis of about 25%–40%.<sup>16–19</sup>

This systematic review and meta-analysis considered publications that include a comparison between preoperative FNAC (index test) and postsurgical histopathological diagnosis (reference test) of WT in the parotid gland. In addition, the mean growth rate of the tumor as measured by imaging modalities was calculated.

## 2 | METHODS

### 2.1 | Search strategy

This systemic review and meta-analysis followed the referred Reporting Items for Systematic Reviews and Meta-Analyses (PRISMA) extension for diagnostic test accuracy guidelines.<sup>20</sup> A comprehensive search of PubMed and Scopus was conducted on July 25, 2021 to identify relevant publications. The search terms used were “fine needle aspiration” OR “fine needle sampling” OR “FNA,” AND “Warthin tumor” OR “adenolymphoma” OR “parotid” AND “tumor” OR “neoplasm” OR “mass” as well as “growth rate.” No date restriction was applied. To expand the search, “similar articles” function in PubMed and “related articles” function in Google Scholar were used. In addition, the reference list of selected articles was screened.

### 2.2 | Eligibility criteria

Articles that used FNAC for the diagnosis of a parotid gland lesion and histopathological assessment for a final postoperative diagnosis were included. Cases with a non-diagnostic FNAC result were not included for the

assessment of FNAC accuracy. Case reports, letters, or comments to the authors, article not in English, and cases or articles that did not address WT were excluded. To calculate WT growth rate, we included articles that diagnosed WT using histopathology or cytology. WT size evaluations were based on articles reporting on CT- or MRI-based tumor size evaluation at least twice with a minimum time interval of 3 months, a measured dimension, and which mention follow-up duration. If more than two size evaluations were available, only the first and the last were included. In cases where several articles used the same database in overlapping years, only the most recent published article was included to avoid data duplication.

### 2.3 | Data extraction, processing, and synthesis

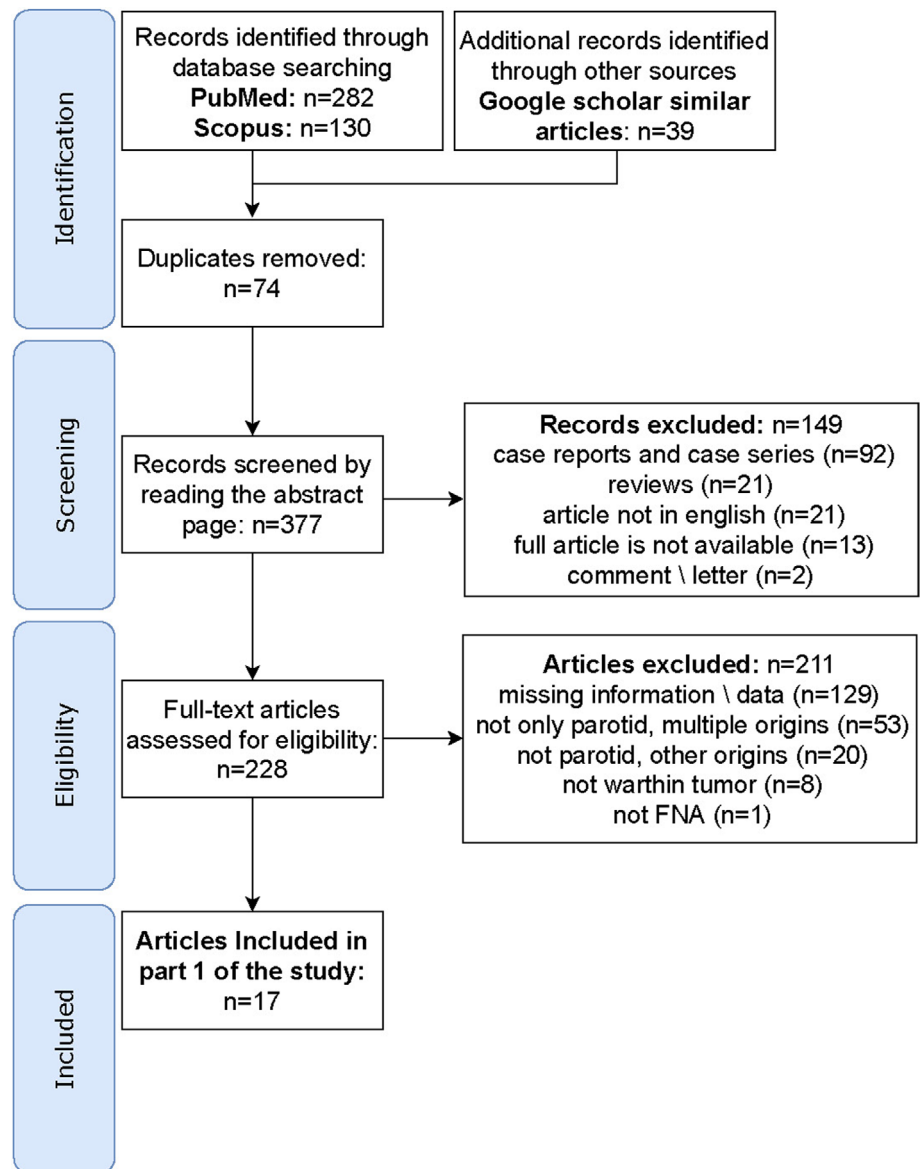
The following data were extracted for each case: method of needle guidance, needle size, patient characteristics, the time (years) range of the data, FNAC diagnosis, and final histopathological diagnosis. Data regarding follow-up duration for each lesion, imaging modality used, and initial and final size of WT were also extracted.

The following parameters were calculated: *true positives (TP)*: FNAC and histopathological diagnosis is WT; *false positive (FP)*: FNAC result is WT, but histopathological diagnosis is not; *false negative (FN)*: FNAC result is a different lesion (not WT), but histopathological result is WT; *true negative (TN)*: both FNAC and histopathology results are not WT. Our goal was to conduct meta-analysis of individual FNAC estimates in the diagnosis of WT; for this reason, all the included studies contain cases of FP, FN, and TP and some studies also contain TN cases. Studies that lack case of FP, FN, or TP were excluded. All the false positive and false negative results were classified as malignant, benign, or normal. Cytodiagnostic or histopathologic results that were classified as “probably malignant,” “suspected malignant,” “suspicious for malignancy,” “cannot exclude malignancy” were included in the malignant group.

### 2.4 | Quality assessment

The included studies were assessed for quality of methodology based on the Diagnostic Accuracy Research Quality Assessment-2 (QUADAS-2) tool.<sup>21</sup> The risk of bias was rated as “low,” “high,” or “unclear,” corresponding to a score of “2,” “1,” and “0,”

**FIGURE 1** Flow diagram for identification of studies for assessment of fine-needle aspiration cytology accuracy in diagnosing Warthin tumor in the parotid gland [Color figure can be viewed at [wileyonlinelibrary.com](http://wileyonlinelibrary.com)]



respectively. A study awarded a cumulative score  $\geq 6$  was considered of high quality.

## 2.5 | Statistical analysis

IBM SPSS Statistics for Windows, Version 27.0 was used for data analysis. R software and related packages were used for the meta-analysis. The pooled sensitivity, specificity, PPV, and NPV were calculated to assess the diagnostic value of FNAC. Mean percent diameter change for the entire population and percent diameter change for subgroups were calculated to assess WT growth rate. Dependent variables were assessed for normality using the Kolmogorov–Smirnov test and by graphically comparing frequencies distribution to bell shape. The *T* test was used to compare the means of subgroups; *p*-value

$<0.05$  was considered statistically significant. Between-study heterogeneity was evaluated using the Cochran *Q* test and the Higgins *I* square test, where  $I^2 > 50\%$  indicates statistically significant heterogeneity. Random and fixed models were used for pooled estimates. Publication bias was evaluated by visual inspection of the symmetry of the funnel plot.

## 3 | RESULTS

The literature search yielded 451 records, of which 17 articles met the inclusion criteria (Figure 1). Table 1 presents key study design elements of all the included articles. The reports were published between 1996 and 2019, conducted in 12 countries, and encompassed a total of 1710 cases, with study samples sizes ranging between 5 and

TABLE 1 Summary of studies reviewed to determine fine-needle aspiration cytology accuracy

Article, year published	Years range	Location	Study design	Needle type	Needle guidance	Age (range)	Males
Al-Khafaji et al. <sup>27</sup>	1986–1996	USA	Retrospective	N/A	N/A	Mean: 56 (5–90)	50.6%
Altin et al. <sup>16</sup>	2008–2017	Turkey	Retrospective	23 G	N/A	Mean: 47.5 (7–82)	54.6%
Atula et al. <sup>28</sup>	1984–1991	Finland	Retrospective	23 G	N/A	Unknown	Unknown
Edizer et al. <sup>29</sup>	2005–2013	Turkey	Retrospective	23 or 25 G	US	Unknown	Unknown
Huang et al. <sup>30</sup>	N/A	Taiwan	Retrospective	N/A	US	Unknown	Unknown
Jafari et al. <sup>31</sup>	2000–2006	France	Retrospective	27 G	US or palpation	Mean: 50.5 (17–87)	60%
Jayaram et al. <sup>32</sup>	N/A	Malaysia	Retrospective	22 G	N/A	Unknown	Unknown
Jechova et al. <sup>33</sup>	2006–2016	Czechia	Retrospective	N/A	US	Median: 57 (12–96)	42.6%
Raymond et al. <sup>34</sup>	1992–2000	Canada	Retrospective	N/A	N/A	Mean: 60.2 (14–88)	1.4:1
So et al. <sup>18</sup>	2006–2017	Canada	Retrospective	N/A	N/A	Mean: 63.2 (SD 10.4)	Unknown
Suzuki et al. <sup>35</sup>	1999–2017	Japan	Retrospective	21 or 22 G	US or free hand technique	Unknown	Unknown
Zabren et al. <sup>19</sup>	1990–1998	Switzerland	Retrospective	22 G	N/A	Mean: 55 (16–97)	46%
Akbas et al. <sup>36</sup>	1994–2000	Turkey	Retrospective	25 G	US	Unknown	Unknown
Behzatoglu et al. <sup>37</sup>	1997–2002	Turkey	Retrospective	22 G	N/A	Mean: 44 (12–80)	54.6%
Ali et al. <sup>38</sup>	2002–2010	Pakistan	Retrospective	22 G	Free hand technique	Mean: 44 (15–78)	56.5%
Riley et al. <sup>39</sup>	1996–2000	New Zealand	Retrospective	24 G	N/A	Unknown	Unknown
Weinberger et al. <sup>40</sup>	1985–1989	USA	Retrospective	22 G	Free hand technique	Mean: 57 (SD 12.9)	77.7%

Abbreviations: N/A, not available; US, ultrasound.

TABLE 2 Summary of the fine-needle aspiration accuracy analysis

Article	NPV	PPV	Specificity	Sensitivity	TN	FN	FP	TP
Al-Khafaji et al. <sup>27</sup>	97.7	83.3	97.7	83.3	129	3	3	15
Altin et al. <sup>16</sup>	93.3	78.6	93.8	71.7	137	13	9	33
Atula et al. <sup>28</sup>		68.3		87.5		13	4	28
Edizer et al. <sup>29</sup>		93.0		95.2		3	2	40
Huang et al. <sup>30</sup>	78.3	74.2	90.6	88.5	29	8	3	23
Jafari et al. <sup>31</sup>	100	91.7	96.7	100	59	0	2	22
Jayaram et al. <sup>32</sup>		100.0		80.0		1	0	4
Jechova et al. <sup>33</sup>		93.1		96.6		7	15	201
Raymond et al. <sup>34</sup>		89.2		89.2		4	4	33
So et al. <sup>18</sup>		97.2		95.8		3	2	69
Suzuki et al. <sup>35</sup>		94.5		92.6		11	8	137
Zbaren et al. <sup>19</sup>	91.2	84.4	97	62.8	167	15	5	27
Akbas et al. <sup>36</sup>	100	94.7	98.4	100.0	62	0	1	18
Behzatoglu et al. <sup>37</sup>	98.4	100	100	75.0	63	1	0	3
Ali et al. <sup>38</sup>	98.2	90.0	99.1	81.8	111	2	1	9
Riley et al. <sup>39</sup>	95.7	66.7	97.8	50.0	90	4	2	4
Weinberger et al. <sup>40</sup>	90.4	60.0	95	42.9	38	4	2	3
Total (1710 cases)					885	93	63	669
Pooled value [95% CI]								
Random effects model					97.4 [96.4, 98.4]	93.3 [91.5, 95.2]	97.9 [97.0, 98.9]	93.7 [92.1, 95.3]
Fixed effect model					94.0 [92.1, 95.8]	86.6 [81.8, 91.4]	96.5 [95.0, 98.0]	79.5 [74.4, 84.6]

Abbreviations: FN, false negative; FP, false positive; NPV, negative predictive value; PPV, positive predictive value; TN, true negative, TP, true positive.

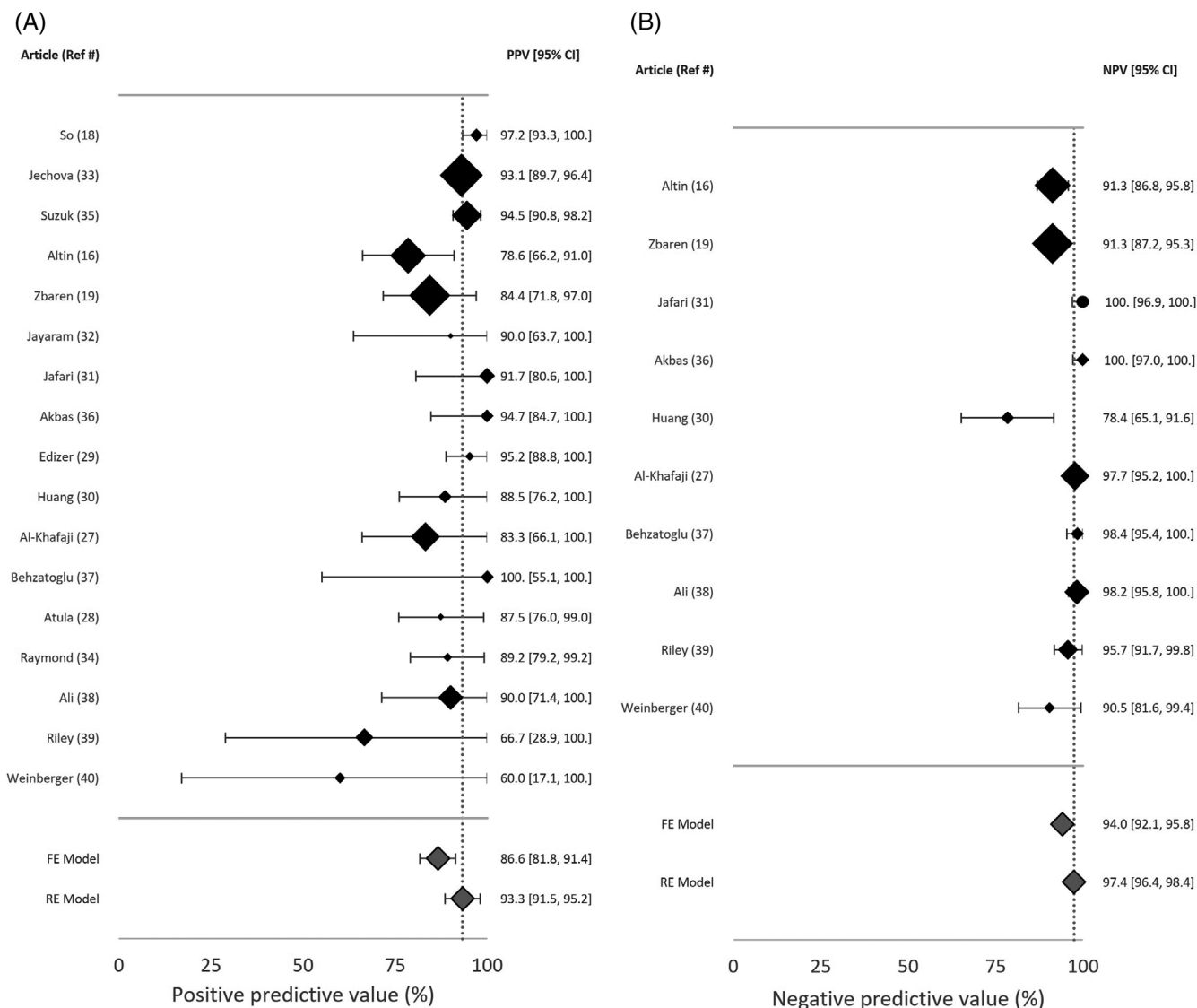


FIGURE 2 Forest plot of (A) positive predictive value (PPV) and (B) negative predictive value (NPV). Dashed line depicts value of random model estimate. FE, fixed model estimate; RE, random model estimate

223 cases. Needle type and needle guidance technique were mentioned occasionally, patient sex was reported in 9 studies, and patient age was reported in 10 studies. The years range of presented data was unavailable for two articles. All the studies were retrospective and involved a medical records database search.

In seven studies, the TN rate was not reported, as the publication focused on evaluation of the concordance between FNA and histopathology in the diagnosis of WT. Study data, individual diagnostic estimates and pooled estimates are summarized in Table 2. Individual and pooled estimates are also presented in a forest plot in Figures 2 and 3. The pooled sensitivity and PPV were calculated based on cases from 17 studies. The random effects model of the 17 studies showed a pooled sensitivity of 93.7% (95%CI: 92.1,

95.3) and pooled PPV of 93.3% (95%CI: 91.5, 95.2). Pooled specificity and NPV were calculated based on the 10 studies in which TN data were reported. The random effects model of these 10 studies showed a pooled specificity of 97.9% (95%CI: 97, 98.9) and a pooled NPV of 97.4% (95%CI: 96.4, 98.4). Heterogeneity assessments showed that PPV and specificity estimates were homogenous ( $Q = 20.2, p = 0.210, I^2 = 20.8$  for PPV, and  $Q = 10.9, p = 0.282, I^2 = 17.4\%$  for specificity). NPV and sensitivity estimates were found to be heterogenous ( $Q = 74.3, p < 0.0001, I^2 = 78.5\%$  for sensitivity, and  $Q = 32.3, p = 0.0002, I^2 = 72.1\%$  for NPV). Visual assessment of the funnel plots for each of the four FNAC estimates showed no asymmetrical distribution (Figure 4). All included studies were of high quality (Figure 5).

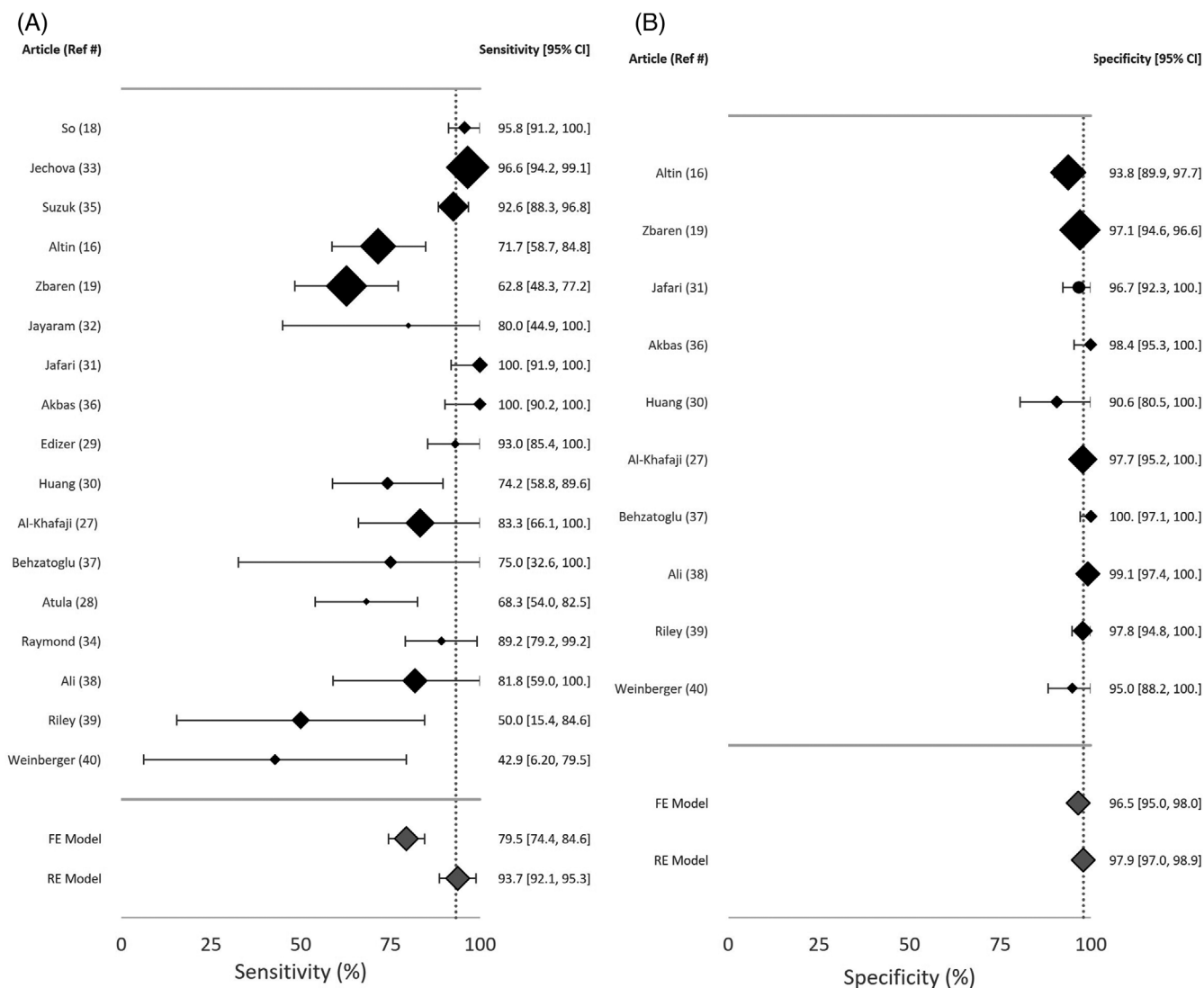


FIGURE 3 Forest plot of (A) sensitivity and (B) specificity. Dashed line depicts value of random model estimate. FE, fixed model estimate; RE, random model estimate

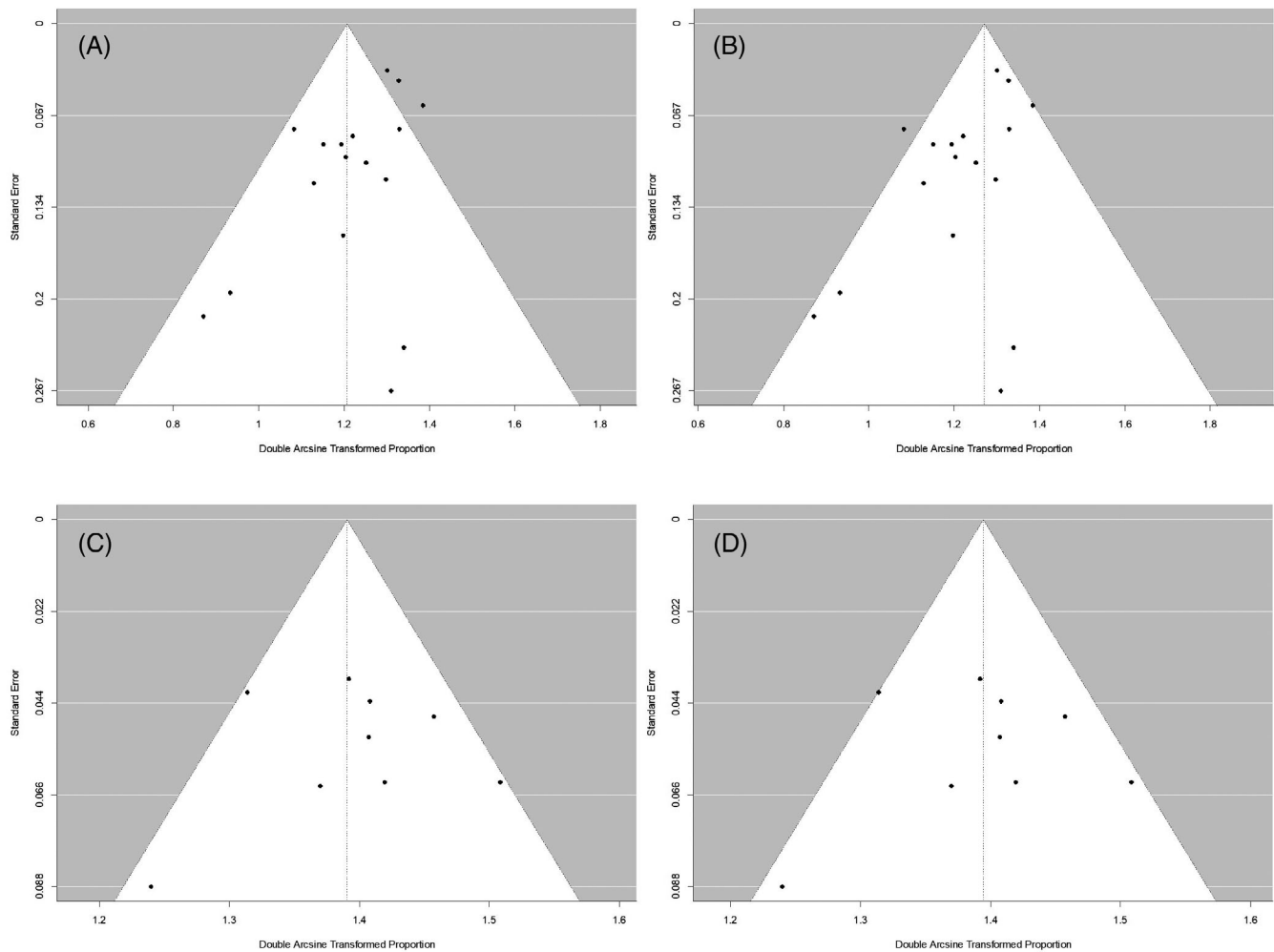
A summary of all cases falsely diagnosed by FNAC is presented in Figure 6. The total FP rate was 3.6% (63 out of 1710 patients), and the FP rate of malignant tumors was 2% (35 out of 1710 patients). When considering all positive FNAC results ( $n = 732$ ), the rate of malignant FP was 4.7% (35 out of 732 patients). Most of the cases in the FP category were classified as malignant (55.5%,  $n = 35$ ), and the leading FP diagnosis was adenoid cystic carcinoma ( $n = 12$ ), followed by mucoepidermoid carcinoma ( $n = 11$ ). The total FN rate was 5.4% (93 out of 1710 patients); 21 (22.5%) were classified as malignant.

#### 4 | DISCUSSION

This systematic review and meta-analysis evaluated the accuracy of FNAC in the diagnosis of WT and

investigated WT growth rate. The study found FNAC to have a high specificity (97.9% [95%CI: 97, 98.9]), and PPV (93.3% [95%CI: 91.5, 95.1]), yet a variable sensitivity (93.7% [95%CI: 92.1, 95.3]) and NPV (97.4% [95%CI: 96.4, 98.4]). Although FNAC is highly specific in the diagnosis of WT, the review found that 35/732 (4.7%) positive results proved malignant is postoperative histopathology, hence, patients choosing an observational approach based on preoperative FNAC WT diagnosis should be followed up with caution. False FNAC results involving WT is a well-known phenomenon.<sup>22</sup> The falsely diagnosed FNAC cases may be the result of sampling error, when WT cysts with acellular fluid are sampled.<sup>12</sup> In addition, WT oncocytes tend to undergo necrosis and to change to squamous or mucinous epithelium which may lead to diagnosis of a malignant tumor.<sup>12</sup> WT necrosis can also cause cyst spillage and subsequent inflammation





**FIGURE 4** Funnel plots for assessment of publication bias. Each point represents a separate study. (A) PPV, (B) sensitivity, (C) specificity, (D) NPV. Horizontal axis represents the effect of the studies, vertical axis represents study size, vertical dashed line indicates effect summary, white triangle shape depicts the values extending 1.96 standard errors around the effect summary, this area should include 95% of studies. Studies with a larger sample size and hence, higher precision, are located at the top, studies with higher estimates are located at the right. When publication bias occurs, one expects asymmetry in the scatter around the effect summary, with more studies showing a positive as opposed to a negative result. NPV, negative predictive value

and reactive changes, thus challenging cytodiagnostics.<sup>10</sup> Other sources of sampling errors are mixed tumors of WT and synchronous benign and malignant lesions.<sup>9</sup> Both FN and FP cases may harbor malignant tumors and should raise concern of progression of malignant disease. Yet, characteristics of these cases were not available for review; thus, future research is warranted to identify the features of falsely diagnosed cases. When considering the overall high PPV, a positive diagnosis of WT by FNAC can be a reasonable option in selected cases with close follow-up.

The cited malignant transformation rate of WT tumors diagnosed by histopathology is 0.1%.<sup>3</sup> Yet, in the case of FNAC diagnosis, false results are mostly due to a sampling error. Although malignant transformation can contribute to lead to a false diagnosis, we think it has a

small effect overall. Additionally, cases of malignant transformation were not included in the review, and this subject is beyond the scope of the current study.

We chose not to present data regarding WT growth rate in this review. The data obtained in appraised publications were very heterogeneous. Moreover, factors influencing growth are many and unknown, all of which may lead to imprecise results. We suggest that future studies conduct more comprehensive, three-dimensional size assessments of WT.

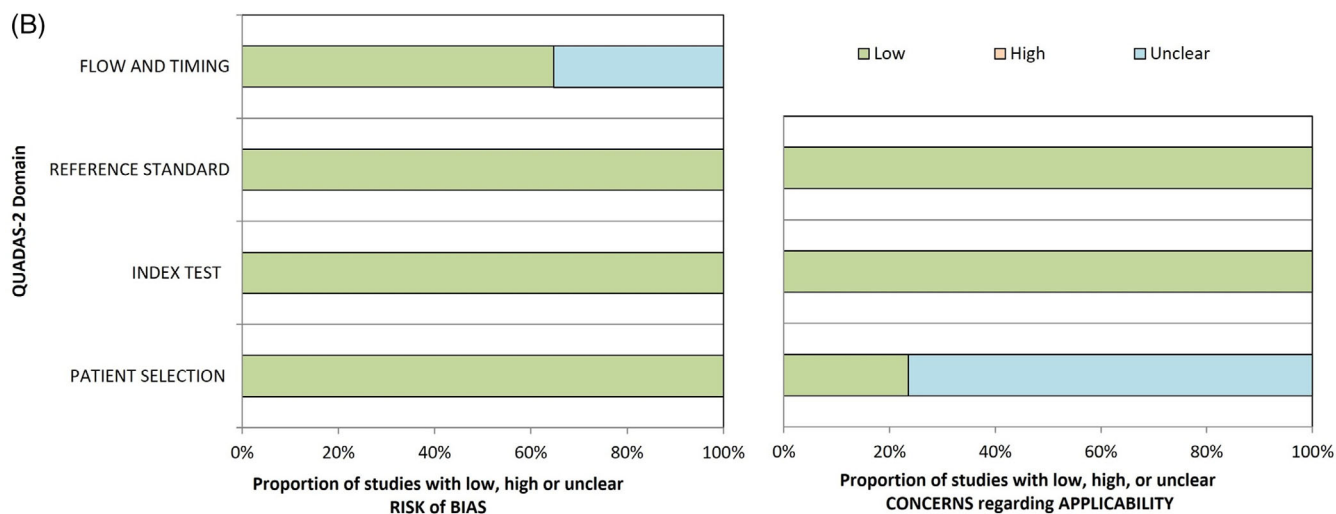
## 5 | LIMITATION

This review had several limitations. Articles reviewed to determine FNA accuracy were retrospective in nature,

(A)

Study	RISK OF BIAS				APPLICABILITY CONCERNS		
	PATIENT SELECTION	INDEX TEST	REFERENCE STANDARD	FLOW AND TIMING	PATIENT SELECTION	INDEX TEST	REFERENCE STANDARD
Al-Khafaji, 1998 <sup>21</sup>	+	+	+	+	+	+	+
Altin, 2019 <sup>22</sup>	+	+	+	+	?	+	+
Atula, 1996 <sup>23</sup>	+	+	+	+	?	+	+
Edizer, 2016 <sup>24</sup>	+	+	+	?	?	+	+
Huang, 2012 <sup>25</sup>	+	+	+	+	?	+	+
Jafari, 2009 <sup>26</sup>	+	+	+	?	+	+	+
Jayaram, 1994 <sup>27</sup>	+	+	+	?	?	+	+
Jechova, 2019 <sup>28</sup>	+	+	+	+	?	+	+
Raymond, 2002 <sup>29</sup>	+	+	+	+	?	+	+
So, 2019 <sup>18</sup>	+	+	+	+	?	+	+
Suzuki, 2019 <sup>30</sup>	+	+	+	?	?	+	+
Zbaren, 2001 <sup>31</sup>	+	+	+	+	?	+	+
Akbas, 2004 <sup>32</sup>	+	+	+	?	?	+	+
Behzatoglu, 2004 <sup>33</sup>	+	+	+	+	?	+	+
Ali, 2011 <sup>34</sup>	+	+	+	+	?	+	+
Riley, 2005 <sup>35</sup>	+	+	+	+	+	+	+
Weinberger, 1992 <sup>36</sup>	+	+	+	+	+	+	+

+ Low Risk     
 - High Risk     
 ? Unclear Risk

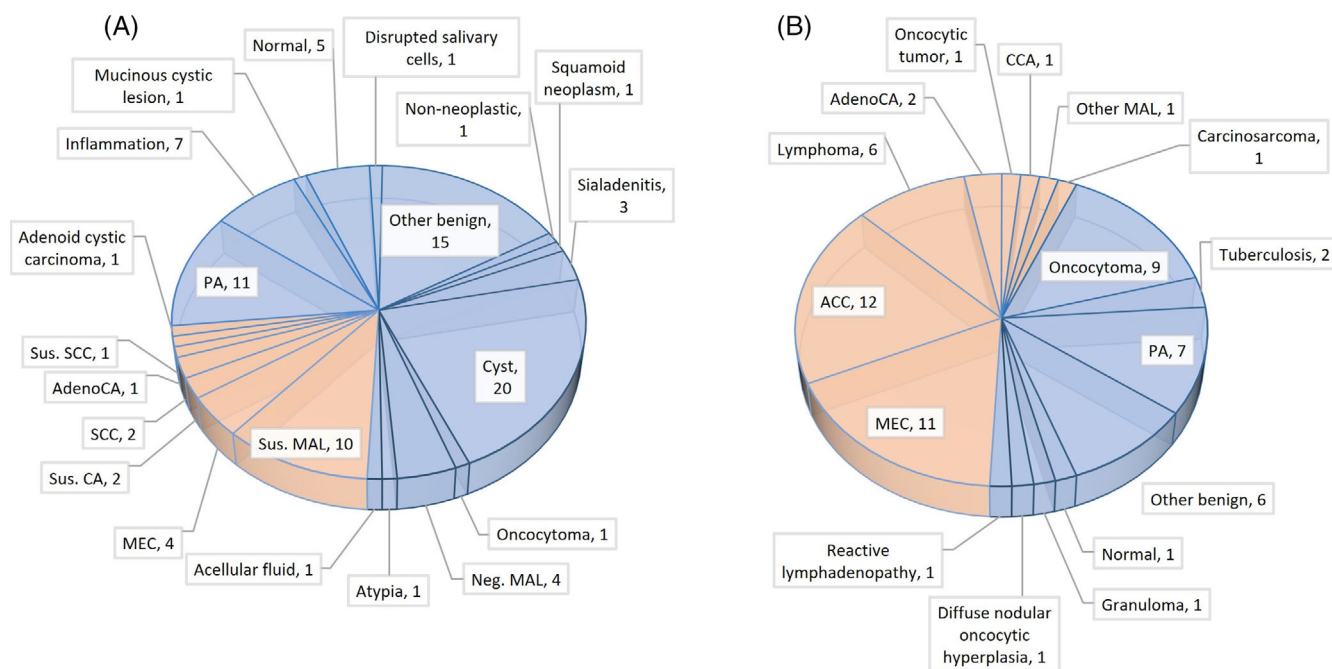


**FIGURE 5** Risk-of-bias and applicability concerns summary for each domain of the Diagnostic Accuracy Research Quality Assessment (QUADAS-2) for each included study. (A) Risk-of-bias table. (B) Risk-of-bias graph [Color figure can be viewed at [wileyonlinelibrary.com](http://wileyonlinelibrary.com)]

and some had a small sample size. Another limitation was that sensitivity and NPV showed a high degree of heterogeneity. Cytodiagnosis terminology used when assessing the salivary glands has some variability between medical centers, which might have been even more pronounced in articles published before 2015, before the Milan system was developed.<sup>23</sup> Given the

variability in reported FN and FP malignancy rates and established by this review, it is important that physicians be familiar with the institutional rate for malignancy when FNAC fails to diagnose correctly. This is key for advising the patient and informing them adequately for decision making. FNAC results are impacted by many factors, including collection method, physician FNA





**FIGURE 6** False negative (A) and false positive (B) results of fine-needle aspiration cytology diagnosis of Warthin tumor of the parotid gland in 17 studies. Blue and orange colors represent benign + normal and malignant cases, respectively. ACC, acinic cell carcinoma; adenoCA, adenocarcinoma; CCA, cribriform cystadenocarcinoma; DBCL, diffuse B cell lymphoma; MEC, mucoepidermoid carcinoma; Neg. MAL, negative for malignancy; PA, pleomorphic adenoma; SCC, squamous cell carcinoma; Sus. CA, suspicion of carcinoma; Sus. MAL, suspicion of malignancy; Sus. SCC, suspicion of squamous cell carcinoma [Color figure can be viewed at [wileyonlinelibrary.com](http://wileyonlinelibrary.com)]

training, freehand versus ultrasound-guided technique, and pathologist versus physician performed FNA. Most of the included studies failed to adequately report on these factors.<sup>24–26</sup>

## 6 | CONCLUSIONS

To the best of our knowledge, this is the first systematic review and meta-analysis of diagnostic accuracy of WT of the parotid gland. The study found that FNAC has high performance in the diagnosis of WT at this site. Although FP results were not common, most turned out to be malignant. The overall high PPV value suggests that selected patients with a cytological diagnosis of WT of the parotid can be assigned to active surveillance.

### ACKNOWLEDGMENTS

We wish to thank Mr. Basem Hijazi from the Azrieli Faculty of Medicine, Bar Ilan University, for the statistical analysis and Galilee-CBR for editorial assistance. The article was written as part of the requirements of the Azrieli Faculty of Medicine, Bar-Ilan University, Safed, Israel, for an MD degree of Roie Fisher.

### CONFLICT OF INTEREST

The authors declare that there is no conflict of interest that could be perceived as prejudicing the impartiality of the research reported.

### DATA AVAILABILITY STATEMENT

The data that support the findings of this study are available from the corresponding author upon reasonable request.

### ORCID

Roie Fisher <https://orcid.org/0000-0001-8832-2343>

Ohad Ronen <https://orcid.org/0000-0001-7084-0695>

### REFERENCES

- Zhan KY, Khaja SF, Flack AB, Day TA. Benign parotid tumors. *Otolaryngol Clin North Am*. 2016;49(2):327-342. doi:10.1016/j.otc.2015.10.005
- Teymoortash A, Krasnewicz Y, Werner JA. Clinical features of cystadenolymphoma (Warthin's tumor) of the parotid gland: a retrospective comparative study of 96 cases. *Oral Oncol*. 2006;42(6):569-573. doi:10.1016/j.oraloncology.2005.10.017
- Faur A, Lazăr E, Cornianu M, Dema A, Vidita CG, Gălușcan A. Warthin tumor: a curious entity—case reports and review of literature. *Rom J Morphol Embryol*. 2008;50(2):269-273.

4. Luers JC, Guntinas-Lichius O, Klusmann JP, Küsgen C, Beutner D, Grosheva M. The incidence of Warthin tumours and pleomorphic adenomas in the parotid gland over a 25-year period. *Clin Otolaryngol*. 2016;41(6):793-797. doi:10.1111/coa.12694
5. Tunç O, Gönüldaş B, Arslanhan Y, Kanlıkama M. Change in Warthin's tumor incidence: a 20-year joinpoint trend analysis. *Eur Arch Otorhinolaryngol*. 2020;277(12):3431-3434. doi:10.1007/s00405-020-06081-w
6. Psychogios G, Vlastos I, Thölken R, Zenk J. Warthin's tumour seems to be the most common benign neoplasm of the parotid gland in Germany. *Eur Arch Otorhinolaryngol*. 2020;277(7):2081-2084. doi:10.1007/s00405-020-05894-z
7. Alnoor F, Gandhi JS, Stein MK, Gradowski JF. Follicular lymphoma diagnosed in Warthin tumor: a case report and review of the literature. *Head Neck Pathol*. 2020;14(2):386-391. doi:10.1007/s12105-019-01045-x
8. Kim JE, Kim TG. Squamous cell carcinoma arising from Warthin's tumor in the parotid gland. *BJR Case Rep*. 2019;5(4):20190032. doi:10.1259/bjrcr.20190032
9. Srivastava S, Nadelman C. Synchronous ipsilateral warthin tumor encased by a separate mucoepidermoid carcinoma of the parotid gland: a case report and review of the literature. *Diagn Cytopathol*. 2010;38(7):533-537. doi:10.1002/dc.21267
10. Cobb CJ, Greaves TS, Raza AS. Fine needle aspiration cytology and diagnostic pitfalls in Warthin's tumor with necrotizing granulomatous inflammation and facial nerve paralysis: a case report. *Acta Cytol*. 2009;53(4):431-434. doi:10.1159/000325346
11. Manucha V, Gonzalez MF, Akhtar I. Impact of the Milan system for reporting salivary gland cytology on risk assessment when used in routine practice in a real-time setting. *J Am Soc Cytopathol*. 2021;10(2):208-215. doi:10.1016/j.jasc.2020.08.005
12. Parwani A, Ali SZ. Diagnostic accuracy and pitfalls in fine-needle aspiration interpretation of Warthin tumor. *Cancer*. 2003;99(3):166-171. doi:10.1002/cncr.11207
13. Schwalje AT, Uzelac A, Ryan WR. Growth rate characteristics of Warthin's tumours of the parotid gland. *Int J Oral Maxillofac Surg*. 2015;44(12):1474-1479. doi:10.1016/j.ijom.2015.07.019
14. Mantsopoulos K, Goncalves M, Koch M, Iro H. Watchful waiting in carefully selected metachronous cystadenolymphomas of the parotid gland: a reliable option? *Br J Oral Maxillofac Surg*. 2019;57(5):425-429. doi:10.1016/j.bjoms.2018.12.018
15. Seok J, Jeong WJ, Ahn SH, Jung YH. The growth rate and the positive prediction of needle biopsy of clinically diagnosed Warthin's tumor. *Eur Arch Otorhinolaryngol*. 2019;276(7):2091-2096. doi:10.1007/s00405-019-05493-7
16. Altın F, Alimoglu Y, Acikalin RM, Yasar H. Is fine needle aspiration biopsy reliable in the diagnosis of parotid tumors? Comparison of preoperative and postoperative results and the factors affecting accuracy. *Braz J Otorhinolaryngol*. 2019;85:275-281.
17. Viguer JM, Vicandi B, Jiménez-Heffernan JA, López-Ferrer P, González-Peramato P, Castillo C. Role of fine needle aspiration cytology in the diagnosis and management of Warthin's tumour of the salivary glands. *Cytopathology*. 2010;21(3):164-169. doi:10.1111/j.1365-2303.2009.00667.x
18. So T, Sahovaler A, Nichols A, et al. Utility of clinical features with fine needle aspiration biopsy for diagnosis of Warthin tumor. *J Otolaryngol Head Neck Surg*. 2019;48(1):1-5. doi:10.1186/s40463-019-0366-3
19. Zbaren P, Schr C, Hotz MA, Loosli H. Value of fine-needle aspiration cytology of parotid gland masses. *Laryngoscope*. 2001;111:1989-1992.
20. McInnes MDF, Moher D, Thombs BD, et al. Preferred reporting items for a systematic review and meta-analysis of diagnostic test accuracy studies the PRISMA-DTA statement. *JAMA*. 2018;319(4):388-396. doi:10.1001/jama.2017.19163
21. Reitsma JB, Leeflang MMG, Sterne JAC, et al. QUADAS-2: a revised tool for the quality assessment of diagnostic accuracy studies. *Ann Intern Med*. 2011;155(4):529-536.
22. Sučić M, Ljubić N, Perković L, et al. Cytopathology and diagnostics of Warthin's tumour. *Cytopathology*. 2020;31(3):193-207. doi:10.1111/cyt.12830
23. Barbarite E, Puram SV, Derakhshan A, Rossi ED, Faquin WC, Varvares MA. A call for universal acceptance of the Milan system for reporting salivary gland cytopathology. *Laryngoscope*. 2020;130(1):80-85. doi:10.1002/lary.27905
24. Ganguly A, Burnside G, Nixon P. A systematic review of ultrasound-guided FNA of lesions in the head and neck-focusing on operator, sample inadequacy and presence of on-spot cytology service. *Br J Radiol*. 2014;87(1044):20130571. doi:10.1259/bjr.20130571
25. Ljung BM, Drejet A, Chiampi N, et al. Diagnostic accuracy of fine-needle aspiration biopsy is determined by physician training in sampling technique. *Cancer*. 2001;93(4):263-268. doi:10.1002/cncr.9040
26. Pinki P, Alok D, Ranjan A, Chand MN. Fine needle aspiration cytology versus fine needle capillary sampling in cytological diagnosis of thyroid lesions. *Iran J Pathol*. 2015;10(1):47-53. doi:10.7508/ijp.2015.01.007
27. Al-Khafaji BM, Nestok BR, Katz RL. Fine-needle aspiration of 154 parotid masses with histologic correlation: ten-year experience at the University of Texas M. D. Anderson Cancer Center. *Cancer*. 1998;84:153-159.
28. Atula T, Grénman R, Laippala P, Klemi P. Fine-needle aspiration biopsy in the diagnosis of parotid gland lesions: evaluation of 438 biopsies. *Diagn Cytopathol*. 1996;15(3):185-190.
29. Edizer DT, Server EA, Yigit O, Yildiz M. Role of fine-needle aspiration biopsy in the management of salivary gland masses. *Turk Arch Otolarengol*. 2016;54(3):105-111.
30. Huang YC, Wu CT, Lin G, Chuang WY, Yeow KM, Wan YL. Comparison of ultrasonographically guided fine-needle aspiration and core needle biopsy in the diagnosis of parotid masses. *J Clin Ultrasound*. 2012;40:189-194.
31. Jafari A, Royer B, Lefevre M, Corlieu P, Périé S, St Guily JL. Value of the cytological diagnosis in the treatment of parotid tumors. *Otolaryngol Head Neck Surg*. 2009;140(3):381-385. doi:10.1016/j.otohns.2008.10.032
32. Jayaram G, Verma AK, Sood N, Khurana N. Fine needle aspiration cytology of salivary gland lesions. *J Oral Pathol Med*. 1994;23(6):256-261. doi:10.1111/j.1600-0714.1994.tb00055.x
33. Jechova A, Kuchar M, Novak S, et al. The role of fine-needle aspiration biopsy (FNAB) in Warthin tumour diagnosis and management. *Eur Arch Otorhinolaryngol*. 2019;276(10):2941-2946. doi:10.1007/s00405-019-05566-7
34. Raymond MR, Yoo JH, Heathcote JG, McLachlin CM, Lampe HB. Accuracy of fine-needle aspiration biopsy for Warthin's tumours. *J Otolaryngol*. 2002;31(5):263-270. doi:10.2310/7070.2002.34289

35. Suzuki M, Kawata R, Higashino M, et al. Values of fine-needle aspiration cytology of parotid gland tumors: a review of 996 cases at a single institution. *Head Neck*. 2019;41(2):358-365. doi:[10.1002/hed.25503](https://doi.org/10.1002/hed.25503)
36. Akbaş Y, Tuna EU, Demireller A, Ozcan H, Ekinci C. Ultrasonography guided fine needle aspiration biopsy of parotid gland masses. *Kulak Burun Bogaz Ihtis Derg*. 2004; 13:15-18.
37. Behzatoğlu K, Bahadır B, Kaplan HH, Yücel Z, Durak H, Bozkurt ER. Fine needle aspiration biopsy of the parotid gland: diagnostic problems and 2 uncommon cases. *Acta Cytol*. 2004; 48(2):149-154. doi:[10.1159/000326308](https://doi.org/10.1159/000326308)
38. Ali NS, Akhtar S, Junaid M, Awan S, Aftab K. Diagnostic accuracy of fine needle aspiration cytology in parotid lesions. *ISRN Surg*. 2011;2011:1-5. doi:[10.5402/2011/721525](https://doi.org/10.5402/2011/721525)
39. Riley N, Allison R, Stevenson S. Fine-needle aspiration cytology in parotid masses: our experience in Canterbury, New Zealand. *ANZ J Surg*. 2005;75(3):144-146. doi:[10.1111/j.1445-2197.2005.03331.x](https://doi.org/10.1111/j.1445-2197.2005.03331.x)
40. Weinberger MS, Rosenberg WW, Meurer WT, Robbins KT. Fine-needle aspiration of parotid gland lesions. *Head Neck*. 1992;14(6):483-487. doi:[10.1002/hed.2880140611](https://doi.org/10.1002/hed.2880140611)

**How to cite this article:** Fisher R, Ronen O. Cytologic diagnosis of parotid gland Warthin tumor: Systematic review and meta-analysis. *Head & Neck*. 2022;44(10):2277-2287. doi:[10.1002/hed.27099](https://doi.org/10.1002/hed.27099)