

Teaching Point
(Section Editor: A. Meyrier)

End-stage renal failure associated with congenital deafness

Nicholas M P Annear¹, Daniel P Gale¹, Sam Loughlin², Huw R Dorkins³ and Patrick H Maxwell¹

¹Department of Nephrology, Imperial College, London, ²Molecular Genetics Laboratory, N.E. Thames Regional Genetics Service and ³N.W. Thames Regional Genetics Service, Kennedy Galton Centre, Harrow HA1 3UJ, UK

Keywords: Branchio-oto-renal syndrome; BOR syndrome; genetic renal disease; sensorineural deafness

Introduction

The commonest cause of hereditary deafness associated with renal failure is the Alport syndrome, but it is important to be aware of other possible diagnoses. We report a patient presenting, at end-stage renal failure, with a family history of sensori-neural deafness, in whom the diagnosis was branchio-oto-renal (BOR) syndrome; resequencing the *EYAI* gene revealed a novel mutation.

Case history

A 26-year-old male was referred as an emergency to the renal service with a plasma creatinine of 1235 $\mu\text{mol/L}$. He had attended his general practitioner with a 3-week history of oral thrush, nausea, weight loss, nocturia and pruritus. He did not complain of visual problems, rash or arthralgia and was not taking any medications. His hearing had been impaired since birth, to the point that he required hearing aids from the age of 11. His mother, maternal grandfather, maternal aunt and uncle, and a brother were also deaf (Figure 1). The maternal aunt was known to have a moderate renal impairment. On examination, the blood pressure was 168/97, the chest was clear and abdominal examination unremarkable. Urinalysis showed proteinuria 4+ and haematuria 3+; urine protein/creatinine ratio was 560 mg/mmol. Blood tests showed a haemoglobin of 7.2 g/dL, MCV 90.6 fL, platelets 243×10^9 g/L, potassium 5.9 mmol/L, urea 47.4 mmol/L and creatinine 1235 $\mu\text{mol/L}$. His serum albumin was 40 g/L, serum calcium 1.97 mmol/L, phosphate 1.96 mmol/L and parathyroid hormone level 64.0 pmol/L. Haematinic levels were normal. His autoimmune screen showed no abnormal-

ity. Abdominal ultrasound demonstrated that both kidneys were <8 cm in bipolar length.

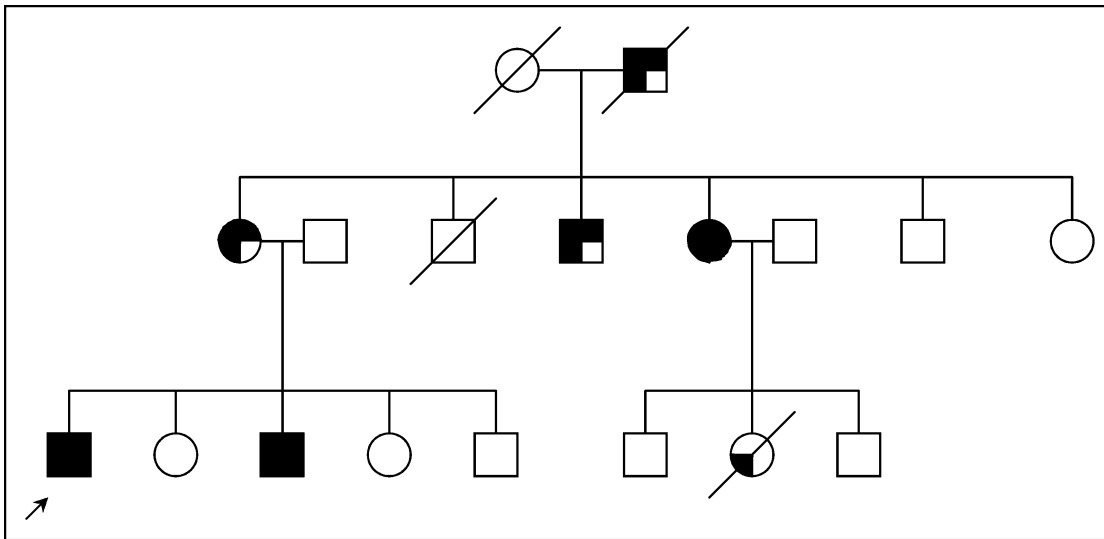
A diagnosis of the Alport syndrome was considered, and a skin biopsy was performed to examine the expression of type IV collagen α -chains; immunohistochemistry showed normal α -I and α -V in the basement membrane. Direct ophthalmoscopy was normal and did not demonstrate anterior lenticonus. In addition, the pattern of inheritance in the kindred was not consistent with X-linked Alport syndrome, since there was evidence of father-to-son transmission. Further examination of the patient revealed preauricular pits bilaterally (Figure 2). The same finding was identified in his mother and brother. The combination of preauricular pits, deafness and renal disease suggested a diagnosis of BOR syndrome.

The patient has been successfully treated with dialysis and a cadaveric renal transplant. He and his fiancée were planning to have children. Genetic counselling was provided, and resequencing of the *EYAI* gene was performed that revealed a c.1376 + 2T > C mutation in intron 13, which alters the consensus splice donor site and is presumed to be the cause of disease in this patient (Figure 3). Genetic counselling of the couple addressed several issues, including the one in two risk that he would transmit the mutant *EYAI* allele each time they conceived. Review of his family history reinforced his understanding that there is substantial variability in the expression of the condition, even amongst carriers of the same mutation. Consequently, the value of conventional prenatal diagnosis would be limited, as demonstration of the presence of the *EYAI* gene mutation would not yield clear prognostic information concerning the risk of significant renal disease. The couple was advised that a potential option is preimplantation genetic diagnosis. While this technique has not yet been applied to BOR syndrome in the United Kingdom, it is now practicable to perform preimplantation genetic haplotyping, which would allow selective implantation of embryos that do not carry the mutation.

Discussion

Cases of familial deafness associated with renal dysfunction are not infrequently mislabelled as the Alport syndrome,

Correspondence and offprint requests to: Nicholas M. P. Annear, Department of Nephrology, Imperial College, London, UK. E-mail: nickannear@doctors.org.uk



Key:	
	Preauricular pits
	Hearing loss
	Branchial fistulae
	Renal abnormalities
	Deceased
	Patient

Fig. 1. The family tree of the patient.

Shown for each of the 18 members is the presence or absence of the four main features of the BOR syndrome: preauricular pits, hearing loss, branchial fistulae and renal abnormalities.

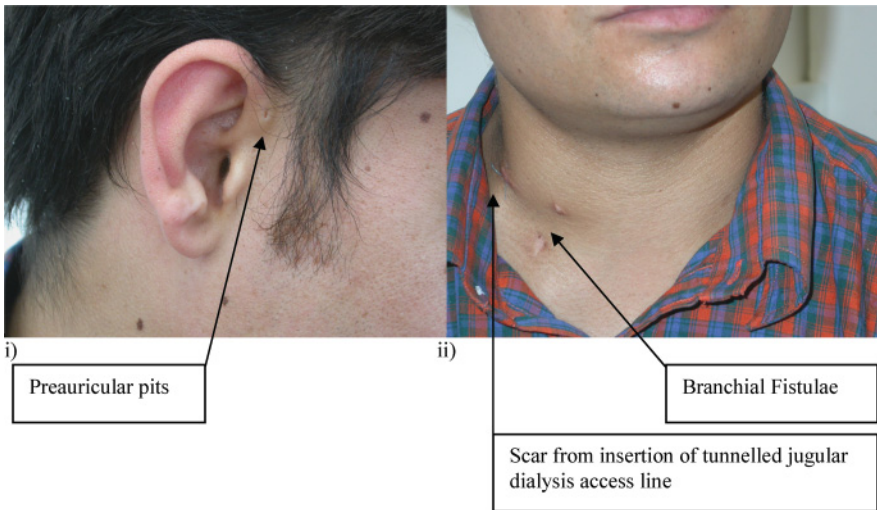


Fig. 2. (i) Preauricular pits and (ii) branchial fistulae in the patient.

without further investigation [1]. The differential diagnosis for patients presenting with deafness and renal dysfunction is wide—a search of the Online Mendelian Inheritance in Man database (OMIM) for sensorineural deafness and renal

disease yields 80 disorders. The commoner diagnoses that nephrologists should be aware of are summarized in Table 1.

An accurate diagnosis may provide useful prognostic information for the patient and family. Furthermore, it may

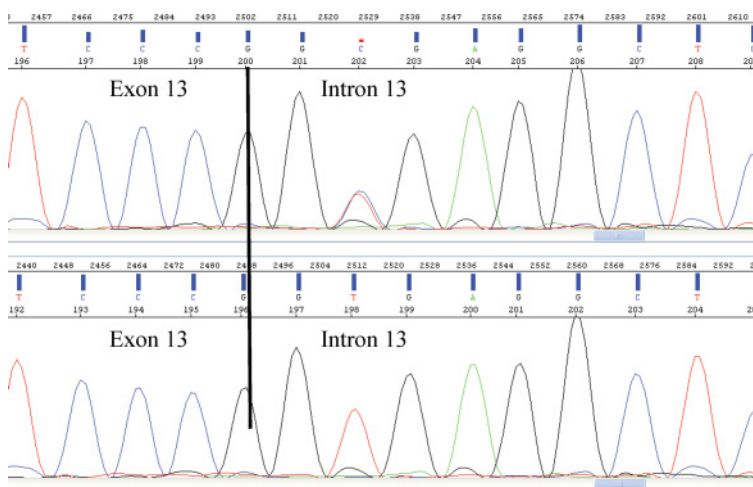


Fig. 3. Sequence analysis of exon 13 of the *EYAI* gene in the patient.

The first (uppermost) trace is from the patient. The second trace is a normal control. The c.1376+2T>C mutation occurs 2 base pairs into intron 13 and affects the splice donor site. This mutation is predicted to result in aberrant splicing of exon 13 to exon 14.

Table 1. Inherited deafness and renal disease [16]

Disease	Main clinical features	Inheritance	Gene implicated
Alport syndrome	Glomerular disease Sensorineural deafness Anterior Lenticonus	X-linked (Autosomal dominant & recessive forms recognized)	<i>COL4A5</i>
Epstein syndrome and Fechtner syndrome ^a	Glomerular disease Sensorineural deafness Macrothrombocytopaenia Leukocyte inclusions—Fechtner Cataracts—Fechtner	Autosomal dominant	<i>MYH9</i>
Branchio-oto-renal syndrome	Renal anomalies Deafness (sensorineural or conductive) Preauricular pits Branchial fistulae	Autosomal dominant	<i>EYAI</i> <i>SIX 1</i> <i>SIX5</i>
Familial hypo-/hyper-parathyroidism, deafness and renal disease (HDR)	Renal anomalies Sensorineural deafness Hypo-/hyper-parathyroidism	Autosomal dominant	<i>GATA3</i> <i>CaSR</i>

^aEpstein and Fechtner syndromes are considered variable expressions of a single illness: 'MYH9-related disease'.

Other causes of deafness and renal disease include Muckle–Wells syndrome, Cockayne syndrome, Refsum's disease, Charcot-Marie-Tooth disease, familial spastic paraplegia, diabetes mellitus, photomyoclonus, mitochondrial cytopathies, ataxia hyperuricaemia and Bartter's syndrome.

assist with selection of suitable living donors among relatives of those at end-stage renal failure.

This report illustrates a case of BOR syndrome (OMIM 113650) [2] presenting in adulthood, in whom renal anomalies had not previously been identified, and a nephrological opinion never previously sought.

BOR is an autosomal dominant disorder characterized by the association of branchial cysts or fistulae, external ear malformation and/or preauricular pits, hearing loss and renal anomalies [3]. Although an association between hearing impairment, preauricular pits and branchial fistulae was recognized in the mid-19th century, BOR was first precisely defined by Melnick and Fraser in the 1970s [4,5]. The estimated incidence of BOR is 1:40 000 and may be the underlying diagnosis in ~2% of profoundly deaf children [6].

There is both phenotypic and genetic heterogeneity within BOR. Reported frequencies of specific features

include hearing loss (93%), preauricular pits or tags (82%), renal anomalies (67%), branchial fistulae (49%), pinnae deformity (36%) and external auditory canal stenosis (29%) [7]. These have been subsequently classified into major and minor anomalies occurring in >20% or ≤20%, respectively [7] (Table 2). Renal abnormalities occur in around 66% of affected individuals and include bilateral hypodysplasia, unilateral renal agenesis, which may be associated with contralateral hypodysplasia, and hydronephrosis caused by pelvi-ureteric obstruction or vesico-ureteric reflux. Patients with ocular and branchial features of BOR in the absence of renal involvement have in the past been described as having branchiootic syndrome, BOS (OMIM 602588 [8], 120502 [9] and 608389 [10]). Other minor anomalies, including haematuria and proteinuria, have also been reported [7,11]. End-stage renal failure affects ~6% of patients, although the prevalence may be higher where other family members

Table 2. Phenotypic features in BOR syndrome [7]

Major anomalies, occurring > 20%	Minor anomalies, occurring ≤ 20%
Hearing loss	Preauricular tag
Preauricular pits	Lacrimal duct aplasia
Renal anomalies	Short palate
Branchial fistulae	Retrognathia
Pinnae deformities	Benign intracranial tumour
External auditory canal stenosis	Cleft palate
	Congenital hip dysplasia
	Euthyroid goitre
	Facial nerve paresis
	Gustatory lacrimation
	Non-rotation of the gastrointestinal tract
	Pancreatic duplication cyst
	Temporoparietal linear naevus

Table 3. Phenotypic criteria for *EYAI* testing in BOR syndrome [15]

Major criteria	Minor criteria
Branchial anomalies	External ear anomalies
Deafness	Middle ear anomalies
Preauricular pits	Inner ear anomalies
Renal anomalies	Preauricular tags
	Other: facial asymmetry, palate abnormalities
	Screening for <i>EYAI</i> mutations is appropriate in those with:
	1. At least three major findings
	2. Two major findings and at least two minor findings
	3. At least one major finding and an affected first-degree relative with BOR syndrome

are similarly affected [1,12]. Progression to end-stage renal failure more commonly occurs during childhood, and presentation in adulthood remains under-recognized [7].

Genetic studies have shown that BOS and BOR are not genetically distinct as had been thought, since two BOS loci map to genes that are mutated in BOR. The commonest two underlying genes act in a regulatory network: *EYAI* (implicated in BOR1/BOS1) and *SIX1* (BOS3). These are predicted orthologues of genes involved in *Drosophila* eye development: eyes absent gene (*eya*) and sine oculis (*so*), respectively. *EYAI*, a transcriptional co-activator, has a conserved, 271-amino-acid C-terminal known as the eye domain (ED). Mutations in *EYAI* account for ~40% of BOR syndrome patients [3]. *SIX1* has two highly conserved domains, a homeodomain (HD) and a specific six domain (SD) [3]. Recent evidence has also implicated another member of the *SIX* gene family in BOR, transcription factor *SIX5* (BOR2), which also forms a regulatory complex with *EYAI* [13]. The underlying gene at a third BOS locus (BOS2 on the long arm of chromosome 1) has not yet been identified.

An important aspect of this case is that patients with branchial abnormalities or preauricular pits and deafness should be screened for renal disease. It has been proposed that all family members of patients with BOR should be screened at least with a renal ultrasound scan [14], and that patients who meet specified criteria should be screened for *EYAI* mutations [15] (Table 3).

Conclusions

There are several causes of deafness and renal disease. This report highlights the importance of considering broader differential diagnoses when faced with an apparently familiar clinical picture.

Teaching points

This case highlights the following important teaching points:

1. Renal dysfunction associated with deafness has a broader differential diagnosis than Alport syndrome alone.
2. BOR syndrome is a common cause of hereditary deafness. Renal anomalies and consequent dysfunction are common in this group. Even within families, the disease is phenotypically heterogeneous due to incomplete penetrance.
3. Patients diagnosed with BOR syndrome should have a full nephrological work-up including ultrasonography, urinalysis and plasma creatinine. Early identification of renal disease may allow intervention to slow decline and enables timely planning of appropriate renal replacement therapy.
4. Resequencing of *EYAI* will identify a causative mutation in ~40% of BOR cases. This confirms the diagnosis and would permit preimplantation genetic diagnosis.

Acknowledgements. We are grateful for support from the NIHR Biomedical Research Centre funding scheme.

Conflict of interest statement. P.H.M. is a founder, director and equity holder in ReOx Ltd. The results presented in this paper have not been published in whole or part previously.

References

1. Misra M, Nolph KD. Renal failure and deafness: branchio-oto-renal syndrome. *Am J Med Genet* 1998; 37: 305–309
2. Online Mendelian Inheritance in Man, OMIM (TM). Johns Hopkins University, Baltimore, MD. MIM Number: 113650: <http://www.ncbi.nlm.nih.gov/omim/> (updated 29 March 2007)
3. Kochhar A, Fischer SM, Kimberling WJ *et al.* Branchio-oto-renal syndrome. *Am J Med Genet A* 2007; 143: 1671–1678
4. Fraser FC, Ling D, Clogg D *et al.* Genetic aspects of the BOR syndrome-branchial fistulas ear pits, hearing loss, and renal anomalies. *Am J Med Genet* 1978; 14: 473–478
5. Melnick M, Bixler D, Silk K *et al.* Autosomal dominant branchiootorenal dysplasia. *Birth Defects Orig Artic Ser* 1975; 11: 121–128
6. Fraser FC, Sproule JR, Halal F. Frequency of the branchio-oto-renal (BOR) syndrome in children with profound hearing loss. *Am J Med Genet* 1980; 7: 341–349
7. Chen A, Francis M, Ni L *et al.* Phenotypic manifestations of branchiootorenal syndrome. *Am J Med Genet* 1995; 58: 365–370
8. Online Mendelian Inheritance in Man, OMIM (TM). Johns Hopkins University, Baltimore, MD. MIM Number: {602588}: <http://www.ncbi.nlm.nih.gov/omim/> (updated 29 March 2007)
9. Online Mendelian Inheritance in Man, OMIM (TM). Johns Hopkins University, Baltimore, MD. MIM Number: {120502}: <http://www.ncbi.nlm.nih.gov/omim/> (updated 8 February 2006)
10. Online Mendelian Inheritance in Man, OMIM (TM). Johns Hopkins University, Baltimore, MD. MIM Number: {608389}: <http://www.ncbi.nlm.nih.gov/omim/> (updated 4 April 2007)

11. Basse F, Lacombe D, Aboulsleman J *et al.* Branchio-oto-renal syndrome: four cases in three families. *Presse Med* 1995; 24: 842–844
12. Pierides AM, Athanasiou Y, Demetriou K *et al.* A family with the branchio-oto-renal syndrome: clinical and genetic correlations. *Nephrol Dial Transplant* 2002; 17: 1014–1018
13. Hoskins BE, Cramer CH, Silvius D *et al.* Transcription factor SIX5 is mutated in patients with branchio-oto-renal syndrome. *Am J Hum Genet* 2007; 80: 800–804
14. Bellini C, Piaggio G, Massocco D *et al.* Branchio-oto-renal syndrome: a report on nine family groups. *Am J Kidney Dis* 2001; 37: 505–509
15. Chang EH, Menezes M, Meyer NC *et al.* Branchio-oto-renal syndrome: the mutation spectrum in EYA1 and its phenotypic consequences. *Hum Mutat* 2004; 6: 582–589
16. Richardson D, Shires M, Davison AM. Renal diagnosis without renal biopsy: nephritis and sensorineural deafness. *Nephrol Dial Transplant* 2001; 16: 1291–1294

Received for publication: 3.1.08

Accepted in revised form: 1.2.08