

Successful management of wound dehiscence after implantation of a subcutaneous implantable cardioverter-defibrillator without device removal

Mitsuhiro Fukata, MD, PhD,* Takeshi Arita, MD, PhD,* Hideki Kadota, MD, PhD,[†] Keita Odashiro, MD, PhD,* Toru Maruyama, MD, PhD,[‡] Koichi Akashi, MD, PhD*

From the *Department of Hematology, Oncology and Cardiovascular Medicine, Kyushu University Hospital, Fukuoka, Japan, [†]Department of Plastic and Reconstructive Surgery, Kyushu University Hospital, Fukuoka, Japan, and [‡]Faculty of Art and Science, Kyushu University, Fukuoka, Japan.

Introduction

A subcutaneous implantable cardioverter-defibrillator (S-ICD) is now being used as an alternative to a transvenous implantable cardioverter-defibrillator (TV-ICD). Because the location of the device in the body differs between S-ICD and TV-ICD, ICD-related complications need to be managed in a device-specific manner. Therefore, therapeutic strategies for infected wounds may differ between patients with S-ICD and those with TV-ICD.

Case report

A 63-year-old man with fever-induced type 1 Brugada electrocardiogram was referred to our department for the evaluation

of Brugada syndrome. He did not have a family history of sudden death. Because he had a history of syncope, an electrophysiological study was performed to assess indications for ICD. Ventricular fibrillation was induced by triple extrastimuli at the right ventricular outflow tract. The patient was informed of treatment options and selected the implantation of an ICD.

After written informed consent was obtained, EMBLEM S-ICD (Boston Scientific, Marlborough, MA) implantation was performed. Based on the results of a surface electrocardiogram screening test showing T-wave oversensing in all leads using an electrode at the left sternal border, but not in the secondary and alternative lead using an electrode at the

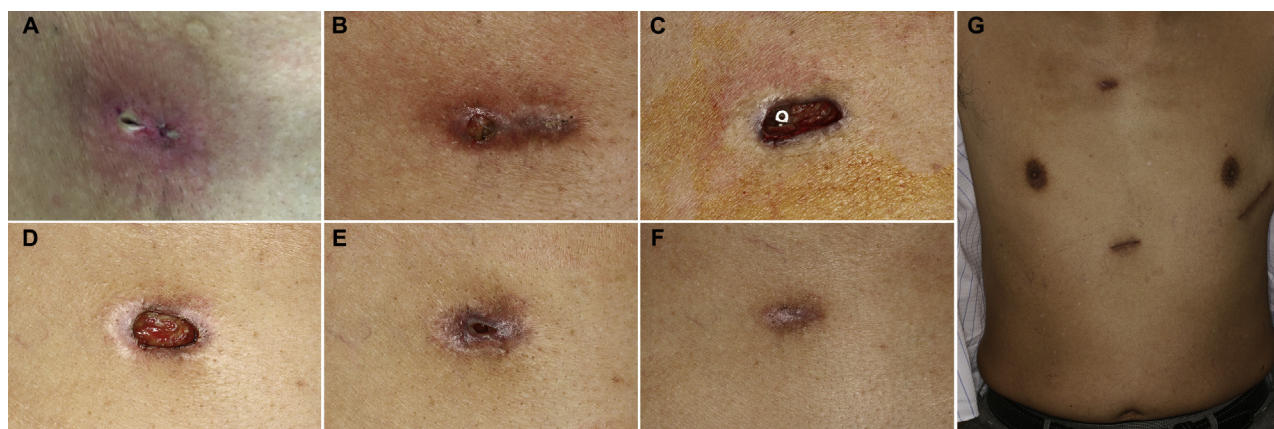


Figure 1 Photographs of the surgical wound at the upper sternum on postoperative day (POD)-3 (A), POD-31 (B: before debridement; C: after debridement), POD-35 (D), POD-49 (E), and POD-70 (F, G).

KEYWORDS Subcutaneous implantable cardioverter-defibrillator; Infection; Wound dehiscence; Basic fibroblast growth factor; Conservative therapy (Heart Rhythm Case Reports 2017;3:415–417)

Address reprint requests and correspondence: Dr Mitsuhiro Fukata, Department of Hematology, Oncology, and Cardiovascular Medicine, Kyushu University Hospital, Maidashi 3-1-1, Higashi-ku, Fukuoka 812-8582, Japan. E-mail address: mfukata-circ@umin.net.

right sternal border, an ICD coil was inserted subcutaneously at the right sternal border. ICD lead insertion was performed using the 3-incision technique. Defibrillation threshold testing was performed in the operating room. An S-ICD shock was appropriately delivered and successfully terminated ventricular fibrillation at 65 J. The 3 surgical wounds were closed using bioabsorbable sutures and covered by a hydrocolloid dressing. Cefazolin was administered intravenously 1 hour

KEY TEACHING POINTS

- Some cases of surgical wound dehiscence without overt infection may successfully heal without device removal. The appropriate management of wounds and careful follow-ups are needed in order to achieve complete wound healing.
- Therapy for superficial erosion or surgical wound dehiscence without device removal may be less harmful for patients with a subcutaneous implantable cardioverter-defibrillator (ICD) than those with a transvenous ICD based on the risk of pathogens tracking along the leads.
- The application of basic fibroblast growth factor represents a promising strategy to accelerate healing in the case of wound dehiscence with a cardiac implantable electronic device, in which infection may cause serious complications.

before the procedure and was continued at 12-hour intervals. In order to minimize T-wave oversensing, a secondary vector (from the A-electrode to the generator) was employed as the sensing configuration of S-ICD based on the findings of an exercise stress test after S-ICD implantation.

On postoperative day (POD)-3, the surgical wound at the upper sternal border (the location of the A-electrode) became reddish and detached (Figure 1A). The wound dressing was removed and daily irrigation was initiated at the hospital.

The patient was discharged on POD-8. The intravenous administration of cefazolin was changed to oral minocycline at the time of discharge. Because the wound at the upper sternal border had not closed on POD-9, the debridement of necrotic tissue and resuturing were performed. However, the healing of subcutaneous tissue was poor and bioabsorbable sutures were exposed on POD-31 (Figure 1B). Further debridement was performed to remove unhealthy granulation tissue. Because the A-electrode was exposed after debridement (Figure 1C), sensing errors during various body movements were examined. In the alternative lead, which is independent of the A-electrode, the QRS/T amplitude ratio was not sufficiently large to eliminate T-wave oversensing. Noise oversensing by shoulder joint motion was detected in the second lead (Figure 2A). In order to prevent an inappropriate shock, the patient was prohibited from this motion, and the shock zone and conditional shock zone were both set at 250 beats per minute (bpm) (maximum rate). Although the A-electrode was exposed, the S-ICD system was not removed because device infection was unlikely based on the appearance of the wound and weak inflammatory response in a blood examination (Figure 3). The patient was instructed to spray basic fibroblast growth factor (bFGF; FIBLAST [Kaken Pharmaceutical, Tokyo, Japan]) after daily irrigation of the wound at home. On POD-35, healthy granulation tissue covered the A-electrode (Figure 1D). The patient continued irrigation and the administration of bFGF. Subcutaneous healthy granulation continually increased (Figure 1E), and the wound completely closed by POD-70 (Figure 1F and G).

Because noise oversensing by shoulder joint motion disappeared in the follow-up visit (8 months after S-ICD implantation, Figure 2B), the shock zone and conditional

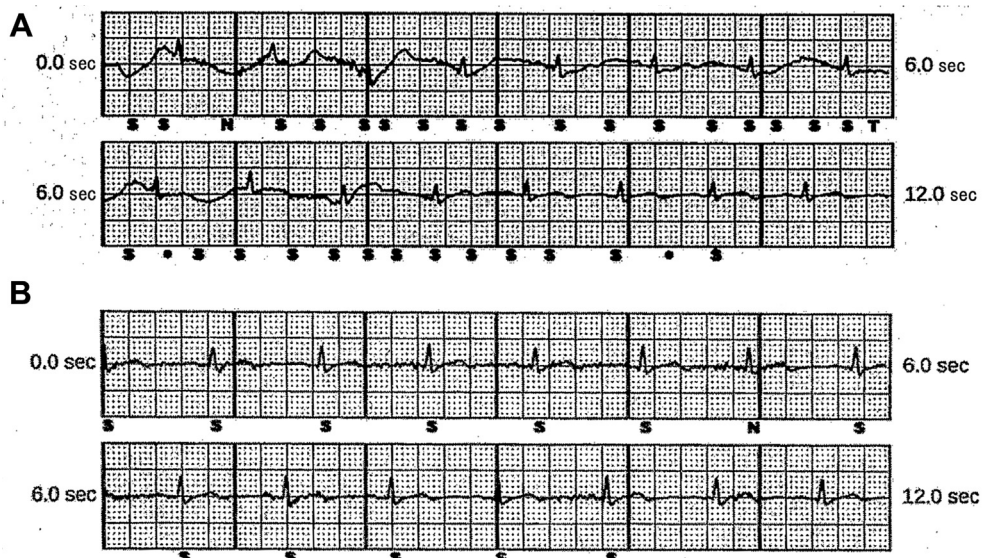


Figure 2 Subcutaneous implantable cardioverter-defibrillator electrogram in a secondary vector during shoulder joint motion on postoperative day 31 (A) and 8 months after implantation (B). **A:** Noises induced by body motion were mainly inappropriately recognized as ventricular activation (marked as “S” under the electrogram), and 1 noise just before 6 seconds after starting the recording was recognized as ventricular tachyarrhythmia (marked as “T” under the electrogram). Only 1 noise during this recording was appropriately recognized as noise (marked as “N” under the electrogram). **B:** Noise induced by body motion was appropriately discriminated. Only 1 true ventricular activation at sinus rhythm during recording was interfered by noise (marked as “N” under the electrogram).

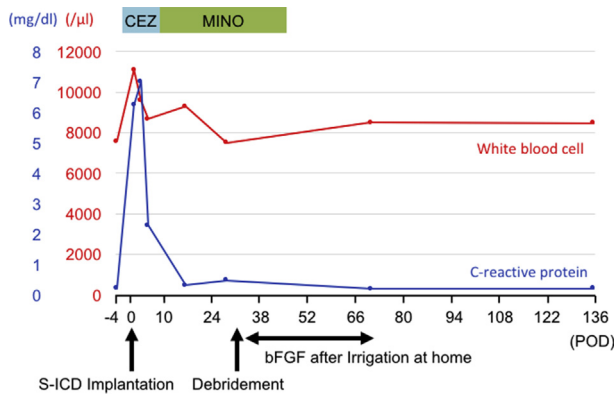


Figure 3 Time course of blood examinations. The white blood cell count and C-reactive protein level both transiently increased after subcutaneous implantable cardioverter-defibrillator (S-ICD) implantation, but rapidly decreased to normal ranges within 1 week. bFGF = basic fibroblast growth factor; CEZ = cefazolin; MINO = minocycline; POD = postoperative day.

shock zone were set at 230 bpm and 200 bpm, respectively. Neither appropriate nor inappropriate shocks were delivered after the implantation of S-ICD.

Discussion

The S-ICD is a device that is clearly distinguished from the TV-ICD based on the necessity of an intracardiovascular lead. A recent study reported similar complication rates in patients with an S-ICD or TV-ICD; however, the nature of the complications differed.¹ Although S-ICD has a lower risk of lead-related complications than TV-ICD, the incidence of non-lead-related complications was higher for S-ICD than for TV-ICD. The rate of infection in earlier studies on S-ICD (4.0%–5.7%)^{2–4} appeared to be greater than that recently reported for TV-ICD (0.7%–1.2%).⁵ Possible factors associated with the higher rate of S-ICD infection include the learning curve for the implantation procedure, larger generator size, and patient selection bias. Some of these factors may be improved. The newly reported 2-incision technique is less invasive than the 3-incision technique and may reduce infection rates at the superior parasternal incision.⁶

Although complete cardiac implantable electronic device (CIED) system removal is initially recommended in the case of overt CIED infection, it is not necessarily required for superficial or incisional infection.⁷ In the case of S-ICD, device-related blood-borne infection is considered to be rare and has not yet been reported. Therefore, if there is no overt “true” device infection, the strategy to treat wound dehiscence without removal of the device may be less harmful for patients with S-ICD than for those with TV-ICD. Successful cases of pocket infections treated with antibiotics without opening the device pocket have been reported.^{2–4} Even if wounds successfully heal, as in the present case, signs of infection need to be carefully followed up so as to prevent overlooking localized and indolent infection after the treatment of wound infection without device removal. When subcutaneous infection is suspected,

a fluorodeoxyglucose–positron emission tomography examination may be crucial for detecting inflammation at a deeper site.

This is the first case report using bFGF for S-ICD surgical wound dehiscence. bFGF is a chemokine that promotes angiogenesis, granulation, and epithelialization via endothelial cell, fibroblast, and keratinocyte migration, respectively. Through these mechanisms, bFGF has been reported to shorten the healing period in patients with burns,⁸ cure wounds without scarring,^{9,10} and reduce pre-existing scars.¹¹ The repair of surgical wounds was previously shown to be partly mediated by bFGF.¹² In addition to these findings, the application of bFGF to superficial infections or wound dehiscence in patients with CIED is considered to be reasonable and has the potential to become a promising strategy. Furthermore, if outpatient treatment is selected and successful, as in the present case, it may be an economically preferable option.

Conclusions

Device removal is a standard therapy for device-related infection in patients with TV-ICD. However, owing to the lower risk of blood-borne infection in patients with S-ICD, in the case of superficial infection or dehiscence alone at suture wounds, treatment without removal of the device may be applicable for patients with S-ICD. Furthermore, the use of bFGF following debridement may promote tissue healing, leading to a reduced incidence of infection.

References

- Brouwer TF, Yilmaz D, Lindeboom R, Buiten MS, Olde Nordkamp LR, Schalij MJ, Wilde AA, van Erven L, Knops RE. Long-term clinical outcomes of subcutaneous versus transvenous implantable defibrillator therapy. *J Am Coll Cardiol* 2016;68:2047–2055.
- Weiss R, Knight BP, Gold MR, Leon AR, Herre JM, Hood M, Rashtian M, Kremers M, Crozier I, Lee KL, Smith W, Burke MC. Safety and efficacy of a totally subcutaneous implantable-cardioverter defibrillator. *Circulation* 2013;128:944–953.
- Lambiase PD, Barr C, Theuns DA, et al. Worldwide experience with a totally subcutaneous implantable defibrillator: early results from the EFFORTLESS S-ICD Registry. *Eur Heart J* 2014;35:1657–1665.
- Aziz S, Leon AR, El-Chami MF. The subcutaneous defibrillator: a review of the literature. *J Am Coll Cardiol* 2014;63:1473–1479.
- Kirkfeldt RE, Johansen JB, Nielsen JC. Management of cardiac electronic device infections: challenges and outcomes. *Arrhythm Electrophysiol Rev* 2016;5:183–187.
- Knops RE, Olde Nordkamp LR, de Groot JR, Wilde AA. Two-incision technique for implantation of the subcutaneous implantable cardioverter-defibrillator. *Heart Rhythm* 2013;10:1240–1243.
- Sekiguchi Y. Conservative therapy for the management of cardiac implantable electronic device infection. *J Arrhythm* 2016;32:293–296.
- Zhang Y, Wang T, He J, Dong J. Growth factor therapy in patients with partial-thickness burns: a systematic review and meta-analysis. *Int Wound J* 2016;13:354–366.
- Akita S, Akino K, Imaizumi T, Hirano A. A basic fibroblast growth factor improved the quality of skin grafting in burn patients. *Burns* 2005;31:855–858.
- Akita S, Akino K, Imaizumi T, Tanaka K, Anraku K, Yano H, Hirano A. The quality of pediatric burn scars is improved by early administration of basic fibroblast growth factor. *J Burn Care Res* 2006;27:333–338.
- Eto H, Suga H, Aoi N, Kato H, Doi K, Kuno S, Tabata Y, Yoshimura K. Therapeutic potential of fibroblast growth factor-2 for hypertrophic scars: upregulation of MMP-1 and HGF expression. *Lab Invest* 2012;92:214–223.
- Nissen NN, Polverini PJ, Gamelli RL, DiPietro LA. Basic fibroblast growth factor mediates angiogenic activity in early surgical wounds. *Surgery* 1996;119:457–465.