

A Rare Case of Caroli's Syndrome

Abstract

Caroli's syndrome is a rare autosomal recessive congenital disorder of the biliary tree characterized by intrahepatic bile duct dilation and hepatic fibrosis. Very few cases have been encountered in routine day-to-day practice. The patients usually present with features of cholangitis such as pain abdomen and jaundice. They may also present with features of chronic liver disease and portal hypertension. Very rarely, they may develop cholangiocarcinoma and present with jaundice, weight loss, and abdominal mass or ascites. Here, we report one such case of a young female who presented to us with features of cholangitis with sepsis and encephalopathy, which was finally diagnosed as Caroli's syndrome. The aim of presenting this case is to learn that even patients with common symptoms of pain abdomen and jaundice may be harboring some rare congenital disease like Caroli's syndrome, as in our case.

Keywords: Caroli's disease, Caroli's syndrome, cholangitis, chronic liver disease, intrahepatic bile duct dilatation

Introduction

Caroli's syndrome is a rare congenital disorder characterized by dilatation of intrahepatic bile ducts and hepatic fibrosis. Caroli's disease is a condition where there is only intrahepatic bile duct dilation without any fibrosis. The incidence is about 1 in 1,000,000 live births,^[1] with only about 200 cases reported in the literature. Caroli's disease usually presents with features of recurrent cholangitis with gallstones whereas Caroli's syndrome has features of chronic liver disease in addition to those of Caroli's disease. Caroli's syndrome is usually autosomal recessive in inheritance. Our patient had also presented with features of cholangitis and sepsis with encephalopathy and ascites, i.e., features of chronic liver disease. The aim of reporting the present case is that it is a rare cause of chronic liver disease and may be easily mistaken for cirrhosis of the liver.

Case Report

An 18-year-old female presented to our emergency department with complaints of abdominal distention and jaundice for 6 months, fever with chills for 7 days, and altered sensorium for 1 day. The abdominal distention and jaundice were gradual in

onset and were progressively increasing since it had started 6 months ago. There was no history of hematemesis or melena. Fever was high grade, continuous, and was not associated with rigors or chills. The patient became drowsy 1 day before admission. There was a history of jaundice in childhood when the patient was 4 years old, which had remitted on its own. There was no history of ethanol abuse. The patient had a history of secondary amenorrhea for the last 2 years. Before that, she had a history of irregular menses. On physical examination, the patient had a Glasgow Coma Scale of 9/15 (E3V2M4), pulse was 100/min, and regular and blood pressure was 110/70 mmHg. Pallor and icterus were present. Chest and cardiovascular system were within normal limits. Abdominal examination revealed hepatosplenomegaly with ascites. Reports of investigations done were as follows: hemoglobin – 6.2 g/dl, total leukocyte counts – 8000/c mm, and bilirubin – 6.1 mg/dl (direct – 2.9 and indirect – 3.2). Alkaline phosphatase was raised (235 IU/ml); aspartate transaminase and alanine transaminase were normal. Malaria card test was negative. Hepatitis B surface antigen, anti-hepatitis C virus, and HIV I and II were negative. Serum ceruloplasmin and urinary copper levels were normal; Kayser–Fleischer ring was absent. With the above findings,

**Satish Kumar Prasad,
Sameer Kumar Mehta,
Ankit Poddar¹**

Bihar Council of Medical Registration, Patna, Bihar,
¹Department Of Medicine, Tata Main Hospital, Jamshedpur, Karnataka Medical Council, Bengaluru, Karnataka, India

Submitted: 28-Mar-2020
Revised: 02-Dec-2020
Accepted: 02-Jun-2021
Published: 19-Jul-2021

Address for correspondence:

Dr. Sameer Kumar Mehta,
H. No. 170, First Floor,
New Sitaramdera, Agrico,
Jamshedpur - 831 009,
Jharkhand, India.
E-mail: sameer.mehta@tatasteel.com

Access this article online

Website:
www.ijabmr.org

DOI:
10.4103/ijabmr.IJABMR_160_20

Quick Response Code:



How to cite this article: Prasad SK, Mehta SK, Poddar A. A rare case of Caroli's syndrome. Int J App Basic Med Res 2021;11:195-7.

This is an open access journal, and articles are distributed under the terms of the Creative Commons Attribution-NonCommercial-ShareAlike 4.0 License, which allows others to remix, tweak, and build upon the work non-commercially, as long as appropriate credit is given and the new creations are licensed under the identical terms.

For reprints contact: WKHLRPMedknow_reprints@wolterskluwer.com

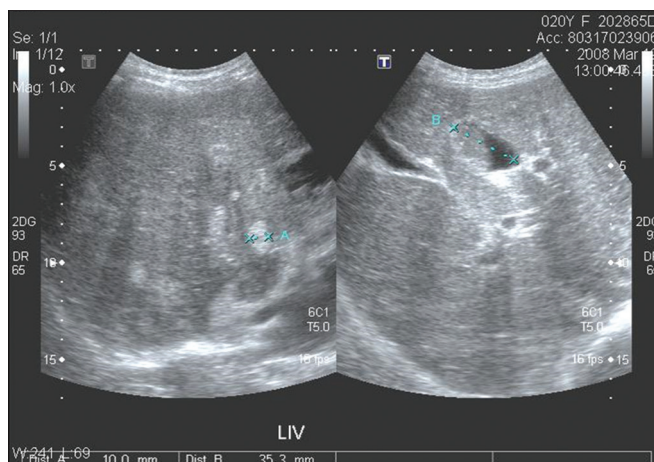


Figure 1: USG Abdomen - Showing multiple heterogenous lesions in both the lobes of liver

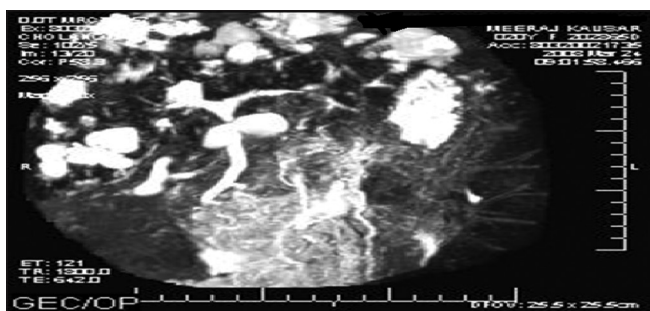


Figure 2: MRI ABDOMEN - multiple saccular and cystic lesions of varying sizes seen predominantly located peripherally and were continuous with the biliary radicles.

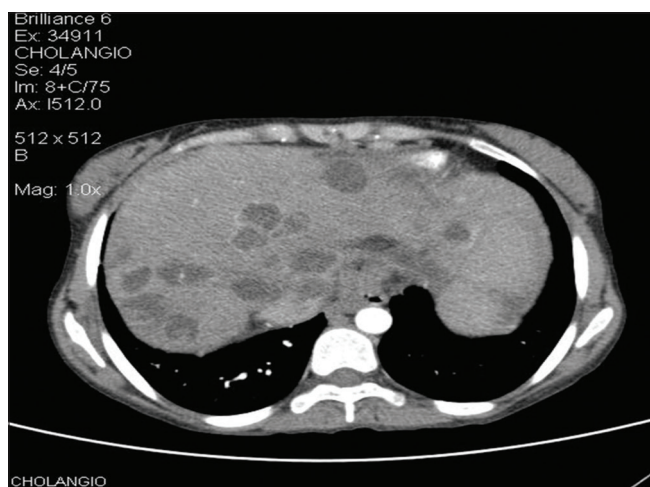


Figure 3: MRI abdomen-shows multiple hypoechoic lesions scattered in both lobes of liver. (A) Few lesions show a hyperechoic focus within it - which represents a vessel. These findings are s/o Caroli disease.

a provisional diagnosis of chronic liver parenchymal disease with portal hypertension with sepsis and hepatic encephalopathy was made. Ultrasound of the abdomen showed multiple heterogeneous lesions in both lobes of the liver [Figure 1], some hyperechoic and well defined, some cystic, and others ill defined. These features were

not suggestive of cirrhosis and so a differential diagnosis of peliosis hepatis or liver metastasis was considered. Magnetic resonance imaging (MRI) abdomen was done, MRI abdomen revealed hypertrophy of left lateral segment of the liver with mild enlargement of the right lobe of liver. Both lobes showed hyper-attenuating nodules which were suggestive of regenerative nodules. Multiple saccular and cystic lesions of varying sizes were seen, predominantly located peripherally, and were continuous with the biliary radicles [Figure 2]. The patient was treated with antibiotics and ursodeoxycholic acid and other supportive therapies. Ascites were present. Liver biopsy was done which showed hepatic fibrosis. MRI and liver biopsy findings confirmed the diagnosis of Caroli's disease with congenital hepatic fibrosis (Caroli's syndrome) with chronic liver disease and portal hypertension. The patient was treated with antibiotics and ursodeoxycholic acid and other supportive therapies. She improved with treatment, and the family was given the option for orthotopic liver transplantation, but the family members were unable to afford it. She was discharged in stable, but she was lost to follow-up after that.

Discussion

Caroli's disease and Caroli's syndrome are rare congenital disorders of the intrahepatic biliary tree, characterized by multiple segmental, saccular, or cystic dilatations of the intrahepatic bile ducts.^[2] Caroli's syndrome includes features of Caroli's disease along with congenital hepatic fibrosis. Caroli's syndrome is autosomal recessive in transmission, but Caroli's disease is sporadic.^[2] Caroli's syndrome is commonly associated with autosomal recessive polycystic kidney disease (ARPKD).^[3,4] Mutations in polycystic kidney and hepatic disease 1 on chromosome 6p21, which is the gene linked to ARPKD,^[3] have been identified in patients with Caroli's syndrome. In patients with ARPKD, CD can be found in 30% of cases.^[5] The incidence of Caroli's disease is approximately 1 in 1,000,000 population with a female preponderance. Caroli's syndrome is more common than Caroli's disease. The clinical features of Caroli's disease are usually characterized by recurrent episodes of cholangitis,^[6] cholelithiasis, biliary abscess, and septicemia. There may be features of chronic liver failure and portal hypertension due to hepatic fibrosis. There is an increased risk of cholangiocarcinoma^[7] (100 times that of the normal population). The laboratory findings may show leukocytosis and raised transaminase levels in cholangitis (as in our case). Dilatation of intrahepatic ducts may be evident in ultrasound (USG), computed tomography (CT), or MRI abdomen, and evidence of portal hypertension may be seen by the Doppler study. The demonstration of the communication between sacculae and bile duct is important for diagnosing Caroli's disease and differentiating it from polycystic liver disease where the sacculae does not communicate with the bile duct. The CT or MRI shows

the “central dot sign”-enhancing dots (representing portal radicles) [Figure 3] within the intrahepatic ducts.^[8] Liver biopsy may show hepatic fibrosis. Carbohydrate antigen 19-9 and carcinoembryonic antigen are done for screening of cholangiocarcinoma.^[9] The treatment consists of antibiotics for cholangitis, ursodeoxycholic acid to decrease the incidence of cholelithiasis,^[10] and endoscopic retrograde cholangiopancreatography or percutaneous transhepatic cholangiography for removal of stones. Liver transplantation is the only cure in case of refractory or chronic cholangitis, liver failure, or malignancy. Genetic counseling is important as the transmission is autosomal recessive. Complications include recurrent cholangitis with sepsis, choledocholithiasis, liver abscess, liver failure with portal hypertension, and cholangiocarcinoma.

Conclusion

Caroli's syndrome is a rare congenital disorder that comprises Caroli's disease (intrahepatic bile duct ectasia) and congenital hepatic fibrosis. Although it is a very rare cause of chronic liver disease (1 in 100,000), it should be suspected, particularly if the patient is young and has history and clinical features suggestive of recurrent cholangitis and other common causes of chronic liver disease and portal hypertension are excluded. As very few such cases have been reported in literature, we were prompted to publish this case. The importance of early diagnosis lies in the fact that the risk of cholangiocarcinoma is about 100 times greater in patients of Caroli's syndrome than in the general population and it can be picked up early if regular follow-up is done.

Declaration of patient consent

The authors certify that they have obtained all appropriate patient consent forms. In the form the patient(s) has/have given his/her/their consent for his/her/their images and other clinical information to be reported in the journal. The patients understand that their names and initials will not

be published and due efforts will be made to conceal their identity, but anonymity cannot be guaranteed.

Financial support and sponsorship

Nil.

Conflicts of interest

There are no conflicts of interest.

References

1. Tiotia R, Sharma M, Narayani V, Singh S, Dewan V, Deswal S, Tiotia A, Baghel S. Atypical presentation of caroli's syndrome: A case report. *Indian Journal of Case Reports*. 2019;76-8.
2. Yamaguchi T, Cristaudi A, Kokudo T, Uldry E, Demartines N, Halkic N. Surgical treatment for monolobular Caroli's disease – Report of a 30-year single center case series. *Biosci Trends* 2018;12:426-31.
3. Moslim MA, Gunasekaran G, Vogt D, Cruise M, Morris-Stiff G. Surgical management of Caroli's disease: Single center experience and review of the literature. *J Gastrointest Surg* 2015;19:2019-27.
4. Suchy FJ. Caroli's disease. Uptodate 2006 Version 14.1. 2006.
5. Kumar A, Akselrod D, Prikis M. Caroli disease revisited: A case of a kidney transplant patient with autosomal polycystic kidney disease and recurrent episodes of cholangitis. *Transplant Proc* 2019;51:541-4.
6. Liang JJ, Kamath PS. Caroli syndrome. *Mayo Clin Proc* 2013;88:e59.
7. Sato Y, Ren XS, Nakanuma Y. Caroli's disease: Current knowledge of its biliary pathogenesis obtained from an orthologous rat model. *Int J Hepatol* 2012;2012:107945.
8. Leelawat K, Sakchinabut S, Narong S, Wannaprasert J. Detection of serum MMP-7 and MMP-9 in cholangiocarcinoma patients: Evaluation of diagnostic accuracy. *BMC Gastroenterol* 2009;9:30.
9. Ros E, Navarro S, Bru C, Gilibert R, Bianchi L, Bruguera M. Ursodeoxy cholic acid treatment of primary Jonas hepatolithiasis in Caroli's syndrome. *Lancet* 1993;342:404-6.
10. Murray KF, Carithers RL Jr. AASLD practice guidelines: Evaluation of the patient for liver transplantation. *Hepatology* 2005;41:1407-32.