



Contents lists available at ScienceDirect

International Journal of Surgery Case Reports

journal homepage: www.casereports.com

Traumatic avulsion of tibialis anterior following an industrial accident: A case report

Aysha Rajeev^{a,*}, Mhiari McDonald^a, Mike Newby^b, Paul Patterson^a^a Department of Trauma and Orthopaedics, Queen Elizabeth Hospital, Gateshead NE9 6SX, UK^b Department of Radiology, Queen Elizabeth Hospital, Gateshead NE9 6SX, UK

ARTICLE INFO

Article history:

Received 14 April 2015

Received in revised form 22 June 2015

Accepted 27 June 2015

Available online 31 July 2015

Keywords:

Tibialis anterior

Traumatic

Avulsion

Whip stitch

ABSTRACT

INTRODUCTION: Rupture of the tibialis anterior tendon is uncommon and can occur spontaneously or following trauma. If suspected, it should be diagnosed promptly, enabling early surgical management and good restoration of function.

PRESENTATION OF CASE: A 48 year old male sustained a crush injury to his right foot when it became stuck in a vertical industrial fan at work. He attended A & E complaining of swelling of the dorsum of foot. On examination, there was tenderness at the base of the first metatarsal. X-ray revealed an avulsion fracture of the first metatarsal, and MRI showed rupture of tibialis anterior. The patient underwent surgical repair 10 days later, with post-operative management in a non-weight bearing, then weight bearing cast. X-ray at 8 weeks showed that the fracture had healed. The patient had a course of physiotherapy and was followed up at 6 months to assess pain and function.

DISCUSSION: Tibialis anterior rupture should be considered if the history is suggestive, and can be diagnosed clinically based on the triad of a 'pseudotumour' of the ruptured tendon, loss of tendon contour, and reduced dorsiflexion of the ankle. In our case, the avulsion fracture prompted further imaging to confirm the diagnosis and plan surgery. There are various operative techniques described in the literature. We used a whip stitch with anchors to reattach the tendon to the base of first metatarsal.

CONCLUSION: A prompt and early diagnosis of surgical repair of tibialis anterior tendon avulsion is important to ensure that the patients return to work as an industrial worker.

© 2015 The Authors. Published by Elsevier Ltd. on behalf of Surgical Associates Ltd. This is an open access article under the CC BY-NC-ND license (<http://creativecommons.org/licenses/by-nc-nd/4.0/>).

1. Introduction

Tibialis anterior rupture is an uncommon injury [1], with few cases previously documented in the literature [1–7]. It can occur either spontaneously or secondary to trauma [2–8]. The diagnosis should be suspected based on history of injury or risk factors [2,4,6,9], and can be made on clinical examination [1–3]. Ultrasound or MRI may be used to aid the diagnosis and ongoing management plan [7,11,12]. Surgical repair of the tendon following traumatic rupture has been shown to produce better outcomes than conservative management [1,10,13,14]. The key to treatment is early diagnosis to enable operative management, which gives the highest chance of regaining function [10,13,14]. This case describes a patient who presented following traumatic rupture of the tibialis anterior tendon, who received early surgical intervention, and aims to add to the available literature on this topic.

2. Case report

A 48 year old man who works in an insulation production factory was admitted to the emergency care department. He sustained a crush injury to his right foot at work. He fell from a step ladder when the ladder slipped on some spilled oil. His foot got sucked into an industrial vertical fan. He immediately complained of pain and swelling in the foot.

On examination there was swelling on the dorsum of the foot. There was tenderness in the base of first metatarsal. The distal foot pulses were palpable with no sensory or motor deficits. There was no pain on passive stretching, indicating no evidence of compartment syndrome. The X-ray examination of the foot revealed an avulsion fracture of the base of the first metatarsal (Fig. 1). He was admitted to the ward for elevation of his foot and ice application. An MRI scan of the foot was done to delineate the fracture, which showed avulsion of the attachment of tibialis anterior from the base of first metatarsal and medial cuneiform (Fig. 2).

The patient underwent surgical reconstruction of the tibialis anterior tendon on the tenth day after the swelling has improved. An anteromedial incision was made. The extensor retinaculum was opened. The tibialis tendon was found to be avulsed from the base

* Corresponding author.

E-mail address: asrajeev18@gmail.com (A. Rajeev).

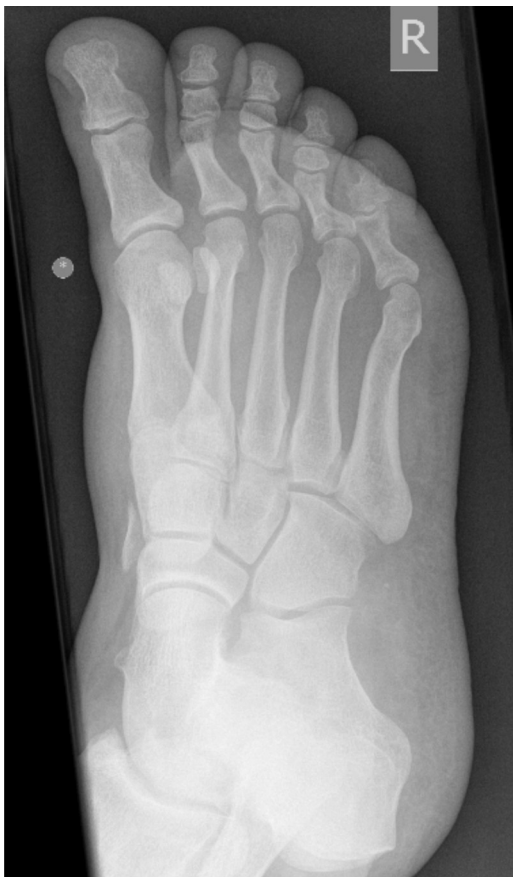

Fig. 1. Radiograph showing avulsion fracture from the medial cuneiform and base of first metatarsal.

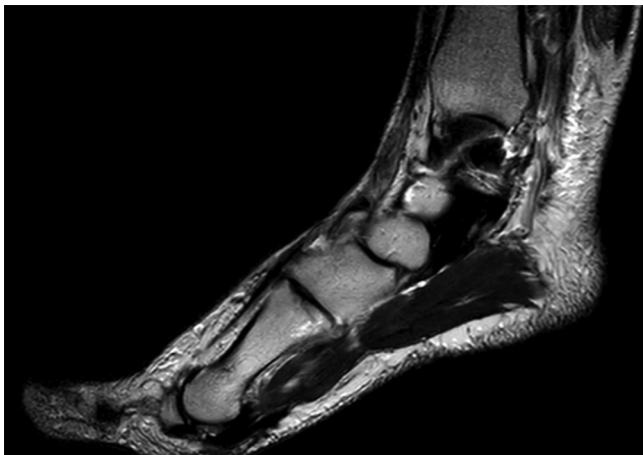

Fig. 2. MRI picture showing avulsion of tibialis anterior.

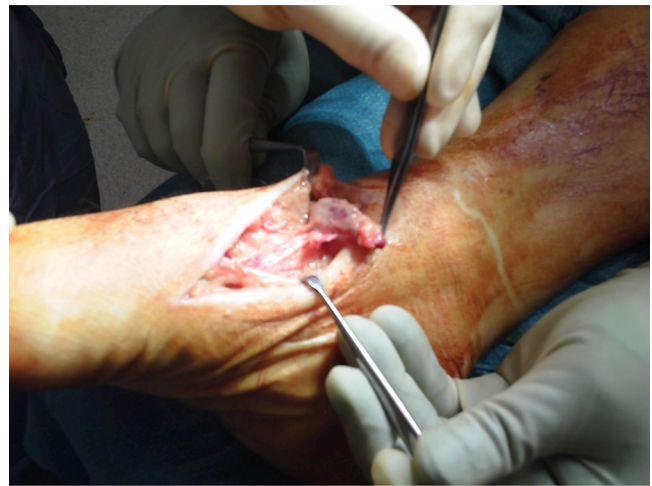

Fig. 3. Operative picture showing avulsion of tibialis anterior tendon.

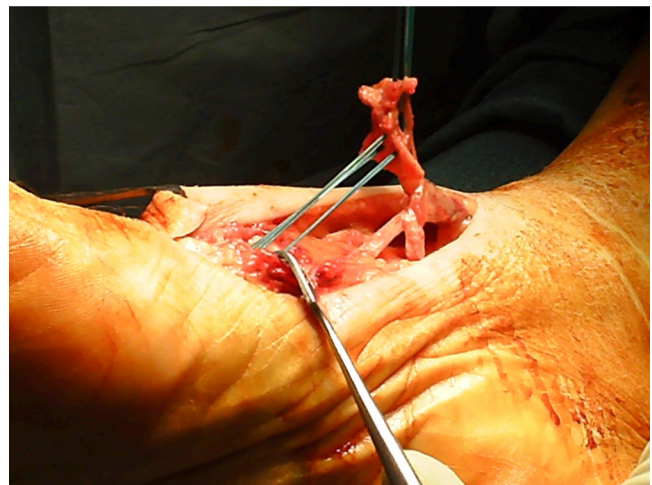


Fig. 4. Picture showing whip stitch being applied to the avulsed tendon end.

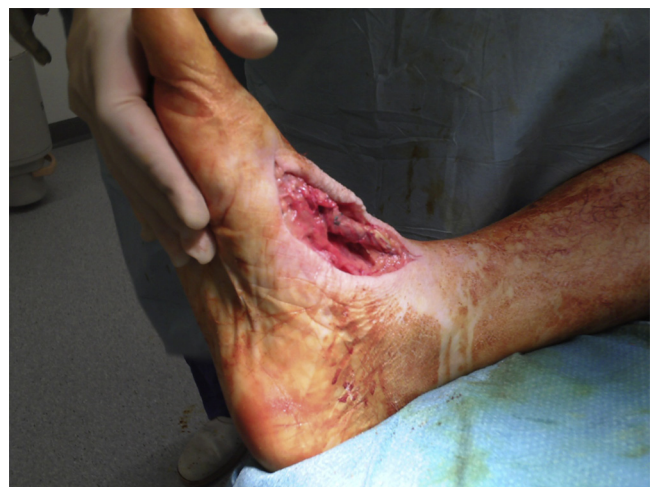

Fig. 5. Picture showing the final repair of the tendon after being attached to the base of first metatarsal.

of first metatarsal and medial cuneiform (Fig. 3). The tendon was mobilised and whip stitch applied to the avulsed end with ethibond sutures (Fig. 4). This was attached to the base of the first metatarsal with suture anchors and augmented with vicryl sutures, with his foot held in dorsiflexion (Fig. 5).

Post operatively, he was given a non-weight bearing, below knee cast, with his foot held in mild dorsiflexion for two weeks and converted in to a weight bearing cast afterwards for another four weeks. The patient was reviewed eight weeks after surgery. The plaster cast was removed. An X-ray taken showed that tendon has started to heal (Fig. 6). Physiotherapy was commenced to regain the

range of movements for foot and ankle. He was followed up again in 6 months. He was fully weight bearing with pain free movements of the foot and ankle and was discharged from the clinic.

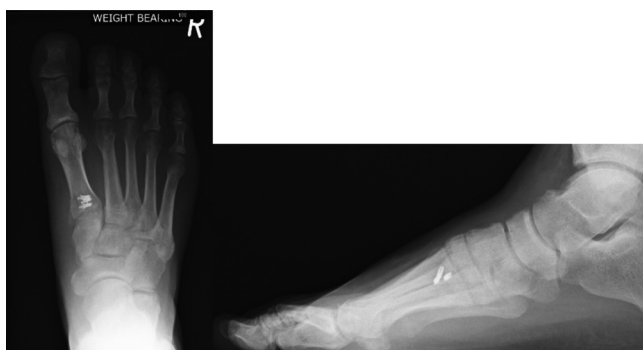


Fig. 6. Radiograph at 8 weeks showing the healed avulsion fracture.

3. Discussion

Tibialis anterior muscle occupies the anterior or the extensor compartment of the leg. It arises from the lateral condyle and upper half or two-thirds of the lateral surface of the shaft of the tibia, the adjoining part of the interosseous membrane, the deep surface of the fascia and from the intermuscular septum between it and the extensor digitorum longus. The fibres run vertically downward to form a tendon which passes through the most medial compartments of the superior and inferior retinacula. It is inserted into the medial and under surface of the first cuneiform bone, and the base of the first metatarsal bone. Tibialis anterior is supplied by the deep peroneal nerve (root value L4, L5). The tibialis anterior tendon is the primary dorsiflexor of the ankle joint. It also inverts the foot at the subtalar and midtarsal joints, and assists in holding up the medial arch of the foot [15]. Rupture can occur following penetrating or blunt trauma [5,7,8], or spontaneously [2–4,6,10]. Spontaneous ruptures tend to occur in males over 45 years of age [1,3,4], and more likely if there is existing tendinopathy [16]. Risk factors include rheumatic diseases, such as gout [16,17], systemic lupus erythematosus and rheumatoid arthritis [18], and diabetes mellitus [2,9]. An association with psoriasis has been documented [19], and cases following cortisone injection around the tarso-talar joint have also been recorded [20].

Given its uncommon nature, the diagnosis may not initially be considered, leading to a delay in management and a poorer outcome for the patient [21]. However, diagnosis can be made on clinical examination at initial presentation [1,10]. Patients often complain of pain or swelling to the dorsum of the foot, and may describe their foot ‘slapping’ when walking [2,3]. The clinical triad of a “pseudotumour” at the anteromedial aspect of the ankle, loss of the tendon contour over the ankle, and weakness of dorsiflexion of the foot [10], is highly suggestive of tibialis anterior rupture. The use of extensor hallucis longus and extensor digitorum to dorsiflex the ankle, causing hyperextension of the hallux and toes, can also be observed. Differential diagnosis includes anterior tibial syndrome or a peroneal nerve palsy, which should be ruled out with a thorough history and examination, including neurological assessment. Additional imaging can aid or confirm diagnosis [11,12]. In this case, an X-ray demonstrating an avulsion fracture of the 1st metatarsal raised suspicion of a possible tendon injury. Unlike the 5th metatarsal, avulsion fractures to the 1st metatarsal are rare due to its short, wide structure [22], and their presence should prompt further imaging for tendon damage [22]. MRI scanning helps establish the extent of the rupture and associated fractures [11,12], and aids surgical planning. Ultrasound can also be used to confirm the diagnosis [7].

There is insufficient evidence to support an optimal surgical technique for repair [1,10,14], but research has demonstrated that early surgery improves functional outcome [10,14]. Delayed

diagnosis, and therefore, delayed surgery often results in a more complex repair [9,10], which may require additional grafting [9] using autogenous or allografts. Surgical repair more than 3 months after initial injury has a reduced success rate [10,14,20]. In this group, and in elderly patients with extensive comorbidities who are unsuitable for operative management, the use of an ankle-foot orthosis, bracing, and shoe adaptations have been advocated [6,14], with some success recorded [6,14], but these may lead to suboptimal function long term [14,23].

In this case, the gentleman was promptly diagnosed, and the operation was carried out 10 days following the injury. The conversion from non-weight bearing to weight bearing cast post-operatively is slightly shorter than in previously documented cases, but in this case it was technically possible to reattach the tendon directly onto bone, without the need for tendonplasty or graft insertion, thus allowing quicker return to full weight bearing [9,10]. Post-operative immobilisation in plaster has been shown to have favourable results [24], and allows early weight bearing as opposed to other methods of immobilisation, such as the use of external fixators [24].

4. Conclusion

Tibialis anterior tendon rupture remains a relatively uncommon injury, but should be considered if there is a suggestive history following trauma or known risk factors. Diagnosis can be made clinically, and, as demonstrated in this case, an avulsion fracture of the 1st metatarsal should raise suspicion of a tendinous injury and prompt further investigation. Additional imaging with MRI scanning is beneficial for planning surgery. This case demonstrates a prompt diagnosis and early surgical repair, and highlights the importance of these factors in ensuring restoration of function and return to normal activity, particularly in younger patients.

Conflict of interest

None.

Funding

None.

Ethical approval

Ethical approval has been got from the hospital trust.

Consent

Informed consent has been obtained.

Guarantor

The author takes full responsibility for the work.

Author contributions

Aysha Rajeev has contributed to study concept, design data collection, data analysis and writing of the paper.

Mhiari McDonald—Preparation of case report.

Mike Newby—Review of the paper.

Paul Patterson contributed towards the management and follow up of the patient.

References

- [1] T. Kausch, J. Rütt, Subcutaneous rupture of the tibialis anterior tendon: review of the literature and a case report, *Arch. Orthop. Trauma Surg.* 117 (1998) 290–293.
- [2] R.R. Miller, K.T. Mahan, Closed rupture of the anterior tibial tendon: a case report, *J. Am. Podiatry Med. Assoc.* 88 (1998) 394–399.
- [3] G. Van Acker, F. Pinggen, J. Luitse, C. Goslings, Rupture of the tibialis anterior tendon, *Acta Orthop. Belg.* 72 (2006) 105–107.
- [4] L.A. Didomenico, K. Williams, A.F. Petrola, Spontaneous rupture of the anterior tibial tendon in a diabetic patient: results of operative treatment, *J. Foot Ankle Surg.* 47 (5) (2008) 463–467.
- [5] M. Constantinou, A. Wilson, Traumatic tear of tibialis anterior tendon during a Gaelic football game: a case report, *Br. J. Sports Med.* 38 (2004) e30.
- [6] B.J. Dooley, P. Kudelka, M.B. Menelaus, Subcutaneous rupture of the tendon of tibialis anterior, *J. Bone Joint Surg.* 62-B (1980) 471–472.
- [7] M.E. Rodrigues, A. Periera, B. Alpoim, J.M. Geada, Traumatic rupture of the tibialis anterior tendon: a case report, *Rev. Bras. Ortop.* 48 (3) (2013) 278–281.
- [8] R. Din, L. Therkilsden, Rupture of tibialis anterior associated with a closed midshaft tibial fracture, *J. Accid. Emerg. Med.* 16 (1999) 4598.
- [9] E. Palmanovich, Y.S. Brin, L. Laver, D. Ben David, S. Massrawe, M. Nyska, I. Hetsroni, Chronic tibialis anterior tendon tear treated with an Achilles tendon allograft technique, *Orthopedics* 36 (11) (2013) 850–853.
- [10] V.J. Sammarco, G.J. Sammarco, C. Henning, S. Chaim, Surgical repair of acute and chronic tibialis anterior ruptures, *J. Bone Joint Surg. Am.* 91 (2) (2009) 325–332.
- [11] R.A. Gallo, B.H. Kolman, R.H. Daffner, R.L. Sciulli, C.C. Roberts, P.J. DeMeo, MRI of tibialis anterior tendon rupture, *Skeletal Radiol.* 33 (2004) 102–106.
- [12] N.J. Khoury, G.Y. el-Khoury, C.L. Saltzman, E.A. Brandser, Rupture of the anterior tibial tendon: diagnosis by MR imaging, *AJR Am. J. Roentgenol.* 167 (1996) 351–354.
- [13] G.G. Markarian, A.S. Kelikian, M. Brage, T. Trainor, L. Dias, Anterior tibialis tendon ruptures: an outcome analysis of operative versus nonoperative treatment, *Foot Ankle Int.* 19 (1998) 792–802.
- [14] B.M. Trout, G. Hosey, S.J. Wertheimer, Rupture of the tibialis anterior tendon, *J. Foot Ankle Surg.* 39 (2000) 54–58.
- [15] S. Standing, *Gray's Anatomy-The Anatomical Basis of Clinical Practice*, 40th ed., Churchill Livingstone, New York, 2008, pp. 1417–1418.
- [16] A. Patten, W.K. Pun, Spontaneous rupture of the tibialis anterior tendon: a case report and literature review, *Foot Ankle Int.* 21 (2000) 697–700.
- [17] J.T. Jerome, M. Varghese, B. Sankaran, S. Thomas, S.K. Thirumagal, Tibialis anterior tendon rupture in gout—case report and literature review, *Foot Ankle Surg.* 14 (2008) 166169.
- [18] S. Otte, H.M. Klinger, F. Lorenz, T. Haerer, Operative treatment in case of a closed rupture of the anterior tibial tendon, *Arch. Orthop Trauma Surg.* 122 (2002) 188–190.
- [19] U. Aydingöz, O. Aydingöz, Spontaneous rupture of the tibialis anterior tendon in a patient with psoriasis, *Clin. Imaging.* 26 (2002) 209–211.
- [20] G.J. Velan, D. Hendel, Degenerative tear of the tibialis anterior tendon after corticosteroid injection—augmentation with the extensor hallucis longus tendon, case report, *Acta Orthop. Scand.* 68 (1997) 308–309.
- [21] J.T. Jerome, M. Varghese, B. Sankaran, K. Thirumagal, Tibialis anterior rupture: a missed diagnosis, *Foot Ankle Online J.* 3 (9) (2010) 2.
- [22] T.M. T. urakami, K. Okamura, S. Harada, M. Setojima, Y. Ikushiba, Y. Miyamoto, S. Li, M. Yamada, Avulsion fracture of peroneus longus at the first metatarsal insertion: a case report, *Br. J. Sports Med.* 38 (2004) e13.
- [23] T.J. Ouzounian, R. Anderson, Anterior tibial tendon rupture, *Foot Ankle Int.* 16 (1995) 406–410.
- [24] B. Lefebvre, J. Beldame, S. Bertiaux, N. Biga, Open and subcutaneous recent tibialis anterior tendon ruptures: does postoperative immobilization method influence outcome, *Orthopaedics Traumatol. Surg. Res.* 97 (2) (2011) 211–216.

Open Access

This article is published Open Access at sciedirect.com. It is distributed under the [IJSCR Supplemental terms and conditions](#), which permits unrestricted non commercial use, distribution, and reproduction in any medium, provided the original authors and source are credited.