

Surgical Approaches to Basilar Apex Aneurysms: An Illustrative Review

Abstract

Surgical management of basilar apex aneurysms remains one of the most challenging areas in neurovascular surgery. Technical demands of treating these aneurysms have inspired several generations of neurosurgeons to push the limitations of technical achievement. Advances in neuroanesthesia, cerebral protection paradigms, and critical care management have enhanced surgical outcomes of these lesions. Several approaches have been described to reach these lesions from anterolateral or lateral corridors. Each surgical approach has its own advantages and limitations and should be chosen for each patient according to the aneurysm's position, projection, parent arteries, and perforators. In this review, we will discuss pros and cons of the common approaches to these aneurysms with description of the important steps of each surgical procedure.

Keywords: *Aneurysm, basilar apex, clipping, microsurgery*

Introduction

Basilar apex aneurysms (BAAs) comprise about half of posterior circulation aneurysms. Their location, proximity to important perforators, and anatomical complexity make these aneurysms one of the most difficult to be treated through either endovascular route or surgery. To achieve optimal surgical results, a combination of excellent technical skills, superb knowledge of operative anatomy, and acquaintance with operative nuances is of paramount importance.

To secure these aneurysms by clipping, different approaches have been described in the literature. Although there are reports of the ventral route (i.e., transclival) and transthoracic ventricular approach to the BAA, the two main approaches for these aneurysms are the subtemporal approach and the transsylvian approach and their variations. In our practice, we employ both approaches but are increasingly relying on a new modification or hybrid approach. We emphasize the importance of tailoring the operation to the patient's particular anatomy.

The pure transsylvian approach has several advantages: neurosurgeons are familiar with this approach because it is used for most of the common aneurysms and tumors. Proximal control is straightforward.

This is an open access journal, and articles are distributed under the terms of the Creative Commons Attribution-NonCommercial-ShareAlike 4.0 License, which allows others to remix, tweak, and build upon the work non-commercially, as long as appropriate credit is given and the new creations are licensed under the identical terms.

For reprints contact: reprints@medknow.com

Exposure of both P1 segments for temporary trapping is uncomplicated. Wide exposure is possible. The transsylvian exposure also has disadvantages: Exposure for posteriorly located perforators is so difficult. Inspection of distal side of clip blade is difficult. Technical features make the treatment of directly anteriorly or directly posteriorly projecting aneurysms very difficult. The subtemporal approach offers the surgeon many advantages: proximal control is easy. The lateral view facilitates the perforator dissection. Tentorial division allows exposure the one-third upper of the clivus for low-lying bifurcations. Fenestrated clips can be placed with excellent visualization of the thalamoperforators. Exposure and clipping of anteriorly or posteriorly directed aneurysm is more possible than the transsylvian approach. The subtemporal exposure also has disadvantages: the field is narrow. Access to the proximal contralateral P1 for temporary trapping is poor. Temporal lobe can be injured in fresh subarachnoid hemorrhage (SAH) in poor grade or obese patients. Cranial nerve III palsy often occurs postoperatively (usually transient). Controlling the intraoperative bleeding can be difficult.

Considering the advantages and disadvantages of each approach allows a more rational design of operative strategies for each patient. In this illustrative review, we first briefly review the surgical anatomy

Jiangbo Li,
Amir
Azarhomayoun¹,
Mohsen
Nouri^{1,2}, Ittichai
Sakarunchai³,
Yasuhiro Yamada⁴,
Kei Yamashiro⁴,
Yoko Kato⁴

Department of Neurosurgery, Affiliated Peace Hospital of Changzhi Medical College, Changzhi, Republic of China, ¹Division of Cerebrovascular Surgery, Gundishapour Academy of Neuroscience, Ahvaz, Iran, ²Stone Lion Neuro Clinic, Jamaica Hospital Medical Center, New York, USA, ³Department of Surgery, Division of Neurosurgery, Prince of Songkla University, Songkhla, Thailand, ⁴Department of Neurosurgery, Fujita Banbuntane Stroke Center, Banbuntane Hospital, Fujita Health University, Aichi, Japan

Address for correspondence:

*Prof. Yoko Kato,
Department of Neurosurgery,
Fujita Banbuntane Stroke
Center, Banbuntane Hotokukai
Hospital, Fujita Health
University, Aichi, Japan.
E-mail: kyoko@fujita-hu.ac.jp*

Access this article online

Website: www.asianjns.org

DOI: 10.4103/ajns.AJNS_76_16

Quick Response Code:



How to cite this article: Li J, Azarhomayoun A, Nouri M, Sakarunchai I, Yamada Y, Yamashiro K, *et al*. Surgical approaches to basilar apex aneurysms: An illustrative review. *Asian J Neurosurg* 2020;15:272-7.

Submitted: 20-Feb-2016 **Accepted:** 23-Mar-2017

Published: 29-May-2020

of the BAAs and then discuss pros and cons of the most common approaches.

Anatomy

The technical challenges of clipping BAAs are related to the complex anatomy inside and around the interpeduncular cistern and the depth of dissection through narrow corridors that is required to secure these lesions. The subarachnoid space within the interpeduncular cistern is enclosed by the clivus and posterior clinoid process anteriorly, the medial sides of the temporal lobes and tentorial edges laterally, the cerebral peduncles posteriorly, and the mammillary bodies and posterior perforated substance superiorly. The terminal basilar artery has a normal diameter of 2.7–4.3 mm and lies 15–17 mm posterior to the posterior side of the internal carotid arteries (ICAs).^[1] This proximity to the ICA provides a basis for seeking a transsylvian approach to these aneurysms. At a proximal point to its bifurcation, the basilar artery gives rise to the bilateral superior cerebellar arteries (SCAs), which may be duplicated. The dentate nuclei are irrigated by these vessels.

The posterior cerebral arteries (PCAs) originate at the basilar bifurcation. They usually have 2–3 mm diameter. The size of the segment of the PCA from the basilar bifurcation to the junction with the posterior communicating artery (PComA) (i.e., P1 segment) depends on the extent to which the PComA contributes to the blood flow of the distal PCA. A fetal-type PCA implies that the P1 is a vestigial band, with all PCA blood flow originating from the carotid artery.

Visualization and preservation of the thalamoperforating arteries is an essential step during the surgery. These critical perforators arise from the posterior side of the basilar trunk, the proximal P1 segment, and the PComA. The cranial nerve most intimately associated with this region is the oculomotor nerve that traverses the space between the PCA and the SCA within the interpeduncular cistern.

The membrane of Lilliequist is a thick layer of arachnoid that anchors from the mammillary bodies superiorly and extends anteriorly and inferiorly before folding posteriorly to form the roof of the prepontine cistern. The basilar apex can be located above, below, or at the level of the dorsum sellae^[2] and is very important for selecting the approach. Sonlanmasının and Değişkenliği showed five different branching patterns of the basilar artery in 170 human cadaveric brains which may complicate surgery at the basilar tip:^[3] bifurcation (82.35%), trifurcation (5.29%), quadrifurcation (5.88%), pentafurcation (3.52%), and nonfurcation (2.94%).^[3] These variations need to be taken into consideration before selecting the surgical approach.

Transsylvian Approaches

The transsylvian exposure provides excellent visualization for aneurysms with necks at the level between the middle

depth of the sella turcica and a line 1 cm superior to the posterior clinoid process. Aneurysms with necks lying inferior to the midsellar level are better approached through the subtemporal corridor or a “half-and-half” conversion with tentorial division.^[4] Extremely high aneurysms are difficult to approach but are probably best tackled through a transsylvian approach above the carotid bifurcation. The orbitozygomatic osteotomy is helpful when tackling high aneurysms because the surgeon’s line of sight can angle more superiorly. Several maneuvers, including drilling the posterior clinoid for low-lying lesions, have been described to tackle anatomic problems encountered during transsylvian exposure.^[2] A transcavernous approach has also been described.^[5]

Orbitozygomatic approach

A helpful supplement to the transsylvian approach is the orbitozygomatic osteotomy [Figure 1].^[6] The initial incision is similar to the standard pterional craniotomy.^[7] The scalp flap and temporalis muscles are reflected anteriorly and inferiorly, respectively. The dissection continues anteriorly to expose the orbital rim, malar eminence, and zygomatic arch. Bur holes are placed in the temporal bone over the zygoma and pterion. A pterional craniotomy is performed. The periorbita is dissected with a No. 1 Penfield dissector. A reciprocating saw is used to perform the orbital and zygomatic osteotomies.^[8] The first osteotomy is an oblique cut across the zygomatic root. The second and third cuts divide the zygoma just superior to the level of the malar eminence. The third cut extends from the inferior orbital fissure. Care is taken with thin retractors to protect the periorbita. The dura is elevated from the anterior wall of the temporal fossa and the orbital roof. The fourth cut divides the superior orbital rim and roof and is begun 1–2 mm lateral to the supraorbital canal. The last two cuts connect the superior and inferior orbital fissures. This is performed after the inferior orbital fissure is identified by direct vision or palpation of the infratemporal fossa with a No. 4 Penfield dissector. Reciprocating saw blade is engaged in the upper end of the fissure, and a shortcut is made to the edge of the previously made notch in the temporal fossa. The final

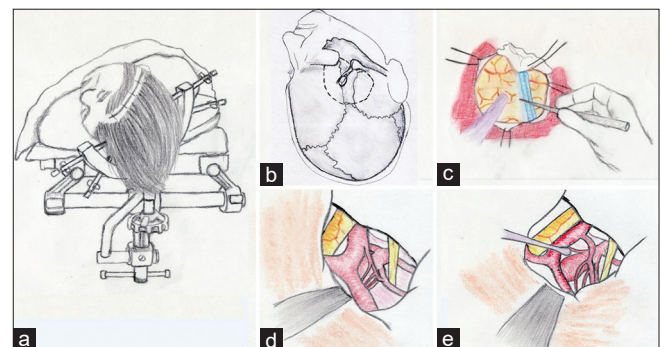


Figure 1: Orbitozygomatic craniotomy for basilar tip aneurysms. Patient positioning and incision (a) and place of burr holes (b) are demonstrated, Sylvian fissure is dissected (c) and the aneurysm is encountered (d), cisterns are opened by microsurgical techniques to expose the aneurysm (e). Please refer to the text for more technical details

cut extends from the lateral margin of the superior orbital fissure to join the fifth cut. Removal of additional bone at the skull base decreases retraction and increases the angle of view superiorly toward the basilar apex.^[9] After the bony removal is accomplished, the dura is opened, the sylvian fissure is widely split, and the microsurgical dissection proceeds similarly to the traditional transsylvian approach.

The relationship between the aneurysm origin and the posterior clinoid process can help guide decisions regarding the surgical approach.^[10] High- or low-lying aneurysm necks are defined as occurring, respectively, higher or lower than 5 mm.^[11] Some neurosurgeons prefer an orbitozygomatic craniotomy to approach normal- or high-lying aneurysms.^[12] In those that are low lying, resection of three bony obstacles (i.e., the anterior clinoid process, the posterior clinoid process, and the dorsum sellae) can be advantageous.^[13]

Pretemporal transzygomatic transcavernous approach

Krisht and Kadri^[14] described the use of the pretemporal transzygomatic transcavernous approach to treat BAAs surgically [Figure 2]. They defined BAAs as highly complex if they were larger than 2 cm, very dysmorphic, or wide based, had a low bifurcation, were posterior or posteroinferior projecting, possessed dolichoectatic changes of the basilar apex compromising the surgical view, or were associated with additional aneurysms affecting the surgical view.^[15] The technique begins with an extended pterional craniotomy with temporal extension. This allows for an inferior reflection of the temporalis muscle. After the craniotomy, the temporal squama is drilled flush within the middle fossa floor. The sphenoid wing is drilled from its lateral to its medial extent until the anterior clinoid process is reached. The anterior clinoid process is exposed and removed. During this step, the meningo-orbital artery is exposed, coagulated, and cut and the posterior third of the lateral and superior orbital wall is removed while preserving the periorbita.

The meningo-orbital artery is the site where the dissection plane between the dura propria of the temporal lobe and the lateral wall of the cavernous sinus can begin.^[16]

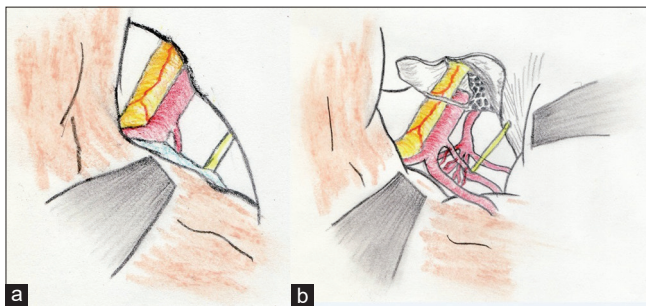


Figure 2: Pretemporal transzygomatic transcavernous approach (a), removal of the anterior clinoid process and better exposure of the basilar artery (b), please refer to the text for more technical details

The subarachnoid dissection is similar to that presented for the transsylvian approach.

The anterior clinoid process removal involves detaching its three bony connections:^[17] the sphenoid bone over the superior orbital fissure, the roof of the optic canal, and the optic strut, usually performed with a 2–3 mm diamond drill bit.

The dura is cut in a curved T-shaped fashion, with the vertical arm of the T following the sphenoid wing indentation.^[18] The incision extends all the way to the entrance of the third nerve and into the oculomotor trigone. This allows for visualization of the third nerve both intradurally and extradurally and allows for increased mobilization of the nerve for exposure of the interpeduncular fossa and region of the posterior clinoid process. Furthermore, releasing the nerve from the dural attachment makes it more tolerant for the mobilization.^[19]

The third cranial nerve is identified lateral to the anterior clinoid process and followed to the level of its exit through the dura at the level of the oculomotor trigone. The fourth nerve is also identified in its epidural course as it crosses over the oculomotor nerve. Adequate exposure of the course of the oculomotor nerve is better achieved if this plane is dissected along its posterolateral extension over the V1 and V2 segments of cranial nerve V, to the level of the ganglion. The space between V1 and V2 is a common area of bleeding controlled with Surgicel (Ethicon, Inc., Somerville, NJ, USA) or Tisseel VH fibrin sealant (Baxter AG, Vienna, Austria).

Pterional approach through the extended lateral corridor

The main limitation of the subtemporal approach is the limited ability to see the contralateral P1 and its medial perforators. In contrast, the transsylvian approach is limited by poor visualization of the posterior perforators of the basilar artery. In an effort to combine the advantages of the subtemporal and transsylvian approaches while minimizing the limitations of each approach, Ciacci *et al.* have developed a modified approach, the pterional approach through the extended lateral corridor [Figure 3] that was a hybrid of “half-and-half” approach. This extended lateral exposure has eliminated most of the risks and liabilities of the pure transsylvian and subtemporal approaches and has many advantages. It is performed from the surgeon’s dominant side, which facilitates surgery due to lateral dissection plane and clipping. Wide opening of the sylvian fissure is possible. The surgical field is centered on cranial nerve III. Mesial temporal lobe structures are elevated out of the incisura to the level of the cerebral peduncle. Posterior dissection is performed behind and below ipsilateral P1, not through the neck. The initial clip is fenestrated with a very small blade to close the contralateral neck. The final clip is a short, conventional clip to eliminate residual neck filling through the fenestration.

For this approach, the patient is positioned as for a pterional craniotomy. The head is rotated no more than 30° away from the operative side to minimize the temporal lobe encroaching on the incisura. A frontotemporal scalp incision is extended down to the zygoma. The scalp is incised to the subgaleal plane but not through the temporalis fascia. As the scalp is reflected anteriorly in the subgaleal plane, we use an interfacial technique to identify the fat pad containing the frontal branch of the facial nerve. This tissue is dissected away from the temporalis fascia for minimizing retraction on the nerve. The temporalis muscle is divided along the zygoma, the anterior temporal squama, and the superior temporal line and reflected posteriorly, as described by Heros and Lee.^[12] These maneuvers minimize the obstruction of the view along the skull base and usually obviate the need for a skull base approach such as the orbitozygomatic resection. The craniotomy is performed with burr holes in the keyhole, at the posterior exposure of the superior temporal line, and at the root of the zygoma. A powerful craniotome is used to connect the burr holes and to extend the flap anteriorly to the mid-supraorbital ridge, yielding a rectangular free bone flap. An extensive subtemporal craniectomy is then performed to provide generous exposure of the anterior temporal tip. A drill and rongeurs are used to remove the inner table and thin the diploe of the frontal bone from the sphenoid ridge to the anterior extent of the flap. This provides additional exposure along the skull base and limits frontal lobe retraction. The sphenoid ridge is then drilled down to a degree that creates a continuous, unobstructed view along the skull base from the middle fossa floor to the floor of the frontal fossa. This extensive bony resection is essential to providing an unobstructed view of the basal cisterns while minimizing the need for brain retraction.

Subtemporal Approach

Most BAAs which were treated by Drake were treated with a subtemporal approach [Figure 4]. As outlined

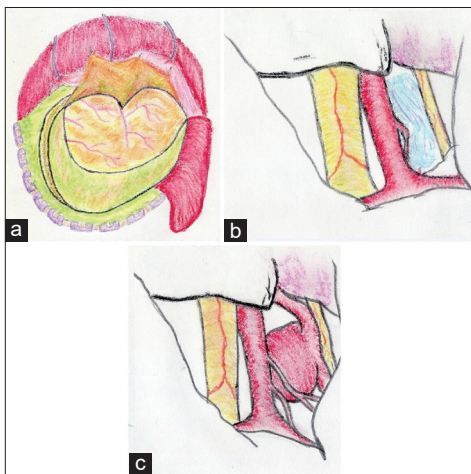


Figure 3: The pterional approach through the extended lateral corridor (a), surgical view before (b) and after (c) aneurysm exposure. Please refer to the text for more technical details

previously, several situations make this approach preferable to the transsylvian route. A right-sided approach usually is preferable to prevent damaging the dominant temporal lobe. Several conditions make a left-sided approach more reasonable. A left cranial nerve III palsy or right hemiparesis favors a left-sided approach to avoid injury to the right cranial nerve III and cerebral peduncle. Occasionally, a tilt of the basilar apex can elevate one P1 segment significantly above the other. If the left PCA is significantly higher than the right PCA, a right-sided approach could risk trapping the left PCA in the blades.

Cerebrospinal fluid (CSF) drainage is paramount for the success of this approach. When the subtemporal approach is used, we place a lumbar drain routinely in the operating room before positioning the patient. CSF drainage is particularly important after SAH. When the Mayfield fixation device is positioned, the surgeon should always consider the possibility of conversion to a transsylvian approach; the ability for doing this work without re-draping is obviously advantageous. After the Mayfield head frame has been positioned with one pin over the forehead and two pins over the occiput, we placed the patient on the side, and we allowed the dependent arm to rest in a sling. We use gel pads to protect the axilla. The chest area, hips, and legs are appropriately padded and taped to the operating table. After the patient is well positioned, we elevate the head slightly and then tilt the vertex 10–20° below horizontal to allow the temporal lobe to fall away from the middle fossa floor, minimizing retraction, and maximizing the working space.

For unruptured aneurysms, we use a straight incision, which extends 10 cm up from a point 1 cm anterior to the tragus. The craniotomy is then based over the zygomatic root and has a diameter of about 3.5 cm. For patients with recent SAH, we favor a larger craniotomy. We use a reverse horseshoe incision and then perform a craniotomy as well as anterior craniectomy. The wider

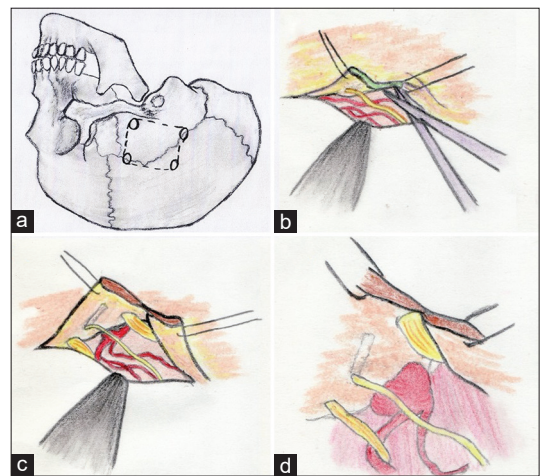


Figure 4: Location of burr holes for a subtemporal craniotomy (a), cutting the edge of tentorium (b), dissecting the trochlear nerve off the tentorium (c), and final exposure of the aneurysm (d). Please refer to the text for more technical details

exposure allows inferior temporal gyrus resection if it is needed for further exposure. Resection of bone down to the floor of the middle fossa minimizes the need for brain retraction. After the craniotomy, the dura is opened in a cruciate fashion such that the inferior limb can be secured inferiorly to minimize extradural bleeding and maximize exposure. Hyperventilation, diuresis, and lumbar drainage often result in sufficient brain relaxation to maneuver subtemporally. In patients with a recent hemorrhage, these maneuvers may not be sufficient. In this situation, we have frequently resected the inferior temporal gyrus with the fusiform and parahippocampal gyri. We did not notice any increased morbidity associated with this method, and the resulting exposure is usually excellent. When resorting to this resection, we have found it helpful to leave the medial pia-arachnoid tissue to serve as an anchor for the retractor. When the uncus is elevated, cranial nerve III elevates with the uncus. To further enhance exposure, we place a tentorial stitch as advocated by Drake. This stitch is placed posterior to the dural insertion of cranial nerve IV. For an extremely low-lying aneurysm, splitting the tentorium may be necessary. Bleeding can be minimized by aggressively coagulating the tentorium over the incision site and by placing small pieces of cotton in the dural leaflets with a nerve hook.

After adequate exposure is achieved, the arachnoid between cranial nerve III and the incisura should be dissected. The next structure to be identified is the SCA as it curves back around the cerebral peduncle in the ambient cistern. The surgeon then follows the SCA medially toward the basilar artery. This route ensures that proximal control will be achieved before encountering the sac. The basilar artery can be cleared anteriorly and posteriorly for a temporary clip. The inferior margin of the ipsilateral P1 is then identified, and dissection is carried across the anterior side of the basilar artery to the contralateral P1. Mistaking the contralateral SCA for the P1 can lead to occlusion of the contralateral P1 and its perforators with a clip. The SCA is differentiated from the PCA by knowing that the PCA is usually larger and invested with thicker tissue, whereas the SCA is usually red. This can be confirmed by continuing the dissection across to the contralateral P1–P2 junction and identifying the PComA and cranial nerve III passing between the SCA and the P1.

After the anterior side of the basilar artery and both P1 origins have been identified and dissected free of arachnoid adhesions and blood, attention is turned to the posterior side of the aneurysm complex. Perforators emanating from the posterior wall of the basilar artery are often adherent to the neck and must be dissected free. This dissection is best started at the ipsilateral P1 and carried to the contralateral P1. The goal of this dissection is to create a space for safe application of an aneurysm clip. Clip length should match the neck length as closely as possible because excessively long clips risk occluding medial perforators emanating

from the contralateral P1. Short-bladed fenestrated clips are almost always used, with the P1 included in the fenestration. Conventional clips are appropriate for apex aneurysms projecting straight anteriorly or posteriorly. Although anteriorly projecting aneurysms may obscure the contralateral P1, the contralateral P1 occasionally can be visualized during the final stage of clip closure. Control of the microscope with the mouthpiece allows subtle maneuvering that can enhance visualization on both sides of the aneurysm during clip closure. The advantages of the subtemporal approach include the easing of visualization of posterior perforators and the easing of proximal control. The disadvantages of the approach are difficult access to the contralateral P1, which may be important for trapping or for inspection of the P1 perforators, the narrow field of view, and difficulty with using the technique when the brain is swollen after SAH.

Conclusion

Achieving successful outcomes for patients with simple and complex aneurysms of the basilar apex requires thoughtful diagnostic workup, careful preparation and development of a strategic plan, and a detailed microsurgical understanding of normal neuroanatomy and patient's specific anatomic variables. It is critical that multidisciplinary teams evaluate these patients. These aneurysms should not be treated at centers that are not identified as cerebrovascular centers, with all that entails. Our knowledge of these lesions and complications of therapy has taken us to a point to analyze each patient and make decisions highly individualized. Critical variables for decision-making include patient age and therefore years of exposure to recurrence, clinical grade, neck width, size of the aneurysm, associated thrombosis, and anatomical variances.

Finally, if a surgical strategy is determined to be optimum for an individual patient, enormous concentration must be focused on every detail of the operation since the margin of error is nonexistent in these surgeries. Furthermore, the surgeon should be experienced, relaxed, and psychologically prepared for unexpected problems of anatomy or intraoperative rupture.

Financial support and sponsorship

Nil.

Conflicts of interest

There are no conflicts of interest.

References

1. Batjer HH, Frankfurt AI, Purdy PD, Smith SS, Samson DS. Use of etomidate, temporary arterial occlusion, and intraoperative angiography in surgical treatment of large and giant cerebral aneurysms. *J Neurosurg* 1988;68:234-40.
2. Bendok BR, Getch CC, Parkinson R, O'Shaughnessy BA, Batjer HH. Extended lateral transsylvian approach for basilar bifurcation aneurysms. *Neurosurgery* 2004;55:174-8.

3. Sonlanmasının I, Değişkenliği A. Anatomical variability in the termination of the basilar artery in the human cadaveric brain. *Turk Neurosurg* 2015;25:586-94.
4. Bendok BR, Getch CC, Malisch TW, Batjer HH. Treatment of aneurysmal subarachnoid hemorrhage. *Semin Neurol* 1998;18:521-31.
5. Ciacci J, Bendok B, Getch C, Batjer HH. Pterional approach to distal basilar aneurysms via the extended lateral corridor: PAVEL. *Tech Neurosurg* 2000;6:221-7.
6. Drake CG. Bleeding aneurysms of the basilar artery. Direct surgical management in four cases. *J Neurosurg* 1961;18:230-8.
7. Drake CG. Ligation of the vertebral (unilateral or bilateral) or basilar artery in the treatment of large intracranial aneurysms. *J Neurosurg* 1975;43:255-74.
8. Drake CG. The treatment of aneurysms of the posterior circulation. *Clin Neurosurg* 1979;26:96-144.
9. Drake CG, Barr HW, Coles JC, Gergely NF. The use of extracorporeal circulation and profound hypothermia in the treatment of ruptured intracranial aneurysm. *J Neurosurg* 1964;21:575-81.
10. Drake CG, Peerless SJ. Giant fusiform intracranial aneurysms: Review of 120 patients treated surgically from 1965 to 1992. *J Neurosurg* 1997;87:141-62.
11. Gross BA, Hage ZA, Daou M, Getch CC, Batjer HH, Bendok BR. Surgical and endovascular treatments for intracranial aneurysms. *Curr Treat Options Cardiovasc Med* 2008;10:241-52.
12. Heros RC, Lee SH. The combined pterional/anterior temporal approach for aneurysms of the upper basilar complex: Technical report. *Neurosurgery* 1993;33:244-50.
13. Hsu FP, Clatterbuck RE, Spetzler RF. Orbitozygomatic approach to basilar apex aneurysms. *Neurosurgery* 2005;56 1 Suppl: 172-7.
14. Krisht AF, Kadri PAS. Surgical clipping of complex basilar apex aneurysms: A strategy for successful outcome using the pretemporal transzygomatic transcavernous approach. *Neurosurgery* 2005;56:261-73.
15. Paine JT, Batjer HH, Samson D. Intraoperative ventricular puncture. *Neurosurgery* 1988;22(6 Pt 1):1107-9.
16. Raymond J, Roy D, Bojanowski M, Moumdjian R, L'Espérance G. Endovascular treatment of acutely ruptured and unruptured aneurysms of the basilar bifurcation. *J Neurosurg* 1997;86:211-9.
17. Rice BJ, Peerless SJ, Drake CG. Surgical treatment of unruptured aneurysms of the posterior circulation. *J Neurosurg* 1990;73:165-73.
18. Samson D, Batjer HH, Bowman G, Mootz L, Krippner WJ Jr., Meyer YJ, *et al.* A clinical study of the parameters and effects of temporary arterial occlusion in the management of intracranial aneurysms. *Neurosurgery* 1994;34:22-8.
19. Samson D, Batjer HH, Kopitnik TA Jr. Current results of the surgical management of aneurysms of the basilar apex. *Neurosurgery* 1999;44:697-702.