

Axially torsional Meckel's diverticulum accompanied by small bowel volvulus: a case report

Journal of International Medical Research

49(10) 1–6

© The Author(s) 2021

Article reuse guidelines:

sagepub.com/journals-permissions

DOI: 10.1177/03000605211053554

journals.sagepub.com/home/imr

Yang Chen , Yongzhi Liu, Lihui Jiang,
Feng Jiang and Tieming Zhu

Abstract

Small bowel volvulus secondary to Meckel's diverticulum is rare, and a delayed diagnosis results in disastrous outcomes. Computed tomography is conducive to early differential diagnosis. In particular, a blind-ending pouch structure on CT always indicates Meckel's diverticulum. Diverticulectomy with or without adjacent partial small intestinal resection is the standard treatment for symptomatic Meckel's diverticulum. However, the therapy for asymptomatic Meckel's diverticulum is controversial. Here, we report the case of a 20-year-old man who suffered intestinal obstruction secondary to small bowel volvulus caused by an axially torsional, gangrenous, and giant Meckel's diverticulum. Diverticulectomy with partial intestinal resection was performed.

Keywords

Meckel's diverticulum, small bowel volvulus, early diagnosis, therapy, intestine, resection

Date received: 15 July 2021; accepted: 28 September 2021

Introduction

Small bowel volvulus, classified as primary and secondary, refers to torsion of a section of the intestine and its associated mesentery. Intestinal obstruction is the most common clinical manifestation of small bowel volvulus.¹ Small bowel volvulus secondary to Meckel's diverticulum is rare.

Department of General Surgery, Affiliated Xiaoshan Hospital, Hangzhou Normal University, Hangzhou, Zhejiang, China

Corresponding author:

Yang Chen, Department of General Surgery, Affiliated Xiaoshan Hospital, Hangzhou Normal University, No. 728 North Yucai Road, Hangzhou City, Zhejiang Prov. 311200, China.

Email: 446977179@qq.com



Creative Commons Non Commercial CC BY-NC: This article is distributed under the terms of the Creative Commons Attribution-NonCommercial 4.0 License (<https://creativecommons.org/licenses/by-nc/4.0/>) which permits non-commercial use, reproduction and distribution of the work without further permission provided the original work is attributed as specified on the SAGE and Open Access pages (<https://us.sagepub.com/en-us/nam/open-access-at-sage>).

Meckel's diverticulum is the most common malformation of the digestive tract and conforms to the "rule of 2s", occurring in 2% of the population at 2 years of age, located 2 feet from the ileocecal valve, 2 cm in length, and with two types of ectopic tissue (gastric and pancreatic).² Computed tomography is a superior imaging method in emergency patients.³ Diverticulectomy with or without adjacent partial small intestinal resection is used to treat symptomatic Meckel's diverticulum; however, this therapy is controversial for asymptomatic Meckel's diverticulum.^{4,5} Here, we report the case of a 20-year-old man who suffered intestinal obstruction secondary to small bowel volvulus owing to Meckel's diverticulum.

This study was approved by the Medical Ethics Committee of Zhejiang Xiaoshan Hospital, approval no. K202181. Verbal informed consent to publish the case report was obtained from the patient.

Case presentation

A 20-year-old man presented to the emergency department with acute onset of sharp and paroxysmal periumbilical pain for 1 day, without previous medical and surgical illness. On admission, his pulse rate was 100 beats per minute, blood pressure was 128/74 mmHg, and body temperature was 36.7°C. Physical examination revealed periumbilical tenderness without muscular defense and rebounding pain. Laboratory examination revealed mild leucocytosis ($11.4 \times 10^9/L$) and normal C-reactive protein concentration. The initial computed tomography (CT) revealed partial small bowel dilation with effusion. Two hours later, the patient complained of persistent periumbilical pain associated with nausea and vomiting, but denied fever. On examination, all abdominal quadrants were tender with periumbilical rebound tenderness. Blood examination was repeated and

revealed that the leucocyte count had increased to $21.4 \times 10^9/L$ with 89.4% segmented neutrophils, and the C-reactive protein concentration was 36 mg/L. Abdominal plain radiographs indicated multiple air-fluid levels (Figure 1). Abdominal contrast-enhanced computed tomography (Figure 2) revealed local dilatation and edema in the proximal small intestine. Additionally, the mesentery of the small

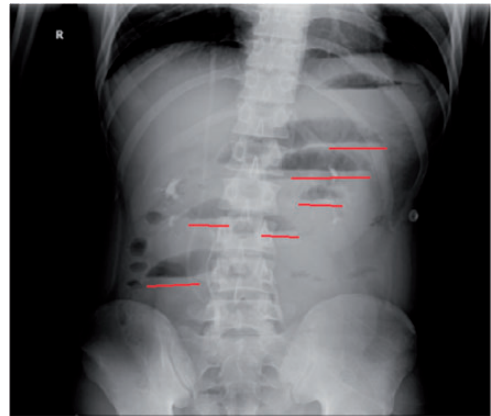


Figure 1. Abdominal plain radiographs showing multiple air-fluid levels (red line).

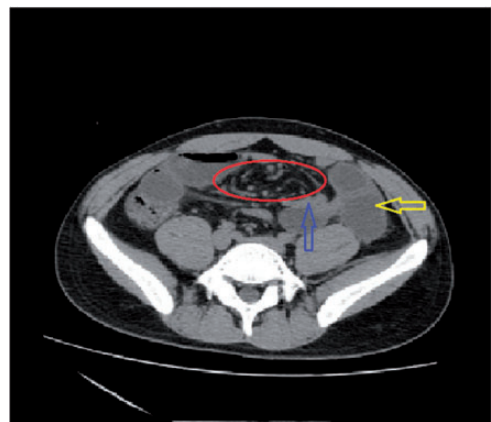


Figure 2. Contrast-enhanced computed tomography showing the "whirlpool sign" (red ring) with dilated intestine (yellow arrow) and collapsed intestine (green arrow).

intestine had swirl-like changes (“whirlpool sign”), which indicated intestinal volvulus. Finally, the patient underwent emergency exploratory laparotomy.

At laparotomy, a long (12 cm), dilated, thick-walled, gangrenous and axially torsional Meckel’s diverticulum (Figure 3) located 80 cm from the ileocecal valve was discovered. Further exploration identified a fibrous band at the apex of the diverticulum that was adhered to the adjoining mesentery. The diverticulum was axially twisted by the band, and the small intestine was twisted around the diverticular base. As a result, the small intestine proximal to the point of the obstruction was dilated. No other necrotic intestine was found. Diverticulectomy combined with partial intestinal resection was performed successfully. Histological examination revealed suppurative inflammation of Meckel’s diverticulum with fibroangiogenesis. The patient was discharged 1 week postoperatively without complications. During the 1-year follow-up, the patient experienced no abdominal pain. The reporting of this study conforms to the CARE guidelines.⁶

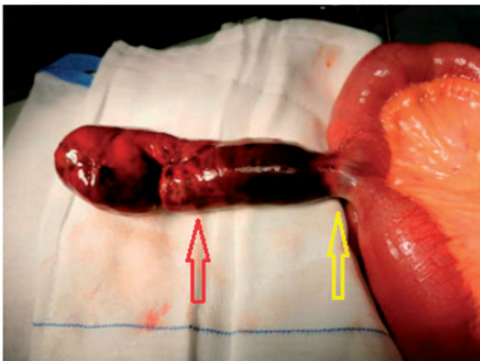


Figure 3. Intraoperative photograph showing a giant and gangrenous (red arrow) Meckel’s diverticulum twisting around its narrow base (yellow arrow).

Discussion

Primary or secondary small bowel volvulus is a rare disease¹ that can result in torsion of partial small intestine without an obvious cause. Conversely, secondary small bowel volvulus occurs in specific conditions, such as congenital bowel malformation (malrotation, Meckel’s diverticulum), postoperative adhesion, and tumor.⁷ The distinct clinical manifestation of small bowel volvulus is intestinal obstruction with nausea, vomiting, and abdominal distention. As the symptoms progress, patients develop intestinal gangrene and perforation due to intestinal ischemia. A previous study reported a high incidence of gangrene (16.9%–46%) and a high mortality rate (3.4%–8%).⁸ Therefore, early diagnosis and treatment are the keys to prevent intestinal gangrene and perforation. The “whirlpool sign” on CT and signs of peritonitis play important roles in guiding decisions regarding diagnostic tests and therapy.¹ In the present case, the small bowel volvulus was the secondary type as was owing to Meckel’s diverticulum.

Meckel’s diverticulum is a common congenital anomaly of the gastrointestinal tract that results from a remnant of the omphalomesenteric duct or vitellointestinal duct during the 5th to 7th weeks of embryogenesis.² The clinical manifestations of Meckel’s diverticulum vary. Gastrointestinal bleeding is the most common presentation of Meckel’s diverticulum in children, with an incidence of up to 40.2%.⁹ However, intestinal obstruction is the most frequent manifestation in adults, accounting for 14% to 40% of cases of symptomatic Meckel’s diverticulum.¹⁰ Other complications are diverticulitis,¹¹ perforation,¹² and tumor.¹³ Although the prevalence of Meckel’s diverticulum ranges from 0.3% to 2.9% in the general population,² a delayed diagnosis leads to life-threatening events. However, early

diagnosis of Meckel's diverticulum associated with complex complications is difficult. CT identified up to 47.5% of cases of both symptomatic and asymptomatic Meckel's diverticulum, in one study.³ ^{99m}Tc-technetium-pertechnetate-labeled abdominal scintigraphy (Meckel scan) is another diagnostic technique for detecting Meckel's diverticulum.¹⁴ However, this imaging examination has certain limitations: (1) patients must fast for 3 to 4 hours to achieve high sensitivity;¹⁴ (2) patients without a history of gastrointestinal bleeding receive no benefits from the examination;¹⁵ and (3) not all hospitals can routinely arrange this examination for emergency patients.

In the present case, we did not detect the blind-ending pouch structure,¹⁶ (Figure 4) which indicates Meckel's diverticulum, in the initial CT scan. However, the subsequent contrast-enhanced CT showed the "whirlpool sign", which represents small bowel volvulus. We assumed that the following reasons accounted for the development of small bowel volvulus secondary to

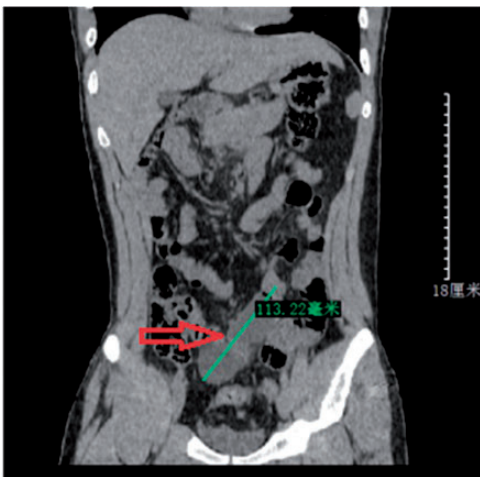


Figure 4. The initial computed tomography image showing a blind-ending pouch structure representing Meckel's diverticulum.

Meckel's diverticulum in our patient: First, the fibrous band that is formed from the incomplete degeneration of the omphalomesenteric duct connected to the abdominal wall or the adjacent mesentery. This fibrous band may suddenly result in abdominal internal hernia¹⁷ or axial torsion of Meckel's diverticulum.¹⁸ Second, the patient had a giant Meckel's diverticulum. The average length is 2.9 cm; however, Meckel's diverticulum in our patient measured 12 cm in length, and giant diverticula lead to axial torsion.¹⁹ Finally, strenuous excise before the onset of symptoms also plays an important role. All of these reasons may disturb normal small bowel mobility and lead to small bowel volvulus.

Diverticulectomy with or without adjoining small intestinal resection is the best solution for symptomatic Meckel's diverticulum.²⁰ Regarding the surgical options, laparotomy and laparoscopic resection have similar outcomes in terms of operative and anesthesia time, length of stay, 30-day mortality, postoperative complications, and reoperation and readmission rates.²¹ Laparotomy is recommended in emergency situations, especially when Meckel's diverticulum is accompanied by intestinal obstruction because the dilated intestine occupies a large space in the abdominal cavity and hinders operative procedures. However, the treatment of asymptomatic Meckel's diverticulum is controversial. Thirunavukarasu et al.⁴ strongly recommend diverticulectomy in asymptomatic patients because Meckel's diverticulum is a high-risk region for malignancy in the ileum. Blouhos et al.⁵ hold the view that Meckel's diverticulum should not be resected routinely. The authors recommend that Meckel's diverticulum be resected when it is longer, with a fibrous band at the tip of diverticulum and a narrow base.

In conclusion, axially torsional Meckel's diverticulum accompanied by small bowel volvulus is a rare clinical complication of Meckel's diverticulum. Early diagnosis of Meckel's diverticulum is the key to prevent disastrous outcomes. CT is conducive to diagnosing Meckel's diverticulum when images show a blind-ending pouch structure.


Declaration of conflicting interest

The authors declare that there is no conflict of interest.

Funding

This research received no specific grant from any funding agency in the public, commercial, or not-for-profit sectors.

ORCID iD

Yang Chen  <https://orcid.org/0000-0003-3197-0520>

References

1. Li X, Zhang J, Li B, et al. Diagnosis, treatment and prognosis of small bowel volvulus in adults: a monocentric summary of a rare small intestinal obstruction [J]. *PLoS One* 2017; 12: e0175866.
2. Ivatury RR. Meckel's diverticulum and the eponymous legend [J]. *J Trauma Acute Care Surg* 2019; 87: 451–455.
3. Kawamoto S, Raman SP, Blackford A, et al. CT detection of symptomatic and asymptomatic Meckel diverticulum [J]. *AJR Am J Roentgenol* 2015; 205: 281–291.
4. Thirunavukarasu P, Sathaiah M, Sukumar S, et al. Meckel's diverticulum—a high-risk region for malignancy in the ileum. Insights from a population-based epidemiological study and implications in surgical management [J]. *Ann Surg* 2011; 253: 223–230.
5. Blouhos K, Boulas KA, Tsalis K, et al. Meckel's diverticulum in adults: surgical concerns [J]. *Front Surg* 2018; 5: 55.
6. Gagnier JJ, Kienle G, Altman DG, et al.; CARE Group. The CARE guidelines: consensus-based clinical case reporting guideline development. *Headache* 2013; 53: 1541–1547.
7. Shen XF, Guan WX, Cao K, et al. Small bowel volvulus with jejunal diverticulum: primary or secondary? [J]. *World J Gastroenterol* 2015; 21: 10480–10484.
8. Awedew AF, Belay WB, Amsalu BT, et al. Small bowel volvulus (SBV) in Northcentral Ethiopia [J]. *BMC Surg* 2020; 20: 221.
9. Chatterjee A, Harmath C, Vendrami CL, et al. Reminiscing on remnants: imaging of Meckel diverticulum and its complications in adults [J]. *AJR Am J Roentgenol* 2017; 209: W287–W296.
10. Lequet J, Menahem B, Alves A, et al. Meckel's diverticulum in the adult [J]. *J Visc Surg* 2017; 154: 253–259.
11. Martí Fernández R, León Espinoza C, Tonazzi Zorrilla R. Meckel's diverticulitis: a laparoscopic approach [J]. *Rev Esp Enferm Dig* 2018; 110: 834.
12. Liu KT and Wu YH. Spontaneous perforation of Meckel diverticulum: a case report [J]. *Medicine (Baltimore)* 2017; 96: e9506.
13. Dogrul AB, Kilic YA, Onurdag F, et al. A gastrointestinal stromal tumor in Meckel diverticulum in an 86-year-old patient [J]. *Am J Med Sci* 2010; 340: 156–157.
14. Grady E. Gastrointestinal bleeding scintigraphy in the early 21st century [J]. *J Nucl Med* 2016; 57: 252–259.
15. Irvine I, Doherty A and Hayes R. Bleeding Meckel's diverticulum: a study of the accuracy of pertechnetate scintigraphy as a diagnostic tool [J]. *Eur J Radiol* 2017; 96: 27–30.
16. Platon A, Gervaz P, Becker CD, et al. Computed tomography of complicated Meckel's diverticulum in adults: a pictorial review [J]. *Insights Imaging* 2010; 1: 53–61.
17. Zhang Y, Guo Y, Sun Y, et al. An internal hernia caused by Meckel's diverticulum: a case report [J]. *BMC Gastroenterol* 2020; 20: 69.
18. Tiong VTY, Shimpi T, Shikhare S, et al. Axial torsion of Meckel's diverticulum [J]. *ANZ J Surg* 2018; 88: E809–E810.
19. Limas C, Seretis K, Soultanidis C, et al. Axial torsion and gangrene of a giant

- Meckel's diverticulum [J]. *J Gastrointestin Liver Dis* 2006; 15: 67–68.
20. Park JJ, Wolf BG, Tollefson MK, et al. Meckel diverticulum: the Mayo Clinic experience with 1476 patients (1950–2002). *Ann Surg* 2005; 241: 529–533.
21. Ezekian B, Leraas HJ, Englum BR, et al. Outcomes of laparoscopic resection of Meckel's diverticulum are equivalent to open laparotomy [J]. *J Pediatr Surg* 2019; 54: 507–510.