

## CASE REPORT

# Unmasking sarcoidosis following SARS-CoV-2 vaccination: A case report

Fatemeh Mohaghegh<sup>1</sup> | Parvaneh Hatami<sup>2</sup>  | Arezoo Refaghat<sup>3</sup> | Amir Hassan Matini<sup>4</sup> | Zeinab Mohseni Afshar<sup>5</sup> | Zeinab Aryanian<sup>2,6</sup>

<sup>1</sup>Department of Dermatology, Skin Diseases and Leishmaniasis Research Center, Isfahan University of Medical Sciences, Isfahan, Iran

<sup>2</sup>Autoimmune Bullous Diseases Research Center, Tehran University of Medical Sciences, Tehran, Iran

<sup>3</sup>Department of Dermatology, Isfahan University of Medical Sciences, Isfahan, Iran

<sup>4</sup>Department of Clinical Pathology, Kashan University of Medical Sciences, Isfahan, Iran

<sup>5</sup>Clinical Research Development Center, Imam Reza Hospital, Kermanshah University of Medical Sciences, Kermanshah, Iran

<sup>6</sup>Department of Dermatology, Babol University of Medical Sciences, Babol, Iran

## Correspondence

Zeinab Mohseni Afshar, Clinical Research Development Center, Imam Reza Hospital, Kermanshah University of Medical Sciences, Kermanshah, Iran.  
Email: [z\\_moseni2001@yahoo.com](mailto:z_moseni2001@yahoo.com)

Zeinab Aryanian and Parvaneh Hatami, Autoimmune Bullous Diseases Research Center, Razi Hospital, Tehran University of Medical Sciences, Tehran, Iran.  
Email: [z\\_aryanian@yahoo.com](mailto:z_aryanian@yahoo.com) and [p\\_hatami2001@yahoo.com](mailto:p_hatami2001@yahoo.com)

## Abstract

Sarcoidosis is an inflammatory and granulomatous disorder, developed due to dysregulation between immune response and certain environmental antigens. We hereby report an interesting case of sarcoidosis following COVID-19 vaccination (COVIran Barekat), which presented with inflammation of previous tattoo sites as well as the development of erythema nodosum and systemic lymphadenopathy, suggested a possible link between the COVID vaccination and dysregulation of the inflammatory process and served as a reminder for clinicians to have enough vigilance before proposing a vaccine booster to these patients.

## KEYWORDS

COVID-19, COVID-19 vaccination, COVIran Barekat, granulomatous inflammation, sarcoidosis

## 1 | INTRODUCTION

The coronavirus disease 2019 (COVID-19) has brought about several consequences, including dermatologic adverse events. These dermatologic complications have been usually *de novo* cutaneous disorders, like pemphigus or psoriasis, which occurred as new-onset or flares of a pre-existing dermatosis.<sup>1,2</sup> However, occasional cases of cutaneous reactions have been reported either after COVID-19 infection or vaccination, which were a part of a systemic disorder; sarcoidosis is such an example that was rarely reported after SARS-CoV-2 infection and far more rarely after SARS-CoV-2 vaccination.<sup>3–5</sup> Here, we report and discuss a case of new-onset sarcoidosis with cutaneous presentations following receiving COVID-19 vaccine.

## 2 | CASE PRESENTATION

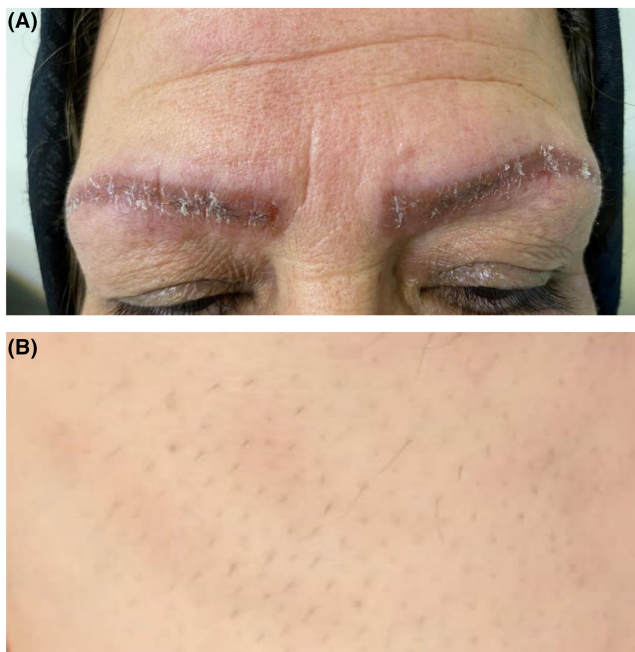A 65-year-old woman presented to the dermatologic clinic with erythematous and erosive lesions of the eyebrows (Figure 1A). She mentioned that these eruptions had begun with bilateral pruritic exfoliating eruptions on the tattooed skin of the eyebrows 1 week after receiving the second dose of SARS-CoV-2 vaccine (COVIran Barekat). Her past medical history was significant for asthma, diabetes mellitus, and congestive heart failure; moreover, she got infected with SARS-CoV-2 2 weeks after the second

vaccine dose, which led to hospitalization. She acknowledged that her skin eruptions improved after receiving dexamethasone for her severe COVID infection during the hospital stay but worsened soon after corticosteroid cessation and discharge. She visited several physicians and underwent multiple therapies including systemic and topical antibiotics, topical corticosteroids, and topical pimecrolimus and tacrolimus, but no beneficial result was demonstrated. In addition, the dermatologists' commission agreed on starting the patient on intralesional triamcinolone, which was also inconclusive. After a while, she developed unilateral cervical lymphadenopathy and symmetrical tender red nodules on the anterior aspects of lower legs, clinically compatible with erythema nodosum (Figure 1B). Laboratory analysis revealed a weakly positive C-reactive protein (CRP) and an elevated level of angiotensin-converting enzyme (ACE). Chest radiography (CXR) showed right hilar prominence and neck spiral computed tomography (CT) scan with contrast revealed lymph node enlargement in bilateral submandibular, submental, and jugular chain regions. Being suspicious to malignancies, she was referred to a hemato-oncologist who took biopsy from her right parotid space lymph node, with histopathological examination reporting noncaseating granulomatous lymphadenitis (Figure 2), which in conjunction with other clinical findings was compatible with sarcoidosis. She was referred to a rheumatologist who started her on methotrexate and prednisolone. After 1 month, erythema nodosum disappeared and eyebrow skin lesions partially resolved.

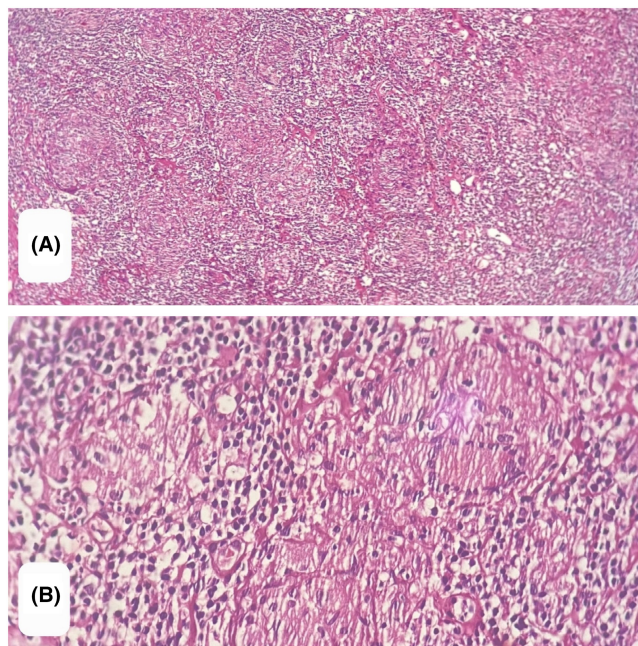
## 3 | DISCUSSION

We encountered a case of unmasking sarcoidosis after SARS-CoV-2 vaccination in a middle-aged female. After nearly 2 years of universal SARS-CoV-2 vaccination, it has been evident that autoimmunity triggered by this vaccine can lead to new-onset immune disorders. In fact, new cases of autoimmunity such as sudden sensorineural hearing loss, as well as flares of known cases such as those with rheumatoid arthritis, have been documented to occur post-COVID vaccination.<sup>6,7</sup> The underlying pathophysiologic mechanism for this autoimmunity is mostly the innate and adaptive immune responses to vaccine adjuvants. Our patient received an inactivated whole virus vaccine against SARS-CoV-2; however, mRNA vaccines are more likely to induce autoimmune phenomena like sarcoidosis.<sup>8–10</sup>

Sarcoidosis is a multisystem granulomatous disorder with an immunologic basis, which is manifested as pulmonary, renal, ophthalmic, musculoskeletal, hepatic, and cutaneous complaints. Genetic, immunologic, and



**FIGURE 1** Exfoliating eruptions on the tattooed skin of the eyebrows, developed 1 week after receiving the second dose of SARS-CoV-2 vaccine (A). Symmetrical tender red nodules on the anterior aspects of lower legs (B)



**FIGURE 2** Noncaseating granulomatous lymphadenitis (H&E  $\times 40$ ) (A) and (H&E  $\times 100$ ) (B).

environmental factors contribute to the development of sarcoidosis.<sup>11,12</sup> There are few reports of new-onset sarcoidosis following SARS-CoV-2 infection and even fewer ones after COVID vaccination.<sup>13</sup> Previously, new development of sarcoidosis had been reported following receiving influenza, varicella-zoster, and BCG vaccines.<sup>14–16</sup>

The most common dermatologic manifestations of sarcoidosis include papules, plaques, and subcutaneous nodules, which usually appear on the limbs and the face. However, lupus pernio and inflammation around the scars or tattooed skin occur less commonly in the settings of sarcoidosis, which was demonstrated in our patient.<sup>17,18</sup>

Autoimmune diseases triggered by vaccination usually take place about 1 week after vaccination.<sup>19</sup> This was true in our patient, who developed cutaneous manifestations 1 week after the second vaccine dose. Therefore, it can be inferred that sarcoidosis was induced in this patient by SARS-CoV-2 vaccination. The patient initially developed sarcoid-like reaction on tattooed skin of her eyebrows, which had previously been reported after SARS-CoV-2 infection.<sup>20</sup> This vaccine-related adverse reaction did not suspect us to sarcoidosis until other compatible clinical findings appeared. There are abundant reports of lymphadenitis, erythema nodosum, and skin reactions following SARS-CoV-2 vaccination, but the simultaneous onset of peripheral and paratracheal lymphadenopathy, along with erythema nodosum, is highly suggestive of sarcoidosis. Although ACE elevation supported our diagnosis, definite diagnosis was made by tissue histopathological examination showing noncaseating granulomas.<sup>21–26</sup>

Sarcoidosis-related skin lesions do not usually need treatment if are not cosmetically serious or accompanied by other organ involvement. In isolated cutaneous sarcoidosis, local corticosteroid, either topical or intralesional, usually suffice. However, in resistant cases or systemic involvement, systemic glucocorticoids and DMARDs are warranted.<sup>27,28</sup> Although the aforementioned systemic treatments usually lead to favorable response in sarcoidosis skin lesions, our patient's cutaneous involvement was not fully responsive. Perhaps, more prolonged therapy is needed and we should wait and watch for gaining response in the near future.

## 4 | CONCLUSION

Although the side effects of SARS-CoV-2 vaccination are yet to be discovered, any immune reaction aroused with temporal relationship to vaccination should be considered a vaccine-induced adverse unless proven otherwise.

## AUTHOR CONTRIBUTIONS

All authors contributed to the preparation of data and finalization of this article.

## ACKNOWLEDGMENTS

The authors would like to thank Razi Hospital Clinical Research Development Center, Imam Reza Hospital Clinical Research Development Center and Autoimmune Bullous Diseases Research Center, for their technical and editorial assistance.

## CONFLICT OF INTEREST

The authors declare that they have no competing interests.

## DATA AVAILABILITY STATEMENT

The data that support the findings of this study are available from the corresponding author, upon reasonable request.

## ETHICAL APPROVAL

Ethics approval from the Medical Ethics Committee of Isfahan University of Medical Sciences was provided.

## CONSENT

A written informed consent was obtained from the patient for publication of this case report and any accompanying images. A copy of the written consent is available for review by the Editor-in-Chief of this journal.

## ORCID

Parvaneh Hatami  <https://orcid.org/0000-0002-3531-2907>



## REFERENCES

- Mohseni Afshar Z, Babazadeh A, Hasanpour A, et al. Dermatological manifestations associated with COVID-19: a comprehensive review of the current knowledge. *J Med Virol*. 2021;93(10):5756-5767.
- Aryanian Z, Balighi K, Hatami P, Tootoonchi NM, Goodarzi A, Mohseni AZ. Morphea in two patients after being infected to and being vaccinated against SARS-CoV-2 infection. *Clin Case Rep*. 2022;10(4):e05667.
- Rabufetti A, Borradori L, Heidemeyer K, et al. New onset of sarcoidosis after COVID-19 infection. *J Eur Acad Dermatol Venereol*. 2022;36:e756-e759.
- Ekinci AP, Büyükbabani N, Meşe S, et al. COVID-19-triggered sarcoidal granulomas mimicking scar sarcoidosis. *J Eur Acad Dermatol Venereol*. 2021;35:e477-e480.
- Abu Rached N, Mansour R, Susok L, et al. Sarcoidal immune reaction following SARS-CoV-2 vaccination. *Clin Exp Dermatol*. 2022;47(5):970-972.
- Nahra V, Makandura M, Anthony DD, Mattar M. A case series on the COVID-19 vaccines and possible immune-related adverse events: a new challenge for the rheumatologists. *Cureus*. 2022;14(9):e29660. doi:10.7759/cureus.29660
- Tsetsos N, Poutoglidis A, Vlachtsis K, Kilmpasanis A, Gougousis S. Sudden sensorineural hearing loss following the second dose of COVID-19 vaccine. *Cureus*. 2021;13(8):e17435. doi:10.7759/cureus.17435
- Chen Y, Xu Z, Wang P, et al. New-onset autoimmune phenomena post-COVID-19 vaccination. *Immunology*. 2022;165(4):386-401.
- Mohseni Afshar Z, Babazadeh A, Janbakhsh A, et al. Vaccine-induced immune thrombotic thrombocytopenia after vaccination against Covid-19: a clinical dilemma for clinicians and patients. *Rev Med Virol*. 2022;32(2):e2273.
- Jara LJ, Vera-Lastra O, Mahroum N, Pineda C, Shoenfeld Y. Autoimmune post-COVID vaccine syndromes: does the spectrum of autoimmune/inflammatory syndrome expand? *Clin Rheumatol*. 2022;41:1603-1609.
- Ungprasert P, Ryu JH, Matteson EL. Clinical manifestations, diagnosis, and treatment of sarcoidosis. *Mayo Clin Proc Innov Qual Outcomes*. 2019;3(3):358-375.
- Chen ES, Moller DR. Etiologies of sarcoidosis. *Clin Rev Allergy Immunol*. 2015;49(1):6-18.
- Rademacher J-G, Tampe B, Korsten P. First report of two cases of Löfgren's syndrome after SARS-CoV-2 vaccination-coincidence or causality? *Vaccine*. 2021;9(11):1313.
- Psaltis NM, Gardner RG, Denton WJ. Systemic sarcoidosis and red dye granulomatous tattoo inflammation after influenza vaccination: a case report and review of literature. *Ocul Immunol Inflamm*. 2014;22(4):314-321.
- Heydari-Kamjani M, Vante I, Uppal P, Beckler MD, Kesselman MM. Uveitis sarcoidosis presumably initiated after administration of Shingrix vaccine. *Cureus*. 2019;11(6):e4920.
- Osborne GE, Mallon E, Mayou SC. Juvenile sarcoidosis after BCG vaccination. *J Am Acad Dermatol*. 2003;48(5):S99-S102.
- Ungprasert P, Wetter D, Crowson C, Matteson E. Epidemiology of cutaneous sarcoidosis, 1976–2013: a population-based study from Olmsted County, Minnesota. *J Eur Acad Dermatol Venereol*. 2016;30(10):1799-1804.
- Wanat KA, Rosenbach M. Cutaneous sarcoidosis. *Clin Chest Med*. 2015;36(4):685-702.
- Barbhaiya M, Levine JM, Bykerk VP, Jannat-Khah D, Mandl LA. Systemic rheumatic disease flares after SARS-CoV-2 vaccination among rheumatology outpatients in New York City. *Ann Rheum Dis*. 2021;80(10):1352-1354.
- Steadman L, Mastacouris N, Eilers D. Cutaneous sarcoid-like reaction on tattooed skin after recovery from coronavirus disease 2019. *J Clin Aesthet Dermatol*. 2021;14(11):16-17.
- Santiago J, Negron-Ocasio G, Ortiz-Troche S, et al. Rare expression of systemic sarcoidosis after a novel RNA vaccine. *Chest*. 2021;160(4):A1233-A1234.
- Chahed F, Ben Fadhel N, Ben Romdhane H, et al. Erythema nodosum induced by Covid-19 Pfizer-BioNTech mRNA vaccine: a case report and brief literature review. *Br J Clin Pharmacol*. 2022. doi:10.1111/bcp.15351. Epub ahead of print.
- Cameli N, Silvestri M, Mariano M, Bennardo L, Nisticò SP, Cristaudo A. Erythema nodosum following the first dose of ChAdOx1-S nCoV-19 vaccine. *J Eur Acad Dermatol Venereol*. 2022;36(3):e161-e162.
- Al-Ani RM, Rashid RA. Supraclavicular lymphadenitis following COVID-19. 2021. doi:10.21203/rs.3.rs-670161/v1
- Cheong KM, Tsai T-Y. A woman with painful neck after COVID-19 vaccination. *Ann Emerg Med*. 2022;79(2):e13-e14.
- Hsu H-T, Su H-A, Chen Y-C. Erythema nodosum, after Medigen vaccination against COVID-19? *J Formos Med Assoc*. 2022;121(3):723-724.
- Haimovic A, Sanchez M, Judson MA, Prystowsky S. Sarcoidosis: a comprehensive review and update for the dermatologist: part I. Cutaneous disease. *J Am Acad Dermatol*. 2012;66(5):699-e1-18.
- Wanat KA, Rosenbach M. A practical approach to cutaneous sarcoidosis. *Am J Clin Dermatol*. 2014;15(4):283-297.

**How to cite this article:** Mohaghegh F, Hatami P, Refaghat A, Matini AH, Mohseni Afshar Z, Aryanian Z. Unmasking sarcoidosis following SARS-CoV-2 vaccination: A case report. *Clin Case Rep*. 2022;10:e06660. doi:10.1002/ccr3.6660