

# Arthroscopic Suprapectoral Biceps Tenodesis With Tenodesis Screw



Brian Forsythe, M.D., William A. Zuke, B.S.,  
Richard N. Puzzitiello, B.S., and Anthony A. Romeo, M.D.

**Abstract:** There are many methods for long head of the biceps tendon (LHBT) tenodesis, but a consensus on a superior method has yet to be met. In this article, we introduce a method for arthroscopic suprapectoral biceps tenodesis using a tenodesis screw in the bicipital tunnel. The intra-articular portion of the biceps tendon is transected. The subdeltoid space is then viewed via a lateral portal, and the tendon is mobilized from the bicipital tunnel. The tendon is retrieved through the anterior portal, and 5 whipstitch passes and a second distal stitch are placed. Three of the suture tails are passed through the tenodesis screwdriver, and the tendon is maneuvered to the previously reamed bone socket located 1.5 cm superior to the pec tendon, just inferior to the bicipital groove. Once the tenodesis screw is fixated in sufficient bone stock, 5 alternating half hitches reinforce the construct by creating a closed loop through the screw. This described technique allows full visualization of the LHBT dissection and tenodesis throughout the procedure. Additionally, this technique provides a method to incorporate whipstitching with an arthroscopic tenodesis screw to provide additional strength to tendon fixation.

The function of the long head of the biceps tendon (LHBT) is controversial; however, pathology affecting the LHBT can cause substantial pain.<sup>1</sup> In the event of persistent discomfort after nonoperative treatment, biceps tenodesis is an effective surgical option.<sup>2</sup> Lower incidence of cosmetic deformity is associated with tenodesis compared with tenotomy, and tenodesis is commonly performed in young, active patients.<sup>3,4</sup> A tenodesis also has the advantage of maintaining the length-tension relationship of the biceps muscle, which may reduce spasms.<sup>4,5</sup>

Several techniques are available for biceps tenodesis, with variation in surgical approach, location of tenodesis, and method of fixation. Tenodesis locations have included osseous sites at the entrance of the bicipital groove proximally, the suprapectoral and subpectoral regions, or in soft-tissue sites such as the conjoint tendon.<sup>1,5-7</sup> Methods of fixation include simple suture, interference screw, suture anchor, and bone tunnel techniques.<sup>2,5-7</sup>

An anatomical study described the bicipital tunnel as having 3 zones.<sup>8</sup> The most proximal, zone 1, is the bony bicipital groove, which is encased by synovium and confined by the fibers of the subscapularis tendon. Zone 2 is bordered proximally by the inferior border of the subscapularis tendon and transverse humeral ligament and distally by the superior border of the pectoralis major tendon. Zone 3 is defined by the portion of the bicipital tunnel deep to the pectoralis major tendon.<sup>8</sup> This Technical Note describes an arthroscopic technique for LHBT tenodesis using an interference screw in zone 2 of the bicipital tunnel, described as a suprapectoral tenodesis (Video 1).

## Surgical Technique

### Imaging and Indications

Indications for a tenodesis include biceps instability, tendinopathy, partial biceps tears, SLAP lesions, and biceps pulley lesions.<sup>7</sup> Clinical exam may

*From the Division of Sports Medicine, Department of Orthopaedic Surgery, Midwest Orthopaedics at Rush University Medical Center, Chicago, Illinois, U.S.A.*

*The authors report the following potential conflicts of interest or sources of funding: B.F. receives support from Stryker, ArthroSurface, Sonoma, and Jace Medical. A.A.R. receives support from Orthopedics Today, Arthrex, AANA, MLB, NuTech, Smith & Nephew, Zimmer, Aesculap, OrthoSpace, Histogenics, and Medipost. Full ICMJE author disclosure forms are available for this article online, as supplementary material.*

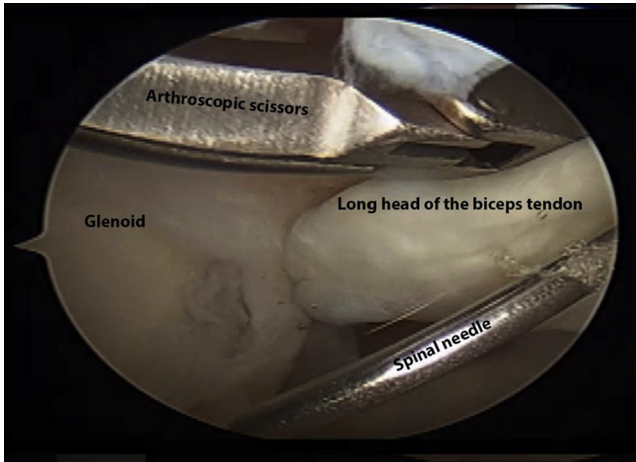
*Received October 9, 2017; accepted October 31, 2017.*

*Address correspondence to Brian Forsythe, M.D., Midwest Orthopaedics at Rush University Medical Center, 1611 West Harrison Street, Suite 300, Chicago, IL 60612, U.S.A. E-mail: Forsythe.research@rushortho.com*

© 2017 by the Arthroscopy Association of North America. Published by Elsevier. This is an open access article under the CC BY-NC-ND license (<http://creativecommons.org/licenses/by-nc-nd/4.0/>).

2212-6287/171249

<https://doi.org/10.1016/j.eats.2017.10.015>

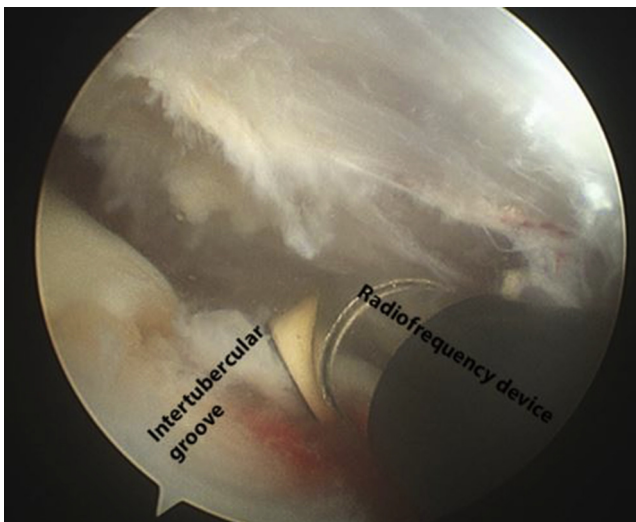


**Fig 1.** Right shoulder in the beach chair position. Arthroscopic view from the posterior portal of the long head of the biceps tendon being transected from its origin on the superior glenoid.

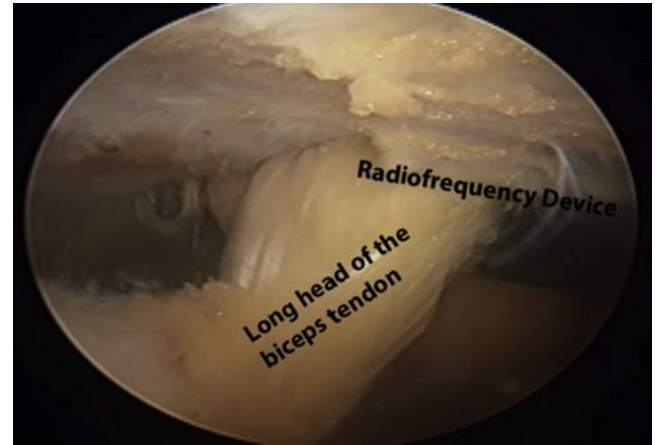
reveal positive Speed, Yergason, and O'Brien tests.<sup>9</sup> Pain at the bicipital groove is also a common clinical finding.

### Arm Positioning

With the patient in the beach chair position, the arm is placed in about 45° abduction, forward flexion, and slight external rotation to approximately 10° to 20°. Flexion of the elbow between 10° and 20° prevents overextension of the biceps muscle tendon unit during fixation.



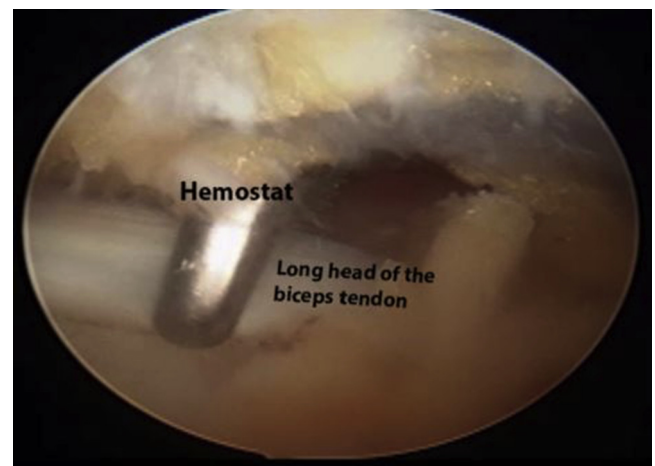
**Fig 2.** Right shoulder in the beach chair position. Arthroscopic view of the subdeltoid space from the lateral portal. The area around the superior border of the pectoralis major tendon and the distal portion of the intertubercular groove is gently debrided with a radiofrequency device beginning along the lateral aspect of the bicipital tunnel.



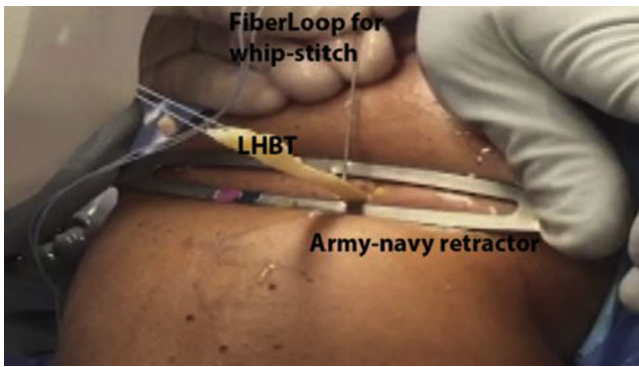
**Fig 3.** Right shoulder in the beach chair position. Arthroscopic view of the subdeltoid space from the lateral portal. The long head of the biceps tendon is mobilized from the bicipital tunnel with the radiofrequency device after adhesions are released.

### Diagnostic Arthroscopy and Portal Placement

A standard posterior viewing portal is established to inspect the intra-articular LHBT. An anterior rotator interval portal via an outside-in spinal needle technique is made to inspect the intra-articular LHBT. Percutaneously, a spinal needle is passed through the LHBT and an O PDS suture is used to mark the biceps tendon and assist with subsequent manipulation distally in the bicipital groove. After the LHBT is transected from the superior labrum with arthroscopic scissors (Fig 1), a lateral portal is created about 2 cm lateral and 1 cm anterior to the posterolateral border of the acromion. This portal allows visualization of the subdeltoid space.



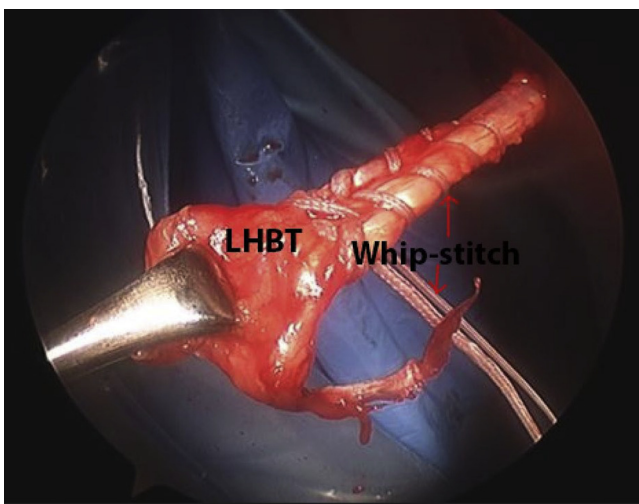
**Fig 4.** Right shoulder in the beach chair position. Arthroscopic view of the subdeltoid space from the lateral portal. A hemostat is used to remove the long head of the biceps tendon from the subdeltoid space through the accessory anterosuperolateral portal.



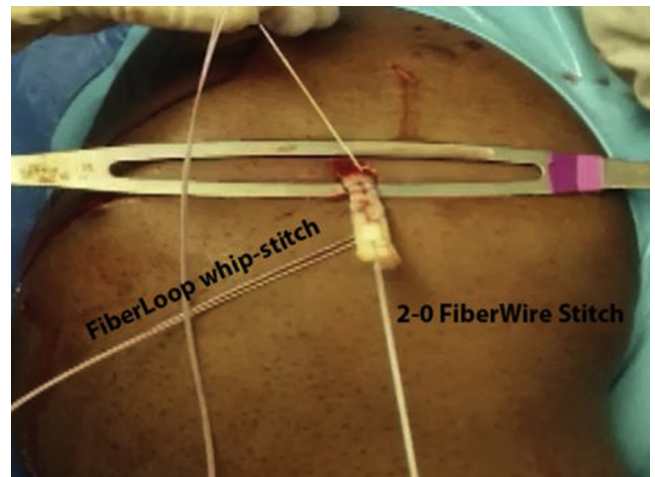
**Fig 5.** Right shoulder in the beach chair position. With the biceps tendon removed from the anterosuperolateral portal with the aid of a suture placed near the cut end, the long head of the biceps tendon is whipstitched. The open body of an army-navy retractor can be used to depress the soft tissue.

**Arthroscopic Suprapectoral Biceps Tenodesis Technique**

With the arthroscope positioned in the posterior or lateral portal, the area around the superior border of the pectoralis major tendon and the distal portion of the intertubercular groove is gently debrided with a radio-frequency device beginning along the lateral aspect of the bicipital tunnel (Fig 2). The LHBT is then mobilized by release of any adhesions and, if necessary, the distal fibers of the transverse humeral ligament (Fig 3). The superior border of the pectoralis major tendon is a consistent reference point and can facilitate identification of the LHBT for mobilization. The O PDS suture marking the proximal, intra-articular LHBT can be cycled to aid in localization. The anterior portal is typically used as the working portal for this dissection. If



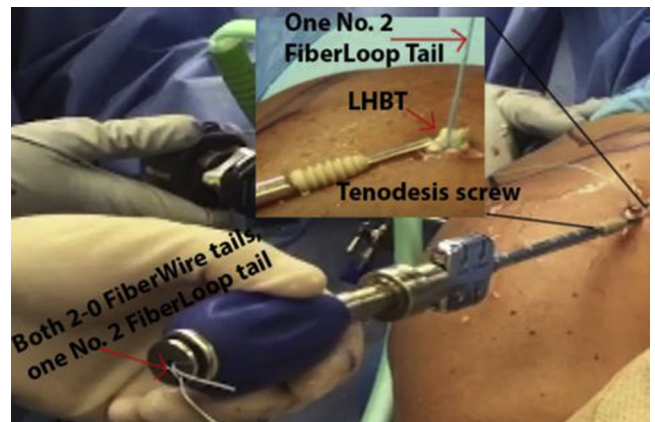
**Fig 6.** Right shoulder in the beach chair position. Gross image of the long head of the biceps tendon removed from the accessory anterosuperolateral portal on the left shoulder. Five whipstitches are passed through the tendon, leaving approximately 2 cm from the proximal end.



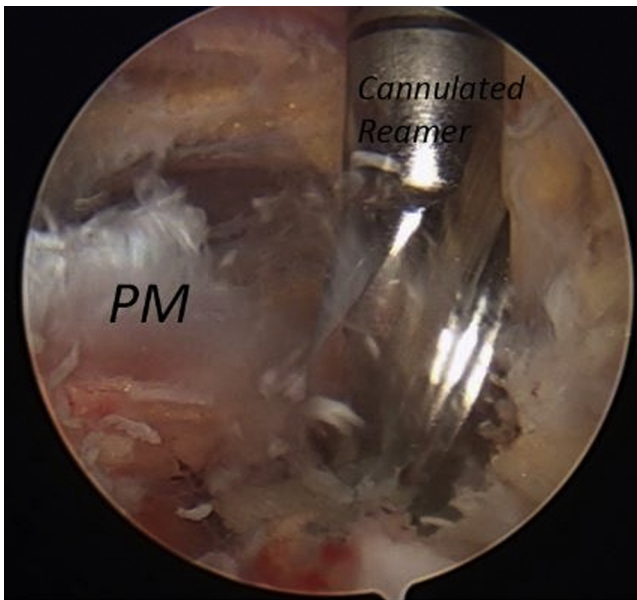
**Fig 7.** Right shoulder in the beach chair position. Gross image of the long head of the biceps tendon removed from the accessory anterosuperolateral portal on the left shoulder. After the tendon is whipstitched, a second 2-0 FiberWire suture is placed 5 to 8 mm from the proximal tip of the tendon.

necessary, the accessory anterosuperolateral portal can be made before the tendon is mobilized to assist with the dissection. This portal is localized with a spinal needle positioned perpendicular to the LHBT in zone 2, about 1.5 cm proximal to the superior border of the pectoralis major tendon. This portal will be used for subsequent bone socket preparation.

Once mobilized, the LHBT is removed from the subdeltoid space through the portal with a hemostat (Fig 4). A suture is placed near the cut end of the tendon to assist with the extraction. This technique decreases the risk of tearing the tendon during preparation for the tenodesis screw. With careful assessment of the tendon length and the tenodesis location, 5 Krackow whipstitches are then placed in the LHBT



**Fig 8.** Right shoulder in the beach chair position. Gross image of the long head of the biceps tendon removed from the accessory anterosuperolateral portal on the left shoulder. Three suture limbs are passed through the tenodesis screw, leaving one free limb. The tendon is held close to the tip of the screw to allow for increased maneuverability.



**Fig 9.** Right shoulder in the beach chair position. Arthroscopic view of the subdeltoid space visualized from the lateral portal. A guide wire followed by a cannulated reamer is advanced 1.5 cm superior to the pec major tendon via the accessory anterosuperolateral portal.

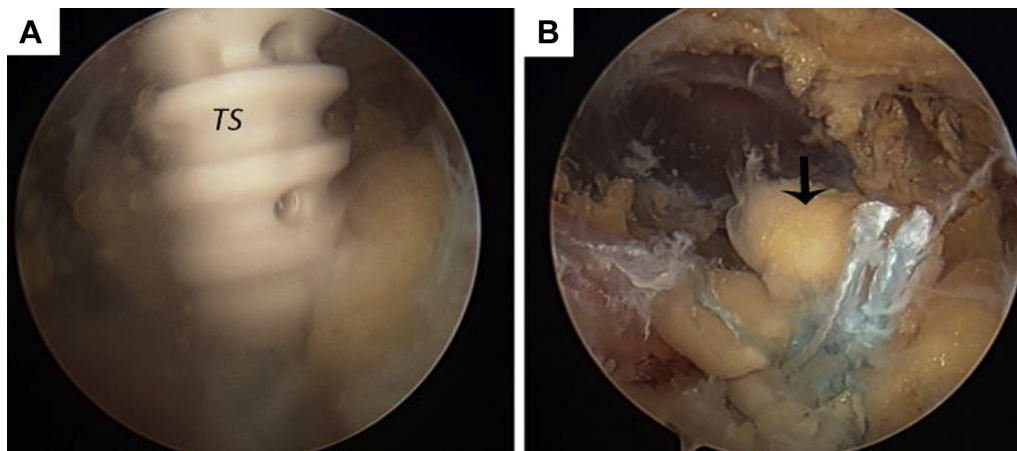
using no. 2 FiberLoop (Arthrex, Naples, FL; Fig 5). Typically, the tendon is whipstitched, leaving approximately 2 cm of tendon proximal to the FiberLoop suture (Fig 6). This portion of the tendon is then removed. A second 2-0 FiberWire (Arthrex) is then placed 5 to 8 mm from the proximal tip of the tendon to ensure that some of the tendon tissue can be advanced into the bone socket later. Particularly in larger shoulders, the LHBT cannot be retracted sufficiently to allow whipstitch placement. In these cases, the open body of an army-navy retractor over the tendon can depress soft tissues to facilitate proper whipstitching and

fastening to the tenodesis screw (Fig 7). In addition, flexing the elbow will increase tendon excursion.

Preparation of the tenodesis screw begins by passing one of the no. 2 FiberWire (Arthrex) suture tails and both 2-0 FiberWire (Arthrex) tails through the tenodesis screw. A 6.25-mm PEEK (polyether ether ketone) vented tenodesis screw (Arthrex) is used in this technique (Fig 8). Holding the tendon close to the tip of the screw with the limbs of the FiberWire, the cut end of the tendon can be maneuvered with the tenodesis driver. Once the LHBT is firmly associated with the tip of the tenodesis screw, a 2.4-mm guide wire is placed approximately 1.5 cm superior to the border of the pectoralis major tendon perpendicular to the humerus. Through the accessory anterosuperolateral portal, a cannulated 6.5-mm reamer is advanced over the guide wire and a unicortical bone socket is reamed. A 7.0-mm threaded bone tap finishes the bone socket preparation (Fig 9). Guided by the tip of the tenodesis driver, the tendon is inserted into the bone socket while visualizing through the lateral portal to ensure complete insertion of the tendon. The most distal whipstitch should be near the cortical rim of the bone socket. The authors believe that the whipstitch is critical for tendon reinforcement to preserve tendon integrity during insertion of the tenodesis screw. The suture tails are then tied to one another with 5 alternating half hitches using an arthroscopic knot pusher to reinforce the tenodesis construct. This creates a closed loop through the cannulated tenodesis screw, which prevents tendon slippage past the screw. The suture tails are cut to finalize this technique (Fig 10).

## Discussion

This technique uses an interference screw to fix the LHBT at a site distal to the bony bicipital tunnel, proximal to the superior border of the pectoralis major



**Fig 10.** Right shoulder in the beach chair position. Arthroscopic view of the subdeltoid space visualized from the lateral portal. (A) The long head of the biceps tendon (arrowhead) implanted and secured with the tenodesis screw (TS). (B) The final fixation of the long head of the biceps tendon (arrowhead) superior to the pectoralis major tendon.

tendon. The strength of this construct has been shown to be similar to techniques involving tenodesis screws distal to the superior border of the pectoralis major tendon, described as subpectoral locations. In addition, this technique provides a method to incorporate whipstitching with an arthroscopic tenodesis screw to reinforce the fixation construct. This technique is also advantageous in that it allows full visualization of the LHBT dissection and tenodesis steps of the technique (Table 1).

The biomechanical strength of various tenodesis constructs has been previously investigated. A cadaveric study by Werner et al.<sup>5</sup> compared suprapectoral biceps tenodesis to subpectoral biceps tenodesis techniques. Load-to-failure testing was performed and found the suprapectoral group to have a significantly decreased load to failure compared with the subpectoral group. Of note, the 2 techniques differed in the tenodesis construct as the tendon was whipstitched in the subpectoral tenodesis, while the tendon was not whipstitched in the suprapectoral tenodesis. Our tenodesis construct differs in this regard and may offer additional biomechanical strength. Thus, the implications of this biomechanical study are unclear with respect to our technique.

There is a relative paucity of randomized clinical trials comparing subpectoral and suprapectoral tenodesis techniques.<sup>7,10</sup> However, several retrospective studies afford clinical evidence for various tenodesis locations and techniques.<sup>7,10</sup> Werner et al. compared subpectoral and suprapectoral tenodesis using an interference screw with a minimum 2-year follow-up and found no significant differences in several shoulder scores (Constant-Murley, ASES, SANE, SST, LHB score, and VR-36) between groups. They also found no range-of-motion or strength deficits in either group after 2 years of follow-up.

One concern that has been raised about an arthroscopic biceps tenodesis technique is that patients may have persistent bicipital groove pain and tendinopathy if a proximal tenodesis site leaves a portion of the tendon within the bicipital groove.<sup>11,12</sup> Intra-articular

**Table 1.** Advantages and Limitations

Advantages
<ul style="list-style-type: none"> <li>• Full visualization of tenodesis location.</li> <li>• Full visualization of technique.</li> <li>• Whipstitches provide additional strength to the tendon for tenodesis.</li> <li>• Neurovascular structures are further from the working tenodesis area and less at risk.</li> </ul>
Limitations
<ul style="list-style-type: none"> <li>• Tendon extraction may be limited in shoulders with excess soft tissues.</li> <li>• Severe tendinosis distal to the bicipital groove may reduce strength of the tendon, risking rupture during technique.</li> <li>• Does not address most distal biceps tendon disease; the tendon deep to the pectoralis major is not excised.</li> </ul>

**Table 2.** Pearls and Pitfalls

Pearls	Pitfalls
<ul style="list-style-type: none"> <li>• Use an army/navy retractor to depress soft tissue to facilitate whipstitching the tendon.</li> <li>• A “holding” simple suture at the most proximal end of the transected tendon improves tendon extraction.</li> <li>• Ensure the tendon is firmly held at the tip of the tenodesis screw to facilitate tendon maneuvering.</li> <li>• Consider performing tenodesis early, before significant soft tissue swelling occurs.</li> </ul>	<ul style="list-style-type: none"> <li>• Extraction of tendon with severe inflammation may result in tearing and necessitate a more distal technique.</li> <li>• Using an Allis clamp for tendon extraction may tear the tendon.</li> <li>• Soft tissue swelling from arthroscopic fluid may increase difficulty of tendon extraction.</li> </ul>

findings of biceps tenosynovitis continuing distally into the bicipital groove suggest an inflammatory component within the groove and support this hypothesis.<sup>10</sup> Although the arthroscopic tenodesis technique described in this study is proximal to the pectoral tendon, the tenodesis site is distal to the bicipital groove. The tenodesis site is in zone 2, described as No Man’s Land, which results in complete removal of the LHBT from the bony bicipital groove.<sup>8</sup> Because no portion of the tendon remains in the groove, the incidence of persistent post-operative pain may be reduced.<sup>10</sup> This presented technique for biceps tenodesis can serve as another approach to consider for tenodesis of the long head of the biceps tendon (Table 2).

**References**

1. Abraham VT, Tan BHM, Kumar VP. Systematic review of biceps tenodesis: arthroscopic versus open. *Arthroscopy* 2016;32:365-371.
2. Patel KV, Bravman J, Vidal A, Chrisman A, McCarty E. Biceps tenotomy versus tenodesis. *Clin Sports Med* 2016;35:93-111.
3. Tahal DS, Katthagen JC, Vap AR, Horan MP, Millett PJ. Subpectoral biceps tenodesis for tenosynovitis of the long head of the biceps in active patients younger than 45 years old. *Arthroscopy* 2017;33:1124-1130.
4. Slenker NR, Lawson K, Ciccotti MG, Dodson CC, Cohen SB. Biceps tenotomy versus tenodesis: clinical outcomes. *Arthroscopy* 2012;28:576-582.
5. Werner BC, Lyons ML, Evans CL, et al. Arthroscopic suprapectoral and open subpectoral biceps tenodesis: a comparison of restoration of length-tension and mechanical strength between techniques. *Arthroscopy* 2015;31:620-627.
6. Dickens JF, Kilcoyne KG, Tintle SM, Giuliani J, Schaefer RA, Rue J-P. Subpectoral biceps tenodesis: an anatomic study and evaluation of at-risk structures. *Am J Sports Med* 2012;40:2337-2341.
7. Werner BC, Evans CL, Holzgrefe RE, et al. Arthroscopic suprapectoral and open subpectoral biceps tenodesis: a comparison of minimum 2-year clinical outcomes. *Am J Sports Med* 2014;42:2583-2590.

8. Taylor SA, Fabricant PD, Bansal M, et al. The anatomy and histology of the bicipital tunnel of the shoulder. *J Shoulder Elbow Surg* 2015;24:511-519.
9. Hegedus EJ, Goode AP, Cook CE, et al. Which physical examination tests provide clinicians with the most value when examining the shoulder? Update of a systematic review with meta-analysis of individual tests. *Br J Sports Med* 2012;46:964.
10. Gombera MM, Kahlenberg CA, Nair R, Saltzman MD, Terry MA. All-arthroscopic suprapectoral versus open subpectoral tenodesis of the long head of the biceps brachii. *Am J Sports Med* 2015;43:1077-1083.
11. Sanders B, Lavery KP, Pennington S, Warner JJP. Clinical success of biceps tenodesis with and without release of the transverse humeral ligament. *J Shoulder Elbow Surg* 2012;21:66-71.
12. Johannsen AM, Macalena JA, Carson EW, Tompkins M. Anatomic and radiographic comparison of arthroscopic suprapectoral and open subpectoral biceps tenodesis sites. *Am J Sports Med* 2013;41:2919-2924.