

A Challenging Colectomy for Acute Severe Ulcerative Colitis Complicated by COVID-19

Key Words: COVID-19, SARS-CoV-2, IBD, surgery, colectomy

INTRODUCTION

Inflammatory bowel diseases (IBD), including ulcerative colitis (UC) and Crohn disease, are conditions with variable clinical patterns and multiple disease courses.¹ About 20-40% of patients with IBD require immunomodulating biological treatment, which is associated with an increased risk of various infections. When such treatment fails, surgery often represents the next valid option.²

Recently, management of patients with IBD has been severely disrupted by the SARS-CoV-2 outbreak.³ Since January 2020, SARS-CoV-2 has rapidly spread to many countries, with Northern Italy being one of the worst-affected areas.⁴ The Italian national health care system underwent swift and significant alterations to address the emergency, with hospitals deferring elective services and activities, including surgery. Access to IBD units was limited to patients with disease flares only and for dispensing biological drugs.^{5, 6} No data or formal recommendations for the management of patients with IBD with concomitant COVID-19 were available during the first phase of the emergency.⁷

We report here the case of a patient with acute severe ulcerative colitis (ASUC) complicated by COVID-19 who required an urgent colectomy after a prolonged hospitalization.

CASE PRESENTATION

On February 28, 2020, a female patient aged 60 years affected by long-standing, left-sided UC was admitted with a severe disease flare to the gastroenterology unit of the Istituto di Ricovero e Cura a Carattere Scientifico Sacro Cuore Don Calabria, Negrar di Valpolicella (Verona), Italy, presenting with bloody diarrhea, up to 10 bowel movements per day, abdominal pain, and fatigue.

A week earlier, the patient had received an infusion of the infliximab biosimilar CT-P13,⁸ which was interrupted because of a severe reaction. At admission, laboratory tests showed mild anemia (hemoglobin level of 11 g/dL) and a C-reactive protein level of 35 mg/dL, and her body temperature was 36.8°C. Infection and toxic megacolon were dismissed, and a sigmoidoscopy revealed severe disease with large, deep ulcers and mucosal friability (Fig. 1A). Therefore, intravenous corticosteroid therapy with anti-thrombotic prophylaxis and total parenteral nutrition were started.

During the following 5 days, clinical features did not improve. A second

sigmoidoscopy confirmed no improvement (Fig. 1B), and no feasible “rescue” therapy was obvious because of the previous failure of infliximab and the poor safety record of cyclosporine. Thus, the multidisciplinary team (MDT) agreed upon an elective colectomy and accelerated steroid tapering was initiated.

Unfortunately, the patient developed a fever with a dry cough and dyspnea in the subsequent days. A diagnosis of SARS-CoV-2 infection was reached on March 12 after real-time polymerase chain reaction testing of a nasopharyngeal swab.⁹ Chest radiography and a chest computed tomography scan showed multiple pulmonary infiltrates and areas of parenchymal thickening, with bilateral “ground-glass” opacities, confirming COVID-19-related pneumonia (Fig. 2).

The patient was transferred to a dedicated COVID-19 unit and treated with oral hydroxychloroquine and darunavir/cobicistat along with supplemental oxygen for 10 days¹⁰ as per local treatment protocol. Her ASUC symptoms worsened to up to 12 bowel movements per day, with continued abdominal pain and persistent hypoalbuminemia requiring albumin supplementation and blood transfusions for worsening anemia.

In the absence of any COVID-19 surgery protocol, colectomy was repeatedly delayed because of

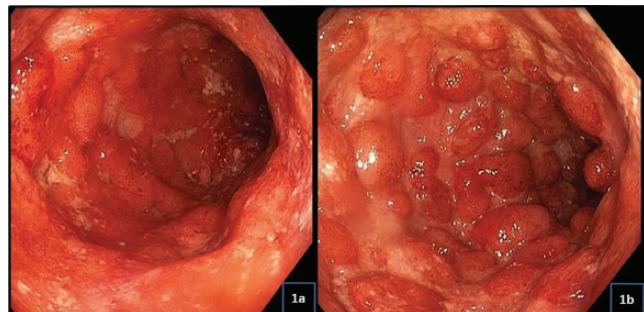

FIGURE 1. Endoscopic images showing severe inflammation features at admission (A) and after 5 days of intravenous corticosteroids (B).

COVID-19-related risks such as postoperative respiratory failure and because of the patient's nutritional status. Repeat nasopharyngeal swabs tested positive, and septic shock occurred because of a central venous catheter-related infection; the septic shock was

promptly resolved with daptomycin and meropenem.

Respiratory conditions slowly improved over the following days, and on April 7 a chest CT scan revealed a substantial regression of pneumonia. Thus, the MDT decided upon an urgent

colectomy in adherence with a dedicated COVID-19 surgical care pathway because nasopharyngeal swabs continued to test positive. On April 10, the patient underwent a laparoscopic colectomy with terminal ileostomy in a dedicated COVID-19 operating room (Figs. 3 and 4).

There were no acute surgical complications, and the ileostomy remains viable. No signs of respiratory failure were apparent in the postoperative phase. However, because of recurrent discharge from the inflamed rectal stump and a new central venous catheter-related infection, a combination of meropenem, daptomycin, and caspofungin was prescribed.

On April 18, 8 days after surgery, the patient's body temperature was stable at 37°C, rectal discharge had decreased, and serum inflammation markers had improved. On April 28, 2020, a negative result was obtained from a nasopharyngeal swab, and the patient was discharged the following day.

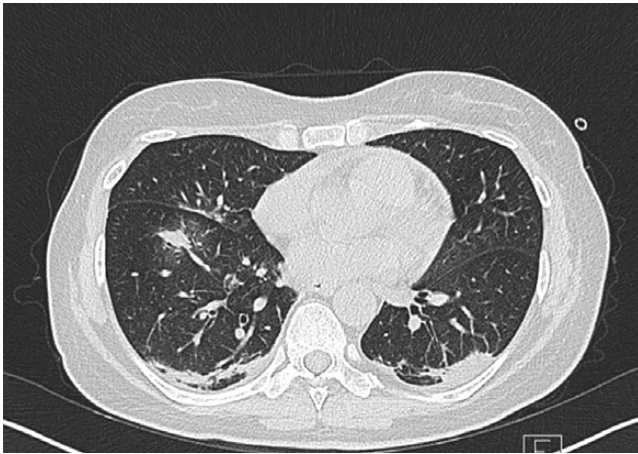


FIGURE 2. Chest computed tomography scan image showing lung opacities.

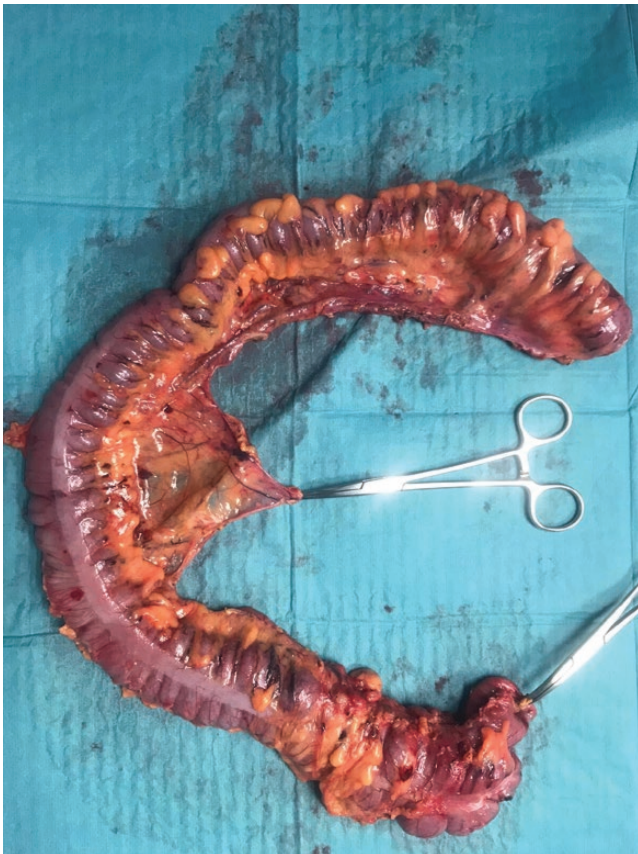

FIGURE 3. The colonic specimen after the urgent colectomy.

DISCUSSION

We have reported the complex multidisciplinary management of a patient with ASUC undergoing a colectomy while suffering COVID-19-related pneumonia. In reviewing the recent literature, we determined that this is one of the first such reports.

The European COVID-19 outbreak seems to have started in January 2020. With Italy at its center, an emergency was declared, and management strategies for patients with IBD were dramatically affected. The World Health Organization¹¹ and the International Organization for the Study of Inflammatory Bowel Disease¹² advised avoiding routine corticosteroids and canceling or postponing elective surgery. Formal recommendations, published only recently, have since confirmed these indications.^{13, 14} Furthermore, a preliminary report on the clinical outcomes of COVID-19 in patients with IBD has shown that active disease, older age, and comorbidities are associated with worse outcomes.¹⁵

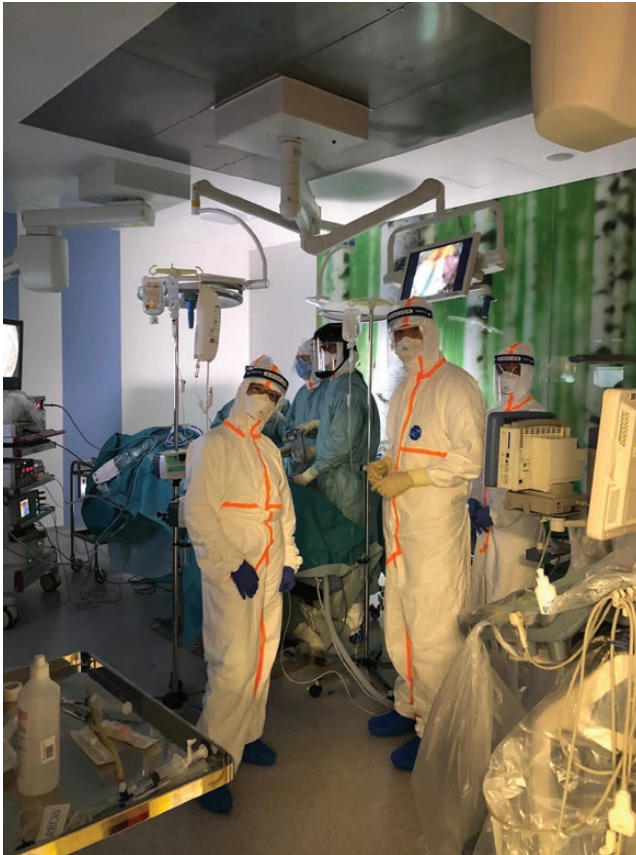

FIGURE 4. The COVID-19 operating room.

Our patient with ASUC and concomitant COVID-19 represented a significant management challenge. She developed a severe IBD flare requiring corticosteroid treatment, increasing the risk of a negative COVID-19 outcome. The persistence of COVID-19-related pneumonia and the progressive worsening of her IBD led to a prolonged hospital stay and several MDT discussions. The necessary colectomy, initially elective and then urgent, was hindered by infection complications, logistical difficulties, and the lack of real-world COVID-19 case studies to refer to.

The worsening of a patient's clinical condition before surgery because of anemia, hypoalbuminemia, and infection is a known risk factor for surgical complications.¹⁶ Such conditions often

lead to a prolonged, complicated post-operative course even in the absence of COVID-19. Further case studies are needed to better evaluate the timing of surgical intervention in situations such as this.

Mirko Di Ruscio, MD,*
Angela Variola, MD,*
Andrea Angheben, MD,†
Silvia Resimini, DSc,‡
Andrea Geccherle, MD,*
Giacomo Ruffo, MD,§ and
Giuliano Barugola, MD§

From the *IBD Unit, Istituto di Ricovero e Cura a Carattere Scientifico Sacro Cuore Don Calabria, Negrar di Valpolicella (Verona), Italy; †Department of Infectious Tropical Diseases and Microbiology, Istituto di Ricovero e Cura a Carattere Scientifico Sacro Cuore

Don Calabria, Negrar di Valpolicella (Verona), Italy; ‡Clinical Research Unit, Istituto di Ricovero e Cura a Carattere Scientifico Sacro Cuore Don Calabria, Negrar di Valpolicella (Verona), Italy; §Department of Surgery, Istituto di Ricovero e Cura a Carattere Scientifico Sacro Cuore Don Calabria, Negrar di Valpolicella (Verona), Italy

Author contributions: MDR and AV wrote the article. SR collected the data. AG, GR, and GB critically reviewed the article. All authors have read and approved the article.

Supported by: This publication was supported by the Italian Ministry of Health Fondi Ricerca Corrente-Linea 3 for the Istituto di Ricovero e Cura a Carattere Scientifico Sacro Cuore Don Calabria Hospital.

Address correspondence to: Mirko Di Ruscio, IBD Unit, Istituto di Ricovero e Cura a Carattere Scientifico Sacro Cuore Don Calabria, Via Don A. Sempredoni 5, 37024 Negrar di Valpolicella (Verona), Italy (mirkodiruscio88@gmail.com; mirko.diruscio@sacrocuore.it).

ACKNOWLEDGMENTS

The authors thank Elinor Julie Rae Anderson for language editing. Patient verbal and formal consent for publication was given.

REFERENCES

- Ungaro R, Mehandru S, Allen PB, et al. Ulcerative colitis. *Lancet*. 2017;389:1756–1770.
- Wong DJ, Roth EM, Feuerstein JD, et al. Surgery in the age of biologics. *Gastroenterol Rep (Oxf)*. 2019;7:77–90.
- Huang C, Wang Y, Li X, et al. Clinical features of patients infected with 2019 novel coronavirus in Wuhan, China. *Lancet*. 2020;395:497–506.
- Remuzzi A, Remuzzi G. COVID-19 and Italy: what next? *Lancet*. 2020;395:1225–1228.
- Magro F, Abreu C, Rahier JF. The daily impact of COVID-19 in gastroenterology. *United European Gastroenterol J*. 2020;2050640620920157.
- Danese S, Ceccconi M, Spinelli A. Management of IBD during the COVID-19 outbreak: resetting clinical priorities. *Nat Rev Gastroenterol Hepatol*. 2020.
- Rubin DT, Feuerstein JD, Wang AY, et al. AGA clinical practice update on management of inflammatory bowel disease during the COVID-19 pandemic: expert commentary. *Gastroenterology*. 2020. S0016-5085(20)30482-0.
- Albshesh A, Ben-Horin S. CT-P13: a review on a biosimilar to infliximab in the treatment of inflammatory bowel disease. *Expert Opin Biol Ther*. 2019;19:971–978.
- Corman VM, Landt O, Molenkamp R, et al. Detection of 2019 novel coronavirus (2019-nCoV) by real-time RT-PCR. *Euro Surveill*. 2020;25:2000045.
- Costanzo M, De Giglio MAR, Roviello GN. SARS CoV-2: recent reports on antiviral therapies based on lopinavir/ritonavir, darunavir/umifenovir, hydroxychloroquine, remdesivir, favipiravir and other drugs for the treatment of the new coronavirus. *Curr Med Chem*. 2020.

11. World Health Organization. *Clinical management of severe acute respiratory infection (SARI) when COVID-19 disease is suspected: interim guidance, 13 March 2020* (License: CC BY-NC-SA 3.0 IGO). [https:// apps. who. int/ iris/handle/ 10665/ 331446](https://apps.who.int/iris/handle/10665/331446) (May 2020, date last accessed).
12. International Organization for the Study of Inflammatory Bowel Disease. IOIBD update on COVID19 for patients with Crohn's disease and ulcerative colitis. <https://www.ioibd.org/ioibd-update-on-covid19-for-patients-with-crohns-disease-and-ulcerative-colitis/> (May 2020, date last accessed).
13. Kennedy NA, Jones GR, Lamb CA, et al. British Society of Gastroenterology guidance for management of inflammatory bowel disease during the COVID-19 pandemic. *Gut*. 2020;69:984–990.
14. Remzi FH, Panis Y, Spinelli A, et al. International Organization for the Study of IBD recommendations for surgery in patients with IBD during the coronavirus disease 2019 pandemic. *Dis Colon Rectum*. 2020;63:870–873.
15. Bezzio C, Saibeni S, Variola A, et al. Outcomes of COVID-19 in 79 patients with inflammatory bowel disease in Italy. *Gut*. 2020. pii: [gutjnl-2020-321411](https://doi.org/10.1136/gutjnl-2020-321411).
16. Schineis C, Lehmann KS, Lauscher JC, et al. Colectomy with ileostomy for severe ulcerative colitis-postoperative complications and risk factors. *Int J Colorectal Dis*. 2020;35:387–394.