

Successful Intralesional Laser Therapy for Sclerotherapy-resistant Huge Venous Malformation

Yoshitaka Wada, MD, PhD*
 Hidetaka Miyazaki, DDS, PhD†
 Hirohisa Kusuhara, MD, PhD‡
 Kazuhisa Uemura, MD*
 Shinichi Asamura, MD, PhD*

Summary: Venous malformations (VMs) are compressible, blue-purple tumors that are present at birth, and are treated with either surgery or sclerotherapy, or a combination of both. Patients often experience recurrent hemorrhage, swelling, pain, or difficulty in daily life. Treatment of massive VMs can, therefore, be challenging. We applied intralesional laser photocoagulation (ILP) to a 19-year-old female patient with a huge VM who had shown resistance to sclerotherapy. It spanned from the dorsal area to the lateral chest. ILP is delivered directly into thick, deep lesions through a bare fiber delivery system. The effect on deep components is optimized without directly contacting the cutaneous or mucosal surfaces to minimize epithelial damage. We applied ILP to the lesion at 30 W in continuous mode (10 seconds) under ultrasound monitoring using an Nd:YAG laser of 1064-nm wavelength. In total, there have been 4 sessions of the same treatment; the lesion was treated with a combined 120 kJ of energy. Satisfactory regression of the huge VM was achieved by this ILP treatment. No significant complications (major bleeding, severe pain, post-perforation skin ulcer, and scar contraction) occurred during the treatment. ILP has been indicated for only sclerotherapy-resistant cases until now, but we suggest that it is a potentially safe and minimally-invasive resolution of VM without scarring or loss of normal shape, sensory feel, or function. ILP appears to be a safe and minimally-invasive resolution of VM. We propose that this technique could become a first-choice treatment modality for VM. (*Plast Reconstr Surg Glob Open* 2020;8:e3269; doi: [10.1097/GOX.0000000000003269](https://doi.org/10.1097/GOX.0000000000003269); Published online 17 December 2020.)

INTRODUCTION

Venous malformations (VMs) are compressible, blue-purple tumors that are present at birth, and are treated with either surgery or sclerotherapy, or a combination of both. Patients often experience recurrent hemorrhage, swelling, pain, or difficulty in daily life.¹⁻³ Treatment of massive VMs can, therefore, be challenging.

The clinical use of intralesional laser photocoagulation (ILP) for treatment of VM was first reported a

quarter-century ago.⁴ Although some surgeons have subsequently reported successful results using ILP, it has not been widely reported in recent years. In all cases where ILP was used for the treatment of large VMs in the oral-maxillofacial region, results have been good and patient satisfaction has been high.^{1,5-8} Therefore, surgeons have started to be used for VM in the limbs or trunk.

Here, we present our techniques and results, and discuss the efficacy of the use of ILP against sclerotherapy-resistant VM. We present 1 of our cases as a demonstration. The patient had a huge VM in the trunk who had been resistant to sclerotherapy. We achieved safe and satisfactory regression of the VM using ILP.

PATIENT AND METHODS

A 19-year-old woman presented with an enlarging blue-colored lesion, secondary to an extensive venous lesion that involved an area spanning the dorsal area and the

From the *Department of Plastic and Reconstructive Surgery, Wakayama Medical University, Wakayama-shi, Wakayama, Japan; †Department of Oral and Maxillofacial Surgery, Faculty of Medicine, Oita University, Hasama-machi, Yufu-shi, Oita, Japan; and ‡Department of Plastic and Reconstructive Surgery, Faculty of Medicine, Kindai University, Osakasayama-shi, Osaka, Japan.

Drs. Wada and Miyazaki contributed equally to this work.

Received for publication March 3, 2020; accepted September 30, 2020.

Copyright © 2020 The Authors. Published by Wolters Kluwer Health, Inc. on behalf of The American Society of Plastic Surgeons. This is an open-access article distributed under the terms of the [Creative Commons Attribution-Non Commercial-No Derivatives License 4.0 \(CCBY-NC-ND\)](https://creativecommons.org/licenses/by-nc-nd/4.0/), where it is permissible to download and share the work provided it is properly cited. The work cannot be changed in any way or used commercially without permission from the journal.

DOI: [10.1097/GOX.0000000000003269](https://doi.org/10.1097/GOX.0000000000003269)

Disclosure: The authors have no financial interest to declare in relation to the content of this article.

Related Digital Media are available in the full-text version of the article on www.PRSGlobalOpen.com.

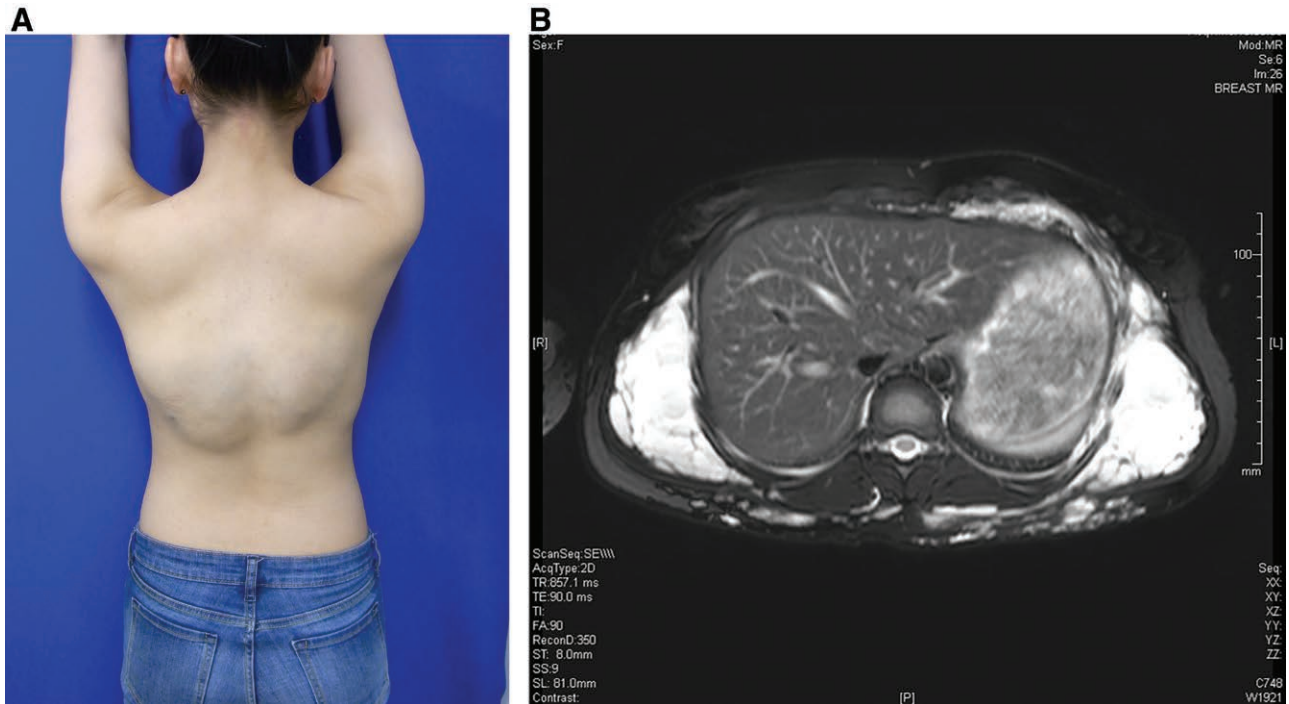


Fig. 1. Pre-treatment findings. A, Venous malformation from the dorsal area to the lateral chest, enlarging and blue in color. B, Preoperative MRI showing the lesion (arrowheads). It involves the dorsal and the lateral chest area.

lateral chest. She frequently felt pain and weight on her back. Sclerotherapy with anhydrous ethanol had been used for several years in another hospital, but the effect was limited and the patient was dissatisfied (Fig. 1).

We applied ILP to the lesion at 30 W in continuous mode (10 seconds) under ultrasound (US) monitoring using a Nd-YAG laser at 1064-nm wavelength (VersaPulse Holmium/Nd-YAG Laser Dual Wave length model; Lumenis Ltd., Yokneam, Israel) with a 0.55-mm fiber. (see Video 1 [Online], which shows ultrasound B mode image of the vascular lesion during ILP Laser irradiation of the vascular lesion through the inserted fiber. An increase of the US signal density is observed at the fiber tip.) Several skin perforations were needed to access the entire lesion. Over a year and a half, 4 sessions of the same treatment took place and the lesion was treated with 120 kJ of energy in total. Satisfactory regression of the huge VM was achieved by ILP treatment. No significant complications occurred during the treatment (major bleeding, severe pain, skin ulcer, or scar contraction post perforation). Clinical examination and MRI 2 years after the first treatment showed effective regression and palliation of the VM symptoms (Fig. 2). The patient provided informed consent to inclusion in this report.

DISCUSSION

VM consists of dysplastic capillary, arterial, venous, or lymphatic vessel elements, and it can essentially involve any tissue or anatomic area. They are the most common type of vascular malformations and vary widely in their presentations. They undergo accelerated growth during adolescence and pregnancy and following traumas (including

surgery).⁸ Treatment of huge VM often aims to control the symptoms. Sclerotherapy has been considered to be the standard treatment modality for VM, but the majority of cases are resistant to it, depending on the location, size, and symptoms.⁹ Use of sclerosant carries a serious risk of local side-effects (swelling, nerve injury, necrosis, and scarring) and systemic side effects (pulmonary embolism, cardiac arrest, pulmonary hypertension, and acute renal failure).^{10,11} Sclerotherapy can involve intraoperative exposure to radiation. For these reasons, treatment centered on control of symptoms has been considered to be appropriate, rather than wide and radical removal of the lesion.⁸

We have applied ILP to 3 patients with VM on the trunk and lips who had shown resistance to sclerotherapy. ILP is effective and safe for treatment of massive vascular lesions. In this technique, laser energy is delivered directly into thick, deep lesions through a bare fiber delivery system, thereby maximizing the effect on deep components. There is no direct contact with the cutaneous or mucosal surface; so epithelial damage is minimized.¹ We preoperatively confirm by MRI and ultrasonography if the extent and border of the lesion can be clearly drawn. ILP is partly a “blind” technique; so there is a risk of unintended destruction of surrounding tissue. To minimize risk, we routinely use ultrasound navigation for ILP.^{6,12,13}

In the featured patient, we had concern whether the laser-coagulated debris, hemolytic hemoglobin, and/or cytokine might be released into the circulation because it was such a large case of VM. This could potentially induce pulmonary embolism or could affect other important organs, but there have been no previous reports of systemic side effects. We frequently examined urine and

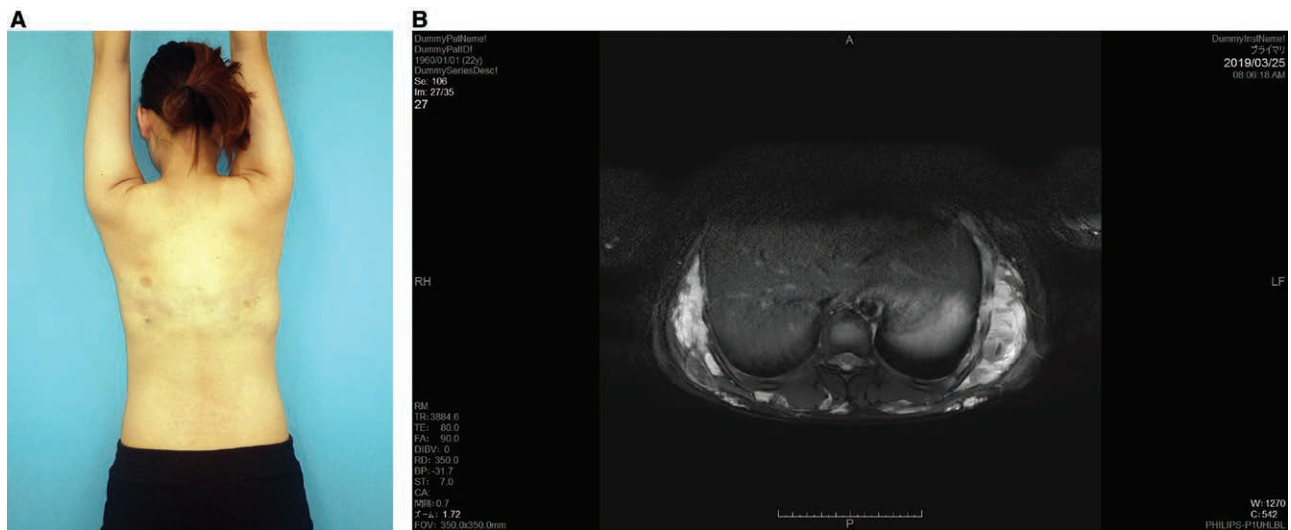

Fig. 2. Post-treatment findings. A, One year after the 4 treatment sessions, there is marked regression of the lesion without scarring or contracture. B, MRI 6 months after the 4 treatment sessions, showing regression of the lesion (arrowheads). Satisfactory regression without scarring and contracture was achieved in venous malformation treated with ILP. Video Ultrasound B mode image of the vascular lesion during ILP laser irradiation of the vascular lesion through the inserted fiber. An increase in the US signal density is observed at the fiber tip.

blood from ILP procedures. No gross hematuria was observed, but myoglobinuria was observed in all sessions. As a precautionary measure against renal failure, we increased the volume of infusion for 1 week after treatment. Similar continued careful monitoring management and collection of information are considered necessary.

No definite guidelines related to the treatment of VM have been determined on a global level. In our institution, we have used ILP for 3 cases of VM, each resulted in excellent patient satisfaction. We suggest there will be similar effectiveness of procedures that can be performed in other cases of VM in the trunk.

Accurate and careful evaluation before and after the treatment is essential for selection of an appropriate treatment strategy. Although ILP has been indicated for only sclerotherapy-resistant cases until now, the present case showed it can be an effective treatment over the short-term for cases that have been resistant to sclerotherapy. A large-scale demonstration of this procedure with more patients is needed to prove and strengthen its effectiveness, and the need for a long-term follow-up is crucial to evaluate future success.

CONCLUSIONS

ILP appears to be a safe and minimally-invasive resolution of VM. It does not lead to scarring or loss of normal shape, sensory feel, or function. Although it has been indicated for only sclerotherapy-resistant cases until now, we propose that this technique could become a first-choice treatment modality for VM.

Yoshitaka Wada, MD, PhD

Department of Plastic and Reconstructive Surgery
Wakayama Medical University
Wakayama-shi, Wakayama
641-8509, Japan
E-mail: wada@wakayama-med.ac.jp

ACKNOWLEDGMENT

We acknowledge editing and proofreading by Benjamin Phillis from the Clinical Study Support Center at Wakayama Medical University. Funds were from institutional sources only.

REFERENCES

- Miyazaki H, Ohshiro T, Romeo U, et al. Retrospective study on laser treatment of oral vascular lesions using the "leopard technique": the multiple spot irradiation technique with a single-pulsed wave. *Photomed Laser Surg.* 2018;36:320–325.
- Enjolars O, Wassef M, Chapot R. Introduction: ISSVA classification; venous malformations (VM). In: Enjolars O, Wassef M, Chapot R, ed. *Color Atlas of Vascular Tumors and Vascular Malformations*. New York, N.Y.: Cambridge University Press, 2007:1–11, 168–223.
- Miyazaki H, Kato J, Watanabe H, et al. Intralesional laser treatment of voluminous vascular lesions in the oral cavity. *Oral Surg Oral Med Oral Pathol Oral Radiol Endod.* 2009;107:164–172.
- Apfelberg DB. Intralesional laser photocoagulation-steroids as an adjunct to surgery for massive hemangiomas and vascular malformations. *Ann Plast Surg.* 1995;35:144–148.
- Miyazaki H, Romeo U, Ohshiro T, et al. Treatment strategies for large oral venous malformations using intralesional laser photocoagulation. *Lasers Med Sci.* 2014;29:1987–1990.
- Miyazaki H, Ohshiro T, Watanabe H, et al. Ultrasound-guided intralesional laser treatment of venous malformation in the oral cavity. *Int J Oral Maxillofac Surg.* 2013;42:281–287.
- Asai T, Suzuki H, Takeuchi J, et al. Effectiveness of photocoagulation using an Nd:YAG laser for the treatment of vascular malformations in the oral region. *Photomed Laser Surg.* 2014;32:75–80.
- Nassiri N, Thomas J, Cirillo-Penn NC. Evaluation and management of peripheral venous and lymphatic malformations. *J Vasc Surg Venous Lymphat Disord.* 2016;4:257–265.
- Mimura H, Fujiwara H, Hiraki T, et al. Polidocanol sclerotherapy for painful venous malformations: evaluation of safety and efficacy in pain relief. *Eur Radiol.* 2009;19:2474–2480.

10. Berenguer B, Burrows PE, Zurakowski D, et al. Sclerotherapy of craniofacial venous malformations: complications and results. *Plast Reconstr Surg.* 1999;104:1–11.
11. Prasetyono TO, Kreshanti P. Efficacy of intra-lesional alcohol injection as alternative and/or complementary treatment of vascular malformations: a systematic review. *J Plast Reconstr Aesthet Surg.* 2010;63:1071–1079.
12. Ma LW, Levi B, Oppenheimer AJ, et al. Intralesional laser therapy for vascular malformations. *Ann Plast Surg.* 2014;73:547–551.
13. Liu G, Liu X, Li W, et al. Ultrasound-guided intralesional diode laser treatment of congenital extratruncular venous malformations: mid-term results. *Eur J Vasc Endovasc Surg.* 2014;47:558–564.