



ELSEVIER

Contents lists available at ScienceDirect

JPRAS Open

journal homepage: www.elsevier.com/locate/jpra

Original Article

The utility of a novel vacuum-assisted foreign body extraction technique from wounds

Waleed Khalid Albayati^a, Nawras Farhan^{a,*},
Ahmed Khalaf Jasim^b, Yasir Naif Qassim^b, Ali Adwal Ali^c

^a Ghazi al-Hariri Surgical Specialties Hospital, Department of Plastic and Reconstructive Surgery, Medical City, Baghdad, Iraq

^b Department of Surgery, College of Medicine, Baghdad University, Baghdad, Iraq

^c Department of Surgery, College of Medicine, Kirkuk University, Kirkuk, Iraq

ARTICLE INFO

Article history:

Received 20 September 2020

Accepted 10 October 2020

Available online 17 November 2020

Keywords:

Foreign bodies

FB

Novel

Vacuum

Negative pressure

Soft tissues

ABSTRACT

Retained soft tissue foreign bodies following injuries are frequently seen in the Emergency and Plastic Surgery practice. The patients with such presentations require a watchful and detailed clinical assessment to overcome the anticipant possibility of missing them. However, the diagnosis based on the clinical evaluation is usually challenging and needs to be supported by imaging modalities that are suboptimal and may fail in identifying some types of foreign bodies. Owing to that, serious complications such as chronic pain, infection, and delayed wound healing can be faced that necessitate a prompt intervention to halt those detrimental consequences. The classical method of removal is a surgical exploration which is not free of risks. It can cause injuries to vital structures such as nerves and tendons if the foreign body is close to them, also it can be affected by the surgeon's experience and the foreign body's characteristics.

In light of that, we conducted a single-center study to understand the utility of a novel vacuum-assisted technique for foreign body removal. The technique is noninvasive and facilitates a real-time foreign body extraction using readily available materials. Twenty patients with 23 Foreign Bodies of various kinds, shapes, and sizes were recruited in our study by using a nonprobability convenient

* Corresponding author.

E-mail address: nawras.farhan@nhs.net (N. Farhan).

sampling method. Results demonstrated the ability of the described technique to extract 22 of them with no noticeable side effects. This study may encourage further trials adopting similar principles to promote the management of retained foreign bodies with fewer complications, and a potential of time and cost-saving.

© 2020 The Author(s). Published by Elsevier Ltd on behalf of British Association of Plastic, Reconstructive and Aesthetic Surgeons.

This is an open access article under the CC BY-NC-ND license (<http://creativecommons.org/licenses/by-nc-nd/4.0/>)

Introduction

Retained Foreign Bod(ies) (FB) following penetrating, lacerating, or crush injury are frequently encountered in the Emergency Department and the Plastic Surgery practice. When FB are suspected, a thorough assessment of the wound is fundamental since they are often overlooked during the initial evaluation.^{1,2} General diagnostic workup for retained FB involves a detailed history and physical examination as well as imaging techniques that are suboptimal and not always successful in identifying all types of FB.^{1,3-7} As a result, delayed presentation, in some cases, can be unavoidable and leads to several complications that warrant removal such as chronic pain, soft tissue infection, delayed wound healing, and abscess formation,⁸⁻¹⁰ in addition to the late intervention which results in further neurovascular injuries, blood loss and a wider surgical incision with more chances for iatrogenic sequelae.^{11,12}

The optimal therapeutic window for FB removal is the first 24 h post-injury to permit better evaluation of the wound's entry and exist also, to reduce the inflammatory response and scar formation.¹⁰ However, surgical removal in emergency settings is usually challenging and multifactorial. FB may reside deeply in soft tissues with close proximity to vital structures such as nerves and tendons making their extraction technically difficult.^{3,13} On the other hand, the elimination process can be influenced by the surgeon's experience, the appropriateness of the setting, and the FB characteristics like the size, shape, and the materials' type.^{2,14}

Furthermore, the blind surgical exploration for approaching and managing FB is invasive and may expose the patient to additional risks.^{11,12} Thus, research advocated the utility of ultrasound-guided interventions to mitigate the blind surgery-associated complications, yet, none of them has been recognized as "ideal" due to various limitations in terms of availability, accuracy, and reliance on the operators' experience.^{12,13,15-17}

In light of those facts, this study has been conducted to demonstrate a novel vacuum-assisted technique for FB removal which harnesses readily available materials to achieve a noninvasive, real-time FB extraction at the point of care, hence, fewer complications, with a potential of time and cost-saving.

Methods

Patients' recruitment

This was a single-centre study conducted over 18 months. All patients who visited the Plastic Surgery Department of the hospital were considered for this study. By using a nonprobability convenience sampling process, 20 patients have participated in this study. Any patient with suspected FB met the inclusion criteria. Patients were excluded from the study only if the written consent to participate in this trial could not be obtained.

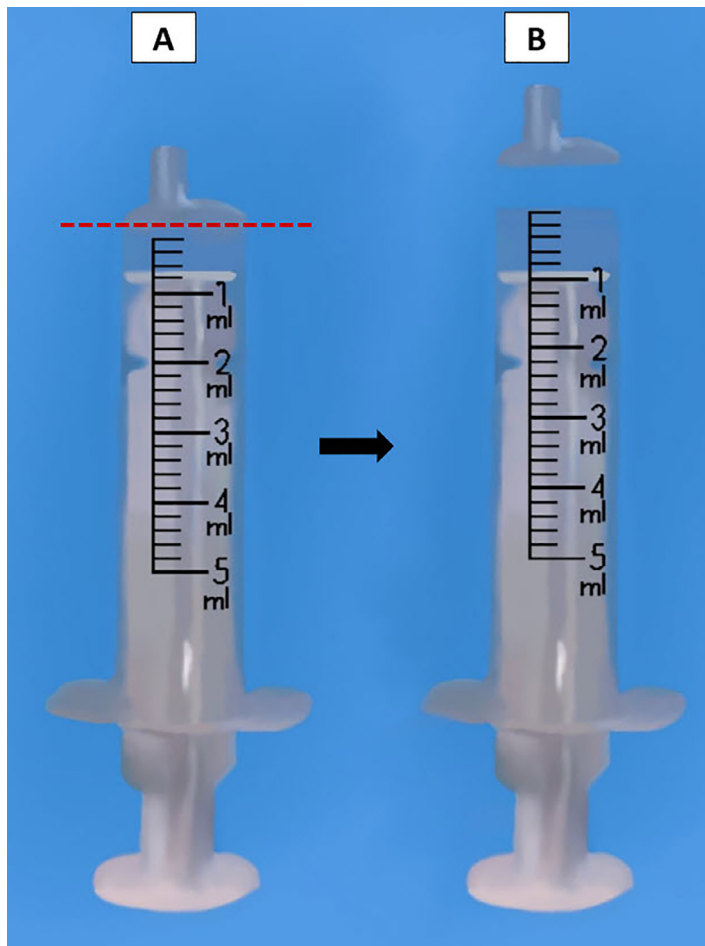


Figure 1. The modified Syringe. A. The conventional five ml syringe. B. The modified syringe after cutting the distal part. --- The place of cutting.

Study materials

A conventional needle-free five ml syringe manufactured by BD (Becton–Dickinson, Franklin Lakes, NJ, USA) has been used. It is a disposable syringe with a Luer-Slip tip type. Under a sterile condition, the distal part of the syringe's barrel, and the syringe's tip were removed with the aid of a scalpel blade No. 24 and a circle cut with even margins was attained, [Figure 1](#).

Patients' assessment and procedure

The recruited patients underwent a thorough assessment as per the hospital guidelines by two plastic surgery consultants, with two separate sessions to mitigate the inter-observer influence. The process included attaining a full history regarding the date, duration, and the mechanism of injury along with a general physical examination and a local wound examination of clinical signs that herald FB retention like pain, swelling, erythema, mass on palpation, abnormal sensation and neurovascular deficits.^{2,10,18} When the two plastic surgery consultants agreed on the presence of the FB, an X-ray

Table 1
Summary of study results.

Case No.	Age/Gender	(No.) / Type of the FB	Site of the FB	Length*	Width of the FB in mm	Time from the onset to presentation
1	23y F	(1) wood	Hand	10×3		5 d
2	52y F	(1) wood	Hand	16×2		25 d
3	33y M	(3) metallic	Trunk (2) Thigh (3)	5×5		10 d
4	14y M	(1) wood	Foot	11×2		30 d
5	42y F	(1) wood	Hand	7 × 3		3 d
6	28y M	(1) metallic	Hand	5 × 3		14 y
7	55y M	(1) wood	Hand	13×2		7 d
8	19y F	(1) wood	Foot	14×3		28 d
9	26y M	(1) glass	Face	7 × 4		5 d
10	34y M	(1) glass	Face	5 × 2		8 d
11	22y F	(1) wood	Hand	10×3		12 d
12	30y F	(1) wood	Foot	15×3		11 d
13	41y M	(1) metallic	Arm	5 × 5		50 d
14	20y F	(1) wood	Hand	5 × 2		7 d
15	41y M	(2) glass	Face	4 × 2		11 d
16	62y M	(1) wood	Hand	11×2		25 d
17	19y M	(1) glass	Foot	4 × 2		30 d
18	72y M	(1) wood	Foot	12×2		38 d
19	46y F	(1) wood	Hand	8 × 2		12 d
20	23y M	(1) wood	Hand	9 × 2		6 d

F, female; FB, Foreign Body; M, male; d, days; y, years.

image and/or an Ultra-Sound (US) visualization have been done to the wound, to support the clinical evidence of the FB presence and also, to help in the pre-intervention of the FB localization.

After determining the FB site, either by the imaging modalities (X-ray or US) or by the clinical signs (i.e. the area of maximum tenderness or fluctuation), a small skin incision was created via a surgical blade no.15 under a local anesthetic condition. The length of the incision varied according to the shape and the size of FB. However, it should be equal to the shortest dimension (the width) of the FB to allow a passive delivery of the FB with the least possible tissue damage.

Then, the modified syringe, [Figure 1](#), was perpendicularly applied to the site of incision and the syringe plunger was pulled gradually to its end. This method creates a negative pressure environment which was sufficient to pull the FB, and after three to five trials the FB was successfully evacuated. The method is illustrated further in the accompanying [Video](#).

Following the removal of the FB, the wound was thoroughly irrigated, and dressings were applied as per the hospital practice with no need for suturing as the incisions were small in all the cases.

Results

A total of 23 retained FB in twenty patients have been subjected to the mentioned technique. In all cases, the presence of the FB was suggested clinically with a100% agreement between the two observers (i.e. the plastic surgery consultants both agreed on the presence of the FB based on their clinical assessment). Furthermore, the FB existence was confirmed by the imaging techniques in all patients. The duration between the date of injury and the date of the retained FB presentation varied from a few days to many years with a median of 11.5 days. Eleven of the 23 FB were located in the upper extremities, while other patients had the retained FB in their lower extremities (six of the 23 FB), the face (four of 23 FB), and the trunk (two of the 23 FB). As per the imaging findings, 17 out of the 23 FB were superficially located relative to the FB inlet whilst others were deeply settled within the soft tissues. Additionally, the dimensions' mean of the visualized FB was (three×eight) mm (measured by the imaging techniques). The majority of the FB isolated were organic (wood). However, other FB materials like glass pieces, needles, and shells were also evacuated. In this study, we were able to extract all the FB visualized by the imaging techniques except for one case. [Table 1](#) summarizes the study results.

Case reports

A record of two patients recruited in this study shows the ability of the modified syringe to extract the retained soft tissue FB and the effect of the delayed intervention on the utility of this method as a result of fibrosis.

Patient 2

A 52-year-old female presented with pain and tenderness over the proximal phalanx of the right index finger. She gave a history of pricking the mentioned site before 25 days when she was working in the garden. On examination, there was a mild swelling, redness, tenderness and a palpable mass (FB) felt by the bimanual palpation. The US showed the presence of a FB measuring 16 mm × 2 mm and appeared to be a piece of wood. The patient was admitted to the Operation Room (OR) for the FB extraction under local anesthesia (lidocaine 1%) using the mentioned technique. After retrieving the FB, the wound was irrigated with Normal Saline and the patient was kept on monitoring for three hours. The patient was assessed during the subsequent follow-up visits, three visits with two-week intervals and no complications were witnessed. The accompanying **Video** illustrates the extraction method of the FB from the patient's 2 right index finger using the modified syringe.

Patient 6

A 28-year-old health care worker in the Radiology Department, attended the Plastic Surgery outpatient clinic when he felt a sudden onset of pain and abnormal sensation in his left thumb after being appointed to work in the MRI unit for the first time. He denied any history of trauma or injury in recent years; with no abnormal findings on the clinical examination. However, his X-ray imaging showed a metallic FB in the proximal phalanx of his left thumb. The patient was admitted to the OR and a small incision was done over the dorsal aspect of the designated site. Five trials of retrieving the FB were attempted using the modified syringe, but no benefit was yielded. A decision of switching to the classical open surgery method was made and the FB was founded to be deeply sited within the soft tissues and surrounded by fibrosis. The wound was irrigated and dressed according to the hospital's routine practice and the patient was discharged. On the follow-up visits, the patient remembered that he was a victim of a blast injury 14 years ago and he had sustained a small wound in his left thumb at that time.

Discussion

Wounds with retained FB are a common presentation in the Emergency and Plastic surgery Departments which could be passed unnoticed during the initial assessment.¹⁹ Inevitable complications, as a result, are usually seen making the early detection and removal of FB of critical importance.^{8,10,11,13} The identification and retrieval process of the retained FB in the acute care settings is not always straightforward²⁰ and can be affected by the FB nature, the injury mechanism, and human-related factors.^{2,3,13,14,21}

The utilization of the negative pressure principle in wounds' management has a deep-rooted history²² until nowadays, it has been proving its ability to promote wound healing, enhance the neovascularization process, and granulation tissue formation.²²⁻²⁴ Although the role of the negative pressure application has been reported in the literature for removing debris and dead tissues from various injuries,^{25,26} the utility of this approach in managing the retained soft tissue FB *per se* is not well-established, in addition to a variety of technical limitations, and the relatively high cost of sophisticated systems.²⁷⁻²⁹

In this trial, we tried to explore the feasibility of applying the negative pressure concept for the retained FB removal through harnessing readily available, non-invasive, and easy to use materials. We used the previously explained modified syringe to evacuate various kinds, sizes, and shapes of FB, and the procedure was successful in all cases except in "patient 6" where the presence of the fibrosis interfered with a passive FB extraction.

The negative pressure generated by a five ml conventional syringe was measured by a previous study and found to be approximately 334 mmHg of a maximum vacuum.³⁰ However, according to

Haseler et al.³⁰ who examined 20 operators, they found that the maximum vacuum could be achieved by 13 operators only. Also, in our application, the syringe was not tightly sealed to the wound, thus the exact pressure generated within the soft tissues cannot be determined. Studies show that the application of 125 mmHg negative pressure to the wound surface activates biological pathways and increases the blood flow rate.^{23,31,32} However, for the purpose of the FB removal, higher pressure amounts should be applied.³³ There is a controversy on the safe pressure threshold that should be employed on the soft tissues. The negative pressure of 400 mmHg or greater on tight seal applications has shown a decline in the blood flow resulting in ischemia that is manifested as pain and discomfort by patients,^{31,34} yet, no one of our patients experienced such symptoms.

While performing the procedure, the modified syringe was also able to drain the collected pus and debris associated with the FB which can enhance the wound healing process.³⁵ This technique can be carried out easily with no notable adverse effects, besides the other advantages of avoiding the possible iatrogenic injuries to the vital structures associated with the conventional methods as well as the anesthesia risks and the post-surgery scar formation. On the other hand, this study can pave the way for similar approaches in the future, but with some more modifications with regards to the amount of the applied vacuum or the shape of the syringe which could refine the general concept of this method. Moreover, the described technique can be used for other kinds of FB like injectable silicon, for instance.

Study limitation

One of the variables that should be considered is the mass of the FB and its relation to the amount of negative pressure applied. In this study, the mass of the evacuated FB was not measured. The number of suction trials and its relation to the location and the depth of the FB within the soft tissue should be determined as well. In addition to the need for a method to standardize the used negative pressure. The main objective of this study is to spot the lights on the utility of negative pressure in managing retained soft tissue FB with the aid of a simple and non-invasive technique. A larger-scale study with a better standardization should be attempted to affirm the feasibility of utilizing this concept. Despite its easiness and availability, the explained approach may fail to extract the deeply sited FB. Furthermore, the period between the injury and the presentation plays a critical role in determining the effectiveness of this maneuver. As the results show, the longer the period the more the chance of developing fibrosis and this will tether the FB and hinder their extraction. However, this study can open up an avenue for future endeavours of utilizing the vacuum-assisted retained FB removal.

Prior presentations

None.

Funding

None

Conflicts of Interest

None declared

Ethical approval

Not required.

Supplementary materials

Video legend

Illustration of the Foreign Body extraction technique from the patient's 2 right index finger

Supplementary material associated with this article can be found, in the online version, at doi: [10.1016/j.jpra.2020.10.008](https://doi.org/10.1016/j.jpra.2020.10.008).

References

- DeBoard RH, Rondeau DF, Kang CS, Sabbaj A, McManus JG. Principles of basic wound evaluation and management in the emergency department. *Emerg Med Clin North Am.* 2007;25(1):23–39.
- Anderson MA, Newmeyer 3rd WL, Kilgore Jr ES. Diagnosis and treatment of retained foreign bodies in the hand. *Am J Surg.* 1982;144(1):63–67.
- Bradley M. Image-guided soft-tissue foreign body extraction - success and pitfalls. *Clin Radiol.* 2012;67(6):531–534.
- Banerjee B, Das RK. Sonographic detection of foreign bodies of the extremities. *Br J Radiol.* 1991;64(758):107–112.
- Ginsburg MJ, Ellis GL, Flom LL. Detection of soft-tissue foreign bodies by plain radiography, xerography, computed tomography, and ultrasonography. *Ann Emerg Med.* 1990;19(6):701–703.
- Steele MT, Tran LV, Watson WA, Muellemann RL. Retained glass foreign bodies in wounds: predictive value of wound characteristics, patient perception, and wound exploration. *Am J Emerg Med.* 1998;16(7):627–630.
- Davis J, Czerniski B, Au A, Adhikari S, Farrell I, Fields JM. Diagnostic accuracy of ultrasonography in retained soft tissue foreign bodies: a systematic review and meta-analysis. *Acad Emerg Med.* 2015;22(7):777–787.
- Levine MR, Gorman SM, Young CF, Courtney DM. Clinical characteristics and management of wound foreign bodies in the ED. *Am J Emerg Med.* 2008;26(8):918–922.
- Ozsarac M, Demircan A, Sener S. Glass foreign body in soft tissue: possibility of high morbidity due to delayed migration. *J Emerg Med.* 2011;41(6):e125–e128.
- Halaas GW. Management of foreign bodies in the skin. *Am Fam Phys.* 2007;76(5):683–688.
- Polat B, Atici Y, Gürpınar T, et al.. *Acta Ortop Bras.* 2018;26(3):198–200.
- Kurtulmus T, Saglam N, Saka G, Imam M, Akpinar F. Tips and tricks in the diagnostic workup and the removal of foreign bodies in extremities. *Acta Orthop Traumatol Turc.* 2013;47(6):387–392.
- Fu Y, Cui LG, Romagnoli C, Li ZQ, Lei YT. Ultrasound-guided removal of retained soft tissue foreign body with late presentation. *Chin Med J (Engl).* 2017;130(14):1753–1754.
- Kiely J. The use of ultrasound guidance for foreign body removal. *J Plastic, Reconstruct Aesth Surg.* 2019;72(5):848–862.
- Blankstein A, Cohen I, Heiman Z. Ultrasonography as a diagnostic modality and therapeutic adjuvant in the management of soft tissue foreign bodies in the lower extremities. *Isr Med Assoc J.* 2001;3(6):411–413.
- Coombs CJ, Mutimer KL, Slattery PG, Wise AG. Hide and seek: pre-operative ultrasonic localization of non radio-opaque foreign bodies. *Aust N Z J Surg.* 1990;60(12):989–991.
- Callegari L, Leonardi A, Bini A, et al. Ultrasound-guided removal of foreign bodies: personal experience. *Eur Radiol.* 2009;19(5):1273–1279.
- Lammers RL. Soft tissue foreign bodies. *Ann Emerg Med.* 1988;17(12):1336–1347.
- Ebrahimi A, Radmanesh M, Rabiei S, Kavoussi H. Surgical removal of neglected soft tissue foreign bodies by needle-guided technique. *Iran J Otorhinolaryngol.* 2013;25(70):29–36.
- Lulla A, Whitman T, Amii R, Chiem AT. Role of ultrasound in the identification of longitudinal axis in soft-tissue foreign body extraction. *West J Emerg Med.* 2016;17(6):819–821.
- Rooks VJ, Shiels 3rd WE, Murakami JW. Soft tissue foreign bodies: a training manual for sonographic diagnosis and guided removal. *J Clin Ultrasound.* 2020.
- Miller C. The history of negative pressure wound therapy (NPWT): from "Lip Service" to the modern vacuum system. *J Am Coll Clin Wound Spec.* 2013;4(3):61–62.
- Huang C, Leavitt T, Bayer LR, Orgill DP. Effect of negative pressure wound therapy on wound healing. *Curr Probl Surg.* 2014;51(7):301–331.
- Seo SG, Yeo JH, Kim JH, Kim J-B, Cho T-J, Lee DY. Negative-pressure wound therapy induces endothelial progenitor cell mobilization in diabetic patients with foot infection or skin defects. *Exp. Mol. Med.* 2013;45(11):e62–e62.
- Maurya S, Bhandari PS. Negative pressure wound therapy in the management of combat wounds: a critical review. *Adv Wound Care (New Rochelle).* 2016;5(9):379–389.
- Temiz G, Sirinoglu H, Guvercin E, et al. A useful option to obtain maximal foreign body removal and better prognosis in high pressure injection injuries: negative pressure wound therapy with instillation. *J Plast Reconstr Aesthet Surg.* 2016;69(4):570–572.
- Kim JJ, Franczyk M, Gottlieb LJ, Song DH. Cost-effective alternative for negative-pressure wound therapy. *Plast Reconstr Surg Glob Open.* 2017;5(2):e1211.
- EWMA EWMA *Ewma Document: Negative Pressure Wound Therapy Overview.* 26. Challenges And Perspectives Ma Healthcare Ltd; 2017.
- Kumar P. Exploiting potency of negative pressure in wound dressing using limited access dressing and suction-assisted dressing. *Indian J Plast Surg: Off Public Assoc Plastic Surg India.* 2012;45(2):302–315.
- Haseler LJ, Sibbitt RR, Sibbitt Jr WL, Michael AA, Gasparovic CM, Bankhurst AD. Syringe and needle size, syringe type, vacuum generation, and needle control in aspiration procedures. *Cardiovasc Intervent Radiol.* 2011;34(3):590–600.
- Morykwas MJ, Argenta LC, Shelton-Brown EI, McGuirt W. Vacuum-assisted closure: a new method for wound control and treatment: animal studies and basic foundation. *Ann Plast Surg.* 1997;38(6).
- Lambert KV, Hayes P, McCarthy M. Vacuum assisted closure: a review of development and current applications. *Eur J Vasc Endovasc Surg.* 2005;29(3):219–226.
- Fodor PB, Cimino WV, Watson JP, Tahernia A. Suction-assisted lipoplasty: physics, optimization, and clinical verification. *Aesth Surg J.* 2005;25(3):234–246.
- Dockery GL, Crawford ME. *Lower Extremity Soft Tissue and Cutaneous Plastic Surgery.* Saunders; 2006.
- Fay MF. Drainage systems. Their role in wound healing. *Aorn J.* 1987;46(3):442–455.