

## CASE REPORT

# Oxcarbazepine-induced Stevens–Johnson syndrome: a pediatric case report

Burçin Beken<sup>1,\*</sup>, Ceren Can<sup>1</sup>, Aysegül Örencik<sup>2</sup>, Nuray Can<sup>3</sup>  
and Mehtap Yazıcıoğlu<sup>1</sup>

<sup>1</sup>Department of Pediatric Allergy and Immunology, Trakya University Medical School, Edirne, Turkey,

<sup>2</sup>Department of Pediatrics, Trakya University Medical School, Edirne, Turkey, and <sup>3</sup>Department of Pathology, Trakya University Medical School, Edirne, Turkey

\*Correspondence address. Department of Pediatric Allergy and Immunology, Trakya University Medical School, Edirne, Turkey.  
Tel: +90 (284) 235 76 41 (4900); Fax: +90 (284) 235 23 38; E-mail: burcinbeken@gmail.com

## Abstract

Stevens–Johnson syndrome (SJS) and toxic epidermal necrolysis are two rare but life-threatening diseases characterized by detachment of epidermis, bullous skin lesions and mucous membrane erosions. Anti-epileptic drugs are highly suspected to be the causative agents. Although carbamazepine (CBZ) is the most associated anti-epileptic drug, oxcarbazepine (OXC), which is a monohydrated derivative of CBZ, is proposed to be safer because of the different metabolism of the two drugs. Herein, we report a case of SJS induced by oxcarbazepine. A 6-year-old boy with benign rolandic epilepsy, admitted to our hospital with generalized maculopapular rash after starting oxcarbazepine. The diagnosis of SJS was made with cytotoxic skin lesions and mucous membrane involvement. After discontinuing of the drug and topical corticosteroid initiation, the lesions were improved. We report this case to attract attention to the serious side effect of this anti-epileptic drug.

## INTRODUCTION

Stevens–Johnson syndrome (SJS) and toxic epidermal necrolysis (TEN) are bullous mucocutaneous reactions characterized by extensive necrosis and detachment of epidermis. These two conditions are accepted as two variants of the same disease. SJS is the less severe form with detachment <10% of body surface area and mucosal involvement of at least two sites (ocular, oral or genital) [1].

Medications are the major trigger of SJS/TEN and the risk is limited to the first 8 weeks of the treatment [2]. In children, the medications often associated with SJS/TEN are sulfonamide antimicrobials, phenobarbital, carbamazepine (CBZ) and lamotrigine. According to the literature, it appears that a newer anti-epileptic drug, oxcarbazepine (OXC), which is structurally

related to CBZ, has rarely been reported as a trigger of SJS [3]. Here, we report a rare pediatric case of OXC-induced SJS.

## CASE REPORT

A 6-year-old boy, with the diagnosis of benign rolandic epilepsy was admitted to our hospital because of uncontrolled seizures. OXC was started by the pediatric neurology department with the starting dose of 12 mg/kg/day for the first 5 days. The dose was increased to 18 mg/kg/day and after using this dose of drug for 5 days our patient had rashes around the mouth and on the lips. The rashes had spread toward his face, body, arms and legs within a few days. He admitted to our hospital 5 days after the rash had started.

Received: November 14, 2016. Revised: February 12, 2017. Accepted: April 4, 2017.

© The Author 2017. Published by Oxford University Press.

This is an Open Access article distributed under the terms of the Creative Commons Attribution Non-Commercial License (<http://creativecommons.org/licenses/by-nc/4.0/>), which permits non-commercial re-use, distribution, and reproduction in any medium, provided the original work is properly cited. For commercial re-use, please contact [journals.permissions@oup.com](mailto:journals.permissions@oup.com)

On physical examination; he had red maculopapular rashes and flat atypical target lesions mostly on his face and less intensely on his trunk and extremities. There were bullous lesions and hemoragic crusts on his lips (Fig. 1). Photosensitivity and erythema on the preputium penis were observed. He also had malaise, myalgia and pain on swallowing.

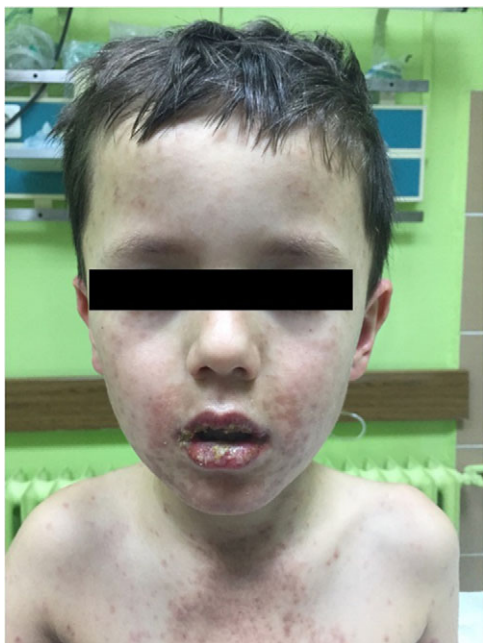On laboratory examination, complete blood count and biochemical markers were within normal limits. The diagnosis of SJS was made with cytotoxic skin lesions involving 10% body surface area and two mucous membranes (oropharynx and penis) and the recent exposure to OXC.

He was hospitalized and OXC treatment was stopped. Topical corticosteroid (methylprednisolone asepton) was applied to the lesions on his mouth and skin. Punch biopsy, taken from the lesions revealed focal full thickness epidermal necrosis, basal vacuolar changes and perivascular lymphocytic infiltrates in the papillary dermis (Fig. 2). Immunohistochemical studies with CD3, CD4, CD8, CD20 and CD56 antibodies revealed the cytotoxic origin of these T cells; extensive positivity with CD3 and CD8 antibodies in contrast with others. There was no immune deposition in direct immunofluorescence studies with C3, IgG, IgM, IgA and fibrinogen antibodies.

On the third day of his hospitalization there became peeling on some lesions of his cheeks and arms. On the seventh day of his hospitalization significant improvement was observed and he was discharged from the hospital. Two months after discharge patch test with both CBZ and OXC was performed and detected negative.

## DISCUSSION

The pathophysiological mechanisms that induce skin damage in SJS/TEN are not fully understood. Drugs can stimulate the immune system by binding to the major histocompatibility complex (MHC) I and the T-cell receptor. This results in the clonal expansion of drug-specific cytotoxic T cells that kill



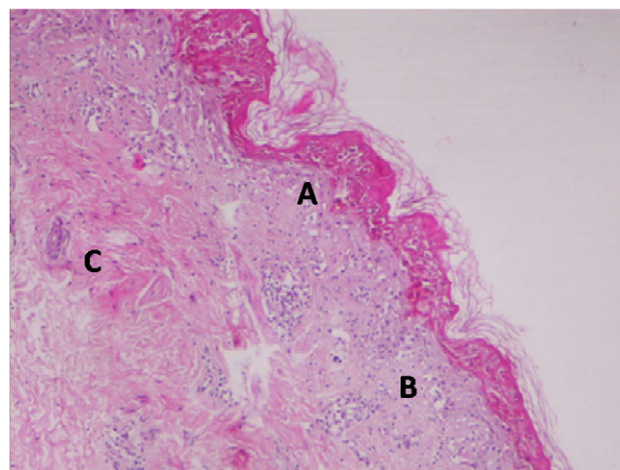
**Figure 1:** Widespread erythematous macules and papules most intensely on the face and trunk. Bullous lesions and hemoragic crusts on the lips

keratinocytes directly by perforin/granzyme pathway or indirectly by inducing cells to release soluble death mediators [4]. The cytotoxic, CD8+ T cells (CTLs) and natural killer cells have been showed to infiltrate the skin lesions and blisters of SJS/TEN patients [5, 6]. In our case, immunohistochemistry revealed that infiltrating lymphocytes in papillary dermis were CTLs. Our data are in agreement with previous reports of the presence of CTLs at the site of skin lesions in patients with SJS [5–7].

OXC is a 10-keto analog of CBZ, however, there is significant differences between the two drugs. OXC is almost completely metabolized to its keto form to yield the active monohydroxy derivative (MHD) which is the major pharmacologically active component. MHD undergoes glucuronidation at the hydroxyl group through uridine 5'-diphospho-glucuronosyltransferase and none of the enzymatic pathways of the OXC metabolism is affected by cytochrome P-450 system. OXC and its metabolites are almost completely excreted in the urine. The 10,11-epoxide derivatives of CBZ oxidation are known to be responsible for most of the side effects of CBZ. Because of this difference of the metabolism of OXC from CBZ, OXC has been proposed to be safer and well tolerated than CBZ [8].

Although carbamazepine is the major anti-epileptic drug associated with SJS/TEN; OXC-induced SJS/TEN is extremely rare with the incidence of 0.5–6/1.000.000 in 1 year in normal population according to the FDA. There are only a few case presentations of OXC-induced SJS in the literature [3, 9]. To the best of our knowledge, our patient is the youngest of all among the cases reported so far in the literature.

OXC is different from CBZ with a ketone in place of the carbon–carbon double bond on the dibenzazepine ring at the 10th position (10-keto). Because of the difference on the metabolism of the two drugs, there is no need of dose adjustments of OXC in hepatic diseases. There are also fewer adverse reactions with OXC. Rashes occur in 3% of patients taking OXC and 7% of patients taking CBZ. Cross-reactions between the two drugs were also reported and the risk of having a hypersensitivity reaction with OXC is 25–30% in patients who have previously experienced a hypersensitivity reaction to CBZ [8]. Recent studies demonstrated that CTLs are drug-specific and directed against the native form of the drug rather than against a reactive metabolite [10]. Both drugs share the same molecular



**Figure 2:** Full thickness epidermal necrosis (A), basal vacuolar changes (B) and perivascular lymphocytic infiltrates in the papillary dermis (C) (H&E ×200)

structure of dibenzazepine ring, so we speculate that this might explain why OXC can induce SJS as CBZ.

In conclusion, we present a rare case of OXC-induced SJS. OXC can also be a trigger of SJS. Because of the high mortality and morbidity rates of SJS, the clinicians must be aware of this serious side effect. Before starting an anti-epileptic drug, including the newer ones, patients should be informed in detail and encourage to contact with physicians urgently in case of any adverse cutaneous drug reaction.

## ACKNOWLEDGEMENTS

None.

## CONFLICT OF INTEREST STATEMENT

None declared.

## FUNDING

None.

## ETHICAL APPROVAL

There is no need for ethical approval for a case report according to the local ethical guidelines.

## CONSENT

A written informed consent was taken from the patient's parents.

## GUARANTOR

None.

## REFERENCES

1. Bastuji-Garin S, Rzany B, Stern RS, Shear NH, Naldi L, Roujeau JC. Clinical classification of cases of toxic epidermal necrolysis, Stevens–Johnson syndrome, and erythema multiforme. *Arch Dermatol* 1993;129:92–6.
2. Sassolas B, Haddad C, Mockenhaupt M, Dunandt A, Liss Y, Bork K, et al. ALDEN, an algorithm for assessment of drug causality in Stevens–Johnson Syndrome and toxic epidermal necrolysis: comparison with case-control analysis. *Clin Pharmacol Ther* 2010;88:60.
3. Guleria VS, Sharda C, Rana T, Sood AK. Oxcarbazepine induced toxic epidermal necrolysis—a rare case report. *Indian J Pharmacol* 2015;47:459–61.
4. Harr T, French LE. Stevens–Johnson syndrome and toxic epidermal necrolysis. In: Harr T, French LE, eds. *Adverse Cutaneous Drug Eruptions*, Vol. 97. Basel: Karger, 2012,149–61.
5. Nassif A, Bensussan A, Boumsell L, Deniaud A, Moslehi H, Wolkenstein P, et al. Toxic epidermal necrolysis: effector cells are drug specific cytotoxic T cells. *J Allergy Clin Immunol* 2004;114:1209–15.
6. Chung WH, Hung SI, Yang JY, Su SC, Huang SP, Wei CY, et al. Granulysin is a key mediator for disseminated keratinocyte death in Stevens–Johnson syndrome and toxic epidermal necrolysis. *Nat Med* 2008;14:1343–50.
7. Yazicioglu M, Iscan B, Turgut B, Yalcin O. Stevens–Johnson syndrome: a case report. *Allergol Immunopathol*. 2009;37:219–21.
8. Schmidt D, Elger CE. What is the evidence that oxcarbazepine and carbamazepine are distinctly different antiepileptic drugs? *Epilepsy Behav* 2004;5:627–35.
9. Trivedi BS, Darji NH, Malhotra SD, Patel PR. Antiepileptic drugs-induced Stevens–Johnson syndrome: A case Series. *J Basic Clin Pharm* 2016;8:42–4.
10. Wei CY, Chung WH, Huang HW, Chen YT, Hung SI. Direct interaction between HLA-B and carbamazepine activates T cells in patients with Stevens–Johnson syndrome. *J Allergy Clin Immunol* 2012;129:1562–9.