

# Intra operative indocyanine green video-angiography in cerebrovascular surgery: An overview with review of literature

S. Balamurugan, Abhishek Agrawal, Yoko Kato, Hirotooshi Sano

Department of Neurosurgery, Fujita Health University Hospital, Toyoake, Japan

## ABSTRACT

Microscope integrated Near infra red Indocyanine green video angiography (NIR ICG VA) has been frequently used in cerebrovascular surgery. It is believed to be a simple and reliable method with acquisition of real time high spatial resolution images. The aim of this review article was to evaluate the efficacy of intra operative Indocyanine green video angiography (ICG VA) in Aneurysm, brain arteriovenous malformations (AVM) and extracranial-intracranial (EC-IC) bypass surgeries and also to analyze its limitations. Intra operative imaging is a very useful tool in guiding surgery; thus, avoiding surgical morbidity. Now-a-days, many cerebrovascular units are using ICG VA rather than Doppler and intra operative DSA in most of their aneurysm surgeries, and surgeons are incorporating this technique for AVM and in EC-IC bypass surgeries too. This article is an overview of the beneficial effects of ICG VA in cerebrovascular surgery and will also point out its limitations in various circumstances. Intra operative ICG VA gives high resolution, real time images of arterial, capillary, and venous flow of cerebral vasculature. Although it gives adequate information about the clipped neck, parent/branching artery and perforator involvement, it has some limitations like viewing the neck residuals located behind the aneurysm, thick walled atherosclerotic vessels, and thrombosed aneurysms. In AVM surgery, it is useful in detecting the residual nidus in diffuse type AVM, but cannot be relied in deep seated AVMs and it gives exact information about the anastomosis site in EC-IC bypass, thus, avoiding early bypass graft failure. NIR ICG VA is a simple, reliable, and quick method to pick up subtle findings in cerebrovascular procedures. But in selected cases of aneurysms, endoscopy and intra operative Digital subtraction angiography (DSA) may be helpful, whereas in deep seated AVMs, navigation may be required as an adjunct to confirm intra operative findings.

**Key words:** Aneurysms, arteriovenous malformations, cerebral revascularization, extracranial-intracranial bypass, indocyanine green, video angiography

## Introduction

The success of aneurysm surgery lies on complete clipping of aneurysmal neck and preservation of main/branching and perforating arteries. The goal of brain arteriovenous malformations (AVM) surgery is total excision of the nidus without any residue. The aim in extracranial-intracranial (EC-IC) bypass surgery is avoiding occlusion at the anastomotic site,

thereby avoiding early bypass graft failure. Microvascular Doppler, Intra operative Digital subtraction angiography (DSA), and Neuronavigation are used for the abovementioned purpose, but they are not without limitations. Microscope integrated near infrared indocyanine green video-angiography (ICG VA) has recently been applied to cerebrovascular surgery. After the introduction of intra operative ICG VA, the literature is surged with articles mentioning that the surgical morbidity is greatly reduced, mainly in EC-IC bypass and the usage of other intra operative imaging modalities have been grossly reduced in many centers for most of the aneurysm and AVM surgeries. But ICG VA has also its own limitations in giant and complex intracranial aneurysms and in deep seated large AVMs. This article is an overview of the role of ICG VA intra operatively and find out its limitations in special circumstances. The results of ICG VA were compared with intra/post-operative angiography and were analyzed in detail.

Access this article online	
Quick Response Code:	Website: www.asianjns.org
	DOI: 10.4103/1793-5482.92168

### Address for correspondence:

Dr. Yoko Kato, 1-98 Dengakugakubo Kutsukake-cho, Toyoake-shi, Aichi Pref, Japan. E-mail: kyoko@fujita-hu.ac.jp

## Indocyanine Green Video Angiography – Principles and Technique

Fluorescence angiography was first used by ophthalmologists

to measure the retinal blood flow by using the fluorescent dye, fluorescein. Feindel *et al.*,<sup>[1]</sup> were the first to apply the fluorescence angiography for intra operative visualization of cerebral micro circulation. With the use of indocyanine green (ICG) and its integration into a compact system with modern video technology, fluorescence angiography has recently re-emerged. Raabe *et al.*,<sup>[2,3]</sup> were the first to demonstrate that ICG-VA is suitable for the intra operative assessment of cerebral vascular flow.

The advantage of ICG over fluorescein is that the light emission is more intense and easier to detect, and the adverse reactions are also very low. ICG was approved by US Food and Drug Administration in 1956 and 1975 for cardio circulatory measurements, liver function tests, and ophthalmic angiography.<sup>[2]</sup> ICG-VA is integrated with a surgical microscope made by Carl Zeiss Ltd, Germany. Microscope integrated ICG-VA technology focuses on obtaining high resolution and high contrast near-infrared (NIR) images after intravenous injection of ICG dye so that the blood flow in the cerebral vasculature can be assessed.

ICG dye is a NIR fluorescent dye that was originally used for ophthalmic angiography. It is given by intravenous (iv) route with a recommended dose of 0.2-0.5 mg/kg with a maximum daily dose of 5 mg/kg.<sup>[2,3]</sup> After iv injection, it is immediately bound by globulins and remains intravascular until its excretion by the liver. ICG is not reabsorbed into the intestine and it will not enter the hepatic circulation also.

The surgical field is illuminated by a light source (NIR-light) with a wavelength covering the ICG absorption band. After iv injection of the dye, its fluorescence is induced and recorded by a non-intensified video camera. An optical filter blocks both ambient and excitation light so that only ICG-induced fluorescence is collected. So arterial, capillary, and venous angiographic images can be observed on the video screen in real time.

## Literature Review

The most important basic principle of neurovascular surgery is maintaining the integrity of tissue perfusion. Disruption of vascular supply may occur during various cerebrovascular procedures, especially in intracranial aneurysm clipping, and results in postoperative neurological deficits and adverse outcomes.<sup>[2]</sup> The main goals of intracranial aneurysm surgery is to occlude the aneurysm completely from the brain circulation without any residual neck and maintain the normal blood flow in parent, branching, and perforating vessels.<sup>[4,5]</sup> The majority of intracranial aneurysms can be treated by microsurgical clipping; among them, some may require vascular reconstruction.<sup>[4-8]</sup> The neurosurgeon may be unable to confirm the surgical results with visual microscopic inspection only.

Postoperative angiograms can be used to ensure the surgical results, but if the residual aneurysm or stenotic artery exists, the patient may require repeat surgery.<sup>[9-14]</sup> In postoperative angiographic studies, the incidence of residual filling of aneurysm has ranged from 2-8% and the parent or branching artery occlusion was 4-12%.<sup>[2,15-17]</sup> The patients with unsuspected vessel occlusion will have significant morbidity for which a second procedure brings no relief. Moreover, postoperative neck residuals carry risk of regrowth and rupture of the aneurysm.<sup>[18-20]</sup> So people have recommended Intra operative angiography as a useful tool and have reported that it had a significant impact on the surgical procedure in 7-34% of cases.<sup>[15,16,21-25]</sup>

In many neurosurgical centers, micro vascular Doppler sonography is widely used in aneurysm surgery and it exhibits good correlation with postoperative angiography also. Although it is noninvasive, with low cost and less time consuming method, people have experienced mixed results when using it for evaluation of clip induced stenosis. The interpretation of Doppler signals is subjective and insonation of small perforating vessels may be difficult and unreliable.<sup>[2]</sup>

Even though studies have already shown that the Intra operative DSA would improve the result of aneurysm clipping, it is unlikely to become the standard of care in many centers. It is time consuming, expensive, and requires additional experienced people and it has a complication rate of 0.4-2.6%.<sup>[2,9,10,14,22-24]</sup>

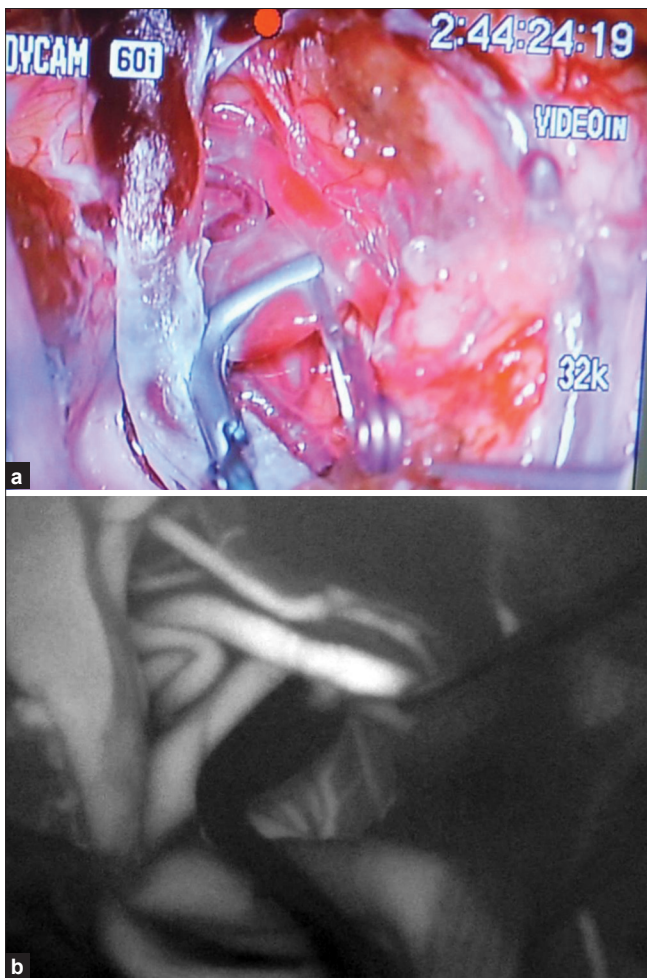
The application of Intra operative ICG VA for the assessment of cerebral vascular flow was first described by Raabe *et al.*<sup>[2]</sup> In this study, Intra operative ICG VA was performed in 12 aneurysm cases and no side effects were observed by them. They divided the time course of ICG angiography into arterial, capillary, and venous phases comparable to that of DSA. The integration of ICG VA with surgical microscope was also successfully reported by the same group.<sup>[26]</sup> In the later study also, there were no side effects reported and they did the clip correction within two minutes after ICG VA.

In another publication by the same group,<sup>[3]</sup> the findings of ICG VA were compared with intra/postoperative DSA.

Many authors have reported the useful findings of Intra operative ICG VA and its significant role in the course of surgery.<sup>[26-30]</sup> They have confirmed the findings of ICG VA with intra/postoperative DSA.<sup>[2,3,31]</sup> More than 90% of findings of ICG VA were well correlated with intra/post operative DSA findings. Integration of the ICG VA into the surgical microscope considerably improved the simplicity and speed with which the procedure can be accomplished. To perform Intra operative DSA, an experienced team is usually needed and it will take minimum 20 minutes to perform the procedure. This time limit may exceed the ischemic tolerance

of brain tissue in critical cases. Clip readjustment for the occluded vessels after seeing the Intra operative DSA was still associated with a 33% rate of stroke.<sup>[32]</sup> But for using ICG VA, there is no need to move the microscope from the surgical field or to interrupt the operation. The surgeon can get the results within two minutes of injecting the ICG dye and can alter the clip position within another two minutes before the critical cerebral ischemia occurs [Figure 1]. This obviously reduces the surgical morbidity. ICG VA is a simple and quick method, and the image quality and spatial resolution are excellent when compared to other methods. The technique of ICG VA allowed blood flow to be assessed in smaller vessels even less than one millimeter in diameter.<sup>[2,3]</sup> So the patency of perforating arteries can be well assessed with the operating microscope.

Studies have shown that the complications of ICG VA were less when compared to other invasive procedures, 0.05-0.2%.<sup>[33,34]</sup> They are hypotension, tachycardia, nausea, pruritus, syncope, and skin eruptions. But most of the studies reported no adverse effects due to this ICG VA technique.<sup>[2,3,26,27,30,35]</sup>



**Figure 1:** Intra operative image showing a clipped aneurysm (a). Corresponding post-clipping ICG angiography of the aneurysm demonstrating no residual neck along with preservation of the perforators (b)

## Limitations

Neck residuals located behind the aneurysm still cannot be detected by ICG VA.<sup>[36]</sup> In a study,<sup>[37]</sup> after clipping the aneurysm, the ICG VA showed absence of residual filling, but after incising the aneurysm dome, slow dye extravasation was found. The reasons were incomplete clipping of wide aneurysm neck and atheroma at the aneurysm neck, not allowing complete closure of the clip blades. Some advised long term follow-up of angiographic evaluation for those patients in which certainty of complete exclusion was not assured by opening the dome of the aneurysm.<sup>[37]</sup> Kurana *et al.*,<sup>[29]</sup> also reported a study in which they were misled by the findings of ICG VA.

Anatomy outside the microscope's viewing area was not visualized during this procedure and blood in the operative field with arachnoid scarring added to the misinterpretation of the results. Vessels covered by aneurysm or brain tissue cannot be observed using this technique.<sup>[2,3,38]</sup> ICG VA may be affected by calcifications and thick walled atherosclerotic vessels or by partially or completely thrombosed aneurysms.<sup>[3,26]</sup> The area of observation for contrast flow is much smaller during ICG VA than during DSA.

In the ICG VA, only the first part of the distal branching vessel is available for observation, whereas during DSA, the distal flow can be compared between different branches remote from the site of clipping.<sup>[3]</sup> Additionally, deep seated aneurysms have been difficult to assess as they have been reported to be associated with neck residuals more often than surface aneurysms.

Repeated injections of ICG within short intervals may cause false positive findings.<sup>[36]</sup> Filling of arteries from proximal to distal should be undertaken carefully to avoid misdiagnosing the retrograde filling of the branches distal to the aneurysm. In cases of deep seated, giant, thick walled and complex aneurysms, there may be a need for verification of the results by intra operative DSA.<sup>[36]</sup>

Even with intra operative DSA, 50% of cases require at least two different angiographic views to find out the neck remnants covered by the clip or branching artery.<sup>[25]</sup> Payner *et al.*,<sup>[13]</sup> reported a 7.9% residual aneurysms and a 4.8% rate of distal arterial branch occlusion visible on post operative DSA, but not during intra operative DSA. So ICG VA can be used as a primary intra operative imaging modality in regular aneurysm surgeries, since it is a simple, reliable, quick, and safe method. In selected, complicated giant aneurysms and aneurysms in deeper locations, we may need Doppler, intra operative DSA, and endoscopy to confirm the findings of ICG VA.

## ICG VA in AVM Surgery

Even with the availability of preoperative embolization, stereotactic guidance, electrophysiological monitoring,

intra operative angiography, and image guided techniques, microsurgical excision of AVMs in eloquent areas is still a challenge for neurosurgeons.<sup>[39,40]</sup> Although advances in interventional neuro-radiology and stereotactic radiosurgery offer alternatives to microsurgery, complete micro surgical resection is the only treatment option that immediately eliminates the risk of hemorrhage from the AVM.<sup>[39,41]</sup>

Identification of AVM nidus and complete excision are the main goals in AVM surgery. According to the literature, residual nidus of AVMs had high chances of re-rupture.<sup>[42]</sup> Neuronavigation is a novel technology used for identification of AVM, but it cannot assess the flow of AVM.<sup>[43,44]</sup> The role of intra operative DSA in AVM surgery is well established,<sup>[21,45,46]</sup> but at the same time, it increases the operating time, expense, and potentially operative morbidity. The information of intra operative DSA is not integrated into the operative view and therefore must be interpreted. ICG VA addresses many of these limitations.<sup>[35]</sup>

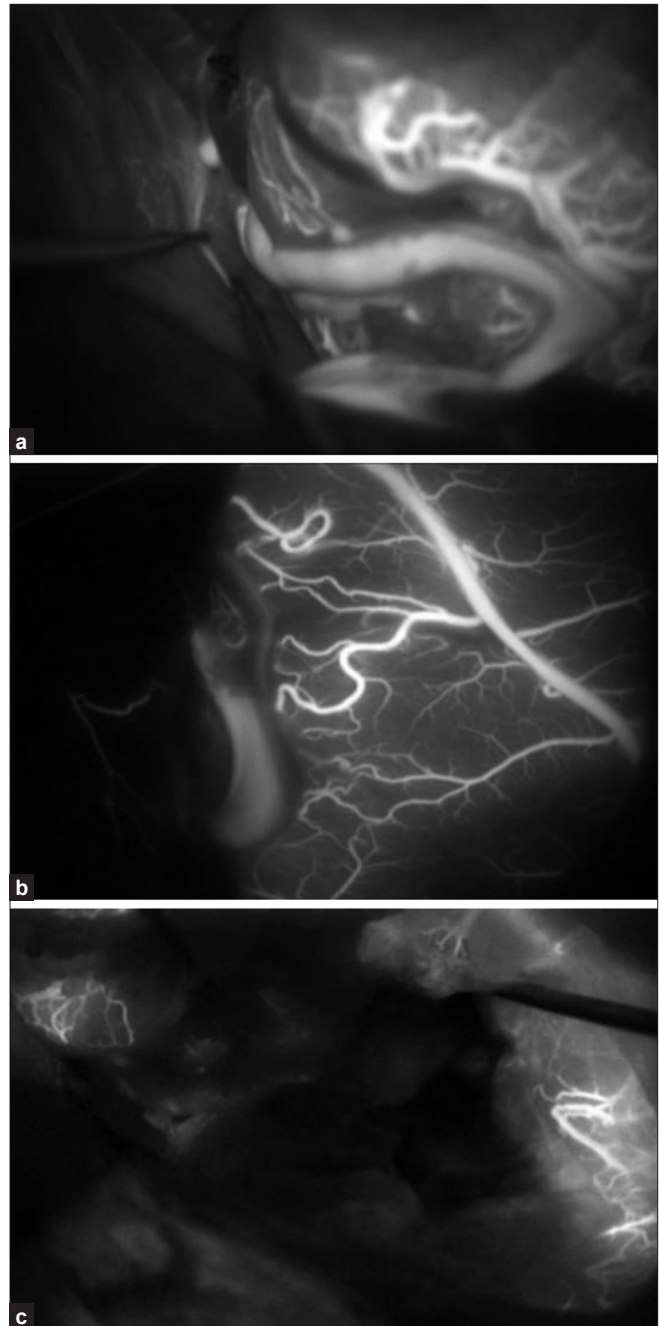
ICG VA is ideal for early identification of AVM arteries and veins; thus, helps the surgeon to make and modify the operative strategy for AVM excision [Figure 2]. The timing of fluorescence can distinguish vessels in both physiological and pathological states. Arterialized veins emit fluorescence in the late arterial phase.<sup>[35]</sup> Effectiveness of ICG VA for the detection of residual nidus in children has already been reported.<sup>[43,47]</sup> Especially in children, chances of occlusion of femoral artery is more with intra operative DSA, and ICG VA will be more useful in these cases.

It has been reported<sup>[47]</sup> that in diffuse type of AVMs, ICG VA was more helpful to find out the residual nidus. At the same time, ICG VA was not very useful in deep seated AVMs since these lesions must be approached through a long and narrow corridor and also when the vessels were covered by the blood clots and brain tissue.<sup>[35,43]</sup> Thick walled atherosclerotic vessels also altered the results of ICG VA. In the above situations, intra operative DSA remains the gold standard intra operative imaging tool. ICG VA can be a helpful adjunct to DSA in the surgery of deep seated AVMs.

### ICG VA in Extracranial - intracranial Bypass

Cerebral revascularization is an important element in the surgical treatment of complex intracranial aneurysms.<sup>[6-8,12]</sup> It has a major role in moyo moyo disease and, now-a-days, its usage is increasing in cerebral ischemia also. One of the current critical issues in successful EC-IC bypass surgery is the intra operative assessment of graft patency<sup>[7,8,12,48]</sup> [Figure 3].

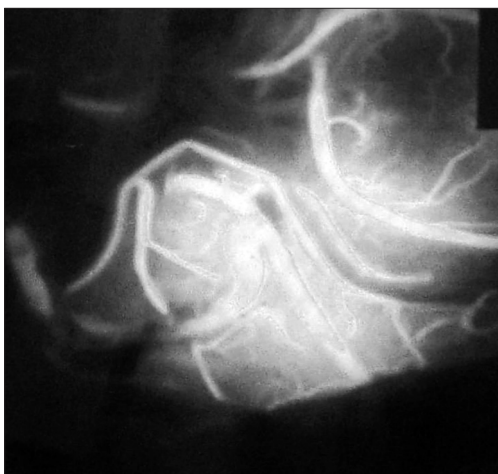
The main obstacle of the EC-IC bypass surgery is early bypass graft occlusion and concomitant bypass failure.<sup>[49,50]</sup> Unrecognized early bypass graft occlusion will lead to cerebral ischemia, which is responsible for morbidity associated with EC-IC bypass surgery.<sup>[49,50]</sup> So it is ideal to assess the bypass graft function intra operatively to avoid complications.



**Figure 2:** Intra operative ICG angiography demonstrating a feeding artery (a) and a draining vein (b) in an AVM. Post-operative image (c) of AVM showing complete removal of nidus

Direct intra operative inspection may fail to predict EC-IC bypass patency reliably; thus, the post operative bypass patency rate is reported to be only between 90-96%.<sup>[48-50]</sup> Ultrasonography and thermal artery imaging have been previously used, but these techniques are limited with respect to image quality and spatial resolution.<sup>[48]</sup>

Although intra operative DSA is the gold standard<sup>[51]</sup> technique for the evaluation of graft patency, it has its own limitations like invasiveness, high cost, and the necessity to use ionizing radiation in the operating room.



**Figure 3:** Intra operative ICG angiography after superficial temporal artery to middle cerebral artery anastomosis showing a patent bypass

The reliability of ICG VA in detecting stenosis and nonfunctioning bypasses has already been reported.<sup>[31,43,48]</sup> Its usefulness has been proved in high flow bypass also.<sup>[48]</sup> Because of its high image quality and spatial resolution, it will help not only to judge the graft flow but also the anatomical relationships at the anastomotic site. Takagi *et al.*,<sup>[43]</sup> also reported the usefulness of ICG VA in superficial temporal artery to middle cerebral artery bypass. The findings of ICG VA were positively validated during the post operative period by performing DSA or CT angiography.<sup>[31]</sup> The patency rate of EC-IC bypass, which was below 90% previously, has now become 100% with the usage of ICG VA.<sup>[48]</sup>

### Summary and Conclusion

Even though micro vascular Doppler is being used for a long time in cerebrovascular surgery, it has its own limitations. Though Intra operative DSA is the gold standard technique, it needs an additional professional experience and the table position needs to be changed. Moreover, it is time consuming, expensive, and has radiation exposure also in the operating suite. So ICG VA is replacing the above in many neurosurgical centers, because it is a simple, rapid, and reliable method and we can get real time images with good quality and high spatial resolution, and also, it is not an expensive one.

In aneurysm surgery, ICG VA gives adequate information about the clipped neck and parent/branching artery involvement in more than 90% cases. Even the perforators of 0.5 mm diameter can also be picked up well with this technique. But the neck residuals located behind the aneurysm still cannot be detected by ICG VA. ICG fluorescence may also be affected by calcifications, thick walled atherosclerotic vessels, and thrombosed aneurysms. Intra operative digital subtraction angiography still remains the method of choice for the above such cases, and for giant, complex aneurysms and aneurysms in deeper locations.

In AVM surgery, though neuronavigation is useful in identifying the nidus, it cannot assess the flow of AVMs. By using ICG VA, we can identify the blood flow in arterialized veins and also it is useful in identifying the residual nidus, especially in diffuse type AVMs. But in deep seated AVMs, we cannot rely only on this method and we may require intra operative DSA to confirm the findings.

In EC-IC bypass, ICG VA gives exact information about the anastomotic site, so that early bypass graft failure can be avoided.

The reported side effects are very low with this technique when compared to other invasive methods. To avoid false positive findings, repeated injections of ICG within short intervals should not be given.

Even though there are certain limitations, ICG VA is widely being used in many centers, because it is simple, safe and we can get faster results with high resolution real time images. For selected cases of Aneurysm and AVMs, we may require intra operative DSA/endoscope or neuronavigation to confirm the findings of ICG VA.

### References

1. Feindel W, Yamamoto YL, Hodge CP. Intra carotid fluorescein angiography - A new method for examination of epicerebral circulation in man. *Can Med Assoc J* 1967;96:1-7.
2. Raabe A, Beck J, Gerlach R, Zimmermann M, Seifert V. Near infrared Indocyanine green video angiography - A new method for intra operative assessment of vascular flow. *Neurosurgery* 2003;52:132-9.
3. Raabe A, Nakaji P, Beck J, Kim LJ, Hsu FP, Kammerman JD, *et al.* Prospective evaluation of surgical microscope integrated intra operative near infrared Indocyanine green video angiography during aneurysm surgery. *J Neurosurgery* 2005;103:982-9.
4. Park DH, Kang SH, Lee JB, Lim DJ, Kwon TH, Chung YG, *et al.* Angiographic features, Surgical management and outcomes of proximal middle cerebral artery aneurysms. *Clin Neurol Neurosurg* 2008;110:544-51.
5. Sharma BS, Gupta A, Ahmed FU, Suri A, Mehta VS. Surgical management of giant intracranial aneurysms. *Clin Neurol Neurosurg* 2008;110:674-81.
6. Chibbaro S, Tacconi L. EC-IC bypass for the treatment of cavernous sinus aneurysms. *J Clin Neurosci* 2006;13:1001-5.
7. Kai Y, Hamada J, Morioka M, Yano S, Mizuno T, Kuroda J, *et al.* Treatment strategy for giant aneurysms in the cavernous portion of the internal carotid artery. *Surg Neurol* 2007;67:148-55.
8. Qui aones-Hinojosa A, Lawton MT. *In situ* bypass in the management of complex intracranial aneurysms - Technique application in 13 patients. *Neurosurgery* 2005;57:140-5.
9. Alexander TD, Macdonald RL, Weir B, Kowalczyk A. Intraoperative angiography in cerebral aneurysm surgery - A prospective study of 100 craniotomies. *Neurosurgery* 1996;39:10-7.
10. Chiang VL, Gaillond P, Murphy KJ, Rigamonti D, Tamargo RJ. Routine intraoperative angiography during aneurysm surgery. *J Neurosurg* 2002;96:988-92.
11. Derdeyn CP, Moran CJ, Cross DT 3<sup>rd</sup>, Sherburn EW, Dacey RG Jr. Intracranial aneurysm - Anatomic factors that predict the usefulness of intra operative angiography. *Radiology* 1997;205:335-9.
12. Kubo Y, Ogasawara K, Tomitsuka N, Otawara Y, Kakino S, Ogawa A. Revascularisation and parent artery occlusion for giant internal carotid artery aneurysms in the intra cavernous portion using intra operative monitoring of cerebral hemodynamics. *Neurosurgery* 2006;58:43-50.

13. Payner TD, Horner TG, Leipzig TJ, Scott JA, Gilmore RL, Denardo AJ. Role of intra operative angiography in the surgical treatment of cerebral aneurysms. *J Neurosurg* 1998;88:441-8.
14. Tang G, Cawley CM, Dion JE, Barrow DL. Intraoperative angiography during aneurysm surgery - A prospective evaluation of efficacy. *J Neurosurg* 2002;96:993-9.
15. Allcock JM, Drake CG. Postoperative angiography in cases of ruptured intracranial aneurysms. *J Neurosurg* 1963;20:752-9.
16. Macdonald RL, Wallace MC, Kestle JR. Role of angiography following aneurysm surgery. *J Neurosurg* 1993;79:826-32.
17. Thornton J, Bashir Q, Aletich VA, Debrun GM, Ausman JL, Charbel FT. What percentage of surgically clipped intracranial aneurysms have residual nidus? *Neurosurgery* 2000;46:1294-8.
18. David C, Vishteh A, Spetzler R. Late angiographic follow up review of surgically treated aneurysms. *J Neurosurg* 1999;91:396-401.
19. Hernesniemi J, Vaplahti M, Niskanen M, Tapaninaho A, Kari A, Luukkonen M, *et al.* One year outcome in early aneurysm surgery – A 14 years experience. *Acta Neurochir(wien)* 1993;122:1-10.
20. Ohman J, Heiskanen O. Timing of operation for ruptured supratentorial aneurysms – A prospective randomized study. *J Neurosurg* 1989;70:55-60.
21. Barrow DL, Boyer KL, Joseph GJ. Intra operative angiography in the management of neurovascular disorders. *Neurosurgery* 1992;30:153-9.
22. Feuerberg I, Lindquist C, Lindqvist M, Steiner L. Natural history of postoperative aneurysm rests. *J Neurosurg* 1987;66:30-4.
23. Klopfenstein JD, Spetzler RF, Kim LJ, Feiz-Erfan I, Han PP, Zabramski JM, *et al.* Comparison of routine and selective use of intra operative angiography during aneurysm surgery – A prospective assessment. *J Neurosurg* 2004;100:230-5.
24. Martin NA, Benston J, Viuela F, Hieshima G, Reicher M, Black K, *et al.* Intra operative digital subtraction angiography and the surgical treatment of intracranial aneurysms and vascular malformations. *J Neurosurg* 1990;73:526-33.
25. Nanda A, Willis BK, Vannem Reddy PS. Selective intra operative angiography in intracranial aneurysm surgery – Intra operative factors associated with aneurysmal remnants and vessel occlusion. *Surg Neurol* 2002;58:309-15.
26. Raabe A, Beck J, Seifert V. Technique and image quality of intra operative Indocyanine green angiography during aneurysm surgery using surgical microscope integrated near infrared video technology. *Zentralbl Neurochir* 2005;66:1-6.
27. Mohanty A. Near infrared Indocyanine green video angiography in aneurysm surgery. *Neurol India* 2009;57:366-7.
28. Li J, Lan Z, He M, You C. Assessment of microscope integrated Indocyanine green angiography during intracranial aneurysm surgery – A retrospective study of 120 patients. *Neurol India* 2009;57:453-9.
29. Khurana VG, Seow K, Duke D. Intuitiveness, Quality and Utility of intra operative fluoresce video angiography – Australian Neurosurgical experience. *BJNS* 2010;24:163-72.
30. Imizu S, Kato Y, Sangli A, Oguri D, Sano H. Assessment of incomplete clipping of aneurysms intra operatively by a near infrared indocyanine green video angiography integrated microscope. *Minim Invasive Neurosurg* 2008;51:199-203.
31. Ma CY, Shi JX, Wang HD, Hang CH, Cheng HL, Wu W. Intra operative indocyanine green angiography in intracranial aneurysm surgery – Microscopical clipping and revascularization. *Clin Neurol Neurosurg* 2009;110:840-6.
32. Batjer HH, Frankfurt AI, Purdy PD, Smith SS, Samson DS. Use of etomidate, temporary arterial occlusion and intra operative angiography in surgical treatment of large and giant cerebral aneurysms. *J Neurosurg* 1988;68:234-40.
33. Cochran ST, Bomyea K, Sayre JW. Trends in adverse events after intravenous administration of contrast media. *AJM Am J Roentgenol* 2001;176:1385-8.
34. Hope-Ross M, Yannuzzi LA, Gragoudas ES, Guyer DR, Slakter JS, Sorenson JA, *et al.* Adverse reactions due to indocyanine green. *Ophthalmology* 1994;101:529-33.
35. Killory BD, Nakaji P, Gonzales LF, Ponce FA, Wait SD, Spetzler RF. Prospective evaluation of surgical microscope integrated intra operative near infrared Indocyanine green angiography during cerebral AVM surgery. *Neurosurgery* 2009;65:456-62.
36. Dashti R, Hernesniemi J, Niemela M. The role of intra operative Indocyanine green video angiography in cerebrovascular surgery. *Eur Neurol Dis* 2007;2:112.
37. Mery FJ, Amin-Hanjani S, Charbel FT. Is an angiographically obliterated aneurysm always secure? *Neurosurgery* 2008;62:979-82.
38. De Oliveira JG, Beck J, Seifert V, Teixeira MJ, Raabe A. Assessment of flow in perforating arteries during intracranial aneurysm surgery using intra operative Near infrared Indocyanine green video angiography. *Neurosurgery* 2007;61(suppl. 3):63-72.
39. Sisti MB, Kader A, Stein BM. Microsurgery for 67 intracranial AVMs less than 3 cm in diameter. *J Neurosurg* 1990;79:653-60.
40. Spetzler RF, Martin NA, Carter LP, Flom RA, Raudzens PA, Wilkinson E. Surgical management of large arterio venous malformations by staged embolization and operative excision. *J Neurosurg* 1987;67:17-28.
41. Pikes HJ, Beach ML, Harbaugh RE. Microsurgical treatment of AVM - Analysis and comparison with stereotactic radiosurgery. *J Neurosurg* 1998;88:641-6.
42. Hoh BL, Carter BS, Ogilvy CS. Incidence of residual intracranial AVMs after surgical resection and efficacy of immediate surgical re-exploration. *Acta Neurochir (Wien)* 2003;146:1-7.
43. Takagi Y, Samamura K, Hashimoto N. Intra operative Near-infrared Indocyanine green video angiography performed with surgical microscope – Applications in Cerebrovascular surgery. *Eur Neurol Rev* 2008;3:66-8.
44. Mathiesen T, Peredo I, Edner G, Kihlström L, Svensson M, Ulfarsson E, *et al.* Neuronavigation for AVM surgery by intra operative three dimensional ultrasound angiography. *Neurosurgery* 2007;60(suppl. 2):345-50.
45. Anegawa S, Hayashi T, Torigoe R, Harada K, Kihara S. Intra operative angiography in the resection of arterio venous malformations. *J Neurosurg* 1994;80:73-8.
46. Munshi I, MacDonald RL, Weir BK. Intra operative angiography of brain AVM. *Neurosurgery* 1999;45:491-9.
47. Takagi Y, Kikuta KI, Nozaki K. Detection of a residual nidus by surgical microscope integrated intra operative Near infrared Indocyanine green video angiography in a child with a cerebral AVM – Case report. *J Neurosurg Pediatr* 2007;107:416-8.
48. Woitzik J, Horn P, Vajkoczy P, Schmiedek P. Intra operative control of extracranial-intracranial bypass surgery patency by near infrared Indocyanine green video angiography. *J Neurosurg* 2005;102:692-8.
49. Mandelovitsch A, Taussky P, Rem JA, Gratzl O. Clinical outcome of standard extracranial – intracranial bypass surgeries in patients with symptomatic atherosclerotic occlusion of internal carotid artery. *Acta Neurochir (Wien)* 2004;146:95-101.
50. Schmiedek P, Piepgras A, Leinsinger G, Kirsch CM, Einhüpl K. Improvement of cerebrovascular reserve capacity by EC-IC bypass surgery in patients with internal carotid artery occlusion and hemodynamic cerebral ischemia. *J Neurosurg* 1994;81:236-44.
51. Yanaka K, Fujita K, Noguchi S, Matsumaru Y, Asakawa H, Anno I, *et al.* Intra operative angiographic assessment of graft patency during extracranial – intracranial bypass surgery. *Neurol Med Chir (Tokyo)* 2003;43:509-13.

**How to cite this article:** Balamurugan S, Agrawal A, Kato Y, Sano H. Intra operative indocyanine green video-angiography in cerebrovascular surgery: An overview with review of literature. *Asian J Neurosurg* 2011;6:88-93.

**Source of Support:** Nil, **Conflict of Interest:** None declared.