

CASE REPORT

Noninvasive ventilation via bilevel positive airway pressure improved sleep in a child with congenital central hypoventilation syndrome: A case report

Liqiang Yang | Shuyao Qiu | Jianwen Zhong | Dabo Liu 

Shenzhen Hospital, Southern Medical University, Shenzhen, China

Correspondence

Dabo Liu, Shenzhen Hospital, Southern Medical University, Shenzhen 518101, Guangdong, China.

Email: gzdaboliu@126.com**Abstract**

We report the polysomnography findings of a 2-year-old girl who was previously diagnosed with CCHS and treated with bilevel positive airway pressure (BiPAP) and O₂ supplementation for a year. The girl had convulsions 2 times in the last 10 days. After we replaced her nasal cannula with a nasal mask and adjusted the parameters of the BiPAP, her sleep and ventilation were improved. The polysomnographies measured under spontaneous breathing without oxygen supplementation showed that her sleep structure, heart rate, and oxygen saturation during sleep were improved 1 month and 1 year after effective BiPAP treatment.

KEYWORDS

CCHS, polysomnography, sleep structure, ventilatory support

1 | INTRODUCTION

Congenital central hypoventilation syndrome (CCHS) is a rare condition with an incidence rate of 1/148000~1/200,000 live births.¹ It is characterized by the lack of adequate autonomic control of breathing. CCHS causes alveolar hypoventilation and reduced or absent ventilatory responses to hypercapnia and hypoxia, mainly during sleep. Most infants with CCHS have worse ventilation. Therefore, it is necessary to start the ventilatory support as early as possible and maintain it lifelong for patients with CCHS.

It is well known that ventilation of the children with CCHS can be successfully managed by noninvasive ventilation.² However, it is not clear how the characteristic of sleep changes under spontaneous breathing after the treatment of noninvasive ventilation. That can be helpful to know the changing regularity of disease and adjust the

parameters of ventilator. This paper introduces a child with CCHS whose sleep was improved significantly by using effective bilevel positive airway pressure (BiPAP).

2 | CASE PRESENTATION

A two-year-old girl presented to our hospital because she had 2 convulsions in the last 10 days. She was previously diagnosed with CCHS with genetic testing showing a variant in exon 3 of Phox2b (genotype 20/25). She had been treated with BiPAP (PHILIPS BiPAP AVAPS 30) and oxygen inhalation (FiO₂: 30%) via a nasal oxygen cannula for a year before presenting to our hospital. Results of examinations during sleep on BiPAP without oxygen inhalation were as follows: saturation of oxygen (SpO₂): 80%; heart rate (HR):110 beats per min (bpm); and transcutaneous partial pressure of carbon dioxide (T_{cp}CO₂): 88 mmHg.

This is an open access article under the terms of the [Creative Commons Attribution-NonCommercial-NoDerivs](https://creativecommons.org/licenses/by-nc-nd/4.0/) License, which permits use and distribution in any medium, provided the original work is properly cited, the use is non-commercial and no modifications or adaptations are made.

© 2022 The Authors. *Clinical Case Reports* published by John Wiley & Sons Ltd.

The BiPAP was set at S/T mode (Spontaneous Time) as follows: inspiratory positive airway pressure (IPAP):16 cmH₂O; expiratory positive airway pressure (EPAP): 4 cmH₂O; backup respiratory rate: 25 breaths/min; and inspiratory time: 0.8 s. The brain nuclear magnetic resonance showed no obvious abnormality. After the patient was admitted, we found her nasal oxygen cannula caused massive air leakage around the nasal area. We replaced her nasal oxygen cannula with a nasal mask. The parameters of ventilator were reset as follows: IPAP: 12 cmH₂O; EPAP: 5 cmH₂O, backup respiratory rate: 20 breaths/ min; and inspiratory time: 1.1 s. Respiratory variables during sleep were improved significantly after 1 month of treatment. During the treatment of BiPAP without oxygen inhalation, SpO₂ was above 95%, the average HR was 70–80 bpm, and TcpCO₂ was less than 50 mmHg. During the 1-year follow-up, there were no convulsions observed. We monitored the patient's oxygen saturation remotely and instructed the parent to adjust the BiPAP according to the oxygen saturation. All her neurocognitive evaluations showed normal results.

Figure 1 shows the polysomnographies during sleep under spontaneous breathing (with no oxygen inhalation) at admission (baseline), and 1 month and 1 year after the BiPAP treatment. As shown in Table 1, the percentage of rapid eye movement (REM) was 3.5% at the baseline; it was increased at 1 month (19.8%) and 1 year (12.5%) after the treatment. The baseline percentage of stage N3 was 96.5%; it was decreased to 53.8% and 28.8% at 1 month and 1 year, respectively. There was no stage N1 or stage N2 at

the baseline. The percentage of stage N1 was increased at 1 year (2.4%). The stage N2 sleep was increased to 26.3% and 56.3% at 1 month and 1 year, respectively. The baseline average SpO₂ was 85%; it was improved to 91% and 93% at 1 month and 1 year, respectively. The oxygen desaturation index was 30.1 times/h at baseline; it was decreased to 21.1 and 11.3 times/h at 1 month and 1 year, respectively. The microarousals index was increased at 1 month (2.4 times/h) and 1 year (10.5 times/h) compared to the baseline (0.9 times/h).

3 | DISCUSSION

For this patient with CCHS, with effective treatment of BiPAP, the sleep structure, SpO₂, HR, and the ability of arousal were improved significantly under spontaneous breathing (without oxygen inhalation and BiPAP).

For CCHS patients, maintaining successful ventilation is critical for respiratory management. Typically, there are two approaches to establish artificial airway for in patients with CCHS: tracheotomy and noninvasive ventilation. The noninvasive ventilation approaches included pressure-controlled BiPAP and volume-targeted BiPAP, both can adopt S/T mode. The BiPAP with S/T mode has been successfully applied to the children with CCHS when the tracheotomy was declined by their parents. For patients with CCHS, sometimes they are incapable to trigger the ventilator to switch from IPAP to EPAP during sleep due to the dysfunction of respiratory center. When set at the

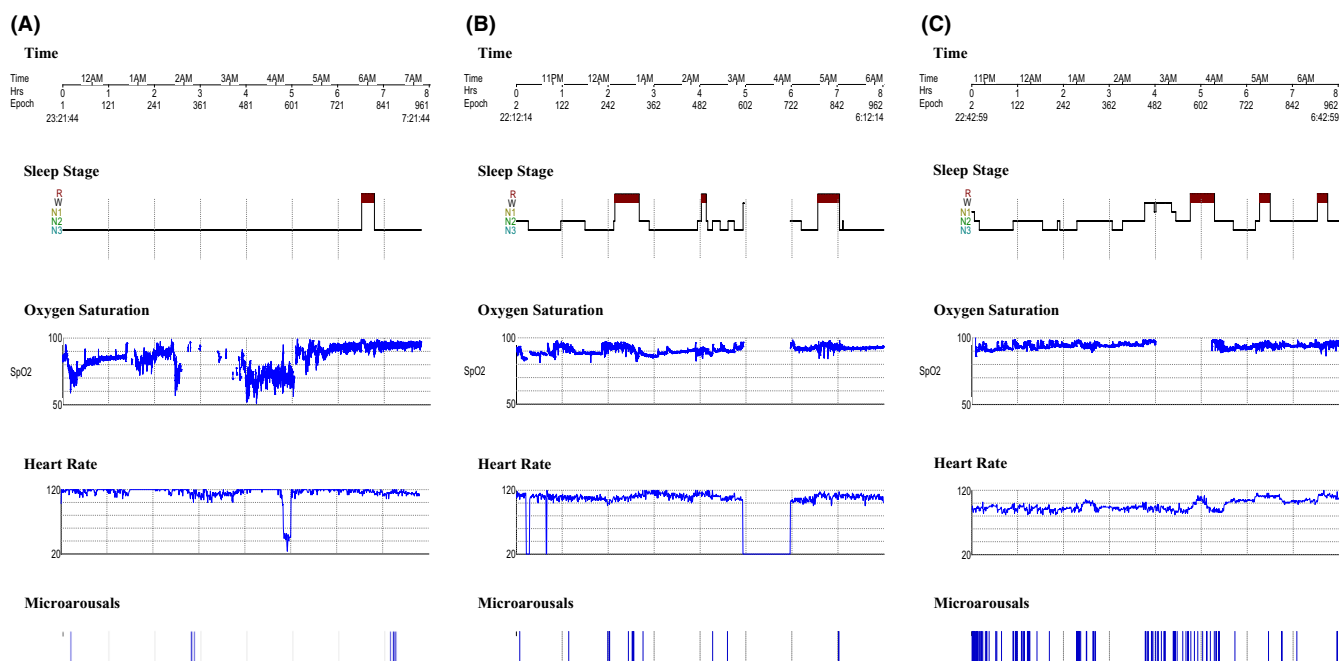


FIGURE 1 Polysomnography at baseline, and 1 month and 1 year after bilevel positive airway pressure (BiPAP) the treatment. (A) Baseline (at admission); (B) 1 month follow-up; and (C) 1-year follow-up

TABLE 1 Physiological variables and sleep parameters at baseline, and 1 month and 1 year after BiPAP treatment

	Baseline	1 month	1 year
Height (cm)	83	84	95
Body weight (kg)	11.5	12.5	14
TRT (min)	468.5	577.5	505.5
TST (min)	468.5	495	472.5
RL (min)	390.5	129	286
Sleep stage			
REM (%)	3.5	19.8	12.5
N1 (%)	0	0	2.4
N2 (%)	0	26.3	56.3
N3 (%)	96.5	53.9	28.8
SpO ₂ during TST			
Average SpO ₂ (%)	85	91	93
Lowest SpO ₂ (%)	51	81	86
ODI (≥3%) (times/h)	30.1	21.1	11.3
Average HR (bpm)	123 (range: 82–151)	115 (range: 81–142)	98 (range: 79–115)
Microarousals (times/h)	0.9	2.4	10.5

Abbreviations: BiPAP, bilevel positive airway pressure; bpm, beats per minute; HR, heart rate; N1, stage 1; N2, stage 2; N3, stage 3; ODI, oxygen desaturation index; REM, Rapid eye movement, stage R; RL, R stage latency sleep, onset to first epoch of Stage REM in min; SpO₂, oxygen saturation; TRT, total recording time; TST, total sleep time.

S/T mode, if spontaneous breathing does not occur within a certain period of time, the BiPAP will provide one mechanically triggered breathing according to the preset IPAP time. Therefore, the BiBAP S/T mode can help the patients with abnormal central ventilation control switch between IPAP and EPAP effectively.

Choosing a proper interface is important for the success of noninvasive ventilation. There are five major interfaces based on the way the pressured air is supplied: oronasal (full-faced) mask, nasal mask, nasal pillow, oral mask, and total face mask. Each interface has its advantages and disadvantages. One of the considerations in choosing a proper interface is to avoid the unintended air leakage. For this case, the BiPAP device did not function effectively because of the massive air leakage caused by the nasal cannula. Therefore, we replaced the nasal cannula with a nasal mask.

Supplemental oxygen is used to enhance oxygen saturation when noninvasive ventilation is not adequate. However, oxygen supplementation alone is insufficient to improve ventilation, since it does not correct the hypoventilation. Thus, oxygen supplementation without correcting hypoventilation may result in chronic hypercapnia, leading to the development of cor pulmonale. Therefore, it is recommended that the pressure of BiPAP should be adjusted first before considering supplementing oxygen. For this child, although normal oxygen saturation could be achieved by oxygen supplementation, excess carbon dioxide could not

be expelled through gas exchange. The sustained carbon dioxide retention might be the reason for repetitive convulsions. Prolonged tachycardia may lead to excessive load on the heart, which may lead to heart failure. After adjustment of parameters of BiPAP and replacement the nasal cannula with a nasal mask, the child did not have any convulsions; her heart rate decreased to the normal range.

Hypoventilation mostly occurs during sleep. It has been shown that patients with CCHS have more severe hypoventilation and central apneas during non-rapid eye movement (NREM) sleep than REM sleep; this may be due to increased excitatory inputs to the respiratory system during REM sleep.³ In addition, it has been shown that the patients with CCHS do not arouse in response to endogenous hypoxemia and hypercapnia if they only depend on their spontaneous breathing during sleep. Once they get well-ventilated during sleep, they will arouse in response to exogenous hypercapnia and hypoxia.^{4,5} Guilleminault et al. reported that the degree of arousal in patients with CCHS was depended on the level of end-tidal PCO₂ and sleep stage,⁶ indicating the ability of arousal in CCHS patients was affected by the efficiency of ventilation. For this case, the patient's arousal ability was increased significantly after effective noninvasive ventilation support.

Sleep stage, especially REM sleep, is closely related to the development of nervous system in children. REM sleep can help facilitate the formation and consolidation of certain types of memory. Under normal development,

REM sleep accounts for up to 55% of the total sleep time in infancy. With the development and maturity of the brain, REM sleep gradually decreases until it reaches the level of adults (20–25%) at the age of 5.⁷ REM sleep can be affected by the abnormal breathing during sleep. We previously reported that the children with decreased REM sleep (REM < 10%) had severer apnea-hypnea index and more obvious behavioral problems.^{8,9} It has been shown that patients with CCHS may suffer from a spectrum of neurocognitive impairment.^{10,11} We found that the percentage of REM sleep was increased after effective BiPAP treatment from 3.5% to 10% or more. The patient had no significant impairment of neurocognition at the follow-up.

4 | CONCLUSIONS

In this patient, with effective treatment of BiPAP using a nasal mask, the spontaneous breathing on sleep, sleep structures, and arousal ability were improved.

AUTHOR CONTRIBUTIONS

DL and LY participated in the design of study and drafting the manuscript. LY, SQ, and JZ conceived of the study and helped to draft manuscript. All authors read and approved the final manuscript.

ACKNOWLEDGMENT

Not applicable.

CONFLICT OF INTEREST

The authors declare that they have no competing interests.

DATA AVAILABILITY STATEMENT

All data generated during this case report are included in this published article.

CONSENT

Written informed consent was obtained from the patient's parents for publication of the case report.

ORCID

Dabo Liu  <https://orcid.org/0000-0003-4468-5374>

REFERENCES

1. Shimokaze T, Sasaki A, Meguro T, et al. Genotype-phenotype relationship in Japanese patients with congenital central hypoventilation syndrome. *J Hum Genet.* 2015;60:473-477.
2. Boit P, Samuels M. Mask ventilation in the early management of congenital central hypoventilation syndrome. *Arch Dis Child Fetal Neonatal ed.* 2008;93:F400-F403.
3. Huang J, Colrain IM, Panitch HB, et al. Effect of sleep stage on breathing in children with central hypoventilation. *J Appl Physiol.* 2008;105:44-53.
4. American Thoracic Society. Clinical policy statement: congenital central hypoventilation syndrome: genetic basis, diagnosis and management. *Am J Respir Crit Care Med.* 2010;181:626-644.
5. Marcus CL, Bautista DB, Amihyia A, Ward SL, Keens TG. Hypercapnic arousal responses in children with congenital central hypoventilation syndrome. *Pediatrics.* 1991;88:993-998.
6. Guilleminault C, McQuitty J, Ariagno RL, Challamel MJ, Korobkin R, McClead RE Jr. Congenital central alveolar hypoventilation syndrome in six infants. *Pediatrics.* 1982;70:684-694.
7. Kahn A, Dan B, Groswasser J, Franco P, Sottiaux M. Normal sleep architecture in infants and children. *J Clin Neurophysiol.* 1996;13:184-197.
8. Yang L, Huang Z, Zhong J, Qiu S, Liu D. The characteristics and clinical significance of REM < 10% in children with sleep-disordered breathing. *Int J Pediatr Otorhinolaryngol.* 2018;110:53-56.
9. Yang L, Zhou Y, Zhong J, et al. Analysis of behavioral problems in children with sleep-disordered breathing and decreased REM sleep. *Int J Pediatr Otorhinolaryngol.* 2021;147:110783.
10. Zelko FA, Nelson MN, Leurgans SE, Berry-Kravis EM, Weese-Mayer DE. Congenital central hypoventilation syndrome: neurocognitive functioning in school age children. *Pediatr Pulmonol.* 2010;45:92-98.
11. Charnay AJ, Antisdell-Lomaglio JE, Zelko FA, et al. Congenital central hypoventilation syndrome: neurocognition already reduced in preschool-aged children. *Chest.* 2016;149:809-815.

How to cite this article: Yang L, Qiu S, Zhong J, Liu D. Noninvasive ventilation via bilevel positive airway pressure improved sleep in a child with congenital central hypoventilation syndrome: A case report. *Clin Case Rep.* 2022;10:e06320. doi: [10.1002/ccr3.6320](https://doi.org/10.1002/ccr3.6320)