



Functional Medicine

von Brunn's Nests and Follicular Cystitis Following Intradetrusor OnabotulinumtoxinA Injections for Overactive Bladder



Silpa Nekkanti^{a,*}, Andrew Doering^a, Debra L. Zynger^b, Andrew F. Hundley^a

^a The Ohio State University Wexner Medical Center, Dept. of Obstetrics and Gynecology, 395 W. 12th Ave., Suite 522, Columbus, OH, 43210, USA

^b The Ohio State University Wexner Medical Center, Dept. of Pathology, 410 W. 10th Ave., E401 Doan Hall, Columbus, OH, 43210, USA

ARTICLE INFO

Article history:

Received 3 May 2017

Received in revised form

8 June 2017

Accepted 14 June 2017

Keywords:

OnabotulinumtoxinA

Botox

Overactive bladder

Von Brunn's Nests

ABSTRACT

A 67-year-old female with refractory OAB was treated with intradetrusor Botox. She subsequently developed multiple papillary bladder lesions with tissue biopsy showing Von Brunn's nests. Von Brunn's nests are benign bladder lesions similar in appearance to a rare urothelial tumor called Nested Variant of Urothelial Carcinoma (NVUC). It is critical that patients with these findings undergo evaluation to rule out the presence of carcinoma. This finding suggests the possibility of a previously unreported adverse reaction in association with intradetrusor Botox.

© 2017 The Authors. Published by Elsevier Inc. This is an open access article under the CC BY-NC-ND license (<http://creativecommons.org/licenses/by-nc-nd/4.0/>).

Introduction

Overactive Bladder (OAB) affects about 10.7% of men and women, with a projected prevalence of 20.1% by 2018.¹ Symptoms consist of urinary urgency, frequency, and nocturia with or without urge incontinence. First and second line interventions include behavioral modification and medication. For patients with refractory symptoms, intradetrusor OnabotulinumtoxinA (Botox) injections is one of three alternative options. Botox has been shown to eliminate urgency urinary incontinence episodes in up to 27% of patients.² Recognized adverse events include injection site pain, urinary tract infections, hematuria, and urinary retention.³ We report a case of an unreported tissue response following Botox injections with the formation of multiple bladder lesions consisting of von Brunn's nests and follicular cystitis (marked lymphocytic inflammation with follicle formation). We find this to be clinically significant given the unusual nature of the findings and the potential morphologic similarity to the nested variant of urothelial carcinoma (NVUC).⁴

Case presentation

A 67-year-old female with an unremarkable medical history was evaluated for refractory OAB. Previous failed treatment included

behavioral modification, Oxybutynin XL, and Mirabegron. Evaluation showed stage II anterior vaginal wall prolapse and increased bladder sensitivity with idiopathic detrusor overactivity on urodynamic testing.

The patient received intradetrusor Botox injections with 100 units per protocol with normal cystoscopy findings. Per protocol, injection sites were identified approximately 1 cm above the level of the trigone and 0.5 ml of reconstituted Botox was injected 2 mm into the detrusor in a 7 × 3 grid, approximately 1 cm apart for a total of 20 injections. The patient reported significant improvement in symptoms with resolution of urinary urge incontinence episodes from a pre-treatment minimum of 4 episodes a day. She had no symptoms of dysuria, hematuria, or urinary tract infections in the six-month interval following treatment. After 7 months, the patient's symptoms returned and she presented for consideration of repeat Botox. Urine dip prior to the procedure showed moderate blood, negative nitrites, and negative leukocyte esterase. Cystoscopy revealed multifocal papillary bladder lesions and the decision was made to abort the procedure (Figs. 1 and 2). Her only risk factor for bladder cancer was a remote smoking history of 1 pack per day for 15 years but had not smoked in approximately 29 years.

She otherwise had a negative history for chemotherapy or radiation exposure and a negative family history of bladder or kidney cancer. She was referred to urology for further evaluation and management and subsequently underwent a transurethral resection of the bladder lesions. Within the lamina propria, pathologic examination demonstrated von Brunn's nests, cystitis cystica,

* Corresponding author.

E-mail address: Silpa.Nekkanti@osumc.edu (S. Nekkanti).

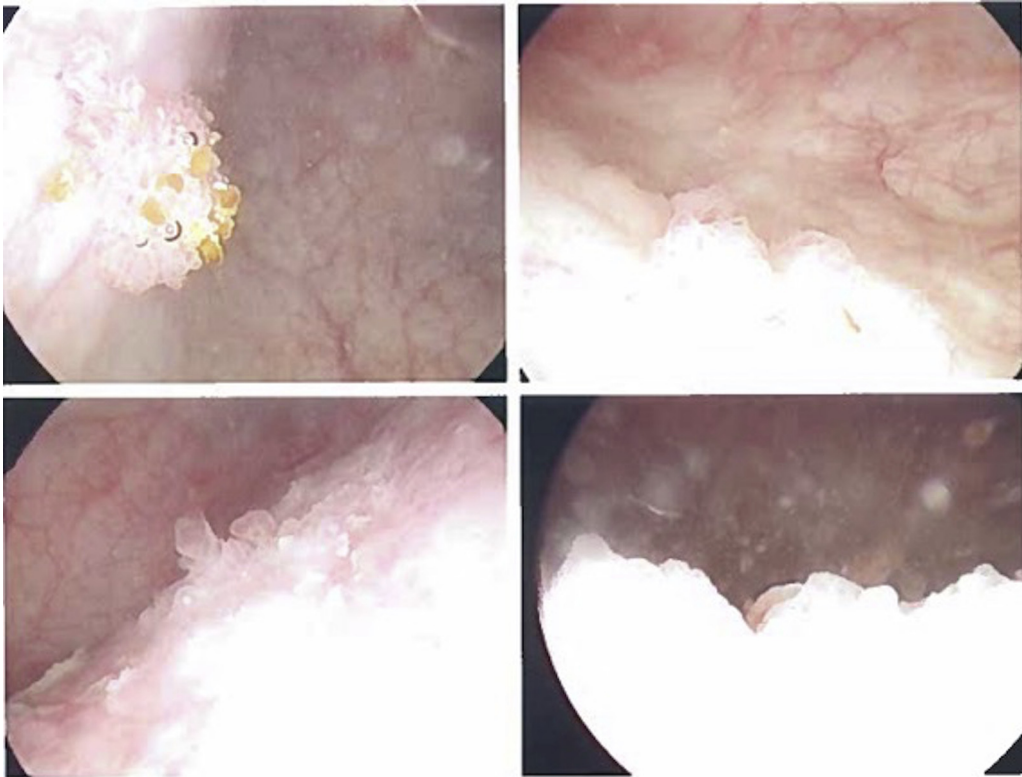


Figure 1. Papillary lesions in lower quadrants on cystoscopy.

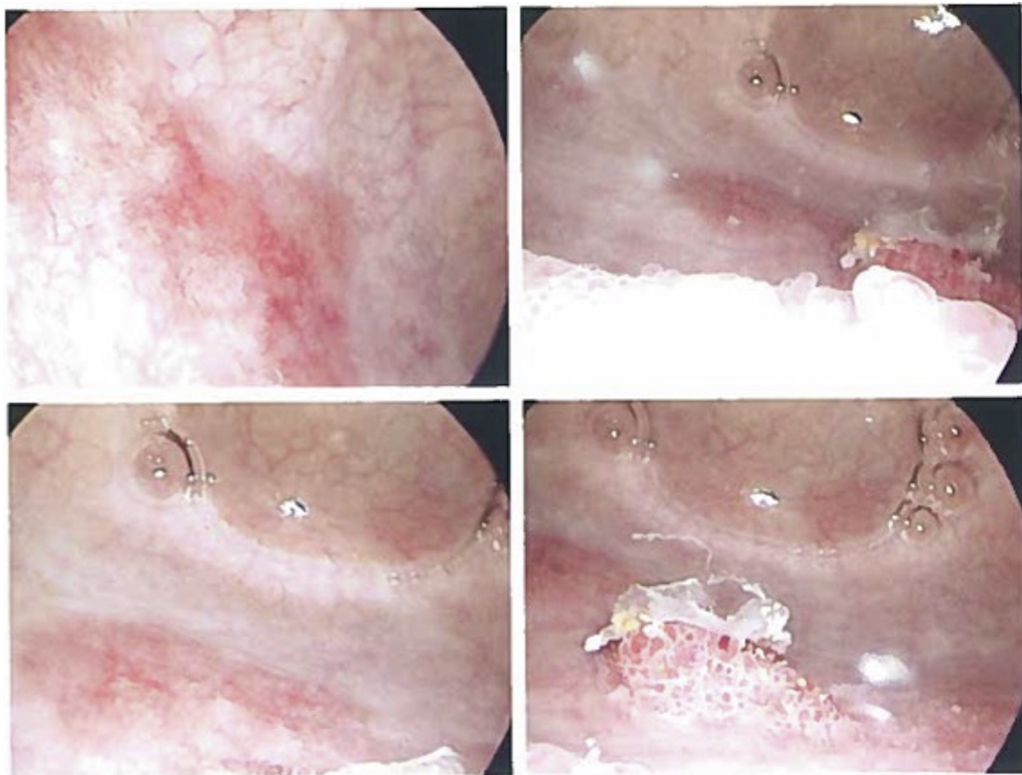


Figure 2. Papillary lesions in upper quadrants on cystoscopy.

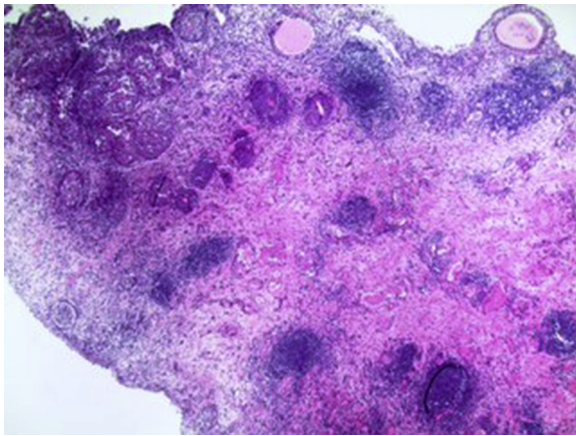


Figure 3. von Brunn's nests, cystitis cystica and marked chronic inflammation 4x.

marked chronic inflammation with follicle formation, and acute inflammation including eosinophils and neutrophils. (Figs. 3 and 4). Muscularis propria was present and had no pathologic change. No papillary lesions were present microscopically. Given this previously unreported reaction to Botox and the unclear significance of these findings, the patient was advised that further Botox injections were not recommended. The patient subsequently elected to pursue percutaneous tibial nerve stimulation and ultimately underwent sacral neuromodulation with >50% improvement in her symptoms.

Discussion

Intradetrusor Botox for OAB is an increasingly common procedure that results in significant clinical improvement with a well-tolerated side effect profile. Visco et al. found that the most

common adverse events were urinary retention, requiring short-term self-catheterization in 5% of participants and increased urinary tract infections in 33% of participants. Serious adverse events were not attributable to the treatment received.³ Other common side effects that have been reported in the literature include injection site pain and hematuria. Botox injections are placed in 0.5 mL aliquots into the detrusor muscle. Other than a slight wheal that may form, there is no distortion to the appearance of the bladder immediately following injections.⁶ To our knowledge there have been no previously reported cases of new-onset tissue pathology or visible development of lesions following Botox injections. von Brunn's nests are non-neoplastic reactive lesions that occur in the bladder. They are groups of urothelial cells that are found in the superficial lamina propria that arise from invagination of the surface urothelium. The cytological appearance of von Brunn's nests is relatively bland with generally smooth and rounded contours of the nest.⁵ However, reactive changes such as nucleomegaly can appear atypical. This can present not only as a diagnostic challenge to the clinician performing cystoscopy but also to the pathologist who must differentiate this non-neoplastic lesion from a potentially more concerning finding. Cystoscopically there was a concern for a potential neoplastic process. Of significant relevance is the similarity of florid proliferations of von Brunn's nests to NVUC. NVUC is a rare tumor with an incidence of only 0.3% of invasive bladder tumors and is characterized by an unusual, bland morphology on microscopy.⁴ Volmar compared the morphologic and immunohistochemical characteristics of florid proliferations of von Brunn's nests to NVUC. Patients with florid proliferations of von Brunn's nests demonstrated larger nests of cells with regular shape and spacing compared to the smaller, irregular nests of NVUC with irregular spacing and infiltrative base. The presence of muscularis propria invasion is a key distinguishing feature. This may not be present in early lesions and the bland cytology of this tumor can prove challenging when only lamina propria invasion is present. Immunohistochemical stains

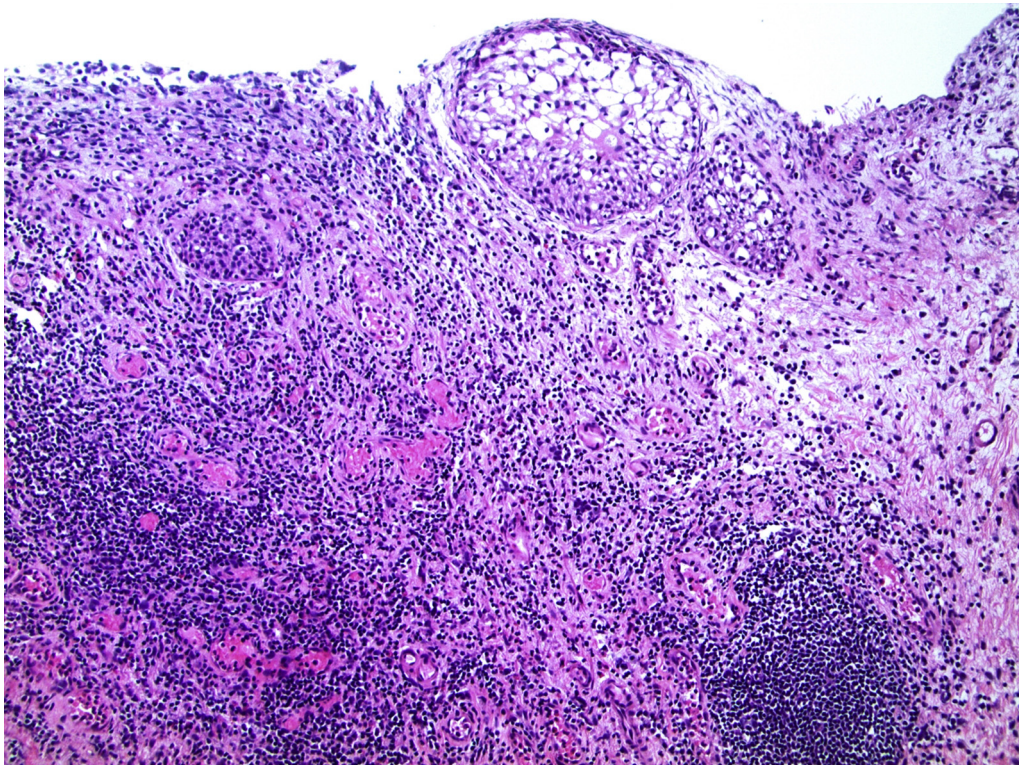


Figure 4. von Brunn's nests with underlying marked chronic inflammation 10x.

for MIB-1, p53, p27, and CK20 have also shown high variability, suggesting that the cystoscopic and microscopic evaluation of these tumors will continue to be of paramount importance. While our case does not illustrate an association of malignancy with Onabotulinum toxin A, it does demonstrate the possibility of an associated inflammatory reaction to the toxin that has not been clearly documented in our literature.

Conclusion

Given that the patient's only known change in her medical history between her two cystoscopic procedures was her intradetrusor Botox injection, this tissue reaction would appear to be secondary to that procedure. Careful tissue inspection and pathologic diagnosis is critical if lesions are found following Botox injections. While we are unaware of other reported cases of abnormal tissue responses to Botox, repeat cystoscopy

following the procedure may be required based on the patient's symptoms.

Conflicts of interest

The authors do not have any conflicts of interest.

References

1. Irwin DE, Kopp ZS, Agatep B, et al. Worldwide prevalence estimates of lower urinary tract symptoms, overactive bladder, urinary incontinence, and bladder outlet obstruction. *BJU Int.* 2011;108(7):1132–1138.
2. Gormley EA, Lightner DJ, Burgio KL, et al. Diagnosis and treatment of overactive bladder (non-neurogenic) in adults: AUA/SUFU guideline. *J Urol.* 2012;188(suppl. 6):2455–2463.
3. Sun Y, Luo D, Tang C, Yang L, Shen H. The safety and efficiency of OnabotulinumtoxinA for the treatment of overactive bladder: a systematic review and meta-analysis. *Int Urol Nephrol.* 2015;47(11), 1779–1778.
4. Volmar KE, Chan TY, De Marzo AM, Epstein JI. Florid von Brunn nests mimicking urothelial carcinoma. *Am J Surg Pathol.* 2003;27(9):1243–1252.
5. Young RH. Tumor-like lesions of the urinary bladder. *Mod Pathol.* 2009;22:S37–S52.