


## CLINICAL ARTICLE

# Comparison of Open Reduction and Internal Fixation with Plate and Titanium Elastic Intramedullary Nail in Treating Pediatric Humeral Fracture

Jin-song Kong, MD<sup>1†</sup>, Yang Huang, MD<sup>1†</sup>, Tao Chen, MD<sup>1</sup>, Qi-hao Weng, MD<sup>2</sup>, Yi-jing Zheng, MD<sup>2</sup>, Yang Yu, MD<sup>2</sup> 

<sup>1</sup>Department of Orthopaedics, Taizhou Municipal Hospital, Taizhou and <sup>2</sup>Department of Orthopaedics, The Second Affiliated Hospital and Yuying Children's Hospital of Wenzhou Medical University, Wenzhou, China

**Objective:** To investigate the therapeutic efficacy of titanium elastic intramedullary nail (TEN) and open reduction and internal fixation with plate (ORIF) in the treatment of humeral fracture in children.

**Methods:** A retrospective study was carried out in a total of 69 patients who were admitted to the hospital from January 2013 to December 2018. These patients, including 41 males and 28 females, were aged from 6 to 12 years old with a median of 8 years. These patients were diagnosed with humeral fracture and underwent the surgery of ORIF ( $n = 22$ ) or TEN ( $n = 47$ ). The intraoperative bleeding, operation time, length of stay (LOS), and fracture healing time were compared between the two groups. The therapeutic effect was assessed by the shoulder range of motion, the elbow range of motion, the UCLA shoulder function score, and the Mayo elbow performance score (MEPS) 6 months after the surgery.

**Results:** The intraoperative bleeding ( $97.20 \pm 27.83$  mL vs  $185.60 \pm 37.50$  mL,  $P < 0.05$ ), the operation time ( $53.70 \pm 11.87$  min vs  $73.50 \pm 13.33$  min,  $P < 0.05$ ), and the fracture healing time ( $9.30 \pm 4.23$  weeks vs  $13.45 \pm 3.67$  weeks,  $P < 0.05$ ) in the TEN group was significantly decreased than those in the ORIF group. There was no significant difference in the LOS between the two groups. The length of follow-up is 3 and 6 months. The shoulder range of motion ( $110.88^\circ \pm 15.82^\circ$  vs  $98.37^\circ \pm 16.22^\circ$  at 3 months and  $162.88^\circ \pm 17.29^\circ$  vs  $117.65^\circ \pm 19.38^\circ$  at 6 months, both  $P < 0.05$ ), the elbow range of motion ( $105.23^\circ \pm 2.81^\circ$  vs  $87.12^\circ \pm 4.73^\circ$  at 3 months and  $137.47^\circ \pm 4.82^\circ$  vs  $109.67^\circ \pm 5.83^\circ$  at 6 months, both  $P < 0.05$ ), and the UCLA shoulder function score ( $28.58 \pm 4.74$  vs  $21.64 \pm 7.23$  at 3 months and  $33.05 \pm 3.27$  vs  $25.78 \pm 3.87$  at 6 months, both  $P < 0.05$ ), and the MEPS ( $80.76 \pm 3.53$  vs  $65.33 \pm 9.43$  at 3 months and  $97.48 \pm 1.23$  vs  $88.22 \pm 3.65$  at 6 months, both  $P < 0.05$ ) in the TEN group were greater than those in the ORIF group. In the TEN group, complications occurred in three of 47 cases (6.38%), including one case (2.13%) of bone nonunion and two cases (4.25%) of irritation response around the nail. In the ORIF group, complications occurred in four of 22 cases (18.18%), including one case (4.55%) of delayed healing, one case (4.55%) of deep infection, and two cases (9.08%) of radial nerve injury. The complication rate was not significantly different between the two groups.

**Conclusion:** TEN can be a good technique for the treatment of humeral fracture in children, with the advantages of less intraoperative bleeding, shorter operative time, quicker healing, and better recovery of shoulder range of motion and elbow range of motion.

**Address for correspondence** Yang Yu, Department of Orthopaedics, The Second Affiliated Hospital and Yuying Children's Hospital of Wenzhou Medical University, 109 Xueyuan West Road, Wenzhou, Zhejiang, China 325000 Tel: 0086-577-88816381; Email: wzyuyang1981@163.com

**Grant Sources:** Medical Health Science and Technology Project of Zhejiang Provincial Health Commission: 2019KY782, Science and Technology Project of Taizhou: 1901ky50.

**Disclosure:** The authors declare that they have no competing interests.

**Ethical approval:** This work was approved by the Ethics Committee of the Second Affiliated Hospital and Yuying Children's Hospital of Wenzhou Medical University.

<sup>†</sup>These two authors contributed equally to this work.

Received 25 May 2020; accepted 19 November 2020

**Key words:** Humeral fracture; Open reduction and internal fixation with plate; Range of motion; Titanium elastic intramedullary nail

## Introduction

Previously, many pediatric injuries did not need surgeries. However, the surgical intervention for certain fractures have been chosen because the selection of the implants is increasing, the outcomes of the surgery are improving, compared with non-surgical treatments. The clinical guidelines for treating pediatric femur fractures and humeral fractures have been developed by the American Academy of Orthopaedic Surgeons (AAOS) to help surgeons select the most appropriate surgical or non-surgical treatment<sup>1</sup>. Although these guidelines are helpful, the high-level evidence is still lacking, and ideal treatments for pediatric fractures are still needed. Meanwhile, the guidelines for other types of pediatric fractures are also lacking. Therefore, studies concerning therapeutic strategies for pediatric fractures are meaningful.

The humeral fracture is one of the most common fractures in children who are younger than 16 years of age. Pediatric humeral fracture is usually caused by a high falling accident or traffic accident<sup>2</sup>. There are many traditional surgical methods for the treatment of humeral fracture in children, such as closed reduction and plaster immobilization, open reduction and internal fixation of Kirschner wire, and open reduction and internal fixation with plate (ORIF)<sup>3-5</sup>. However, these methods have limitations. For example, ORIF can cause the disruption of large soft tissues. It can also cause the damage to patients' natural biology, resulting in the large volume of blood loss and associated neurovascular injuries<sup>6</sup>.

These surgical options for treating pediatric humeral fractures have their advantages and the disadvantages. The location of the pediatric humeral fracture is an important factor for the surgical choice. The posterior or lateral approaches are often used for the mid-shaft to more distal fractures. The proximal one-third to mid-shaft fractures are approached anteriorly and anterolaterally. The possibility for an extensile exposure is an advantage of the anterolateral approach. Compared with other approaches, the anterolateral approach lowers the rates of iatrogenic radial nerve palsy (4%), while the lateral approach has a higher rate of iatrogenic radial nerve palsy (20%), and the posterior approach also has a higher rate of iatrogenic radial nerve palsy (11%)<sup>7</sup>.

Although the treatment choices for pediatric humeral fracture remain controversial, surgical techniques, including titanium elastic intramedullary nail (TEN), ORIF, and external fixation, are widely used due to their therapeutic effects<sup>8</sup>. Diaphyseal humeral fractures in preschool children prefer the conservative treatment, as the healing time is shorter in younger children, and these children may have a capacity for spontaneous correction of the deformity<sup>9</sup>. Older children have the characteristics of obvious fracture displacement,

rotation and angulation instability, and they are more likely to have complications<sup>10</sup>. There is still no consensus regarding the age between 6 and 14; many surgeons prefer to use TEN and external fixation in open fractures<sup>11</sup>. Therefore, more comparative studies are still needed in the therapeutic options of treating pediatric humeral fracture.

In the early 1990s, the early enthusiasm for TEN of humeral shaft fractures began in Europe<sup>12,13</sup>. Accumulating studies on the topic are from Europe, particularly the experience of using the flexible nails that originated at the University of Nancy, France<sup>13</sup>. As reported, the popularity of TEN has grown in North America and other parts of the world in other long bones, such as the femur, tibia, and the forearm<sup>14</sup>. TEN is an elastic stable intra-medullary nail which counteracts the distraction and compression forces at the fracture site<sup>15</sup>. It has been used in the treatment of humeral fracture, femoral shaft fractures, proximal humeral fractures, clavicular midshaft fractures, etc. in children<sup>16-18</sup>. For example, Rollo *et al.*<sup>19</sup> showed that humeral fracture patients treated with TEN are more satisfied compared with external fixation. Compared with traditional surgical methods, TEN has superior value to plate fixation with less blood loss, shorter operative time, and less economic loss<sup>20</sup>. Some researchers found hospitalization time was decreased using TEN<sup>17</sup>. Elastic intramedullary nail achieved good results in stability and early weight bearing<sup>21</sup>. Some researchers believed that the treatment of humeral shaft fractures guarantee overlapping results with the use of ORIF, TEN, or the external fixator<sup>22</sup>. Others believed that the treatment of humeral shaft fractures with external fixators provide similar results as those of other techniques<sup>23</sup>. These studies have reported conflicting results regarding the treatment of humeral fracture. However, the comparison between ORIF and TEN in treating humeral fracture is rarely reported.

Here, we compared the efficacy and safety of ORIF and TEN in the treatment of humeral fracture in children, aiming to add valuable evidence and provide guidance to surgeons when treating middle or distal humeral fractures in children. The purpose of the current study could be summarized into three points: (i) to compare the therapeutic efficacy between TEN and ORIF on pediatric humeral fractures; (ii) to compare the complications after the operation between TEN and ORIF; (iii) to provide a theoretical basis for treating pediatric humeral fractures using TEN.

## Materials and Methods

### General Information

A retrospective study was carried out and patients who were diagnosed with humeral fracture that underwent surgery

from January 2013 to December 2018 in The Second Affiliated Hospital and Yuying Children's Hospital of Wenzhou Medical University were enrolled in this study. According to AO classification<sup>24</sup>, they were classified as type A, B, or C.

Inclusion criteria were as follows (i) patients with closed fresh fracture of middle or distal one-third humerus; (ii) patients with no symptoms of radial nerve paralysis; (iii) patients who were 6 to 12 years old and were diagnosed in accordance with AO type humeral fracture; (iv) patients who received TEN or ORIF surgeries to treat humeral fractures; (v) patients with complete data during the hospital and the follow-ups.

Exclusion criteria were as follows (i) pathological middle or distal humeral fracture and humeral nonunion; (ii) other injuries that affect shoulder and elbow function.

### **Surgery Process**

#### *Anesthesia and Position (Step 1)*

The patients underwent different surgeries, including TEN ( $n = 47$ ) and ORIF ( $n = 22$ ) according to their disease status. For ORIF, nerve block of brachial plexus was used, and patients were maintained at supine position. Anterolateral incision of the upper arm<sup>25</sup> was taken. For TEN, patients received general anesthesia, and were maintained in supine position.

#### *Approach and Exposure (Step 2)*

For ORIF, the radial nerve was exposed through the interstitial space between the brachialis and the brachioradialis under direct vision. For TEN, a small incision (about 0.5 cm in length) was made at 2–3 cm above the internal humerus and the lateral condyle.

#### *Pathological Changes, Resection (Step 3)*

For ORIF, after the fracture reached anatomic reduction or near anatomic reduction, the 6–10-hole compression plate was placed in the anterolateral humerus for fixation. For TEN, under C-arm X-ray machine, the bone cones and the long axis of humerus (an angle of 40°–60°) were slowly stabbed into cortical bone, and two intramedullary nails were used to make it pre-curved according to the size of the humeral medullary.

#### *Fixation or Placement of Prosthesis (Step 4)*

For ORIF, cataclastic bone block or sclerite was tightly bound. For TEN, the two elastic intramedullary nails were inserted from the inside and outside of the humerus to the fracture line with elastic intramedullary nail T-shaped holder. If closed reduction inserted into proximal fracture was unsuccessful, an incision (3 cm) was made at the fracture site to ensure a successful reduction under direct vision.

#### *Reconstruction (Step 5)*

For ORIF, if the efficacy of fracture reduction and internal fixation confirmed by C-arm X-ray machine was good, the

incision was washed and sutured. For TEN, proximal elastic intramedullary nail was inserted into tubercle of humerus level. Nail end was cut off, and 1.0–1.5 cm of nail was retained outside the cortical bone.

#### *Postoperative Treatment*

Patients of the two groups took antibiotics for 3 days. Movement of the injured limb was restricted by neck–wrist sling suspension. After the formation of a small amount of callus, external fixator was removed, and active exercise of elbow and shoulder was kept for two weeks. The flexible nails were removed after about 6 months.

#### **Outcome Measures**

Intraoperative bleeding, operation time, length of stay (LOS), fracture healing time, shoulder range of motion and elbow range of motion at 3 and 6 months after surgery, UCLA shoulder function score<sup>26</sup>, Mayo elbow performance score (MEPS)<sup>27</sup>, and complications were compared between the two groups.

#### *Length of Stay (LOS)*

LOS refers to the time interval between the admission to the hospital and the discharge. LOS could indicate the therapeutic effect at hospital, and it is an important parameter that is widely used to evaluate the efficacy of the chosen treatment.

#### *Fracture Healing Time*

Fracture healing time refers to the time interval from the completion of the surgery to the healing (union or non-union) of the fracture. Fracture healing time could indicate the therapeutic effect of the surgery, and it is an important parameter that is widely used to evaluate the complications after surgery.

#### *UCLA Shoulder Function Score*

UCLA shoulder function score was designed to evaluate the postoperative results for shoulder arthroplasty. The UCLA shoulder function score consists of pain (10 points), functions (10 points), elbow range of motion in the joint (5 points), manual muscle test (5 points), and patient satisfaction level (5 points) for a total of 35 points. The following outcome criteria are used: Excellent, 34 points; Good, 28 to 33 points; Fair, 21 to 27 points; and Poor, 20 points. At present, the UCLA shoulder function scoring system is used worldwide and shows good correlation with clinical outcome in patients who have undergone forearm-associated surgeries.

#### *Mayo Elbow Performance Score (MEPS)*

MEPS is a widely used performance index for evaluation of clinical outcomes for a variety of elbow disorders. It consists of assessment of pain, arc of motion, stability, and a patient rating of daily function. Pain is weighted highest of the four variables. The scale ranges from 0 to 100, with a higher score indicating a better outcome.

### Statistical Analysis

All data were analyzed by SPSS software (version 16.0, IBM, Armonk, NY, USA). The differences of sex, fracture site, fracture classification between the two groups were detected by  $\chi^2$  test. The differences of age, course of disease, intraoperative bleeding, operation time, LOS, fracture healing time, shoulder range of motion and elbow range of motion 6 months after surgery, UCLA shoulder function score, and MEPS between the two groups were detected by the *t* test. The *P* value <0.05 was considered statistically significant.

## Results

### General Results

A total of 69 patients were enrolled in this study, including 41 males and 28 females. They were aged from 6 to 12 years with a median of 8 years. There were 25 patients (36.2%) with middle humeral fracture, and 44 patients (63.8%) with distal humeral fracture. Humeral fracture occurred in the left side (27 cases, 39.1%) and in the right side (42 cases, 60.9%). According to AO classification, 20 cases (29.0%) belong to type A fracture, 37 cases (53.6%) belong to type B fracture, and 12 cases (14.4%) belong to type C fracture. Time interval from injury to surgery was from 1 to 8 days with a median of 3 days. There were no significant differences in sex, age, fracture site, course of disease, or fracture classification between the two groups (Table 1).

### Intraoperative and Postoperative Results

Intraoperative bleeding in TEN group was significantly decreased compared to that of ORIF group (TEN vs ORIF,  $97.20 \pm 27.83$  mL vs  $185.60 \pm 37.50$  mL, *P* = 0.000), and operation time (TEN vs ORIF,  $53.70 \pm 11.87$  min vs  $73.50 \pm 13.33$  min, *P* = 0.001) and fracture healing time (TEN vs ORIF,  $9.30 \pm 4.23$  weeks vs  $13.45 \pm 3.67$  weeks, *P* = 0.005) in TEN group were also significantly reduced compared to the ORIF group. There was no significant difference in LOS between the two groups (TEN vs ORIF,  $12.40 \pm 1.58$  days vs  $11.80 \pm 1.25$  days, *P* = 0.963, Table 2).

### Functional Evaluation

Shoulder range of motion (TEN vs ORIF,  $110.88^\circ \pm 15.82^\circ$  vs  $98.37^\circ \pm 16.22^\circ$ , *P* = 0.000) and elbow range of motion (TEN vs ORIF,  $105.23^\circ \pm 2.81^\circ$  vs  $87.12^\circ \pm 4.73^\circ$ , *P* = 0.000) 3 months after surgery, as well as shoulder range of motion (TEN vs ORIF,  $162.88^\circ \pm 17.29^\circ$  vs  $117.65^\circ \pm 19.38^\circ$ , *P* = 0.000) and elbow range of motion (TEN vs ORIF,  $137.47^\circ \pm 4.82^\circ$  vs  $109.67^\circ \pm 5.83^\circ$ , *P* = 0.000) 6 months after surgery, in TEN group were greater than those in ORIF group. UCLA shoulder function score (TEN vs ORIF,  $28.58 \pm 4.74$  vs  $21.64 \pm 7.23$ , *P* = 0.000) and MEPS (TEN vs ORIF,  $80.76 \pm 3.53$  vs  $65.33 \pm 9.43$ , *P* = 0.000) 3 months after surgery, as well as UCLA shoulder function score (TEN vs ORIF,  $33.05 \pm 3.27$  vs  $25.78 \pm 3.87$ , *P* = 0.000) and MEPS (TEN vs ORIF,  $97.48 \pm 1.23$  vs  $88.22 \pm 3.65$ , *P* = 0.000) 6 months after surgery, were higher in TEN group than those in ORIF group (Fig. 1).

### Complications of the Patients

In a total of 47 cases treated with TEN, complications occurred in three cases (6.38%), with one case (2.13%) of bone nonunion and two cases (4.25%) of irritation response around the nail. In a total of 22 children treated with ORIF, complications occurred in four cases (18.18%), with one case (4.55%) of delayed healing, one case (4.55%) of deep infection, and two cases (9.08%) of radial nerve injury. Malunion or implant failure did not occur in any of the patients. The complication rate was not significantly different between the two groups ( $\chi^2 = 2.289$ , *P* = 0.130). X-ray films of typical cases with the treatment of ORIF and TEN were shown in Figs. 2 and 3.

## Discussion

### Comparison of the Therapeutic Efficacy between TEN and ORIF

TEN is currently considered superior in surgical treatment of long bone fractures in school-age pediatric patients. Several biomechanical studies have been performed to investigate superiority of one material over the other for humeral shaft fractures. Westrick *et al.*<sup>28</sup> showed that conservative treatment of humeral shaft fractures has a higher rate of bone

**TABLE 1** Comparison of general information between TEN group and ORIF group

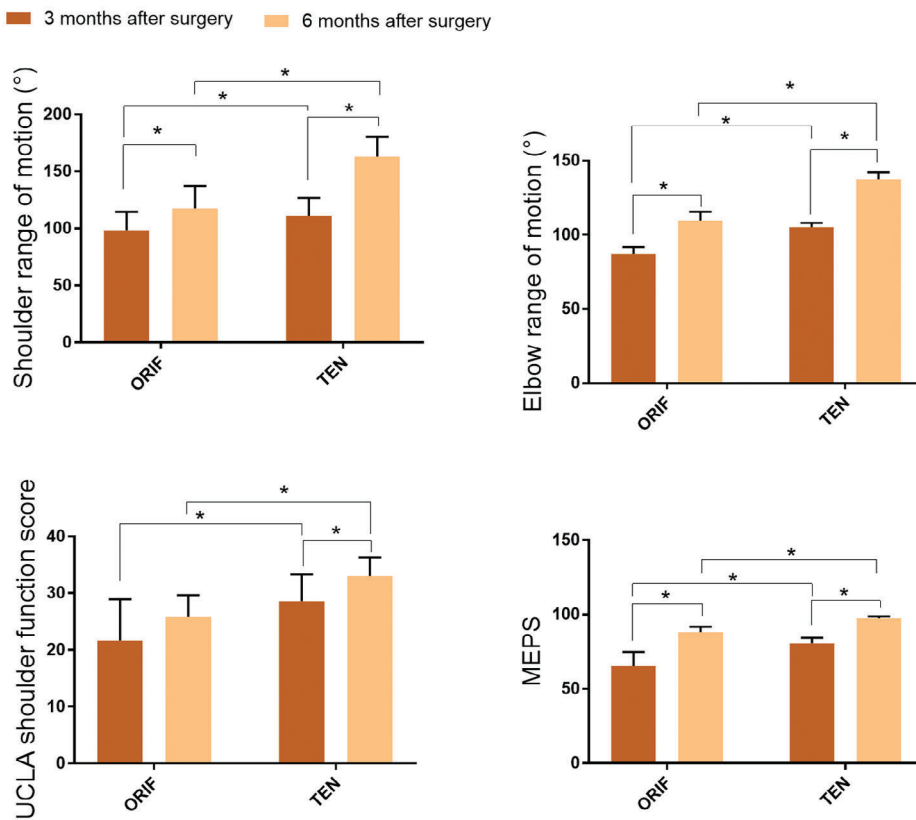
Groups	Sex (n)		Age (years)	Fracture site (n)		Course (days)	Fracture classification (n)*		
	Male	Female		Middle	Distal		A	B	C
TEN	28	19	$8.18 \pm 2.36$	32	15	$3.37 \pm 1.58$	14	26	7
ORIF	13	9	$8.23 \pm 1.89$	12	10	$3.58 \pm 1.34$	6	11	5
	$\chi^2 = 0.001$ <i>P</i> = 0.970		<i>t</i> = 0.583 <i>P</i> = 0.463	$\chi^2 = 1.189$ <i>P</i> = 0.276		<i>t</i> = 1.539 <i>P</i> = 0.338	$\chi^2 = 0.641$ <i>P</i> = 0.726		

\* Patients were classified as A, B, and C types according to AO classification. TEN, titanium elastic intramedullary nail. ORIF, open reduction and internal fixation with plate.

**TABLE 2** Comparison of intraoperative bleeding, operation time, LOS, and fracture healing time between TEN group and ORIF group ( $\bar{x} \pm s$ )

Groups	Intraoperative bleeding (mL)	Operation time (min)	LOS (days)	Fracture healing time (weeks)
ORIF (n = 22)	185.60 ± 37.50	73.50 ± 13.33	11.80 ± 1.25	13.45 ± 3.67
TEN (n = 47)	97.20 ± 27.83	53.70 ± 11.87	12.40 ± 1.58	9.30 ± 4.23
t value	8.384	3.460	0.237	3.267
P value	<b>0.000</b>	<b>0.001</b>	0.963	<b>0.005</b>

LOS, length of stay; ORIF, open reduction and internal fixation with plate; TEN, titanium elastic intramedullary nail.



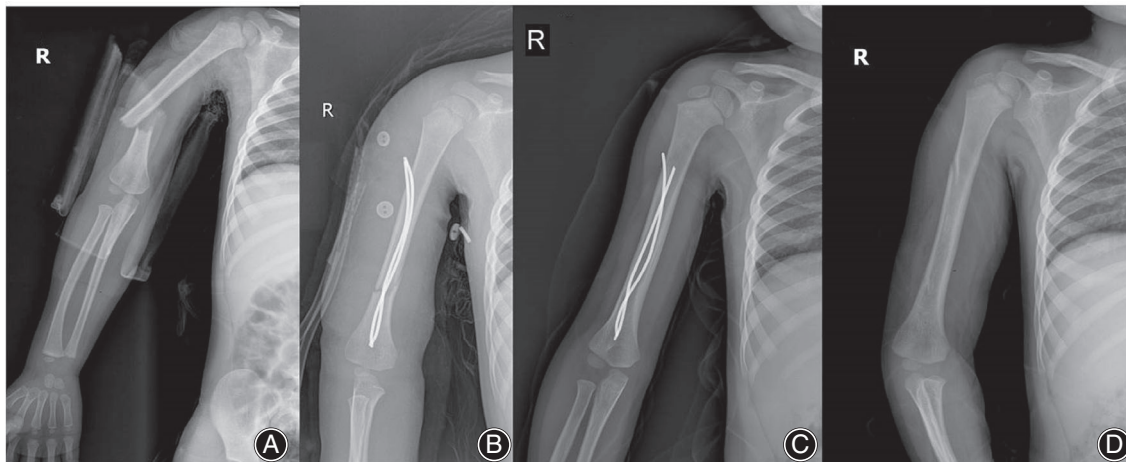
**Fig. 1** Comparison of shoulder range of motion and elbow range of motion, UCLA shoulder function score, and MEPS between TEN group and ORIF group at 3 and 6 months after surgery. MEPS, Mayo elbow performance score. TEN, titanium elastic intramedullary nail. ORIF, open reduction and internal fixation with plate. \* $P < 0.05$ .

nonunion, while operative treatment is associated with a low incidence of iatrogenic nerve palsy but higher rates of infection. Harkin *et al.*<sup>29</sup> demonstrated that there were high rates of delayed union and nonunion with conservative management in comparison with early operative fixation, and that patients with a significant psychiatric history may benefit from consideration of operative intervention. Seo *et al.*<sup>30</sup> showed that dual 3.5-mm locking compression plate (LCP) fixation to the humerus is a possible treatment choice for diaphyseal humeral fractures in comparison with the conventional single 4.5-mm LCP fixation. Rollo *et al.*<sup>19</sup> showed that humeral fracture patients treated with TEN are more satisfied compared with external fixation. These studies revealed that operative treatment with nails or plates is becoming an ideal choice in treating humeral shaft fractures.

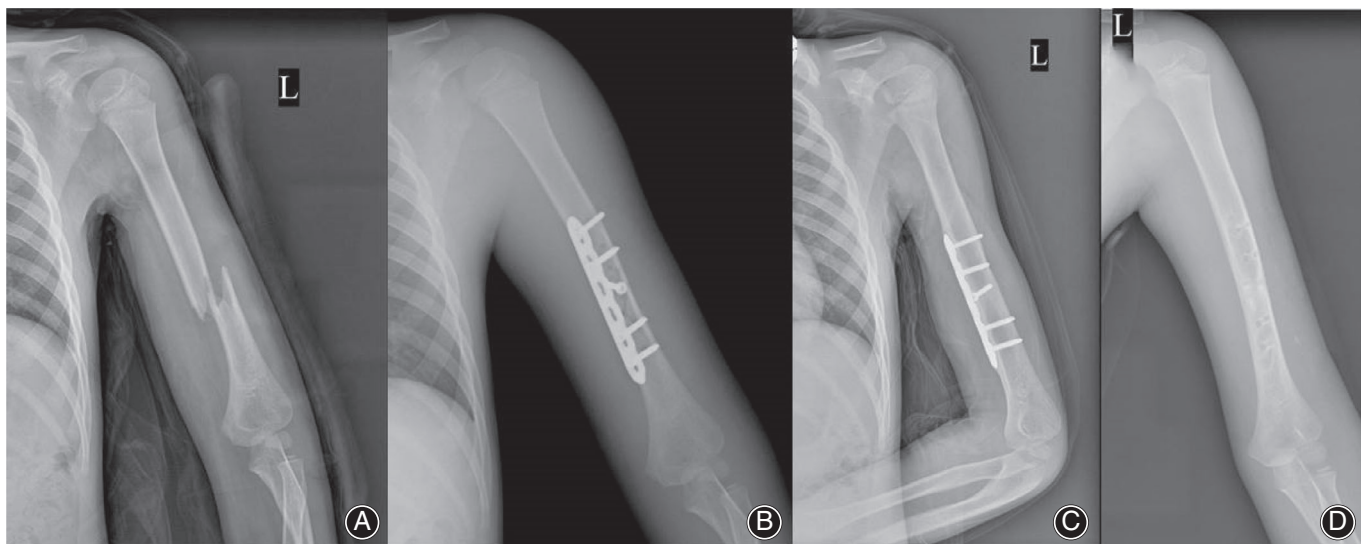
However, the comparison between ORIF and TEN in treating humeral fracture is rarely reported. In the current study, we compared 69 humeral fracture cases treated with TEN or ORIF and found that TEN can be an ideal strategy for the treatment of humeral fracture in children.

The treatments of humeral fracture in children are different from adults, and it is much more important in protecting epiphysis and bone blood supply for children<sup>31</sup>. Disadvantages such as bleeding and higher incidence rate of nerve and epiphysis injury are commonly seen in traditional fixation methods of ORIF with Kirschner wire, plate, and interlocking intramedullary nailing<sup>32</sup>. To combat these shortcomings, TEN was invented and brought many advantages in the treatment of humeral fracture in children. With the elastic characteristic, TEN could easily maintain the





**Fig. 2** The X-ray films of a 9-year-old male patient with distal one-third of humeral fracture using titanium elastic intramedullary nail (TEN) treatment. (A) Preoperative X-ray film. (B) Postoperative X-ray film. (C) Twelve weeks after surgery. (D) X-ray film after pulling nail.



**Fig. 3** The X-ray films of a 12-year-old male patient with middle humeral fracture using open reduction and internal fixation with plate (ORIF) treatment. (A) Preoperative X-ray film. (B) Postoperative X-ray film. (C) Twelve weeks after surgery. (D) X-ray film after pulling nail.

anatomical apposition and cross through the fracture ends. In addition, the slight move of the fracture end caused by TEN is beneficial for the formation of callus. Therefore, TEN has been widely used in the treatment of long bone fracture of limbs<sup>33-35</sup>.

#### **Comparison of the Complications after the Operation between TEN and ORIF**

Most children with humeral shaft fractures are treated conservatively. However, the 1/3 of the distal end of the humerus is triangular in cross section, where the periosteum is weaker than that of the supracondylar region, resulting in poor stability and long healing time after fracture. The blood

supply in the middle and distal one-third humerus mainly comes from the nutrient vessels of middle and upper humerus. If this site is fractured, the nutrient vessels will be injured. Therefore, complications including varus of elbow joints, delayed healing, fracture relocation, malunion, and elbow dysfunction are common during non-surgical treatment. An observation conducted by Rollo *et al.*<sup>36,37</sup> showed that plating with supporting allograft can be a good choice of treating aseptic non-union of the humeral shaft. They also found that the plate-and-bone-strut allograft technique with bone chip augmentation in distal humeral shaft for aseptic non-unions resulted in union of all cases<sup>38</sup>. Older children have the characteristics of obvious fracture displacement,

rotation, and angulation instability, and they are more likely to have complications. For some of these fractures, we use internal fixation, including TEN and ORIF. As a retrospective study, we screened patients who had undergone surgery from previously hospitalized patients, comparing the therapeutic differences between TEN and ORIF. ORIF is not commonly used to treat young patients. However, for patients with poor outcome of conservative treatment, for example those patients who are difficult to effectively fix using brace or splint due to obesity, surgical treatment with ORIF is also an option. However, ORIF may injure the periosteum and muscle of fracture end, which leads to insufficient blood supply of fracture end<sup>39</sup>. TEN avoids large-scale dissection of soft tissue and periosteum. It has limited side effects on bone blood supply and soft tissue injury, and can avoid radial nerve injury and keep the blood circulation of the fracture part and the fixed area, thus to promote fracture healing<sup>40,41</sup>.

### Clinical Experience for Treating Pediatric Humeral Fractures Using TEN

During the TEN surgery, previous studies have summarized some methods dealing with the troubles we met in treating a humeral fracture, which were: (i) the diameter of TEN should be 50%–60% of the narrowest part of the humeral shaft. TEN with a diameter of 2.5 mm is recommended for children aged 6–10 years, and 3.0–3.5 mm is recommended

for children over 10 years; (ii) the thicker the TEN, the stronger the elasticity and fixation. However, the difficulty of insertion will increase; and (iii) postoperative irritability reaction around nails should be watched<sup>42,43</sup>.

### Limitations of the Study

The limitation of this study is that the sample size is small. Also, this study lacks the data from patients who received the conservative treatment or the external fixation. Therefore, larger samples and randomized controlled studies are still needed in our future research.

### Conclusion

Our findings demonstrated that TEN can be an ideal technique for the treatment of humeral fracture in children with the advantages of less intraoperative bleeding, shorter operative time, quicker healing, and better recovery of shoulder range of motion and elbow range of motion.

### Acknowledgments

This study was partially supported by the Medical Health Science and Technology Project of Zhejiang Provincial Health Commission (Grant number: 2019KY782) and the Science and Technology Project of Taizhou (Grant number: 1901ky50).

### References

1. Weltsch D, Baldwin KD, Talwar D, Flynn JM. Expert consensus for a principle-based classification for treatment of diaphyseal pediatric femur fractures. *J Pediatr Orthop*, 2020, 40: e669–e675.
2. Stedtfeld H, Biber R. Proximal third humeral shaft fractures—a fracture entity not fully characterized by conventional AO classification. *Injury*, 2014, 45: S54–S59.
3. Dorr M, Backes M, Luitse J, de Jong V, Schepers T. Complications of kirschner wire use in open reduction and internal fixation of calcaneal fractures. *J Foot Ankle Surg*, 2016, 55: 915–917.
4. Xia S, Lu X, Wang H, Wu Z, Wang Z. Open reduction and internal fixation with conventional plate via L-shaped lateral approach versus internal fixation with percutaneous plate via a sinus tarsi approach for calcaneal fractures - a randomized controlled trial. *Int J Surg*, 2014, 12: 475–480.
5. Keeler K, Dart B, Luhmann S, et al. Antegrade intramedullary nailing of pediatric femoral fractures using an interlocking pediatric femoral nail and a lateral trochanteric entry point. *J Pediatr Orthop*, 2009, 29: 345–351.
6. Lin T, Xiao B, Ma X, Fu D, Yang S. Minimally invasive plate osteosynthesis with a locking compression plate is superior to open reduction and internal fixation in the management of the proximal humerus fractures. *BMC Musculoskelet Disord*, 2014, 15: 206.
7. Claessen FM, Peters RM, Verbeek DO, Helfet DL, Ring D. Factors associated with radial nerve palsy after operative treatment of diaphyseal humeral shaft fractures. *J Shoulder Elbow Surg*, 2015, 24: e307–e311.
8. Badkoobei H, Choi PD, Bae DS, Skaggs DL. Management of the pulseless pediatric supracondylar humeral fracture. *J Bone Joint Surg Am*, 2015, 97: 937–943.
9. Orbach H, Rozen N, Rubin G, Dujovny E, Bor N. Outcomes of French's corrective osteotomy of the humerus for cubitus varus deformity in children. *Isr Med Assoc J*, 2018, 20: 442–445.
10. Mitchell SL, Sullivan BT, Ho CA, Abzug JM, Raad M, Sponseller PD. Pediatric gartland type-IV supracondylar humeral fractures have substantial overlap with flexion-type fractures. *J Bone Joint Surg Am*, 2019, 101: 1351–1356.
11. Kelly DM. Flexible intramedullary nailing of pediatric humeral fractures: indications, techniques, and tips. *J Pediatr Orthop*, 2016, 36: S49–S55.
12. Garg S, Dobbs MB, Schoenecker PL, Luhmann SJ, Gordon JE. Surgical treatment of traumatic pediatric humeral diaphyseal fractures with titanium elastic nails. *J Child Orthop*, 2009, 3: 121–127.
13. Lascombes P, Haumont T, Journeau P. Use and abuse of flexible intramedullary nailing in children and adolescents. *J Pediatr Orthop*, 2006, 26: 827–834.
14. Hutchinson PH, Bae DS, Waters PM. Intramedullary nailing versus percutaneous pin fixation of pediatric proximal humerus fractures: a comparison of complications and early radiographic results. *J Pediatr Orthop*, 2011, 31: 617–622.
15. Govindasamy R, Kasirajan S, Meleppuram J, Thonikadavath F. A retrospective study of titanium elastic stable intramedullary nailing in displaced mid-shaft clavicle fractures. *Rev Bras Ortop*, 2017, 52: 270–277.
16. Nielsen E, Bonsu N, Andras L, Goldstein R. The effect of canal fill on paediatric femur fractures treated with titanium elastic nails. *J Child Orthop*, 2018, 12: 15–19.
17. Govindasamy R, Gnanasundaram R, Kasirajan S, Ibrahim S, Meleppuram J. Elastic stable intramedullary nailing of femoral shaft fracture-experience in 48 children. *Arch Bone Jt Surg*, 2018, 6: 39–46.
18. Xu X, Lu X, Luo L, Zhang X, Wang Y. Effectiveness comparison of titanium elastic nail and locking compression plate fixation in treating femoral subtrochanteric fractures in older children. *Zhongguo Xiu Fu Chong Jian Wai Ke Za Zhi*, 2017, 31: 1184–1189.
19. Rollo G, Guida P, Bisaccia M, et al. TEN versus external fixator in the management of pediatric diaphyseal femoral fractures: evaluation of the outcomes. *Eur J Orthop Surg Traumatol*, 2018, 28: 1421–1428.
20. Allen J, Murr K, Albitar F, Jacobs C, Moghadamian E, Muchow R. Titanium elastic nailing has superior value to plate fixation of midshaft femur fractures in children 5 to 11 years. *J Pediatr Orthop*, 2018, 38: e111–e117.
21. Bauer J, Hirzinger C, Metzger R. Quadruple ESIN (elastic stable intramedullary nailing): modified treatment in pediatric distal tibial fractures. *J Pediatr Orthop*, 2017, 37: e100–e103.
22. Bisaccia M, Meccariello L, Rinonapoli G, et al. Comparison of plate, nail and external fixation in the management of diaphyseal fractures of the humerus. *Med Arch*, 2017, 71: 97–102.
23. Bisaccia M, Meccariello L, Rinonapoli G, et al. Reliability and value of external modular fixation (Hoffmann II®) in the management of humeral shaft fracture. *Clin Cases Miner Bone Metab*, 2018, 15: 423–427.
24. Obruba P, Kopp L, Edelmann K. Treatment of humeral shaft fractures using Hackethal's technique of intramedullary bundle nailing. *Acta Chir Orthop Traumatol Cech*, 2012, 79: 341–346.
25. Singh A, Narsaria N, Seth R, Garg S. Plate osteosynthesis of fractures of the shaft of the humerus: comparison of limited contact dynamic compression plates and locking compression plates. *J Orthop Traumatol*, 2014, 15: 117–122.
26. Ellman H, Hanker G, Bayer M. Repair of the rotator cuff. End-result study of factors influencing reconstruction. *J Bone Joint Surg Am*, 1986, 68: 1136–1144.

- 27.** Morrey B, Bryan R, Dobyns J, Linscheid R. Total elbow arthroplasty. A five-year experience at the Mayo Clinic. *J Bone Joint Surg Am*, 1981, 63: 1050–1063.
- 28.** Westrick E, Hamilton B, Toogood P, Henley B, Firoozabadi R. Humeral shaft fractures: results of operative and non-operative treatment. *Int Orthop*, 2017, 41: 385–395.
- 29.** Harkin FE, Large RJ. Humeral shaft fractures: union outcomes in a large cohort. *J Shoulder Elbow Surg*, 2017, 26: 1881–1888.
- 30.** Seo JB, Heo K, Yang JH, Yoo JS. Clinical outcomes of dual 3.5-mm locking compression plate fixation for humeral shaft fractures: comparison with single 4.5-mm locking compression plate fixation. *J Orthop Surg (Hong Kong)*, 2019, 27: 2309499019839608.
- 31.** Sahu R. Percutaneous Kirschner wire (K-wire) fixation for humerus shaft fractures in children: A treatment concept. *Niger Med J*, 2013, 54: 356–360.
- 32.** Kosuge D, Barry M. Changing trends in the management of children's fractures. *Bone Joint J*, 2015, 97: 442–448.
- 33.** Kraus R, Schiefer U, Schäfer C, Meyer C, Schnettler R. Elastic stable intramedullary nailing in pediatric femur and lower leg shaft fractures: intraoperative radiation load. *J Pediatr Orthop*, 2008, 28: 14–16.
- 34.** Yang M, Chi Y, Wang C, Sun L, Zhang J. Case-control study on therapeutic effects of elastic stable intramedullary nails in the treatment of stable and unstable fractures of femoral shaft in children. *Zhongguo Gu Shang*, 2012, 25: 116–119.
- 35.** Drosos G, Stavropoulos N, Kazakos K. Peroneal nerve damage by oblique proximal locking screw in tibial fracture nailing: a new emerging complication?. *Arch Orthop Trauma Surg*, 2007, 127: 449–451.
- 36.** Rollo G, Prkić A, Bisaccia M, et al. Grafting and fixation after aseptic non-union of the humeral shaft: a case series. *J Clin Orthop Trauma*, 2020, 11: S51–S55.
- 37.** Rollo G, Rotini R, Pichierrì P, et al. Grafting and fixation of proximal humeral aseptic non union: a prospective case series. *Clin Cases Miner Bone Metab*, 2017, 14: 298–304.
- 38.** Rollo G, Prkić A, Pichierrì P, et al. Plate-and-bone-strut fixation of distal third humeral shaft aseptic non-unions: a consecutive case series. *J Clin Orthop Trauma*, 2019, 10: S127–S132.
- 39.** Xue Z, Jiang C, Hu C, Qin H, Ding H, An Z. Effects of different surgical techniques on mid-distal humeral shaft vascularity: open reduction and internal fixation versus minimally invasive plate osteosynthesis. *BMC Musculoskelet Disord*, 2016, 17: 370.
- 40.** Upadhyay A, Lil N. Use of titanium elastic nails in the adult diaphyseal humerus fractures. *Malays Orthop J*, 2017, 11: 53–59.
- 41.** Kapila R, Sharma R, Chugh A, Goyal M. Evaluation of clinical outcomes of management of paediatric bone forearm fractures using titanium elastic nailing system: a prospective study of 50 cases. *J Clin Diagn Res*, 2016, 10: RC12–RC15.
- 42.** Li Y, Stabile K, Shilt J. Biomechanical analysis of titanium elastic nail fixation in a pediatric femur fracture model. *J Pediatr Orthop*, 2008, 28: 874–878.
- 43.** Gibon E, Béranger J, Bachy M, Delpont M, Kabbaj R, Vialle R. Influence of the bending of the tip of elastic stable intramedullary nails on removal and associated complications in pediatric both bone forearm fractures: a pilot study. *Int J Surg*, 2015, 16: 19–22.