

## CASE REPORT

# Post-gastrectomy Syndrome Successfully Treated With Kampo Medicine: A Case Report

后胃切除综合征成功治疗汉方医学：病例报告

Síndrome post-gastrectomía exitosamente tratados con la medicina Kampo: Reporte de un caso

Miwako Ohgishi, *Japan*; Yuko Horiba, *Japan*; Kenji Watanabe, *Japan*



Content designated  
as open access

## Author Affiliations

Center for Kampo  
Medicine, Keio  
University School of  
Medicine, Shinjuku-ku,  
Tokyo, Japan  
(Drs Ohgishi, Horiba,  
and Watanabe); Faculty  
of Environment and  
Information Study, Keio  
University, Fujisawa,  
Kanagawa, Japan  
(Dr Watanabe).

## Correspondence

Kenji Watanabe  
watanabeknji@keio.jp

## Citation

Global Adv Health Med.  
2016;5(1):112-116. DOI:  
10.7453/gahmj.2015.030

## Disclosures

The authors completed  
the ICMJE Form for  
Disclosure of Potential  
Conflicts of Interest and  
had no conflicts  
to disclose.

## Key Words

Senpukukataishasekito,  
cancer, quality of life,  
weight loss, fatigue

## ABSTRACT

Cancer-related gastrectomy can cause post-gastrectomy syndrome, which includes weight loss, dumping syndrome, and reflux esophagitis and negatively affects the quality of life. Comprehensive and individualized patient management is required; however, there is a limit to Western medicine's ability to treat these symptoms. Kampo, a traditional Japanese medicine, adapts treatments to each individual's symptoms and constitution. We treated a 68-year-old male patient with post-gastrectomy syndrome using senpukukataishasekito, a Kampo medicine. He was diagnosed with Stage II-A gastric cancer at age 66 years and underwent a laparoscopic, pylorus-preserving gastrectomy followed by chemotherapy for 13 months. He visited our clinic for chemotherapy-related fatigue, postsurgical weight loss, and limb numbness. He was prescribed both hachimijiogan and hochuekkito. At the second visit, he complained of stomach discomfort, so we prescribed senpukukataishasekito. As his stomach function improved, his body weight increased and his fatigue decreased. We suggest that senpukukataishasekito may be an effective treatment for post-gastrectomy syndrome.

## 摘要

癌症相关胃切除术可能导致胃切除后综合征，其中包括体重下降、倾倒综合征、反流性食管炎和对生活质量的负面影响。需要全面和个性化的病患管理；但西药治疗这些症状的效果有限。日本传统汉方医学采用适应每一个人的症状和体质的疗法。我们用汉方药物旋复花代赭石汤（senpukukataishasekito）治疗过一名68岁的胃切除后综合征男性患者。他在66岁时被诊断患有II-A期胃癌，并接过了保留幽门腹腔镜胃切除术，然后接受化疗13个月。他因为化疗相关的疲劳、术后体重下降和肢体麻木前来我们诊所就诊。给他开了八味地黄丸（hachimijiogan）和补中益气汤（hochuekkito）。第二次就诊时，他主诉胃部不适，因此我们给他开了旋复花代赭石汤。随着胃功能的改善，他的体重增加并且疲劳减轻。我们提出，旋复花代赭石汤也许能够有效治疗胃切除后综合征。

## SINOPSIS

La gastrectomía relacionada con el cáncer puede provocar el síndrome de evacuación gástrica rápida, que incluye pérdida de peso, evacuación gástrica rápida y esofagitis por reflujo gastroesofágico, y afecta

negativamente a la calidad de vida. Es necesario el tratamiento completo e individualizado del paciente; sin embargo, existe un límite en la capacidad de la medicina occidental para tratar estos síntomas. La Kampo, una medicina tradicional japonesa, adapta los tratamientos a los síntomas y constitución de cada individuo. Tratamos a un paciente de 68 años con síndrome de evacuación gástrica rápida usando senpukukataishasekito, una medicina Kampo. Se le diagnosticó un cáncer gástrico en estado II-A a la edad de 66 años y se sometió a una gastrectomía laparoscópica conservando el píloro, seguida de quimioterapia durante 13 meses. Visitó nuestra clínica por cansancio relacionado con la quimioterapia, pérdida de peso posterior a la operación e insensibilidad en las extremidades. Se le prescribieron tanto hachimijiogan como hochuekkito. En la segunda visita, se quejaba de molestias estomacales, así que le prescribimos senpukukataishasekito. A medida que mejoró el funcionamiento de su estómago, aumentó su peso corporal y disminuyó su cansancio. Sugerimos que senpukukataishasekito podría ser un tratamiento eficaz para el síndrome de evacuación gástrica rápida.

## INTRODUCTION

The number of patients with cancer has been increasing worldwide. In Japan, gastrointestinal cancer is the leading type of cancer among men.<sup>1</sup> With developments in therapeutic technique and medicines, patients' long-term survival has increased. After gastrectomy, however, various gastrointestinal dysfunctions such as acid reflux, regurgitation, and anorexia persist, inducing weight loss and impairing postopera-

tive quality of life (QOL). This is known as post-gastrectomy syndrome.<sup>2</sup> Western-based medical treatment of post-gastrectomy syndrome includes acid secretion inhibitors, gastrointestinal promotility agents, and meal instructions.<sup>2</sup> However, because of the variable and subjective nature of these symptoms, there are limitations to Western medicine-only treatment. Comprehensive and individualized management to improve QOL in patients with cancer is vital.

Kampo is a form of traditional medicine practiced in Japan, adapted from ancient Chinese herbal medicine. It is characterized by treatments that are adapted to each individual's symptoms and constitution. Many Kampo formulas have been used for centuries to effectively treat symptoms such as fatigue, weight loss, and appetite loss. It has been reported that the Kampo herbal formulas *rikkunshito* and *daikenchuto* are effective treatments for post-gastrectomy appetite loss, weight loss, diarrhea, constipation, and other symptoms<sup>3,4</sup> and that *hochuekkito* and *juzentaihoto* improve QOL of cancer patients.<sup>5,6</sup> *Senpukukataishasekito* is traditionally used in Japan for gastrointestinal dysfunction in patients with gastric and esophageal cancer, but few case reports exist. Herein, we report a case of successful treatment of post-gastrectomy syndrome with *senpukukataishasekito* following the failure of other Kampo treatments.

### PRESENTING CONCERNS

The patient was a healthy, married 68-year-old man who neither consumed alcohol nor smoked. In July 2010, an upper gastrointestinal endoscopy revealed type o-II c lesions according to Japanese classification of gastric carcinoma<sup>7</sup> in his stomach, and he underwent endoscopic submucosal dissection (ESD). Because the margins were positive, the patient underwent laparoscopic pylorus-preserving gastrectomy in September 2010. The histopathology examination revealed a type o-II c-like advanced lesion that was a poorly differentiated ring cell carcinoma having invasion limited to the muscularis propria, ly (+), UL-III<sub>s</sub>, HMo, VMo, state after ESD, stage IIA, according to the Japanese Classification of Gastric Carcinoma.<sup>7</sup> He was administered tegafur, gimeracil, and oteracil potassium as post-operative adjuvant chemotherapy until October 2011. Although his treatment course went well with no cancer recurrence, he experienced severe fatigue and mild limb numbness following chemotherapy. He visited the Kampo clinic at Keio University Hospital, Tokyo, Japan, in May 2012.

### HISTORY AND CLINICAL FINDINGS

There were no notable findings in the patient's family history. He was taking 24 mg of sennoside, 0.25 mg of brotizolam, and 7.5 mg of zopiclone before sleep, and 3.9 g of S • M compound powder (Daiichi Sankyo Espha Co, Ltd, Tokyo, Japan; it contains taka-diastase 300 mg, magnesium aluminometasilicate 1200 mg, sodium bicarbonate 900 mg, precipitated calcium carbonate 600 mg, *Caryophylli flos* [clove] 30 mg, *Foeniculi fructus* [fennel] 60 mg, *Cinnamomi cortex* [cinnamon bark] 223.5 mg, *Zingiberis rhizoma* [ginger] 73.5 mg, *Zanthoxili fructus* [zanthoxylum fruit] 3 mg, *Coptidis rhizome* [coptis rhizome] 150 mg, *Glycyrrhizae radix* [glycyrrhiza] 354 mg) after each meal. He had no allergies. He was 175 cm tall and weighed 57 kg (72 kg before surgery; minimum weight: 54 kg post-gastrectomy). His body mass index was 18.6. He had a body temperature of 97.7° F, blood pressure of

111/69 mm Hg, and a heart rate of 71 beats per minute. A blood exam showed hemoglobin of 13.0 g/dL and glycated hemoglobin of 6.2%.

### DIAGNOSTIC FOCUS AND ASSESSMENT

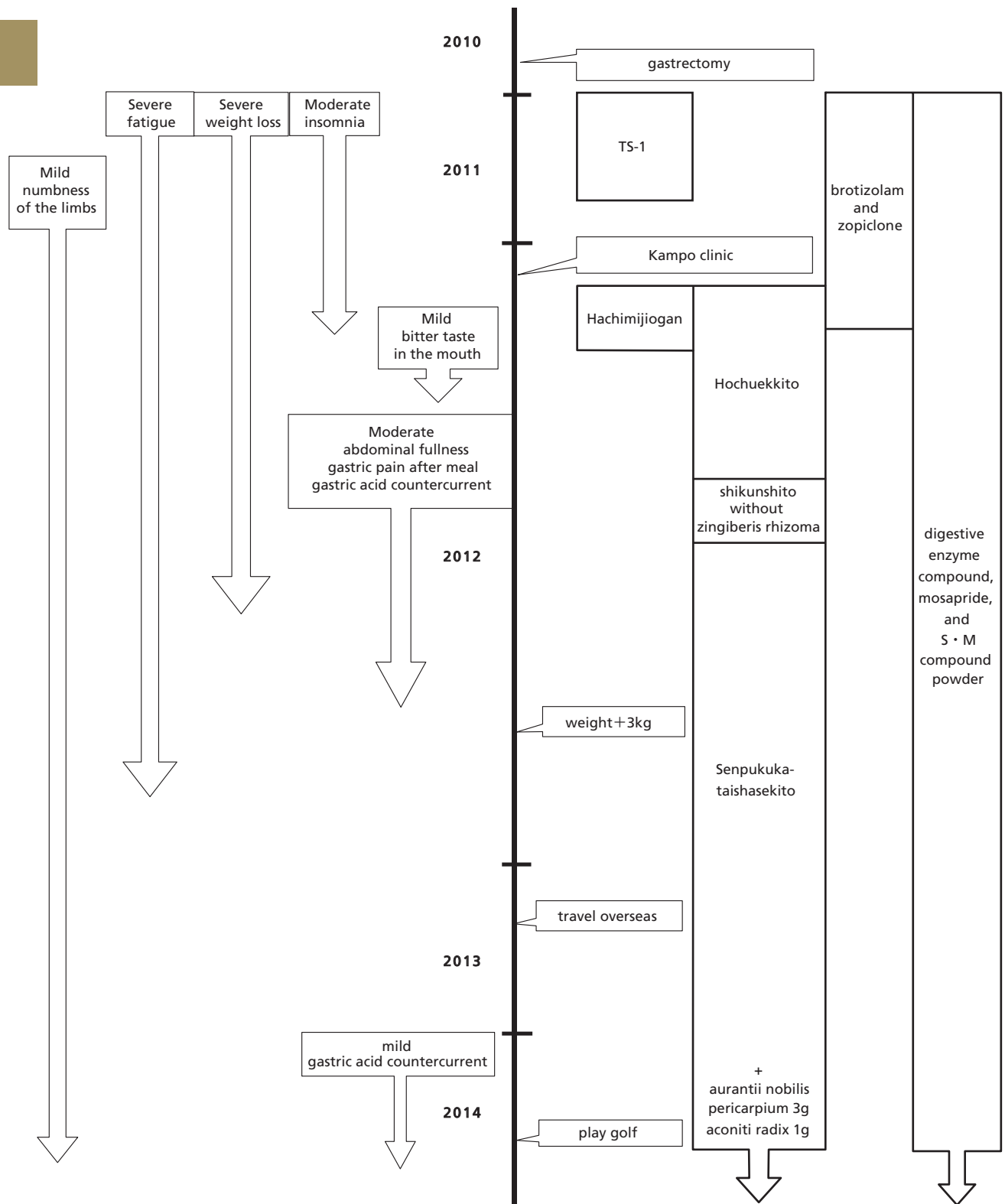
The patient's subjective symptoms were insomnia, fatigue, weight loss, and limb numbness. The Kampo medical findings concluded the patient had a normal physique, a strong floating and string-like pulse, a pale-red tongue with wrinkles with no coating, and dilated sublingual veins. He exhibited deficient abdominal strength, epigastric discomfort and resistance, rectus muscle tension, lower abdominal weakness, and lower abdominal muscle tension. Cold pattern, qi deficiency pattern, and kidney qi deficiency pattern were diagnosed based on Kampo findings.

### THERAPEUTIC FOCUS AND ASSESSMENT

The patient was first prescribed *hochuekkito* (EK-41, Kracie Pharma, Ltd, Tokyo, Japan) and *hachimijiogan* (TJ-7, Tsumura & Co, Tokyo, Japan) (Figure). *Hochuekkito* and *rikkunshito* are variations of *shikunshito*. *Hochuekkito* is used for treating qi deficiency pattern and fatigue, and *hachimijiogan* is used for cold and kidney qi deficiency and limb numbness. The herbal components of the formula are listed in the Table. One month after the first visit, the insomnia had improved and the patient no longer needed hypnotic treatment; however, he complained of a mild bitter taste in his mouth upon waking. We discontinued *hachimijiogan* as we thought this was caused by the *Rehmanniae radix* (*rehmannia* root) in *hachimijiogan*; this alleviated the symptom. In July 2012, the patient complained of a moderate degree of abdominal fullness, gastric pain after eating, and gastric acid reflux. We thought it was caused by the *Zingiberis rhizoma* (ginger) in *hochuekkito* and prescribed instead a decoction of *shikunshito* without *Zingiberis rhizoma*, but the symptoms persisted. In August 2012, we changed the prescription to *senpukukataishasekito*, which is traditionally used for gastrointestinal dysfunction in patients with gastric and esophageal cancer and weaker constitutions. An upper endoscopic examination revealed no abnormalities apart from reflux esophagitis in September 2012. *Senpukukataishasekito* contains the following drugs in raw form: *Pinelliae tuber*, 5 g; *Inula japonica* thumb (dried capitata parts of *Inula britannica* L subsp *japonica* Kitamura), 3 g; hematite, 3 g; *Zizyphi fructus* (jujube), 3 g; *Ginseng radix* (ginseng), 2 g; *Glycyrrhizae radix* (glycyrrhiza), 2 g; and *Zingiberis rhizoma* (ginger), 0.5 g per day. A decoction of these drugs was divided into 3 portions. These herbs included in *shikunshito* without *Zingiberis rhizoma* and *senpukukataishasekito* were products of Uchida Wakanayaku Ltd, Tokyo, Japan.

### FOLLOW-UP AND OUTCOMES

Despite the lack of success with other medications, after 1 month of treatment with *senpukukataishasekito*, the patient's abdominal fullness and gastric pain symptoms improved; after 3 to 4 months, both his



**Figure** Timeline of interventions and outcomes.

gastrointestinal discomfort and his fatigue were reduced. His appetite also improved, and he gained 3 kg. At his initial visit, activities lasting longer than 1.5 h were impossible owing to severe fatigue; 1 year post-treatment, he was able to travel overseas for 2 weeks. In

February 2014, he continued to experience concurrent mild limb numbness and mild gastric acid reflux; we added 3 g of *Aurantii nobilis pericarpium* (citrus Unshiu peel, Uchida Wakanayaku Ltd, Tokyo, Japan) and 1 g of *Processi aconiti radix* (aconitine root, Uchida

**Table 1a** List of the Herbal Components of Hochuekkito, Rikkunshito, Shikunshito, and Senpukukataishasekito

	Hochuekkito	Rikkunshito	Shikunshito	Senpukukataishasekito
<i>Astragali radix</i> (Astragalus root)	○			
<i>Atractylodis lanceae rhizoma</i>	○	○	○	
<i>Ginseng radix</i> (Ginseng)	○	○	○	○
<i>Angelicae radix</i> (Japanese Angelica root)	○			
<i>Bupleuri radix</i> (Bupleurum root)	○			
<i>Zizyphi fructus</i> (Jujube)	○	○	○	○
<i>Aurantii nobilis pericarpium</i> (Citrus unshiu peel)	○	○		
<i>Glycyrrhizae radix</i> (Glycyrrhiza)	○	○	○	○
<i>Cimicifugae rhizoma</i>	○			
<i>Zingiberis rhizoma</i> (Ginger)	○	○	○	○
<i>Pinelliae tuber</i>		○		○
<i>Poria sclerotium</i>		○	○	
<i>Inula japonica</i> thumb (dried capitate parts of <i>inula britannica</i> <i>L. subsp. japonica</i> Kitamura)				○
Hematite (soft hematite)				○

**Table 1b** List of the Herbal Components of Hachimijiogan

Hachimijiogan
<i>Rehmanniae radix</i> (Rehmannia root)
<i>Corni fructus</i> (Cornus fruit)
<i>Dioscoreae Rhizoma</i>
<i>Alismatis Rhizoma</i> (Alisma rhizome)
<i>Poria sclerotium</i>
<i>Moutan cortex</i> (Moutan bark)
<i>Cinnamomi cortex</i> (Cinnamon bark)
<i>Aconiti radix</i> (Aconitine root)

Wakanayaku Ltd, Tokyo, Japan) per day to his treatment, which reduced his symptoms. By 2 years post-treatment, he was able to enjoy golf outings 2 or 3 times a month. He continued taking the same formula with no serious adverse effects.

## DISCUSSION

We presented a case suggesting that senpukukataishasekito might have beneficial effects on patients with post-gastrectomy syndrome following cancer treatment. We initially prescribed hachimijiogan and hochuekkito, but the patient complained of a bitter taste in the mouth, thought to be symptoms of gastric dysfunction caused by the *Rehmanniae radix* in hachimijiogan. However, his insomnia improved with that treatment, and he no longer required hypnotics. As shikunshito is the base of hochuekkito and rikkunshito, hochuekkito and rikkunshito represent variations of shikunshito. Hochuekkito is useful for fatigue and QOL improvement in patients with cancer,<sup>5</sup> and shikunshito is useful for gastrointestinal dysfunction and for patients with weaker constitutions. In our case, gastro-

intestinal discomfort occurred with hochuekkito, which we initially attributed to the *Zingiberis rhizoma* in hochuekkito. We changed the prescription to shikunshito without *Zingiberis rhizoma*, but the symptoms persisted until the prescription was changed to senpukukataishasekito. We concluded the symptoms were not caused by *Zingiberis rhizoma* but rather that the previous medicines were not appropriate for this patient.

The structure of senpukukataishasekito is characterized by the raw drugs senpukuka and taishaseki. Senpukuka is the dried capitate parts of *Inula britannica L subsp japonica* Kitamura (compositae) or closely related plants of the same genus. An old medical text claimed this drug could loosen pressure in the epigastrium and treat hiccups.<sup>8</sup> Taishaseki is soft hematite in earth form, which mainly consists of iron oxide, and is said to supplement blood, constrict veins, and stop bleeding.<sup>8</sup> The effects of the other raw drugs were as follows: *Pinelliae tuber* to treat gastric heaviness and vomiting; *Zizyphi fructus* for chest and abdominal pain and cough; *Ginseng radix* to ease chest pressure and treat poor appetite, abdominal pain, and diarrhea; *Glycyrrhizae radix* for anti-gastric inflammation, analgesic, expectorant, and anti-tussive effects; and *Ingiberis rhizoma* for its diaphoretic and antidiarrheal effects.<sup>8</sup> Shanghanlun at the end of the 2nd century CE, described senpukukataishasekito treatment as follows: "Although the sweating, vomiting or purgation method of treatment has relieved the cold damage, there still remained epigastric discomfort and hiccups, senpukukataishasekito should be given."<sup>9</sup> Keisetsu Otsuka, a Japanese Kampo physician active in the 1900s, argued that senpukukataishasekito can be used postoperatively in patients with gastric cancer or gastric ulcers.<sup>9</sup> It can also be used also for epigastric discomfort, hiccups, and constipation. The target of this medicine is

for a weaker type than shikunshito, and our patient exhibited deficient abdominal strength. He also suffered from epigastric discomfort that hochuekkito and shikunshito could not treat, and thus we chose senpukukataishasekito, which proved effective.

Nutritional changes after gastrectomy result from several processes and can lead to micronutrient deficiencies and food intolerance, which cause significant weight loss. Post-gastrectomy conditions, such as dumping syndrome and alkaline reflux gastritis, may intensify these losses and further hinder nutritional recovery.<sup>2,10</sup> Further, reduced strength due to weight loss can limit the ability to work, and thus weight loss after gastric cancer resection represents an important QOL measure. Being underweight can potentially lead to a poorer prognosis or an inability to tolerate chemotherapy.<sup>10</sup> According to Aoyama et al, weight loss after gastric cancer surgery is caused by 2 mechanisms<sup>10</sup>: first, storage functions are lost due to diminished stomach size; second, it affects ghrelin, a hormone secreted in the stomach that regulates several physiological activities, including appetite stimulation.<sup>11</sup> It has been reported that ghrelin secretion declines after gastric cancer surgery and that serum ghrelin levels are low in the early postoperative stages.<sup>11</sup> Therefore, the primary cause of weight loss after gastric cancer surgery may be reduced food intake due to decreased ghrelin.<sup>9</sup> While ghrelin replacement therapy is a prime therapeutic candidate, the Kampo formula rikkunshito has received attention for its ability to increase ghrelin secretion.<sup>3</sup> Among its ingredients, *Aurantii nobilis pericarpium*, *Zingiberis rhizoma*, and *Atractylodes lancea rhizoma* have been reported as increasing ghrelin signals.<sup>3</sup> Senpukukataishasekito contains *Zingiberis rhizoma*, which may stimulate ghrelin secretion. However, it is important to choose the appropriate medicine for the patient's constitution, as some may not tolerate *Zingiberis rhizoma*.

Due to the variable and subjective nature of post-gastrectomy syndrome symptoms, comprehensive and individualized management is necessary. Kampo is characterized by treatments that are adapted to each individual's symptoms and constitution, making it possible to adjust treatment by adding other raw drugs and modifying quantities. For our patient, we added *aurantii nobilis pericarpium* and *processi aconiti radix* to his treatment, as the former is effective for gastric inflammation and the latter is effective for numbness, and his symptoms were gradually reduced. Kampo offers the flexibility to find a matching formula for patients with various medical conditions and therefore allows us to individualize treatment.

In this report, we demonstrated that senpukukataishasekito may be an effective treatment for post-gastrectomy syndrome, by both reducing fatigue and treating gastrointestinal dysfunction. It represents a new understanding of senpukukataishasekito, which is usually used to treat gastrointestinal dysfunction. It also improved patients' post-gastrectomy QOL. While basic science data for senpukukataishasekito treat-

ment is not yet available, further research is needed to examine the effects of its ingredients on the treatment of post-gastrectomy syndrome.

## PATIENT CONSENT

The patient gave written permission for the publication of this case report.

## REFERENCES

1. Matsuda A, Matsuda T, Shibata A, Katanoda K, Sobue T, Nishimoto H; The Japan Cancer Surveillance Research Group. Cancer incidence and incidence rates in Japan in 2008: a study of 25 population-based cancer registries for the Monitoring of Cancer Incidence in Japan (MCII) Project. *Japan J Clin Oncol*. 2013;44(4):388-96.
2. Koji Nakata. Actual conditions and management of postgastrectomy syndrome—an introduction. Japanese Society of Gastroenterological Surgery educational gathering, 2010. [In Japanese]
3. Gunji S, Ueda S, Yoshida M, Kanai M, Terajima H, Takabayashi A. Effects of rikkunshito, a kampo medicine, on quality of life after proximal gastrectomy. *J Surg Res*. 2013 Dec;185(2):575-80.
4. Endo S, Nishida T, Nishikawa K, et al. Dai-kenchu-to, a Chinese herbal medicine, improves stasis of patients with total gastrectomy and jejunal pouch interposition. *Am J Surg*. 2006 Jul;192(1):9-13.
5. Jeong JS, Ryu BH, Kim JS, Park JW, Choi WC, Yoon SW. Bojungikk-tang for cancer-related fatigue: a pilot randomized clinical trial. *Integr Cancer Ther*. 2010 Dec;9(4):331-8.
6. N.Shimoyama, K. Iijima and T. Mizuguchi. The effectiveness of JUZEN-TAIHO-TO in improving QOL of cancer patients with pain. *Biotherapy*. 1991;5(12):1857-61. [In Japanese]
7. Japanese Gastric Cancer Association. Japanese classification of gastric carcinoma: 3rd English ed. *Gastric Cancer*. 2011;14:101-112.
8. Araki A. New efficacy of old prescriptions. Vol 2. Tokyo, Japan Houjutsu-shinwa-kai; 1972. [In Japanese]
9. Otsuka K. The Commentary of SHANG HAN LUN (the great classic of Chinese medicine). Long Beach, CA: Oriental Healing Arts Institute; 1981.
10. Aoyama T, Yoshikawa T, Shirai J, et al. Comparison of body weight loss in gastrectomy patients who underwent only surgery and those who underwent surgery followed up with S-1 adjuvant chemotherapy. *Japan J Cancer Chemotherapy*. 2012;39(12):1794-96. [In Japanese]
11. Takachi K, Doki Y, Ishikawa O, et al. Postoperative ghrelin levels and delayed recovery from body weight loss after distal or total gastrectomy. *J Surg Res*. 2006;130(1):1-7.