

Metastatic carcinoma of unknown primary with complete metabolic response following sorafenib-based chemotherapy

SAGE Open Medical Case Reports
Volume 7: 1–4
© The Author(s) 2019
Article reuse guidelines:
sagepub.com/journals-permissions
DOI: 10.1177/2050313X19838739
journals.sagepub.com/home/sco



Pedro Luiz Serrano Usón Junior¹ , Jairo Wagner², Marcus Vinicius de Nigro Corpa³, Iracema Moraes Coelho¹, Robert A Nagourney⁴ and Nise Hitomi Yamaguchi¹

Abstract

Background: The treatment of carcinoma of unknown primary based on histopathology and immunohistochemistry is generally chemotherapy. The use of molecular markers, genetic profiling platforms, and personalized medicine is under active investigation.

Case Report: We report the case of a 56-year-old patient who presented to medical attention with palpable axillary adenopathy. Biopsy confirmed poorly differentiated adenocarcinoma. Formal staging revealed extensive metastatic disease to bone and liver. Initial chemotherapy proved ineffective. We describe the diagnostic evaluation, treatment, and achievement of durable remission using a novel sorafenib-based drug combination that was chosen through the application of a functional analytic laboratory platform.

Conclusion: The clinical management of patients with carcinoma of unknown primary continues to present a considerable challenge for practicing oncologists. Laboratory platforms capable of examining cellular response to injury, growth factor withdrawal, and cytotoxic insult at the level of cellular function may provide insights for drug selection in this patient population.

Keywords

Carcinoma of unknown primary, sorafenib, ferroptosis

Date received: 27 November 2017; accepted: 27 February 2019

Introduction

Carcinomas of unknown primary (CUPs) represent an uncommon cancer diagnosis defined by the US National Cancer Institute¹ as “... a rare disease in which malignant (cancer) cells are found in the body but the place the cancer began is not known.”

We report the case of a 56-year-old female who presented to medical attention with palpable axillary adenopathy. Biopsy confirmed a poorly differentiated adenocarcinoma. We describe the diagnostic evaluation, treatment, and durable clinical response of this patient through the use of laboratory-guided therapy.

Case

A 56-year-old female patient presented to her gynecologist in February 2013 with a palpable lymph node in the right axilla. Bilateral mammograms and blood tumor markers

were obtained. Mammograms identified bilateral lymphadenopathy. With the exception of an elevated carbohydrate antigen CA19-9, all other tumor markers were normal. Magnetic resonance imaging (MRI) of the abdomen and computed tomography (CT) confirmed bilateral axillary nodes, multiple liver lesions, retroperitoneal lymph, and multiple

¹Department of Oncology, Hospital Israelita Albert Einstein, São Paulo, Brazil

²Department of Nuclear Medicine, Hospital Israelita Albert Einstein, São Paulo, Brazil

³Department of Pathology, Hospital Israelita Albert Einstein, São Paulo, Brazil

⁴Department of Obstetrics and Gynecology, Division of Gynecologic Oncology, University of California, Irvine, Irvine, CA, USA

Corresponding Author:

Pedro Luiz Serrano Usón Junior, Department of Oncology, Hospital Israelita Albert Einstein, Av. Albert Einstein, 627/701 Morumbi, São Paulo 05651-901, Brazil.

Email: pedroluiz_uson@hotmail.com



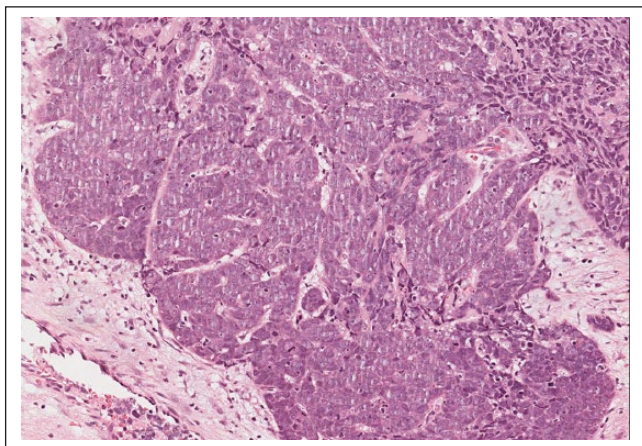


Figure 1. Histopathology of the axillary nodule. Poorly differentiated invasive carcinoma, with intense nuclear pleomorphism and high mitotic activity.

bone lesions. Upper gastrointestinal endoscopy and colonoscopy were negative.

A Positron Emission Tomography Scan (PET-CT) obtained revealed neoplastic disease with high metabolic activity in cervical lymph nodes as well as in mediastinal, mesenteric, and retroperitoneal areas. The lesions in the liver were also identified. High metabolic uptake was also observed in sclerotic bone lesions in the thoracolumbar spine. Brain MRI was negative for central nervous system lesions (Supplemental Appendix 1).

Histopathology of the axillary and liver nodule confirmed poorly differentiated invasive carcinoma (Figure 1). Immunohistochemistry was negative for estrogen and progesterone receptors, Human Epidermal Growth Factor Receptor 2, chromogranin, and synaptophysin, and positive for p63, pan-cytokeratin, and CD56.

Capecitabine 3000 mg daily in divided oral dose was initiated. An additional expanded immunohistochemical (IHC) profile was negative for smooth muscle actin, GCDFP15, epithelial antigen, CD45, COX-2, Platelet-derived growth factor receptor, somatostatin, C-kit, Fibroblast Growth Factor-basic, vascular endothelial growth factor, vascular endothelial growth factor receptor (VEGFR), and CD-20, and positive for vimentin, CD117, p21, Ras, B cell lymphoma 2, Excision Repair Cross-Complementation Group 1, and weak expression of peroxisome proliferator-activated receptor-gamma.

A portion of the tumor was submitted for Ex Vivo Analysis of Programmed Cell Death (EVA/PCD). The techniques have been the subject of prior review.^{2,3} This analysis revealed activity for paclitaxel and vinorelbine, with intermediate activity for fluoropyrimidines, carboplatin, irinotecan, and gemcitabine. A strong cytotoxic signal was observed for sorafenib. Despite the high degree of activity for sorafenib, erlotinib, pazopanib, and imatinib revealed no activity.

Following four cycles of oral capecitabine, the patient, who had previously been asymptomatic, now presented with paresis and spasms in the right lower limb. MRI of the

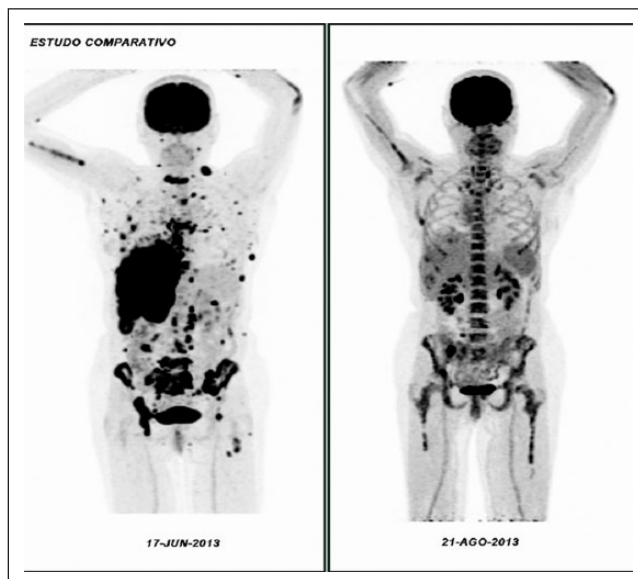

Figure 2. PET-CT, June and August 2013. Important metabolic response within 3 months of cancer treatment.

cervical spine confirmed bony destruction of the entire C7 vertebral body causing dural compression. Radiotherapy was immediately initiated. Then, a new PET-CT in June 2013 revealed massive disease progression (Supplemental Appendix 2). Based upon the results of the ex vivo analysis, we initiated a treatment regimen consisting of oral sorafenib at 200 mg bid, combined with Vinorelbine at 25 mg/m² and Paclitaxel at 80 mg/m², both given weekly.

After 2 months of treatment, PET-CT obtained on 21 August 2013 confirmed significant reduction in the size and metabolic activity of the lesions in the liver as well as in the cervical, supraclavicular, axillary, retroperitoneal, and mediastinal lymph nodes. In addition, the multiple subcutaneous, peritoneal, pleural, and pulmonary nodules as well as the pleural effusion had all disappeared. The bone lesions had also decreased revealing absence of metabolic activity (Figure 2).

The patient remained on the sorafenib/vinorelbine/paclitaxel regimen for over 1 year with continued response and good tolerance. After 1 year of treatment, PET-CT obtained on August 2014 evidences multiple new hepatic lesions. Based on ex vivo analysis, we initiated treatment with carboplatin area under curve 2 and irinotecan 80 mg/m² weekly. Scheme maintained until December 2014, when control PET-CT showed progression of liver lesions besides the appearance of pulmonary nodules. Then we initiated new treatment with gemcitabine (800 mg/m²) 2 weeks in a row every 3 weeks. Despite of treatment, in March 2015, new hepatic lesions are evidenced in PET-CT. We started (fluorouracil, 2400 mg/m²; leucovorin, 400 mg/m²; and oxaliplatin, 85 mg/m² q2w (FOLFOX regimen). After a further progression in July 2015 (Supplemental Appendix 3), the patient died in August 2015.

Discussion

The incidence of CUP ranges from 3% to 5% in demographic surveys, with the majority of the cases having a poor prognosis. The published literature has shown an average survival of 7 to 9 months in cases of metastatic CUP disease.^{4,5}

In the 1970s, the diagnosis of CUP could often only be confirmed at the time of autopsy.⁶ Nowadays, this diagnosis is only entertained if no primary is identified following full clinical examination, including both pelvic and rectal, complete blood counts, biochemical tests, immunohistochemistry, and body imaging by CT and MRI.^{4,7} The use of PET-CT is not formally recommended, although some studies support its use.⁸

It is hypothesized that CUP tumors develop the capacity to invade vascular and lymphatic channels and to generate tumor metastases before the primary lesion has grown to a dimension adequate to permit its identification. The typical spectrum observed is early dissemination in asymptomatic patients, often with the clinical absence of constitutional symptoms of the primary tumor. Patterns of early dissemination have been reported in previous studies.^{9,10}

The treatment indicated by consensus is chemotherapy based on histology, determined by histopathology and immunohistochemistry. The use of molecular markers, genetic profiling platforms, and personalized medicine is under active investigation.^{5,11,12}

Immunohistochemistry can be extremely useful in the diagnosis but often fail to elucidate the primary. Molecular analyses designed to select treatments based upon genomic profiles are under investigation. Due to different tumor susceptibility profiles, many experts believe that conventional empirical chemotherapy should only be used in cases when there are no tumor samples available.^{12,13}

When the patient progressed following chemotherapy, she received radiation to control symptomatic disease. The subsequent choice of treatment was based upon the results of the EVA/PCD functional analysis that identified activity for sorafenib. The activity, however, was unique to sorafenib, as the related pazopanib as well as imatinib and erlotinib revealed no activity.

Sorafenib is a diaryl ether, tyrosine kinase inhibitor active against Raf, PDGFb, VEGFR-2,3, and c-KIT with cross-reactivity with fms like tyrosine kinase 3 and RET that is approved in the United States for the treatment of renal cell, hepatocellular, and thyroid cancer. What distinguishes Sorafenib from all of the other drugs evaluated against the patient's tumor is its unique capacity to induce ferroptosis. Ferroptosis, originally described by Dixon et al.,¹⁴ is a form of non-apoptotic programmed cell death associated with the inhibition of System Xc, a cell surface Na⁺-independent cysteine–glutamate antiporter. Structure activity analyses have subsequently identified sorafenib as a potent inhibitor of Xc, capable of inducing ferroptotic cell death.¹⁵

The subsequent clinical benefit following treatment with this agent associated with chemotherapy could support a role

of ferroptosis in this patient's clinical response. At the time of this writing, there are no molecular signatures for ferroptosis rendering interrogation of tissue blocks impossible. The role of functional analyses, like the EVA/PCD assay, for the selection of chemotherapy drugs and combinations are under investigation.¹⁶

Conclusion

Cases of CUP continue to present considerable clinical challenges for practicing oncologists. This patient's outcome represents an excellent response to a novel treatment regimen that was chosen based upon the patient's own unique drug sensitivity profile. There is an urgent need to develop more targeted and personalized approaches for patients with complicated cases of CUP.

Declaration of conflicting interests

The author(s) declared no potential conflicts of interest with respect to the research, authorship, and/or publication of this article.

Funding

The author(s) received no financial support for the research, authorship, and/or publication of this article.

Informed consent

Consent of the patient's relatives was obtained as legal representatives for the publication of this case report.

Supplemental material

Supplemental material for this article is available online.

ORCID iD

Pedro Luiz Serrano Usón Junior  <https://orcid.org/0000-0001-6122-1374>

References

1. National Cancer Institute. Carcinoma of unknown primary, www.cancer.gov (2017, accessed 9 August 2017).
2. Nagourney RA. Ex vivo programmed cell death and the prediction of response to chemotherapy. *Curr Treat Options Oncol* 2006; 7(2): 103–110.
3. Friedman AA, Letai A, Fisher DE, et al. Precision medicine for cancer with next-generation functional diagnostics. *Nat Rev Cancer* 2015; 15(12): 747–756.
4. Pavlidis N, Briasoulis E, Hainsworth J, et al. Diagnostic and therapeutic management of cancer of an unknown primary. *Eur J Cancer* 2013; 39(14): 1990–2005.
5. Ettinger DS, Handorf CR, Agulnik M, et al. Occult primary, version 3.2014. *J Natl Compr Canc Netw* 2014; 12(7): 969–974.
6. Frost P, Raber MN and Abbruzzese JL. Unknown primary tumors as a unique clinical and biologic entity a hypothesis. *Cancer Bull* 1989; 41(3): 139–141.
7. Schneider JA and Adler DG. Metastatic cancers of unknown primary site. *Hosp Phys* 2005; 33–40, <https://pdfs.semanticscholar.org/93a0/64d70b016e78254d5a2639c3317e0514b671.pdf>

8. Joshi U, van der Hoeven JJ, Comans EF, et al. In search of an unknown primary tumour presenting with extracervical metastases: the diagnostic performance of FDG-PET. *Br J Radiol* 2004; 77(924): 1000–1006.
9. Nystrom JS, Weiner JM, Heffelfinger-Juttner J, et al. Metastatic and histologic presentations in unknown primary cancer. *Semin Oncol* 1977; 4(1): 53–58.
10. Evangelos B and Pavlidis N. Cancer of unknown primary origin. *Oncologist* 1997; 2(3): 142–152.
11. Handorf CR. Gene expression analysis and immunohistochemistry in evaluation of cancer of unknown primary: time for a patient-centered approach. *J Natl Compr Canc Netw* 2011; 9(12): 1415–1420.
12. Greco FA and Hainsworth JD. Novel diagnostic and therapeutic strategies in the management of patients with cancers of unknown primary site. In: Krämer A and Löffler H (eds) *Cancer of unknown primary*. Cham: Springer, 2016, pp. 173–190.
13. Greco FA. Molecular diagnosis of the tissue of origin in cancer of unknown primary site: useful in patient management. *Curr Treat Options Oncol* 2013; 14(4): 634–642.
14. Dixon SJ, Lemberg KM, Lamprecht MR, et al. Ferroptosis: an iron-dependent form of nonapoptotic cell death. *Cell* 2012; 149(5): 1060–1072.
15. Dixon SJ, Patel DN, Welsch M, et al. Pharmacological inhibition of cystine-glutamate exchange induces endoplasmic reticulum stress and ferroptosis. *Elife* 2014; 3: e02523.
16. Moffat JG, Rudolph J and Bailey D. Phenotypic screening in cancer drug discovery—past, present and future. *Nat Rev Drug Discov* 2014; 13(8): 588–602.