



# Allergic reactions to local anesthetic mepivacaine in dental procedures: a case report

Yoonhyoung Nam, Seyeon Min, Wonse Park, Kee-Deog Kim

Department of Advanced General Dentistry, College of Dentistry, Yonsei University, Seoul, Korea

Local anesthetics are an essential part of pain control during dental treatment. Despite its effectiveness and safety, patients should constantly be aware of potential adverse effects, including allergic reactions. Allergic reactions to amide-type local anesthetics (LAs), such as lidocaine and mepivacaine, are rare compared to those to ester-type LAs. Herein, we report the case of a patient with a history of allergy to lidocaine and mepivacaine, with symptoms of itching, diffuse erythema of the wrists and hands, dizziness, and pectoralgia. This case report emphasizes the importance of collecting medical and dental histories of patients is necessary, and how an allergy test in the allergy and clinical immunology department helps select safe LAs for patients.

**Keywords:** Adverse Effects; Allergic Reactions; Lidocaine; Local Anesthetics; Mepivacaine.



This is an Open Access article distributed under the terms of the Creative Commons Attribution Non-Commercial License (<http://creativecommons.org/licenses/by-nc/4.0/>) which permits unrestricted non-commercial use, distribution, and reproduction in any medium, provided the original work is properly cited.



## INTRODUCTION

Pain control is an essential component of all dental procedures. Local anesthesia is unavoidable and compelling and is regarded as a safe, invasive procedure. However, local anesthetics (LAs) might have adverse effects, such as allergic reactions. Therefore, a deeper understanding of LA is required by dental clinicians for successful pain management and emergency control.

LAs are generally classified into two major types: esters and amides. Ester-type LAs, such as benzocaine, procaine, tetracaine, and amilocaine, are metabolized by plasma cholinesterase, whereas amide-type LAs, including lidocaine, mepivacaine, bupivacaine, and prilocaine, are broken down in the liver [1]. Most allergic reactions have been reported for ester-type LA. A known allergen is para-aminobenzoic acid (PABA), which is

released after the hydrolysis of ester-type LAs by cholinesterases [2].

Mepivacaine is an amide-type LA that differs from lidocaine. It has a quick onset time (maxillary infiltration anesthesia: 2–3 min; inferior alveolar nerve block anesthesia: 5–8 min) and a moderate duration of action. When mepivacaine is administered in an acidic environment, such as during inflammation, the base form predominates and quickly passes through the nerve membrane, increasing the local anesthetic effect due to a higher pH than that of lidocaine. Also, mepivacaine is known as one of the less sensitizing anesthetics. Therefore, mepivacaine may be a useful LA [3]. Allergic reactions to amide-type LAs, including mepivacaine, are rare but do occasionally occur [4].

Herein, we report a case of an allergic reaction to mepivacaine in a 57-year-old woman who had a tooth extracted under local anesthesia and managed at Yonsei

Received: February 5, 2023 • Revised: April 21, 2023 • Accepted: May 22, 2023

Corresponding Author: Kee Deog Kim, Department of Advanced General Dentistry, College of Dentistry, Yonsei University, 50-1, Yonsei-ro, Seodaemun-gu, Seoul, 03722, Republic of Korea

Tel: +82-2-2228-8980 Fax: +82-2-2227-8906 E-mail: [kdkim@yuhs.ac](mailto:kdkim@yuhs.ac)

Copyright© 2023 Journal of Dental Anesthesia and Pain Medicine

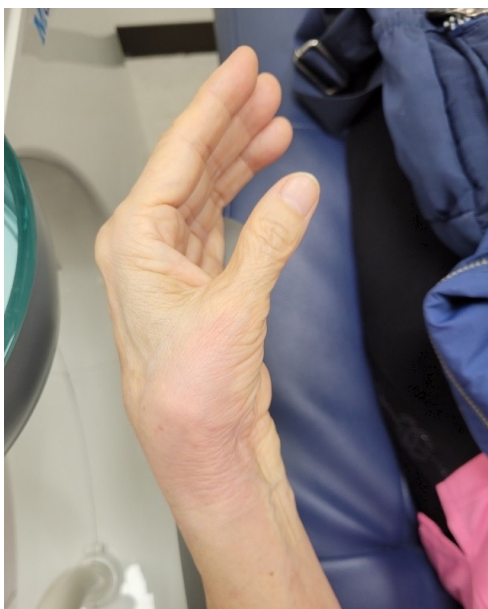

Fig. 1. Diffuse erythema and mild swelling on the left wrist and hand

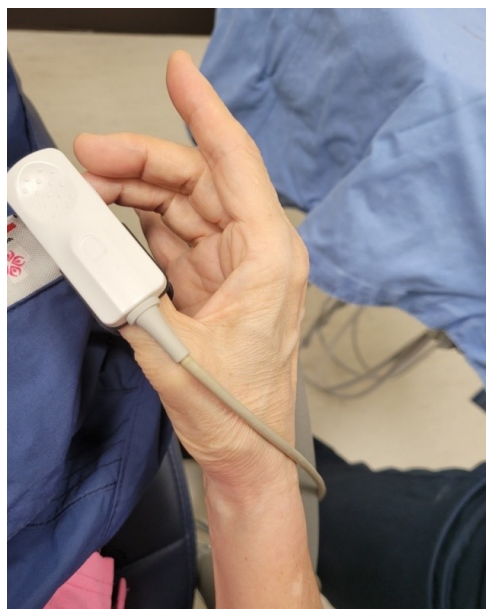


Fig. 2. Diffuse erythema on the right wrist and hand wearing a pulse oximeter

University Dental Hospital.

## CASE REPORT

A 57-year-old woman with osteoporosis, rheumatoid arthritis, hepatitis B, and arrhythmia visited the Advanced General Dentistry Department of the Yonsei University Dental Hospital for tooth extraction. She had a history of lidocaine allergies. When she underwent knee resection surgery under local anesthesia 17 years prior, she was presented with a full-body rash and respiratory distress, raising suspicion that she could be allergic to lidocaine. Subsequently, allergies also appeared whenever she used lidocaine ointment on her skin or in her throat when she gargled with it.

At that time, tooth extraction at the Advanced General Dentistry Department used the administration of lidocaine, mepivacaine, and articaine under local anesthesia. Except for lidocaine, to which the patient is allergic, we considered applying one of the two LAs, mepivacaine or articaine.

Allergy testing in the Department of Allergy at Severance Hospital took several months owing to the

large number of patients, and the situation was similar in other hospitals. However, there was no time to wait because of the severe inflammation and infection and the intolerable pain, which was not controlled by medication, the patient's tooth needed immediate extraction. In spite of the possibility of an allergic reaction, we decided that it would be more beneficial for the patient to relieve pain by having the tooth extracted rather than waiting for an allergy test.

We chose mepivacaine, which has a higher pH than lidocaine, which increases the effect of the drug on inflammation while reducing toxicity [3].

Therefore, 3.6 ml of mepivacaine (Scandonest 3%, Septogon, France; 54 mg in 1.8 ml) without a vasoconstrictor was injected into the buccal and lingual sides of the gingiva with needle aspiration before the extraction procedure. She developed continuous itching, diffuse erythema of the wrists and hands, dizziness, and pectoralgia during the tooth extraction procedure (Figs. 1 and 2). The moment she exhibited these symptoms, we checked her vital signs while she was resting in the supine position (Blood pressure 159/89, SpO<sub>2</sub> 89, pulse rate 74). Forty minutes after the administration of local

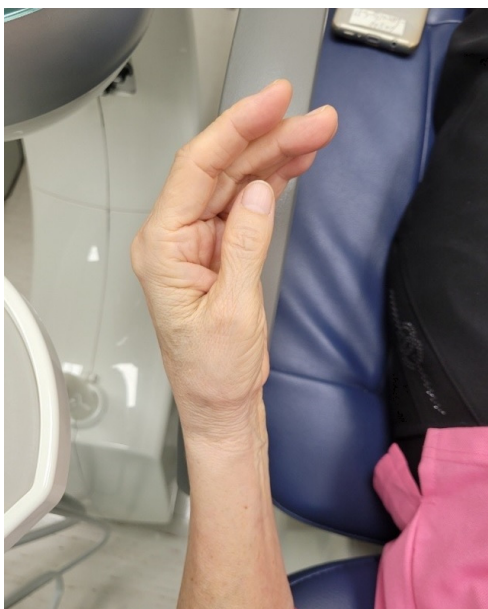

Fig. 3. Alleviated erythema on the left wrist and hand after intravenous injection of anti-histamine.

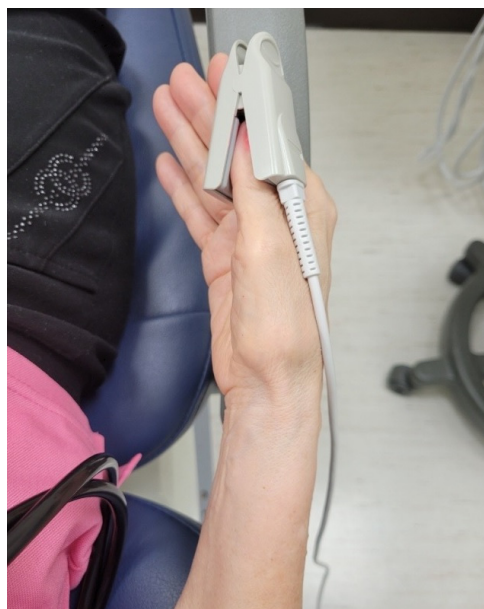

Fig. 4. Alleviated erythema on the right wrist and hand after intravenous injection of anti-histamine.

anesthesia, we hospitalized her in a daily care center and administered an intravenous injection of anti-histamine (Peniramin 4 mg) to alleviate her symptoms (Blood pressure 141/71, SpO<sub>2</sub> 95, pulse rate 72). One hour after local anesthesia, the patient gradually recovered to a normal state (Blood pressure 139/74, SpO<sub>2</sub> 100, pulse rate 70) (Figs. 3 and 4). Continuous monitoring of all vital signs was performed for an hour, and no signs of allergic reactions were noted. After confirming the patient's vital signs were normal and no typical allergic symptoms existed, the patient was discharged. She was instructed to report any discomfort or allergy symptoms to the emergency department. The following day, her symptoms, such as dizziness and itching, disappeared, except for pectoralgia.

She was referred to the Department of Allergy due to an imminent implant surgery. Through a challenge test, the allergist confirmed that articaine is suitable for dental surgeries. She underwent provocation testing with subcutaneous injections of 0.01, 0.1, 0.5, and 1.0 ml of diluted articaine solution. Articaine is recommended for her as a safe alternative to local anesthesia prior to future dental surgeries.

## DISCUSSION

Allergic reactions to local anesthetics are rare and account for 1% of all dental treatments, including oral and maxillofacial surgeries [5]. Because of their low molecular weight, it is assumed that hapten-carrier complexes cause allergic reactions rather than the local anesthetics themselves [6]. Allergic reactions, or hypersensitivity reactions, are classified into 4 categories: immediate (types I, II, and III) or delayed (type IV) [7]. Most types of allergic reactions detected by clinicians are type I. Type I is related to allergen-specific IgE bound to particular high-affinity receptors on mast cells and basophils. If an allergen cross-links to these receptors, mediators (e.g., histamine) are released, which can cause angioedema, urticaria, and/or anaphylaxis [8]. Symptoms and signs of the allergic reaction can appear in the respiratory system (wheezing, coughing, dyspnea, and laryngeal edema), cardiovascular system (tachycardia, palpitations, hypotension, unconsciousness, and cardiac arrest), skin (pruritus, urticaria, and erythema), and gastrointestinal tract (nausea, vomiting, muscle spasm,

and incontinence) [4].

The severity of allergic reactions determines the treatment. Mild allergic reactions can be managed with oral and intramuscular antihistamine agents, such as diphenhydramine. However, if patients are in critical conditions, immediate treatments should be provided, including intramuscular or subcutaneous epinephrine 0.3–0.5 mg injection, basic life support, and transfer to the emergency room in general hospitals [9]. The case we reported was relatively mild, the patient's vital signs were within the normal range, and the patient's symptoms could be rescued with an injection of intravenous antihistamine (4 mg).

Mepivacaine is similar to lidocaine in terms of low toxicity and intermediate duration of action [10]. The cross-reactivity among amide-type LAs was almost comparable between lidocaine and mepivacaine. Lidocaine and mepivacaine should not be used as substitutes in patients with allergy to either substance because of possible cross-allergenicity [11]. No cross-allergenicity to articaine was observed in either study. Articaine differs from other amide-type LAs containing a phenyl-methylated ring in that it has a thiophene ring. Based on this fact, articaine may be the best option; however, a challenge test is still recommended [12]. Articaine may exhibit infrequent cross-allergenicity with other amide-type LAs, including delayed-type reactions [13,14].

Consistent with previously published studies, in this case report, the patient was allergic to lidocaine and mepivacaine, and articaine is advisable for future local anesthesia based on the articaine challenge test, which produced a negative result.

In conclusion, clinicians should consider the patients' history related to allergic reactions, such as the name of the medicine, how to administer the medicine, symptoms, alternative medicine used, and medical and dental histories, such as systemic diseases and abnormal reactions during dental treatment, in order to prepare for a serious allergic reaction to LAs or any drug. Allergy tests in the Department of Allergy and Clinical

Immunology may help select safe LAs or medicines to avoid adverse effects. Furthermore, if a patient has allergic reactions to either lidocaine or mepivacaine, clinicians should consider using alternative LAs, such as articaine, instead of either of the above. Whenever dental clinicians anesthetize patients for routine treatment, awareness of the adverse effects of LA, especially allergic reactions, is an indispensable part of LA use.

#### AUTHOR ORCIDs

**Yoonhyoung Nam:** <https://orcid.org/0000-0003-1104-9371>

**Seyeon Min:** <https://orcid.org/0000-0001-5342-6038>

**Wonse Park:** <https://orcid.org/0000-0002-2081-1156>

**Kee Deog Kim:** <https://orcid.org/0000-0003-3055-5130>

#### AUTHOR CONTRIBUTIONS

**Yoonhyoung Nam:** Conceptualization, Data curation, Formal analysis, Investigation, Resources, Writing - original draft, Writing - review & editing

**Seyeon Min:** Data curation, Investigation, Resources, Writing - review & editing

**Wonse Park:** Conceptualization, Data curation, Supervision, Writing - review & editing

**Kee Deog Kim:** Conceptualization, Data curation, Supervision, Writing - review & editing

**CONSENT:** This case report was submitted after receiving approval from the Yonsei University Health System, Severance Hospital, Institutional Review Board (2-2022-0076).

**CONFLICT OF INTEREST:** The authors have no conflicts of interest to declare.

#### REFERENCES

1. Covino BG. Physiology and pharmacology of local anesthetic agents. *Anesth Prog* 1981; 28: 98-104.
2. Petrikas AZh, Ol'khovskaia EB, Medvedev DV, Diubaïlo MV. *Stomatologiia(Mosk)* 2013; 92: 71-6.
3. Budenz AW, Dugoni AA. Injection technique and local anesthetic agent selection. *Tex Dent J* 2011; 128: 110-2.

4. Speca SJ, Boynes SG, Cuddy MA. Allergic reactions to local anesthetic formulations. *Dent Clin North Am* 2010; 54: 655-64.
5. Lee J, Lee JY, Kim HJ, Seo KS. Dental anesthesia for patients with allergic reactions to lidocaine: two case reports. *J Dent Anesth Pain Med* 2016; 16: 209-12.
6. Sharma V, Harper NJ, Garcez T, Arkwright PD. Allergic reaction to mepivacaine in a child. *Br J Anaesth* 2013; 110: 1059-60.
7. Canfield DW, Gage TW. A guideline to local anesthetic allergy testing. *Anesth Prog* 1987; 34: 157-63.
8. Dispenza MC. Classification of hypersensitivity reactions. *Allergy Asthma Proc* 2019; 40: 470-3.
9. Finder RL, Moore PA. Adverse drug reactions to local anesthesia. *Dent Clin North Am* 2002; 46: 747-57.
10. Kaufman E, Jastak JT. Sedation for outpatient dental procedures. *Compend Contin Educ Dent* 1995; 16: 462, 464, 466 passim; quiz 480.
11. Fuzier R, Lapeyre-Mestre M, Mertes PM, Nicolas JF, Benoit Y, Didier A, et al. Immediate- and delayed-type allergic reactions to amide local anesthetics: clinical features and skin testing. *Pharmacoepidemiol Drug Saf* 2009; 18: 595-601.
12. El-Qutob D, Morales C, Peláez A. Allergic reaction caused by articaine. *Allergol Immunopathol (Madr)* 2005; 33: 115-6.
13. Bircher AJ, Messmer SL, Surber C, Ruffli T. Delayed-type hypersensitivity to subcutaneous lidocaine with tolerance to articaine: confirmation by in vivo and in vitro tests. *Contact Dermatitis* 1996; 34: 387-9.
14. Duque S, Fernández L. Delayed-type hypersensitivity to amide local anesthetics. *Allergol Immunopathol(Madr)* 2004; 32: 233-4.