



Emotion detection deficits and changes in personality traits linked to loss of white matter integrity in primary progressive aphasia



Namita Multani^{a,b}, Sebastiano Galantucci^c, Stephen M. Wilson^{d,e}, Tal Shany-Ur^d, Pardis Poorzand^d, Matthew E. Growdon^d, Jung Yun Jang^f, Joel H. Kramer^d, Bruce L. Miller^d, Katherine P. Rankin^d, Maria Luisa Gorno-Tempini^d, Maria Carmela Tartaglia^{a,b,*}

^a Division of Neurology, Krembil Neuroscience Centre, Toronto Western Hospital, University Health Network, 399 Bathurst St., Toronto, ON M5T2S8, Canada

^b Tanz Centre for Research in Neurodegenerative Diseases, University of Toronto, 60 Leonard Avenue, Toronto, ON M5T2S8, Canada

^c Neuroimaging Research Unit, Institute of Experimental Neurology, Division of Neuroscience, San Raffaele Scientific Institute, Vita-Salute San Raffaele University, Via Olgettina, 58, 20132 Milan, Italy

^d Memory and Aging Center, Department of Neurology, University of California San Francisco, 1500 Owens Suite 320, San Francisco, CA 94158, USA

^e Department of Speech Language and Hearing Sciences, University of Arizona, 1131 E. 2nd Street, Tucson, AZ 85721, USA

^f Department of Psychology, University of Southern California, 3620 South McClintock Ave., Los Angeles, CA 90089, USA

ARTICLE INFO

Keywords:

Diffusion tensor imaging

Emotion detection

Personality

Primary progressive aphasia

Social cognition

ABSTRACT

Non-cognitive features including personality changes are increasingly recognized in the three PPA variants (semantic-svPPA, non fluent-nfvPPA, and logopenic-lvPPA). However, differences in emotion processing among the PPA variants and its association with white matter tracts are unknown. We compared emotion detection across the three PPA variants and healthy controls (HC), and related them to white matter tract integrity and cortical degeneration. Personality traits in the PPA group were also examined in relation to white matter tracts. Thirty-three patients with svPPA, nfvPPA, lvPPA, and 32 HC underwent neuropsychological assessment, emotion evaluation task (EET), and MRI scan. Patients' study partners were interviewed on the Clinical Dementia Rating Scale (CDR) and completed an interpersonal traits assessment, the Interpersonal Adjective Scale (IAS). Diffusion tensor imaging of uncinate fasciculus (UF), superior longitudinal fasciculus (SLF) and inferior longitudinal fasciculus (ILF), and voxel-based morphometry to derive gray matter volumes for orbitofrontal cortex (OFC), anterior temporal lobe (ATL) regions were performed. In addition, gray matter volumes of white matter tract-associated regions were also calculated: inferior frontal gyrus (IFG), posterior temporal lobe (PTL), inferior parietal lobe (IPL) and occipital lobe (OL). ANCOVA was used to compare EET performance. Partial correlation and multivariate linear regression were conducted to examine association between EET and neuroanatomical regions affected in PPA. All three variants of PPA performed significantly worse than HC on EET, and the svPPA group was least accurate at recognizing emotions. Performance on EET was related to the right UF, SLF, and ILF integrity. Regression analysis revealed EET performance primarily relates to the right UF integrity. The IAS subdomain, cold-hearted, was also associated with right UF integrity. Disease-specific emotion recognition and personality changes occur in the three PPA variants and are likely associated with disease-specific neuroanatomical changes. Loss of white matter integrity contributes as significantly as focal atrophy in behavioral changes in PPA.

1. Introduction

Primary progressive aphasia (PPA) refers to a group of neurodegenerative disorders presenting initially with isolated language impairment. Currently three clinical variants are recognized: semantic variant PPA (svPPA), non-fluent variant PPA (nfvPPA) and logopenic variant PPA (lvPPA) (Gorno-Tempini et al., 2011). Each PPA variant is

associated with deterioration of distinct language features: (i) progressive single-word comprehension deficits and anomia in svPPA; (ii) agrammatism and effortful speech in nfvPPA; (iii) profound word-finding difficulty and sentence/phrase repetition deficits in lvPPA (Gorno-Tempini et al., 2011). Moreover, emotional and personality changes can also occur in some patients. Decreased extroversion, warmth and dominance have been described in patients with svPPA,

* Corresponding author at: Memory Clinic - Toronto Western Hospital, Tanz Centre for Research in Neurodegenerative Disease, 399 Bathurst St., West Wing 5-449, Toronto, ON M5T 2S8, Canada.

E-mail address: carmela.tartaglia@uhn.ca (M.C. Tartaglia).

<http://dx.doi.org/10.1016/j.nicl.2017.08.020>

Received 24 January 2017; Received in revised form 21 August 2017; Accepted 23 August 2017

Available online 26 August 2017

2213-1582/ © 2017 The Authors. Published by Elsevier Inc. This is an open access article under the CC BY-NC-ND license (<http://creativecommons.org/licenses/by-nc-nd/4.0/>).

and agitation, depression and apathy in patients with nfvPPA (Rohrer and Warren, 2010; Sollberger et al., 2011).

The diverse linguistic profile of each PPA variant is associated with different patterns of neuroanatomical degeneration that includes both gray and white matter abnormalities. In recent years, Diffusion Tensor Imaging (DTI) studies have revealed significant white matter tract abnormalities in addition to the previously known gray matter atrophy (Galantucci et al., 2011). DTI allows in vivo evaluation of white matter integrity by examining distribution of water molecules within fiber tracts (Ciccarelli et al., 2008) and so facilitates investigation of the contribution of white matter tract deterioration to the deficits observed in PPA. SvPPA is characterized by left anterior temporal lobe (ATL) atrophy, as well as damage to the uncinate fasciculus (UF), the inferior longitudinal fasciculus (ILF), left arcuate fasciculus (AF) and left temporoparietal superior longitudinal fasciculus (SLF-tp) (Galantucci et al., 2011; Gorno-Tempini et al., 2011). Patients diagnosed with nfvPPA display left inferior frontal gyrus (IFG) atrophy and alteration of the left SLF, aslant and fronto-striatal tracts (Catani et al., 2013; Galantucci et al., 2011; Gorno-Tempini et al., 2011; Mandelli et al., 2014). These two variants of PPA are usually associated with frontotemporal lobar degeneration (FTLD) pathology, whereas, lvPPA is caused by Alzheimer disease (AD) pathology and is associated with degeneration of the left temporo-parietal region and significant involvement of left SLF-tp, AF, SLF-II, SLF-III and anterior ILF tracts (Galantucci et al., 2011; Gorno-Tempini et al., 2011). Therefore, white matter tract abnormality in conjunction with gray matter atrophy provides a distinct neuroanatomical profile that is associated with specific features in each PPA variant.

Focal frontal and temporal degeneration in the three PPA variants is associated with behavioral changes in conjunction with the language deficits (Couto et al., 2013; Kumfor et al., 2011; Mahoney et al., 2011; Piguet et al., 2015; Rohrer et al., 2012; Rohrer and Warren, 2010; Rosen et al., 2006). The temporal and frontal lobes are associated with social cognitive functions, including empathy (Kumfor and Piguet, 2012). This allows individuals to infer others' internal emotions, intentions and beliefs, and behavioral response selection (Adolphs, 2009). In svPPA, where there is usually significant change in personality and loss of social cognition, the loss of empathy is usually attributed to right temporal pole atrophy (Rankin et al., 2006) while the orbitofrontal cortex (OFC) and insular atrophy is often associated with apathy, anxiety, abnormal feeding behavior, disinhibition and irritability (Rohrer and Warren, 2010).

Emotion processing is an essential component of social cognition (Ibanez et al., 2014). Accurate recognition of expressive emotions allows effective response to social cues, prevents conflicts and strengthens interpersonal relationships. The following cortical regions are implicated in emotion perception: ventromedial prefrontal cortex, insula, ATL, OFC, right inferior temporal gyrus and right amygdala (Kumfor and Piguet, 2012; Olson et al., 2007). Certain white matter tracts, such as the UF and ILF, are also involved in emotion processing (Philippi et al., 2009; Von Der Heide et al., 2013).

Given that some of the neuroanatomical areas that sub-serve social cognition are atrophied in PPA and there is significant alteration in certain white matter tracts such as the UF and ILF that are also important during emotion processing, we hypothesized that the UF and ILF abnormality will significantly correlate with inaccurate emotion detection. Moreover, we expected the svPPA patients to perform significantly worse than the other PPA variants due to the UF and ILF tract deterioration observed in this group. The purpose of the current study was to compare emotion recognition performance in the three PPA variants and healthy controls and ascertain the relative contribution of white matter tract alterations to their performance in emotion perception. We were also interested in examining the relative contribution of gray matter and white matter abnormalities to personality traits in PPA.

2. Material and methods

2.1. Subjects

Patients diagnosed with PPA ($N = 33$) and age-matched healthy controls ($N = 32$) were recruited at the University of California, San Francisco Memory and Ageing Centre ($N = 65$) from November 2007 to October 2009. Each patient was diagnosed with one of the three PPA variants, svPPA ($N = 13$), nfvPPA ($N = 11$) and lvPPA ($N = 9$), according to the latest criteria (Gorno-Tempini et al., 2011). The UCSF Institutional Review Board approved the study. Patients with prior or current diagnosis of other neurological, psychiatric, major medical condition and substance abuse were excluded from the study. Only subjects who underwent DTI were included in the study. Each study participant underwent neuroimaging, neuropsychological and neurological examination. In addition, study partners completed several questionnaires pertaining to patients' current behavior and personality.

2.2. Neuropsychological assessment

For the purpose of this paper, only a subset of neuropsychological tests were examined. All subjects underwent the Mini Mental State Examination (MMSE) and the PPA group also completed the Western Aphasia Battery (WAB) auditory word recognition subtest. The auditory word recognition assesses individuals' ability to comprehend words. In addition, a subset of participants ($N = 42$; svPPA = 12, nfvPPA = 10, lvPPA = 9, HC = 11) completed an Emotion Evaluation Task (EET), a sub-test of The Awareness of Social Inference Test, TASIT (McDonald et al., 2003). The EET consists of short video vignettes to evaluate recognition of basic emotional expressions (McDonald et al., 2003). At the end of each video clip, the subject is required to select an emotion (from a list) which most accurately represents the emotion the actor is portraying. Study partners were interviewed to complete a Clinical Dementia Rating (CDR). The CDR is a staging scale, which is used to assess severity of dementia. It assesses impairment in six different domains (memory, orientation, judgment and problem solving, community affairs, home and hobbies, and personal care) and provides an overall global score (Morris, 1993). Lastly, a subset of study partners ($N = 21$; HC = 11 PPA = 10; svPPA = 5, nfvPPA = 4, lvPPA = 1) completed the Interpersonal Adjectives Scale (IAS), which provides a measure of the following personality traits: assured-dominant, gregarious-extraverted, warm-agreeable, unassuming-ingenuous, unassertive-submissive, aloof-introverted, aloof-introverted, cold-hearted, arrogant-calculating (Wiggins et al., 1988).

2.3. MRI acquisition

A 3T Siemens TrioTim syngo with a standard 8-channel head-coil was used to acquire T1-weighted and diffusion-weighted images. The parameters of each scan are outlined in our previous paper (Galantucci et al., 2011).

2.4. Diffusion tensor imaging analysis

The FMRIB Software Library (FSL) was used to conduct DTI analysis (<http://fsl.fmrib.ox.ac.uk/fsl/fslwiki/>). Region of interest (ROI)-based DTI analysis was performed for the following tracts: ILF, UF and SLF (Fig. 1). Various DTI metrics were generated to represent different aspects of fiber tract integrity: (i) fractional anisotropy (FA) represents movement of water diffusion along the axon; (ii) axial diffusivity (AD), which measures diffusivity of water molecules along the axon, is interpreted as a measure of axonal damage; (iii) diffusivity of water molecules perpendicular to the axon or myelin damage is represented by radial diffusivity (RD); (iv) mean diffusivity (MD) reflects average motion of water molecules in every direction (Ciccarelli et al., 2008). The preprocessing and tractography analysis are reported in our

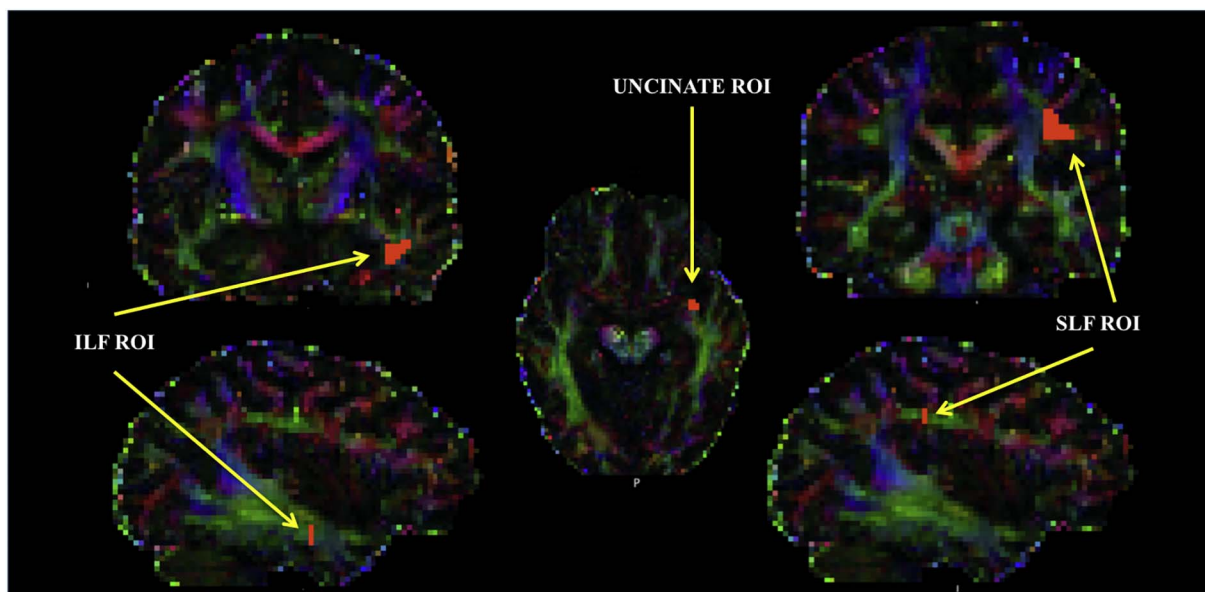


Fig. 1. Seeds used to define the uncinate fasciculus (UF), superior longitudinal fasciculus (SLF) and inferior longitudinal fasciculus (ILF) for each subject.

previous paper (Galantucci et al., 2011).

2.5. T1-Weighted images

Voxel-based morphometry (VBM) within statistical parametric mapping (SPM5) software was performed on T1 images, as described previously (Wellcome Department of Imaging Neuroscience, London, UK; <http://www.fil.ion.ucl.ac.uk/spm/software/spm5/>) (Wilson et al., 2010). The gray matter volumes of areas known for focal atrophy in the three PPA variants (ATL, IFG, posterior temporal lobe - PTL and inferior parietal lobe - IPL) and those connected by the WM tracts examined for the current study (IFG and PTL for SLF, ATL and OFC for UF (Fig. 2), ATL and occipital lobe - OL for ILF) were generated using SPM5 and Harvard-Oxford Atlas based ROIs. Total gray matter volume in each ROI was calculated for each participant, and corrected for total intracranial volume.

2.6. Statistical analysis

The SPSS 21 software was used to conduct the statistical analysis. One-way ANOVA and post-hoc analysis were carried out to examine group mean differences on age, MMSE, CDR-Sum of Boxes (CDR-SoB), EET and WAB (PPA group only). Group differences for IAS were not assessed due to small sample size. In addition, chi-square test was carried out to examine significant gender differences between the groups. The relationship between the EET (one-tailed) and personality traits (IAS T-score; two-tailed), and GM volume (see above) and WM tracts (UF, ILF and SLF) was determined by partial correlation, while controlling for age, gender, TICV and CDR-SoB. Bonferroni correction for multiple comparisons was applied.

Lastly, using the partial correlation results from our analysis, we performed a multivariate linear regression to determine the relative contribution of PPA-specific focal white matter and gray matter abnormalities to predict EET performance. A multivariate linear regression was also carried out to examine personality traits in relation to

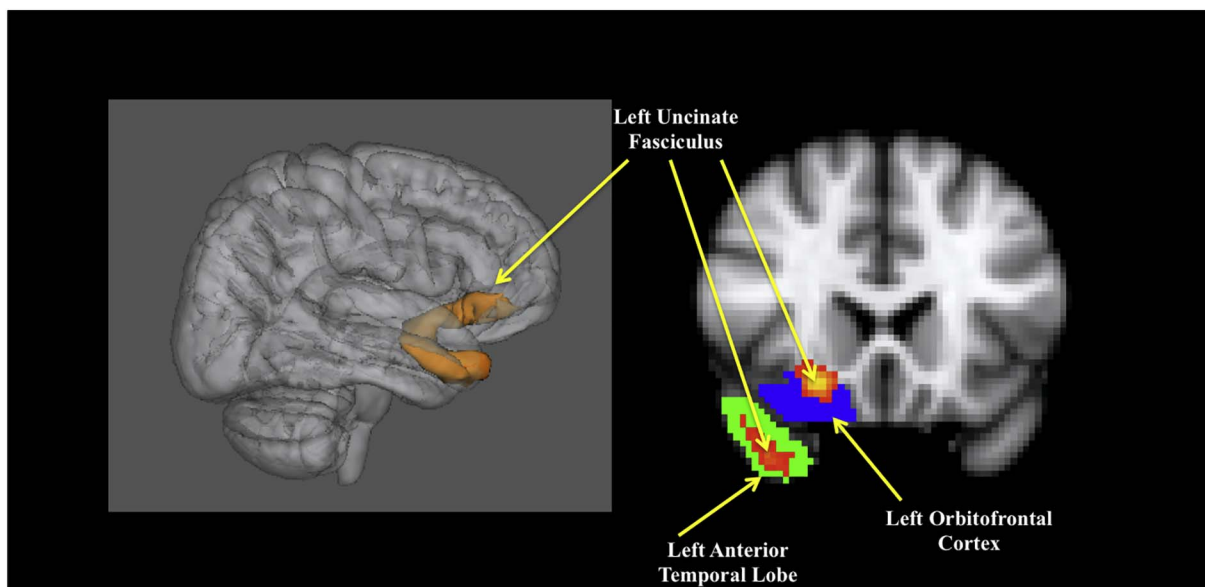


Fig. 2. 3D reconstruction of the uncinate fasciculus tract (left) and the gray matter regions associated with the tract, anterior temporal lobe and orbitofrontal cortex (right).

Table 1
Demographic and general cognitive function of patients with semantic, non-fluent and logopenic variant primary progressive aphasia and healthy individuals.

	svPPA	nfvPPA	lvPPA	HC
Age*	64.0 (7.22)	68.7 (6.79)*	61.6 (6.69)*	67.0 (4.39)
Gender (M/F)	5/8	3/8	5/4	10/22
Education	15.55 (1.635)	15.20 (3.293)	15 (3.317)	17.19 (2.221)
MMSE	21.5 (7.28)*	24.5 (4.35)*	24.0 (6.06)	29.4 (0.71)*
CDR-SoB	5.08 (2.798)*	2.86 (2.336)*	2.72 (1.787)*	0.02 (0.088)*
WAB	50.5 (8.3)	56.6 (7.5)	58.2 (3.5)	

svPPA = semantic variant primary progressive aphasia; nfvPPA = non-fluent variant primary progressive aphasia; lvPPA = logopenic variant primary progressive aphasia; HC = healthy controls.

* $p < 0.05$.

specific regions, again based on the partial correlation results.

3. Results

3.1. Demographics and language performance

General characteristics of each group are summarized in Table 1. There was a significant difference among the groups for age ($F(3,61) = 3.432, p < 0.05$), education ($F(3,56) = 3.013, p < 0.05$) MMSE ($F(3,60) = 12.426, p < 0.05$) and CDR-SoB ($F(3,61) = 30.467, p < 0.05$). A post-hoc Tukey revealed that nfvPPA were significantly older than lvPPA, $p < 0.05$. The healthy controls and svPPA did not differ significantly in age from any of the groups. Although one-way ANOVA suggested a significant difference in education among the four groups, Games Howell post hoc analysis suggested no significant difference at $p < 0.05$. A Games-Howell post-hoc indicated healthy controls performed significantly higher than nfvPPA and svPPA on the MMSE, at $p < 0.05$, however, there was no significant difference among PPA groups. The CDR-SoB score was significantly lower for healthy controls, compared to each PPA variant group. Games-Howell post hoc analysis did not suggest any significant difference between the three PPA groups on the CDR-SoB. Lastly, the three PPA groups were significantly different with respect to the WAB auditory comprehension, one-way ANOVA ($F(2,30) = 3.822, p < 0.05$), as patients with lvPPA performed significantly higher than the svPPA group on the WAB.

3.2. Emotion detection

All four groups demonstrated significant difference on EET performance, as determined by one-way ANOVA ($F(3,38) = 15.379, p < 0.001$) (Fig. 3). Post-hoc Games-Howell test indicated that HC ($M = 12.82, SD = 0.874$) scored significantly greater than the lvPPA group 10.67 ± 1.3 , nfvPPA (8.80 ± 3.1) and svPPA (6.83 ± 2.6). In addition, the lvPPA group significantly outperformed the svPPA group, with a mean difference of 3.833 ± 0.97 ($p = 0.002$). Since there was a significant difference on the WAB auditory single-word comprehension between the PPA groups, we conducted one-way ANCOVA to ensure comprehension deficits (WAB) did not contribute to EET group differences. There was still a significant effect of PPA group on EET performance after controlling for auditory comprehension, $F(2,27) = 3.930, p < 0.05$. As demonstrated above, the lvPPA group performed significantly better than the svPPA group, $p < 0.05$. Patients with nfvPPA did not differ significantly from the other two PPA groups.

3.3. Emotion detection and brain correlates

There was a correlation between the following GM regions and EET score at $p < 0.05$: left OFC ($r = 0.32, p = 0.025$), right OFC ($r = 0.39,$

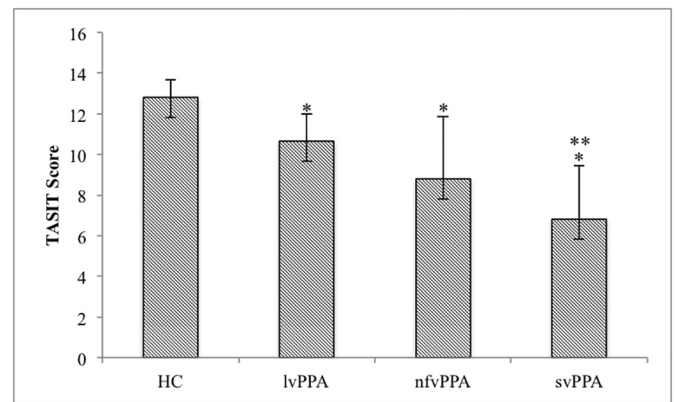


Fig. 3. Mean group differences on emotion evaluation task (EET).

*Performed significantly lower than healthy controls.

**Performed significantly lower than lvPPA.

$p = 0.008$), right OL ($r = -0.29, p = 0.04$), left ATL ($r = 0.34, p = 0.02$), right ATL ($r = 0.35, p = 0.017$). However, these did not withstand correction for multiple comparisons. EET performance was significantly associated with the FA of WM tracts; the right ILF, right UF ($r = 0.50, p = 0.001$), left UF ($r = 0.34, p = 0.019$), right SLF ($r = 0.40, p = 0.007$), and left SLF ($r = 0.30, p = 0.034$). However, only the right ILF, UF and SLF survived the multiple comparison correction (Fig. 4).

Since comprehension would affect EET independently of emotion detection ability, we repeated the partial correlation for EET including comprehension as a covariate. A subset of WM tracts were associated with EET performance when the three PPA groups were examined while controlling for comprehension, CDR-SoB, age, gender and TICV; only the right ILF FA ($r = 0.49, p = 0.005$, the right UF FA ($r = 0.62, p < 0.001$).

3.4. Personality and brain correlates

The association between the IAS subdomains and GM regions and WM tracts are reported in Tables 2 and 3, respectively. The IAS-DE (cold-hearted subdomain) was significantly negatively correlated with the following GM regions: bilateral OFC, bilateral ATL and right PTL (Table 2). The FA values of right ILF, right UF and right SLF were also significantly negatively associated with the cold-hearted subdomain (Table 3). The IAS-FG (aloof-introverted subdomain) significantly negatively correlated with the right OFC, right ATL and the right PTL GM regions (Table 2). In addition, the right ILF and right UF white matter tracts' FA were significantly associated with the IAS-FG (aloof-introverted subdomain) (Table 3). The IAS-HI (unassured-submissive) was only significantly negatively associated with the right UF (Table 3). The IAS-JK trait (unassuming-ingenuous) was significantly negatively correlated with the FA of the right ILF and left UF (Table 3). The IAS-LM trait (warm-agreeable) significantly positively correlated with the following GM regions: right OFC, right ATL and right PTL (Table 2), and FA of WM tracts: right ILF and right UF (Table 3). Lastly, the IAS-NO (gregarious-extraverted) significantly correlated with the right PTL (Table 2). However, when applying Bonferroni adjustment, only the IAS-DE (cold-hearted) withstood corrections for multiple comparisons (corrected $p = 0.001$) with the right UF FA (Fig. 5).

3.5. Regression analysis

A regression analysis was carried out to predict EET performance based on the most significantly associated white matter tract (right UF FA) and its associated GM regions (right OFC and ATL), as well as CDR-SoB, age, gender and TICV. The regression model with all seven predictor variables was significant, with $R^2 = 0.46$ and $F(7,34) = 4.143,$

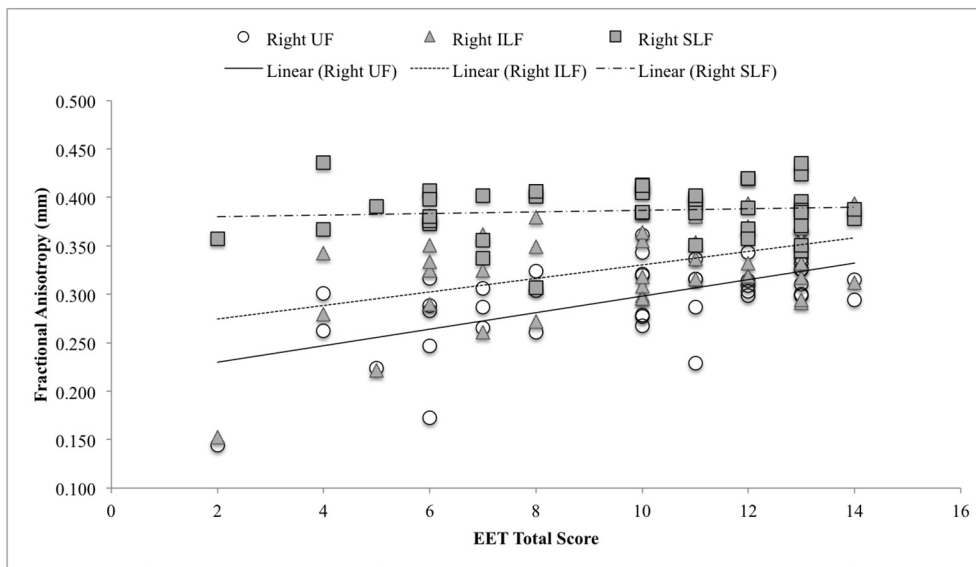


Fig. 4. Correlation between the emotion evaluation task (EET) and the right uncinate fasciculus (circular markers), inferior longitudinal fasciculus (triangle markers) and superior longitudinal fasciculus (square markers) fractional anisotropy. The solid line represents the linear trendline associated with the right UF and EET. The dotted line represents the linear trendline associated with the right ILF and EET. The dashed line represents linear trendline associated with the right SLF and EET.

$p < 0.05$. However, the analysis indicates that only the right UF FA significantly predicts EET performance ($Beta = 0.479$, $t(41) = 0.981$, $p < 0.05$).

A regression analysis was also conducted to examine the cold-hearted trait in relation to the right UF FA, OFC, ATL, CDR-SoB, age, gender and TICV. The regression model with all seven predictor variables was significant, with $R^2 = 0.70$ and $F(7,13) = 4.23$, $p < 0.05$.

However, only the right UF FA significantly predicted cold-hearted trait ($Beta = -0.629$, $t(20) = -2.226$, $p < 0.05$).

4. Discussion

To our knowledge, this is the first study to examine emotion processing in the three PPA variants and its association with changes in

Table 2
Partial correlation between Interpersonal Adjective Scale T-scores and gray matter volumes.

	Assured-dominant		Arrogant-calculating		Cold-hearted		Aloof-introverted	
	r	p	r	p	r	p	r	p
R-OFC	0.11	0.668	-0.07	0.789	-0.73*	0.001	-0.54*	0.025
L-OFC	0.03	0.919	-0.18	0.497	-0.51*	0.035	-0.2	0.445
R-ATL	0.06	0.83	0.04	0.873	-0.69*	0.002	-0.52*	0.031
L-ATL	0.08	0.748	-0.1	0.698	-0.52*	0.034	-0.23	0.366
R-IFG	-0.25	0.331	0.24	0.363	-0.02	0.937	-0.09	0.731
L-IFG	-0.15	0.568	0.15	0.559	0.26	0.32	0.15	0.56
R-IPL	0.07	0.779	-0.25	0.34	-0.27	0.296	0.31	0.219
L-IPL	0.12	0.648	0.19	0.463	-0.1	0.69	-0.22	0.388
R-PTL	0.06	0.823	-0.02	0.937	-0.63*	0.006	-0.59*	0.013
L-PTL	0.02	0.942	0.04	0.891	-0.28	0.283	-0.13	0.422
R-OL	-0.11	0.677	0.13	0.624	-0.37	0.144	-0.21	0.422
L-OL	-0.17	0.509	0.09	0.744	0.03	0.911	0.02	0.941

	Unassured-submissive		Unassuming-ingenuous		Warm-agreeable		Gregarious-extraverted	
	r	p	r	p	r	p	r	p
R-OFC	-0.41	0.106	-0.28	0.278	0.62*	0.009	0.45	0.073
L-OFC	-0.1	0.690	-0.1	0.695	0.39	0.124	0.15	0.564
R-ATL	-0.33	0.196	-0.23	0.386	0.63*	0.007	0.4	0.11
L-ATL	-0.11	0.671	-0.12	0.635	0.38	0.137	0.21	0.427
R-IFG	0.07	0.803	-0.12	0.64	0.2	0.447	0.08	0.755
L-IFG	0.16	0.549	-0.03	0.921	-0.29	0.261	-0.02	0.944
R-IPL	-0.19	0.478	0.22	0.388	0.44	0.081	0.38	0.135
L-IPL	-0.08	0.756	0.11	0.687	0.21	0.417	0.27	0.297
R-PTL	-0.39	0.126	-0.12	0.65	0.69*	0.002	0.52*	0.034
L-PTL	-0.01	0.97	0	0.996	0.23	0.374	0.21	0.431
R-OL	-0.1	0.697	-0.38	0.134	0.05	0.84	0.08	0.772
L-OL	0.09	0.725	-0.19	0.468	-0.05	0.842	0.05	0.839

R-OFC = right orbitofrontal cortex; L-OFC = left orbitofrontal cortex; R-ATL = right anterior temporal lobe; L-ATL = left anterior temporal lobe; R-IFG = right inferior temporal gyrus; L-IFG = left inferior temporal gyrus; R-IPL = right inferior parietal lobe; L-IPL = left inferior parietal lobe; R-PTL = right posterior temporal lobe; L-PTL = left posterior temporal lobe; R-OL = right occipital lobe; L-OL left occipital lobe.

* $p < 0.05$.

Table 3
Partial correlation between Interpersonal Adjective Scale T-scores and fractional anisotropy of inferior longitudinal fasciculus, uncinate fasciculus and superior longitudinal fasciculus.

		Right ILF (FA)	Left ILF (FA)	Right UF (FA)	Left UF (FA)	Right SLF (FA)	Left SLF (FA)
Assured-dominant	<i>r</i>	0.15	0.27	0.26	0.43	− 0.15	− 0.37
	<i>p</i>	0.565	0.294	0.306	0.088	0.577	0.148
Arrogant-calculating	<i>r</i>	0.14	0.042	− 0.12	0.02	− 0.01	0.23
	<i>p</i>	0.603	0.87	0.659	0.943	0.971	0.366
Cold-hearted	<i>r</i>	− 0.55*	− 0.06	− 0.78**	− 0.35	− 0.48*	0.29
	<i>p</i>	0.023	0.808	> 0.001	0.166	0.049	0.258
Aloof-introverted	<i>r</i>	− 0.59*	− 0.22	− 0.65*	− 0.33	− 0.26	0.25
	<i>p</i>	0.014	0.392	0.005	0.2	0.307	0.342
Unassured-submissive	<i>r</i>	− 0.38	− 0.19	− 0.54*	− 0.26	− 0.19	0.25
	<i>p</i>	0.129	0.477	0.026	0.311	0.458	0.340
Unassuming-ingenuous	<i>r</i>	− 0.49*	− 0.29	− 0.45	− 0.49*	− 0.26	− 0.17
	<i>p</i>	0.044	0.251	0.073	0.047	0.314	0.526
Warm-agreeable	<i>r</i>	0.56*	0.03	0.56*	0.26	0.09	− 0.39
	<i>p</i>	0.021	0.91	0.02	0.306	0.737	0.123
Gregarious-extraverted	<i>r</i>	0.37	0.15	0.46	0.24	0.13	− 0.20
	<i>p</i>	0.142	0.575	0.067	0.345	0.607	0.440

ILF = inferior longitudinal fasciculus; UF = uncinate fasciculus; SLF = superior longitudinal fasciculus.

* *p* < 0.05.

** *p* < 0.001 (Bonferroni-adjusted *p*-value).

gray matter volume and white matter tract integrity. Compared to healthy controls, all three PPA variants performed significantly worse on the EET. Moreover, the svPPA group performed significantly worse than both lvPPA and nvfPPA patients. Individuals with lvPPA also outperformed nvfPPA patients but this was not significant. Our investigation of the relative contribution of gray matter volumes and white matter tract integrity to emotion detection performance in PPA revealed that only white matter tract integrity (right UF, SLF and ILF) was associated with emotion detection performance on the EET and the right UF tract was the strongest contributor to emotion detection in PPA. Moreover, the multiple linear regression model suggests that when examining the right UF and its associated GM regions (OFC and ATL), the right UF is the primary predictor of the EET performance. The EET performance and white matter tract association was independent of disease severity, age, gender and total intracranial volume.

Emotion processing is an essential component of social cognition (Ibanez et al., 2014). Most studies on emotion processing in PPA only assess static emotion recognition, using static pictures, rather than more realistic dynamic, multimodal stimuli. The TASIT EET integrates various modalities, incorporating matched facial, vocal, prosody and body gesture cues, depicting realistic scenarios. Atrophy of OFC and its relation to emotion recognition impairment has been reported in previous studies, particularly in svPPA (Kumfor and Piguet, 2012; Rosen et al., 2006). We also found a significant association between the OFC and

EET performance, however, this did not survive correction for multiple comparisons. Nevertheless, there is evidence that OFC plays a critical role in emotion processing. Similar to others, we found that patients with svPPA displayed substantial emotion recognition deficits, compared to the nvfPPA and lvPPA group, and healthy controls, even after accounting for their comprehension deficits (Couto et al., 2013; Downey et al., 2015; Kumfor et al., 2011; Piguet et al., 2015; Rohrer et al., 2012). Previous investigations on whether impairments were specific to negative or positive emotions revealed that patients with svPPA or nvfPPA were significantly impaired on negative emotions (anger, fear, sad) compared to healthy controls and svPPA were also significantly impaired on disgust (Kumfor et al., 2013). However, upon increasing the emotional intensity of the stimuli, the nvfPPA group did not differ from healthy controls.

Investigation of emotion recognition via affective prosody comprehension has revealed that patients with nvfPPA and lvPPA demonstrate significant affective receptive prosody deficits compared to healthy individuals (Rohrer et al., 2012). Moreover, the lvPPA and nvfPPA groups demonstrate modality-specific effects in that they are significantly more accurate at deciphering affective facial expressions than affective prosody (Rohrer et al., 2012). Consequently, it appears that the different modalities can be differentially affected in the three PPA variants. Evidence from previous studies implies that poor emotion recognition in our lvPPA group could be due to impaired affective

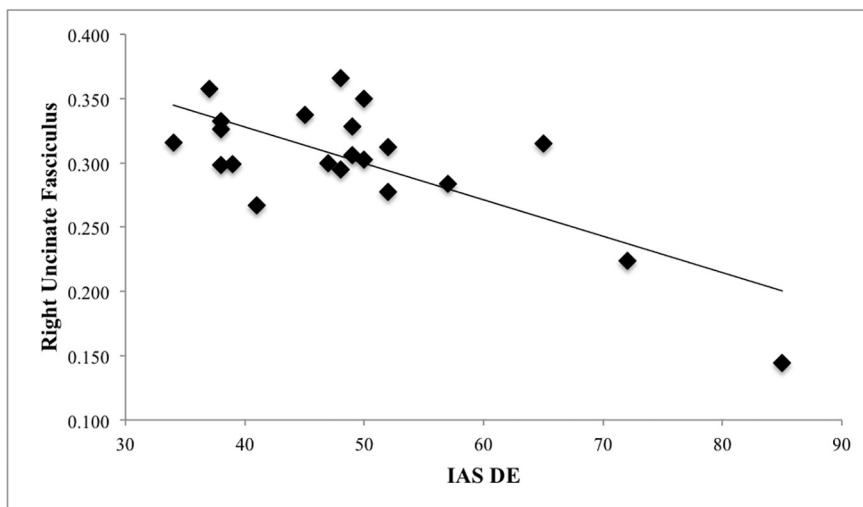


Fig. 5. Correlation between the IAS-DE (cold-hearted) T-score and the right uncinate fasciculus FA.

receptive prosody (Rohrer et al., 2012). Additionally, decreased accuracy could be exaggerated due to difficulty integrating incoming information from all three affective modalities. Future studies should decipher the nature of impairment of the three affective modalities in all three PPA variants. Such findings could result in targeted speech therapy for facilitating emotion recognition.

Impaired emotion recognition is most prominent in individuals with svPPA, in keeping with the focal damage to the UF and ATL. Our results confirm that the right UF is essential in emotion recognition as individuals with svPPA have the greatest atrophy in this area and are the most impaired (Galantucci et al., 2011; Gorno-Tempini et al., 2011). Furthermore, since the right UF is relatively spared in nvPPA and lvPPA, we assume that this contributes towards their better performance in emotion recognition, relative to svPPA and this finding is unrelated to disease severity, as assessed by CDR. Overall, the white matter tracts contributed more to accurate emotion recognition than the atrophied gray matter regions surrounding those tracts. Hence, to the best of our knowledge, this is the first study to demonstrate the more significant contribution of the right UF in emotion recognition in PPA. Patients with right UF lesions due to an acute stroke show emotional empathy impairment, further supporting its role in emotion-related tasks (Oishi et al., 2015). However, it is important to emphasize that the right UF is not the only tract associated with emotion recognition. As demonstrated in the current study, the right ILF and SLF also play a significant role.

Examination of the relationship between personality traits, gray matter volume and white matter tract integrity in PPA revealed that cold-hearted behavior is negatively correlated with the right UF FA. This in conjunction with the emotion perception deficits also being related to the same structure, the right UF, further strengthens the argument that the right UF is a key tract associated with emotion perception and display. Furthermore, the multiple linear regression model also suggests that cold-hearted trait is predominantly associated with the right UF FA, and not its associated GM regions (OFC and ATL). There is evidence that patients with svPPA undergo a significant personality change in their disease and show decline in warmth, extroversion, agreeableness, openness and dominance, as well as display more neurotic traits compared to premorbid levels (Mahoney et al., 2011; Sollberger et al., 2011; Sollberger et al., 2009). Moreover, these patients become significantly less warm and less extroverted as the disease progresses (Sollberger et al., 2011). Several neural correlates have been associated with altered personality in FTD: agreeableness and bilateral OFC volumes; openness with left medial OFC volume; warmth with right prefrontal, insula and anterior temporal regions (Mahoney et al., 2011; Sollberger et al., 2009). Consistent with existing literature, we also found an association between warm-agreeable traits and OFC and ATL, along with the right UF and ILF, however, these did not survive multiple comparison correction. The right UF is implicated in other traits, such as antisocial behavior in psychopathy and loss of emotional empathy in acute ischemic right hemisphere stroke, even in the absence of gray matter damage (Craig et al., 2009; Oishi et al., 2015). Experiments by Oishi et al. demonstrate that loss of right UF integrity, due to a stroke, is the primary contributor of emotional empathy deficit, accounting for as much as 70% variance on empathy task performance, which cannot be accounted by adjacent cortical regions (Oishi et al., 2015). Thus the right UF, a primary site of injury in svPPA, appears to be the most vital tract in recognizing emotions and predicting a cold-hearted behavioral trait. There is also evidence that the UF is an integral component for socialization and alterations in the UF has been implicated in antisocial behavior (Olson et al., 2015). Whether there is a relationship between impaired emotion detection and cold-hearted behavior remains to be explored.

Limitations of this study includes a limited sample size that precluded examining emotion-specific features that could provide insight into the role of different white matter tracts in emotion-specific recognition. There is evidence that different neuroanatomical regions

process negative and positive emotions (Northoff et al., 2000). Moreover, the relationship between personality and emotion detection abnormalities warrants further study.

5. Conclusion

The findings of the current study show emotion detection deficits in the three variants of PPA, with the svPPA group demonstrating the greatest difficulty at recognizing emotions in others. In addition to changes in their emotion detection capability, personality changes are well recognized in individuals with PPA. Previous literature showcases that these changes include increased neurotic traits and decline in warmth, openness, conscientiousness and extroversion. The current findings propose that emotion recognition impairment and changes in personality might result from disruption of the right UF, which serves as a connection between the ATL and OFC.

Therefore, while it is well established that there is diminished tract integrity in the UF in PPA, particularly in svPPA, our findings suggest a behavioral outcome which warrants further study, as it could explain certain non-cognitive symptoms seen in these individuals and could contribute to caregiver burden. Therefore, clinicians should consider an assessment of behavioral traits, as emotion detection and personality change are a critical component of socialization and quality of life.

Acknowledgements

We would like to thank the patients and their care partners for dedicating their time.

Funding

This work was supported by Fonds de Recherche du Québec – Santé, Larry L. Hillblom Foundation (grant number LLHF2002J), National Institute of Neurological Disorders and Stroke at the National Institutes of Health (grant number R01NS050915), and National Institute on Aging at the National Institutes of Health (grant numbers 1R01AG029577-01A2, 5 P01 AG019724, 5-K23-AG021606).

References

- Adolphs, R., 2009. The social brain: neural basis of social knowledge. *Annu. Rev. Psychol.* 60, 693–716.
- Catani, M., Mesulam, M.M., Jakobsen, E., Malik, F., Martersteck, A., Wieneke, C., Thompson, C.K., Thiebaut de Schotten, M., Dell'Acqua, F., Weintraub, S., Rogalski, E., 2013. A novel frontal pathway underlies verbal fluency in primary progressive aphasia. *Brain* 136, 2619–2628.
- Ciccarelli, O., Catani, M., Johansen-Berg, H., Clark, C., Thompson, A., 2008. Diffusion-based tractography in neurological disorders: concepts, applications, and future developments. *Lancet Neurol.* 7, 715–727.
- Couto, B., Manes, F., Montanes, P., Matallana, D., Reyes, P., Velasquez, M., Yoris, A., Baez, S., Ibanez, A., 2013. Structural neuroimaging of social cognition in progressive non-fluent aphasia and behavioral variant of frontotemporal dementia. *Front. Hum. Neurosci.* 7, 467.
- Craig, M.C., Catani, M., Deeley, Q., Latham, R., Daly, E., Kanaan, R., Picchioni, M., McGuire, P.K., Fahy, T., Murphy, D.G., 2009. Altered connections on the road to psychopathy. *Mol. Psychiatry* 14 (946–953), 907.
- Downey, L.E., Mahoney, C.J., Buckley, A.H., Golden, H.L., Henley, S.M., Schmitz, N., Schott, J.M., Simpson, I.J., Ourselin, S., Fox, N.C., Crutch, S.J., Warren, J.D., 2015. White matter tract signatures of impaired social cognition in frontotemporal lobar degeneration. *Neuroimage Clin.* 8, 640–651.
- Galantucci, S., Tartaglia, M.C., Wilson, S.M., Henry, M.L., Filippi, M., Agosta, F., Dronkers, N.F., Henry, R.G., Ogar, J.M., Miller, B.L., Gorno-Tempini, M.L., 2011. White matter damage in primary progressive aphasia: a diffusion tensor tractography study. *Brain* 134, 3011–3029.
- Gorno-Tempini, M.L., Hillis, A.E., Weintraub, S., Kertesz, A., Mendez, M., Cappa, S.F., Ogar, J.M., Rohrer, J.D., Black, S., Boeve, B.F., Manes, F., Dronkers, N.F., Vandenberghe, R., Rascovsky, K., Patterson, K., Miller, B.L., Knopman, D.S., Hodges, J.R., Mesulam, M.M., Grossman, M., 2011. Classification of primary progressive aphasia and its variants. *Neurology* 76, 1006–1014.
- Ibanez, A., Aguado, J., Baez, S., Huepe, D., Lopez, V., Ortega, R., Sigman, M., Mikulan, E., Lischinsky, A., Torrente, F., Cetkovich, M., Torralva, T., Bekinschtein, T., Manes, F., 2014. From neural signatures of emotional modulation to social cognition: individual differences in healthy volunteers and psychiatric participants. *Soc. Cogn. Affect.*

- Neurosci. 9, 939–950.
- Kumfor, F., Irish, M., Hodges, J.R., Piguet, O., 2013. Discrete neural correlates for the recognition of negative emotions: insights from frontotemporal dementia. *PLoS One* 8, e67457.
- Kumfor, F., Miller, L., Lah, S., Hsieh, S., Savage, S., Hodges, J.R., Piguet, O., 2011. Are you really angry? The effect of intensity on facial emotion recognition in frontotemporal dementia. *Soc. Neurosci.* 6, 502–514.
- Kumfor, F., Piguet, O., 2012. Disturbance of emotion processing in frontotemporal dementia: a synthesis of cognitive and neuroimaging findings. *Neuropsychol. Rev.* 22, 280–297.
- Mahoney, C.J., Rohrer, J.D., Omar, R., Rossor, M.N., Warren, J.D., 2011. Neuroanatomical profiles of personality change in frontotemporal lobar degeneration. *Br. J. Psychiatry* 198, 365–372.
- Mandelli, M.L., Caverzasi, E., Binney, R.J., Henry, M.L., Lobach, I., Block, N., Amirbekian, B., Dronkers, N., Miller, B.L., Henry, R.G., Gorno-Tempini, M.L., 2014. Frontal white matter tracts sustaining speech production in primary progressive aphasia. *J. Neurosci.* 34, 9754–9767.
- McDonald, S., Flanagan, S., Rollins, J., Kinch, J., 2003. TASIT: a new clinical tool for assessing social perception after traumatic brain injury. *J. Head Trauma Rehabil.* 18, 219–238.
- Morris, J.C., 1993. The clinical dementia rating (CDR): current version and scoring rules. *Neurology* 43, 2412–2414.
- Northoff, G., Richter, A., Gessner, M., Schlagenhaut, F., Fell, J., Baumgart, F., Kaulisch, T., Kötter, R., Stephan, K.E., Leschinger, A., Hagner, T., Bargel, B., Witzel, T., Hinrichs, H., Bogerts, B., Scheich, H., Heinze, H.J., 2000. Functional dissociation between medial and lateral prefrontal cortical spatiotemporal activation in negative and positive emotions: a combined fMRI/MEG study. *Cereb. Cortex* 10, 93–107.
- Oishi, K., Faria, A.V., Hsu, J., Tippett, D., Mori, S., Hillis, A.E., 2015. Critical role of the right uncinate fasciculus in emotional empathy. *Ann. Neurol.* 77, 68–74.
- Olson, I.R., Plotzker, A., Ezzyat, Y., 2007. The enigmatic temporal pole: a review of findings on social and emotional processing. *Brain* 130, 1718–1731.
- Olson, I.R., Von Der Heide, R.J., Alm, K.H., Vyas, G., 2015. Development of the uncinate fasciculus: implications for theory and developmental disorders. *Dev. Cogn. Neurosci.* 14, 50–61.
- Philippi, C.L., Mehta, S., Grabowski, T., Adolphs, R., Rudrauf, D., 2009. Damage to association fiber tracts impairs recognition of the facial expression of emotion. *J. Neurosci.* 29, 15089–15099.
- Piguet, O., Leyton, C.E., Gleeson, L.D., Hoon, C., Hodges, J.R., 2015. Memory and emotion processing performance contributes to the diagnosis of non-semantic primary progressive aphasia syndromes. *J. Alzheimers Dis.* 44, 541–547.
- Rankin, K.P., Gorno-Tempini, M.L., Allison, S.C., Stanley, C.M., Glenn, S., Weiner, M.W., Miller, B.L., 2006. Structural anatomy of empathy in neurodegenerative disease. *Brain* 129, 2945–2956.
- Rohrer, J.D., Sauter, D., Scott, S., Rossor, M.N., Warren, J.D., 2012. Receptive prosody in nonfluent primary progressive aphasias. *Cortex* 48, 308–316.
- Rohrer, J.D., Warren, J.D., 2010. Phenomenology and anatomy of abnormal behaviours in primary progressive aphasia. *J. Neurol. Sci.* 293, 35–38.
- Rosen, H.J., Allison, S.C., Ogar, J.M., Amici, S., Rose, K., Dronkers, N., Miller, B.L., Gorno-Tempini, M.L., 2006a. Behavioral features in semantic dementia vs other forms of progressive aphasias. *Neurology* 67, 1752–1756.
- Rosen, H.J., Wilson, M.R., Schauer, G.F., Allison, S., Gorno-Tempini, M.L., Pace-Savitsky, C., Kramer, J.H., Levenson, R.W., Weiner, M., Miller, B.L., 2006b. Neuroanatomical correlates of impaired recognition of emotion in dementia. *Neuropsychologia* 44, 365–373.
- Sollberger, M., Neuhaus, J., Ketelle, R., Stanley, C.M., Beckman, V., Growdon, M., Jang, J., Miller, B.L., Rankin, K.P., 2011. Interpersonal traits change as a function of disease type and severity in degenerative brain diseases. *J. Neurol. Neurosurg. Psychiatry* 82, 732–739.
- Sollberger, M., Stanley, C.M., Wilson, S.M., Gyurak, A., Beckman, V., Growdon, M., Jang, J., Weiner, M.W., Miller, B.L., Rankin, K.P., 2009. Neural basis of interpersonal traits in neurodegenerative diseases. *Neuropsychologia* 47, 2812–2827.
- Von Der Heide, R.J., Skipper, L.M., Klobusicky, E., Olson, I.R., 2013. Dissecting the uncinate fasciculus: disorders, controversies and a hypothesis. *Brain* 136, 1692–1707.
- Wiggins, J.S., Trapnell, P., Phillips, N., 1988. Psychometric and geometric characteristics of the revised interpersonal adjective scales (IAS-R). *Multivar. Behav. Res.* 23, 517–530.
- Wilson, S.M., Henry, M.L., Besbris, M., Ogar, J.M., Dronkers, N.F., Jarrold, W., Miller, B.L., Gorno-Tempini, M.L., 2010. Connected speech production in three variants of primary progressive aphasia. *Brain* 133, 2069–2088.