

Aortic Knob Width: A Possible Marker of Vascular Remodeling in Obstructive Sleep Apnea

Kazuki Shiina, Hirofumi Tomiyama, Yoshifumi Takata and Taishiro Chikamori

Department of Cardiology, Tokyo Medical University, Tokyo, Japan

See article vol. 27: 501-508

Obstructive sleep apnea (OSA) is characterized by recurrent episodes of upper airway collapse during sleep, resulting in apneas or hypopneas. Several cohort studies have recently shown that severe OSA is independently associated with an increased risk of myocardial infarction, stroke, and death from cardiovascular disease¹⁻⁴.

The possible mechanisms underlying OSA contribution to atherosclerosis comprise complex and interrelated cascades. Therefore, it is difficult to elucidate the causal relationship between OSA and atherosclerosis. Among these mechanisms, intermittent hypoxia is believed to be the main component linking OSA to atherosclerosis.

Clinical data and experimental evidence in animal models suggest that OSA can have direct proatherogenic effects inducing systemic inflammation, oxidative stress, vascular smooth muscle cell activation, increased adhesion molecule expression, monocyte/lymphocyte activation, increased lipid loading in macrophages, lipid peroxidation, and endothelial dysfunction⁵. In fact, several cross-sectional studies have consistently shown that OSA is independently associated with surrogate markers of premature atherosclerosis, such as intima-media thickness (IMT)^{6,7}, pulse wave velocity (PWV)⁸, cardio-ankle vascular index (CAVI)⁹, and flow-mediated dilation (FMD)¹⁰. Moreover, the effects of OSA treatment with continuous positive airway pressure (CPAP) on these surrogate markers have been shown in some clinical trials⁷.

However, to the best of our knowledge, there are no reports regarding aortic knob width in patients with OSA. In this issue of *Journal of Atherosclerosis and Thrombosis*, Tomita *et al.*¹¹, a significant inde-

pendent correlation between aortic knob width and OSA severity has been shown. They focused on aortic knob width that is believed to reflect vascular remodeling. The vascular remodeling might be one of the phenotypes of vascular damage related to OSA (**Fig. 1**). They measured the aortic knob width in chest radiographs of 549 patients who underwent overnight polysomnography, and evaluated the association between aortic knob width, CAVI, and apnea-hypopnea index (AHI). Interestingly, the aortic knob width increased with increasing OSA severity. Furthermore, multivariate regression analysis revealed that AHI was associated with aortic knob width independent of CAVI and blood pressure in patients with OSA. These findings suggest that OSA may increase the aortic knob width through increase in arterial stiffness and other mechanisms. In patients with OSA, a significant proportion of negative intra-thoracic pressure during obstructive respiratory events is forwarded to the walls of the aorta. Therefore, exaggerated negative intra-thoracic pressure is speculated to play an important role in increase aortic knob width¹¹.

Another interesting point to consider is that simple examinations, such as chest radiography, may provide novel information regarding OSA and may serve as a tool in its screening¹¹. Diagnosis of OSA requires a sleep study, so many patients with OSA remain undiagnosed. If simple examinations, such as aortic knob width measurement using chest radiography, lead to early diagnosis of OSA, it will help to decrease atherosclerosis morbidity and mortality. However, it should be noted that the methodology of aortic knob width measurement is not well established and the accuracy and reproducibility have not been tested. Further study is necessary to assess the standard values of aortic knob width by age.

Finally, further steps include determining the

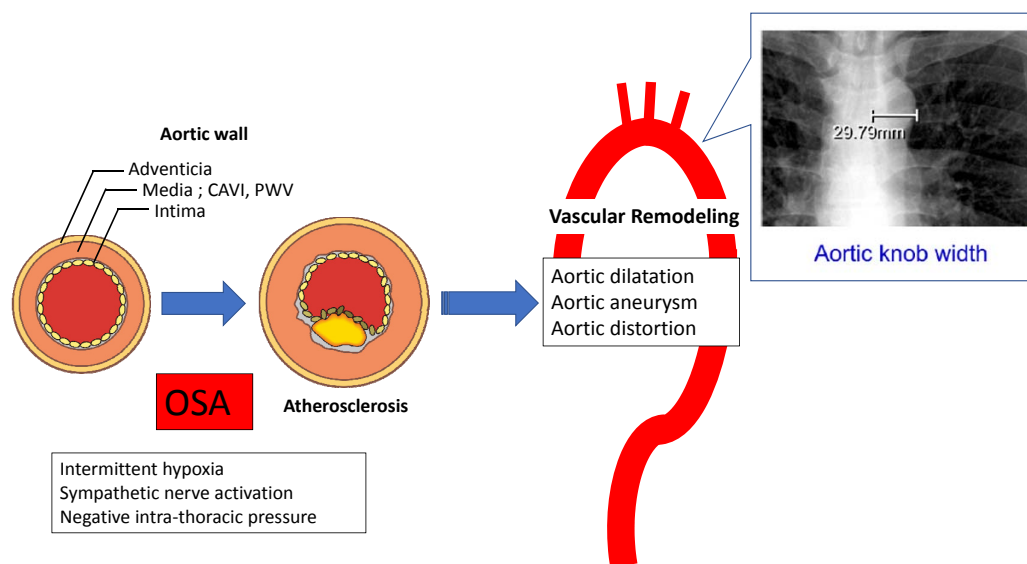


Fig. 1. Proposed mechanisms of vascular remodeling induced by obstructive sleep apnea (OSA)
CAVI; cardio-ankle vascular index, PWV; pulse wave velocity

effect of CPAP, treatment of severe OSA, on the aortic knob width in patients with OSA and assessing the benefits of OSA screening in patients with dilated aortic knob width.

Conflict of Interest

I have no COI to declare regarding this manuscript.

References

- 1) Marin JM, Carrizo SJ, Vicente E, Agusti AG. Long-term cardiovascular outcomes in men with obstructive sleep apnoea-hypopnoea with or without treatment with continuous positive airway pressure: an observational study. *Lancet*, 2005; 65: 1046-1053
- 2) Young T, Finn L, Peppard PE, Szklo-Coxe M, Austin D, Nieto FJ, Stubbs R, Hla KM. Sleep disordered breathing and mortality: eighteen-year follow-up of the Wisconsin sleep cohort. *Sleep*, 2008; 31: 1071-1078
- 3) Marshall NS, Wong KK, Liu PY, Cullen SR, Knuiman MW, Grunstein RR. Sleep apnea as an independent risk factor for all-cause mortality: the Busselton Health Study. *Sleep*, 2008; 31: 1079-1085
- 4) Yaggi HK, Concato J, Kernan WN, Lichtman JH, Brass LM, Mohsenin V. Obstructive sleep apnea as a risk factor for stroke and death. *N Engl J Med*, 2005; 353: 2034-2041
- 5) Drager LF, Polotsky VY, Lorenzi-Filho G. Obstructive sleep apnea: an emerging risk factor for atherosclerosis. *Chest*, 2011; 140: 534-542
- 6) Drager LF, Bortolotto LA, Krieger EM, Lorenzi-Filho G. Additive effects of obstructive sleep apnea and hypertension on early markers of carotid atherosclerosis. *Hypertension*, 2009; 53: 64-69
- 7) Drager LF, Bortolotto LA, Figueiredo AC, Krieger EM, Lorenzi GF. Effects of continuous positive airway pressure on early signs of atherosclerosis in obstructive sleep apnea. *Am J Respir Crit Care Med*, 2007; 176: 706-712
- 8) Shiina K, Tomiyama H, Takata Y, Usui Y, Asano K, Hirayama Y, Nakamura T, Yamashina A. Concurrent presence of metabolic syndrome in obstructive sleep apnea syndrome exacerbates the cardiovascular risk: a sleep clinic cohort study. *Hypertens Res*, 2006; 29: 433-441
- 9) Kumagai T, Kasai T, Kato M, Naito R, Maeno KI, Kasagi S, Kawana F, Ishiwata S, Narui K. Establishment of the cardio-ankle vascular index in patients with obstructive sleep apnea. *Chest*, 2009; 136: 779-786
- 10) Ip MS, Tse HF, Lam B, Tsang KW, Lam WK. Endothelial function in obstructive sleep apnea and response to treatment. *Am J Respir Crit Care Med*, 2004; 169: 348-353
- 11) Tomita Y, Kasai T, Ishiwata S, Daida H, Narui K. Aortic Knob Width as a Novel Indicator of Atherosclerosis and Obstructive Sleep Apnea. *J Atheroscler Thromb*, 2020; 27: 501-508