

# A low cost artisan tension-free tape technique cures pelvic organ prolapse and stress urinary incontinence – proof of concept

Silvia Piñango-Luna<sup>1</sup>, Luis Level-Córdova<sup>1</sup>, Peter Emanuel Petros<sup>2,3</sup>, Alexander Yassouridis<sup>4</sup>

<sup>1</sup>Department of Surgery, Dr. Miguel Pérez Carreño Hospital, Universidad Central de Venezuela, Caracas, Venezuela

<sup>2</sup>University of NSW Professorial Department of Surgery, St Vincent's Hospital, Sydney, Australia

<sup>3</sup>School of Mechanical and Chemical Engineering, University of Western Australia, Perth, Australia

<sup>4</sup>Faculty of Medicine at LMU Munich, Munich, Germany

**Citation:** Piñango-Luna S, Level-Córdova L, Petros PE, Yassouridis A. A low cost artisan tension-free tape technique cures pelvic organ prolapse and stress urinary incontinence – proof of concept. Cent European J Urol. 2020; 73: 490-497.

## Article history

Submitted: Sept. 21, 2020

Accepted: Nov. 15, 2020

Published online: Dec. 3, 2020

## Corresponding author

Peter Petros

University of Western

Australia

Stirling Highway Crawley

Perth, 6004 Western

Australia

pp@kvinno.com

**Introduction** The primary cause of pelvic organ prolapse (POP) is weak cardinal/uterosacral (CL/USL) ligaments and for stress urinary incontinence, weak pubourethral ligaments (PUL).

**Material and methods** A 1 cm wide tape cut from a mesh sheet was applied tension-free to reinforce already plicated CL/USLs for cure of prolapse and directly to PUL for cure of stress urinary incontinence (SUI). 40 tapes were inserted, 10 midurethrally for SUI and 30 for 2<sup>nd</sup>/3<sup>rd</sup> degree prolapse: 15 to uterosacral ligaments and 15 to cardinal ligaments.

**Results** At 12 months follow-up there was 72% cure for POP, 70% for SUI and improvement in urge/noc-turia symptoms in 82% of patients.

At 36 months 8/15 patients were evaluated. Anatomic cure for POP III was 2/4, for POP I-II 6/6.

**Conclusions** Though a 'proof of concept' study, our results may be sufficient to provide, in time, an alternative individual pathway for surgeons wishing to provide more certainty to a prolapse repair than 'native tissue' for an individual patient. The method questions whether expensive mesh kits are really necessary: our data though small, actually part of a learning curve, was within 15 percentage points of more sophisticated, more expensive tensioned slings. Intraoperative complications were low with no tape erosions seen at 12 months. Further validation with larger prospective and comparative trials is required.

**Key Words:** artisan tape <> midurethral sling <> pelvic organ prolapse <> tension-free tape <> native tissue repair <> Integral Theory

## INTRODUCTION

The world population is ageing as is, relatedly and concomitantly, the incidence of prolapse, bladder and bowel incontinence. According to the International Continence Society (ICS), these conditions co-occur; other than stress urinary incontinence (SUI) bladder and bowel conditions are said not to be generally curable [1]. In the PROSPECT trial, pelvic organ prolapse (POP) treated with vaginal repairs or mesh behind the vagina [2] reported cure rates as low as 26% at 6 months [2]. Absent from the PROSPECT

trial [2], were posterior sling operations to repair uterosacral (USL) and cardinal (CL) ligaments, the level 1 supports of DeLancey [3]. Yet such ligament-only repair techniques have consistently reported cure rates of 90% at 12 months for the pelvic organ prolapse quantifications system (POPQ) 3<sup>rd</sup> and 4 degree [4–9], falling to 79% at 5 years [9], with low erosion rates. Importantly, slings used for prolapse differ markedly from the mesh sheets reported in the PROSPECT trial in their modus operandi. Operations using mesh sheets work very differently from slings. Mesh sheet operations block organ descent.

Slings repair prolapse by reinforcing damaged suspensory ligaments [4–9].

Hitherto, sling operations [4–9] have required expensive surgical kits subject to government regulation. Such kits are not generally available in countries with limited health resources. The ‘tension-free’ operations in this work are conceptually similar to the sling methodology used for SUI [10] and also, prolapse repair [4–9]: for SUI, a tension-free tape inserted along the pathway of the pubourethral ligament (PUL); for prolapse, plication of ligaments to shorten them and strengthening them with a ‘tension-free’ tape inserted along the ligament; the tape works by irritating the tissues to create a collagenous neoligament [11]. From a structural perspective [3], it follows that loose or weakened cardinal (CL) and uterosacral (USL) ligaments and their fascial attachments (F), Figure 1, will lead to uterine/apical prolapse. The differential strengths of ligaments, breaking strain 300 mg/mm<sup>2</sup>; vagina 60 mg/mm<sup>2</sup> [13], guided two surgical rules we followed according to the Integral Theory [4–12]:

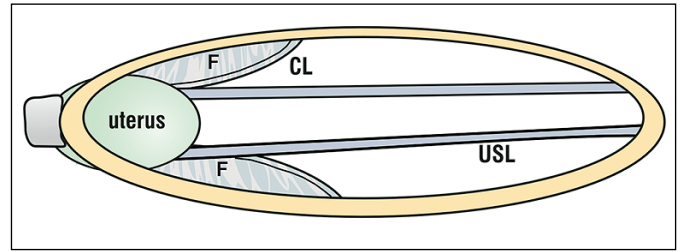
1. No vaginal excision. Excision removes a quantum of collagen/elastin/ nerves required for normal function [12].
2. Collagen deficient ligaments (Figure 1) require shortening and reinforcement with tapes [11].

We reasoned that application of an artisan\* tape ‘tension-free’ at midurethra using a Crile forceps would mimic a standard midurethral sling [10]. The historical precedent of the Fothergill-Manchester operation endorsed our decision to repair CL/USL for apical prolapse. High cure rates for prolapse achieved in older women using posterior CL/USL slings [4–9] endorsed our decision to reinforce already plicated CL and USL with ‘tension-free’ tapes.

This work is part of the first author’s (SP) PhD thesis (co-supervised by PP) which examines the role of loose or damaged ligaments in the pathogenesis of prolapse, SUI and other symptoms [12] and repair thereof by insertion of ‘tension-free’ tapes.

### Ethics

Approval for works comprising the thesis, "Análisis crítico de la teoría integral como predictor de la función del piso pélvico, la disfunción y el manejo. Consideraciones clínicas y experimentales", was granted by Universidad Central de Venezuela in 2016. The ethics committee of Hospital ‘Dr. Miguel Pérez Carreño’



**Figure 1.** Both CL and USL are elongated in uterine prolapse. It is self-evident that loose cardinal (CL) and uterosacral (USL) ligaments (DeLancey level 1 supports) and their fascial attachments F will elongate to cause uterine prolapse, with structural supports restored only by shortening and strengthening.

Caracas – Venezuela, where the operations were performed, was granted ethics approval for data acquisition from hospital records. Informed consent including of deidentified data was obtained from all patient.

### MATERIAL AND METHODS

This tension-free methodology for all the operations was by single incision sling (SIS): for SUI, a tape was inserted directly as in some minislings; for prolapse, plication of ligaments and then reinforcing them with a tape inserted along the line of the ligament. Both operations are conceptually identical to the original ‘tension-free vaginal tape’ (TVT) [10]: the tape creates new collagen to reinforce a weak ligament. In all the operations we followed principles of vaginal conservation, and ligament repair based on the Integral Theory System, as set out in 1997 [4]. All 40 surgeries were carried out by PS and LL. Whereas PS and LL were experienced in vaginal and laparoscopic surgery and midurethral sling operations, all 40 surgeries applying the ‘tension-free’ tape method described here were performed with no learning period. The 40 surgeries were the ‘learning curve’. Because of the collapse of the economy and the health system in Venezuela, no more surgeries were able to be performed to fulfill the original target of 80 patients.

The indications for surgery were

- Symptomatic prolapse with POPQ II or III (n = 13)
- Clinically evident SUI (n = 10)
- Two cases of severe vulvodynia with minimal 1<sup>st</sup> degree uterine prolapse addressed by CL/USL repair.

### Surgical technique

On the day of the surgical intervention, elastic compression stockings were placed and prophylactic

\* A 1 cm wide tape was cut from a larger mesh sheet used for hernia repair. The primary objective of the surgery was to add an extra structural dimension to native tissue ligament repair, applying a 1 cm wide artisan polypropylene tape superimposed on already plicated ligaments, to strengthen them by creating new collagen [11].

with Cefazolin 1–2 g was administered an hour prior to the intervention. After regional or general anesthesia, the patient was placed in lithotomy position. Bladder drainage was carried out with a No. 18 Foley catheter.

Non-absorbable suture material was used for ligament reconstruction and tape fixation to cervix, and long-lasting absorbable suture material for anatomical reconstruction of surgical planes, such as pubocervical fascia fixation to the cervix and closure of vaginal wall.

Using Mayo scissors, 10 cm x 1 cm wide strips (tapes) were cut from a hernia sheet made of low-density, macroporous, polypropylene mesh (Ethicon).

### Reconstruction of the pubourethral ligament for SUI (Figure 2)

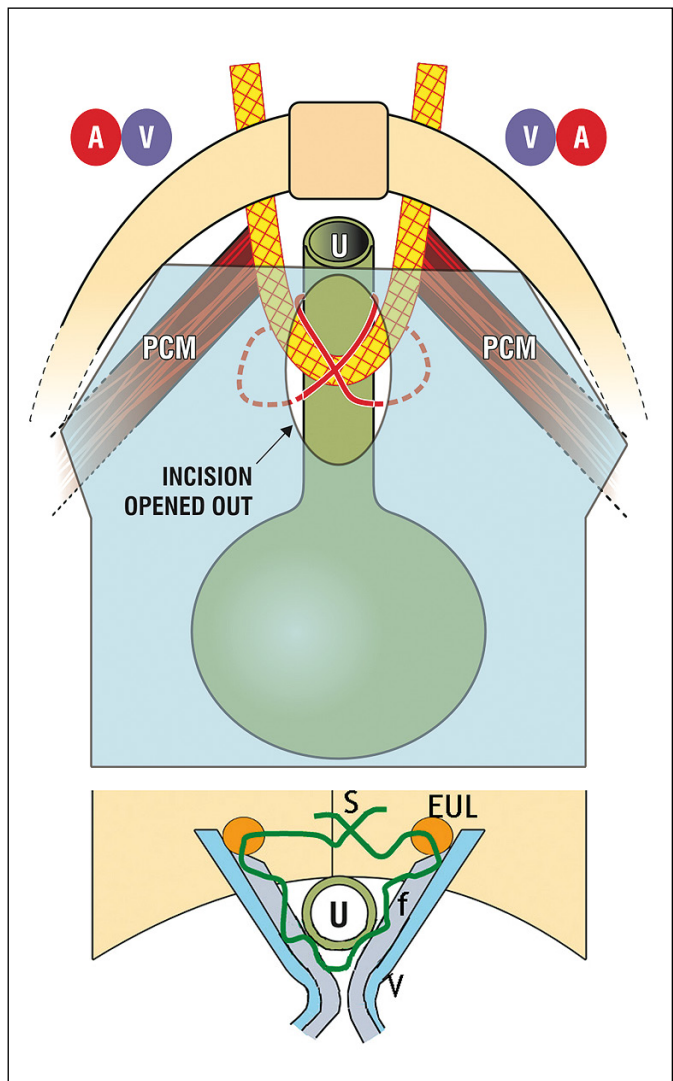
With an 18 Fr Foley catheter in place, a midline incision was performed through the vaginal mucosa at midurethra (Figure 2). Using Metzenbaum scissors, a tunnel for the tape was made in the pubocervical and paraurethral fascia in cephalic direction, towards the retropubic space, between the periosteum and the subpubic ligament; the Metzenbaum scissors penetrated the perineal membrane to a depth of approximately 1.5 cm. The procedure was repeated on the contralateral side. Occasional bleeding from injury to the venous system when encountered was controlled by digital compression of the vaginal wall against the pubis.

The end of a 8 cm tape was grasped with a Crile forceps and directed upwards through the tunnel. This procedure was repeated on the contralateral side of the urethra with sufficient tension for the tape to firmly touch, but not indent the urethra distended by an 18 Fr Foley catheter (Figure 2).

Finally, the suburethral vagina was reconstituted. With Foley catheter in situ, the midline incision was extended to within 0.5 cm of the external meatus; the external pubourethral ligament 'EUL' was located just lateral to the meatus and penetrated by an 00 vicryl suture which was then inserted in a continuous suture, into the right and left vaginal fascia finishing with the contralateral EUL, (Figure 2). The vaginal wall was closed with interrupted, delayed absorption sutures. VIDEO: <https://youtu.be/P1HTF5hh32A>

### Reconstruction of cardinal ligaments for cystocele and /or uterine prolapse (Figure 3)

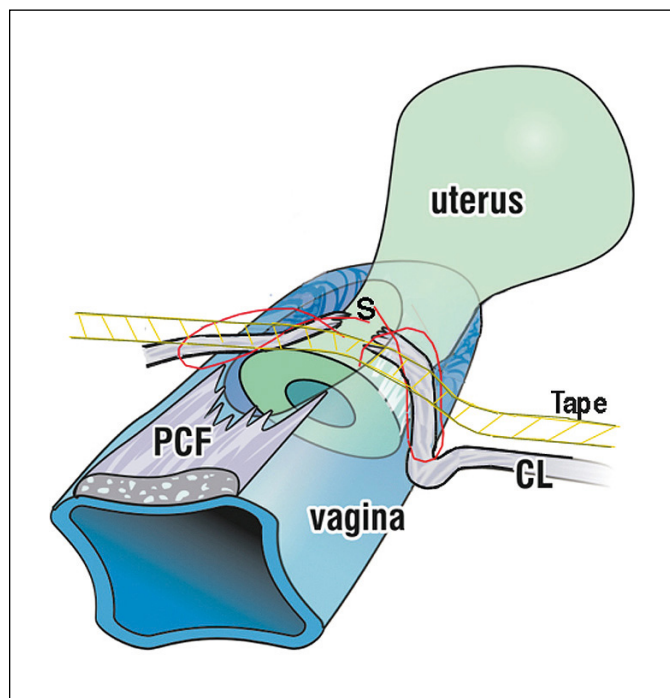
An Auvard weighted speculum was placed on the posterior wall of the vagina. The cervix was grasped with a Pozzi forceps. A full thickness transverse incision was made in the anterior wall of the vagina at



**Figure 2.** Artisan tape used for cure of SUI. Upper figure: Repair of the pubourethral ligament. Schematic view from above. The artisan tape is inserted via a single suburethral incision. The tape is inserted with a Crile forceps below the symphysis via a tunnel made through the perineal membrane as per theTVT. Lower figure: Schematic view looking into the vagina. With an 18 Fr catheter in situ, and using a 2-0 vicryl suture, the external urethral ligament (EUL) lateral to the urethra is located; the suture is placed into the vaginal fascia (f) on one side, then into (f) on the contralateral side, then into the contralateral EUL and tied loosely.

the juncture of bladder to cervix, about 2–3 cm distal to the cervical os or vaginal vault. Dissection proceeded from pubocervical fascia towards urethrovesical junction. Dissection was facilitated by traction of the cervix. This aided identification of the cardinal ligament by palpation.

The cardinal ligaments, 2–3 cms inferior and lateral to the cervix, Figure 3, were grasped with Allis for-



**Figure 3.** Cardinal ligament/pubocervical fascia repair by tension-free tape. Schematic 3D view of the uterus, vagina and cardinal ligaments (CL). CLs are shown torn from their attachment to the anterior cervical ring and prolapsed down the side of the cervix. The pubocervical fascia (PCF) of the vagina is shown torn from the cardinal ligaments and the cervical ring. The CLs are sutured back onto the cervical ring 'S' and the tape is inserted tension-free via tunnels made along the anatomical line of the CLs.

ceps; a suture 'S', was placed in each to bring them to the midline, fixing them to the anterior aspect of the cervix. Additional support was provided where required, by further suturing the cardinal ligaments. VIDEO native tissue CL repair <https://youtu.be/aJDPOELZZfc>

Following plication, a 10 cm long 1 cm wide tape was prepared from a polypropylene sheet used for hernia repair. Under tension, a tunnel parallel to the cardinal ligament was dissected with Metzenbaum scissors laterally in the direction of the pelvic wall for the introduction of the tape, and repeated contralaterally. One end of the tape was grasped with a Crile forceps and inserted into the tunnel made up to the fascia. The procedure was repeated on the contralateral side. The middle part of the tape was fixed to the cervix (Figure 4).

To correct the cystocele, the previously dissected pubocervical fascia (PCF), (Figure 3) was attached to the cervix with sutures using a purse-string ('tobacco pouch') suture. The vaginal wall was closed with a running suture.

### Reconstruction of uterosacral ligaments for uterine prolapse (Figure 4)

An Auvard weighted speculum was placed on the posterior wall of the vagina. The cervix was grasped with a Pozzi forceps. A full thickness 5 cm transverse incision was made in the posterior wall of the vagina, 3–4 cm distal to the cervix or vaginal vault. Blunt dissection of the rectal vaginal fascia was made with identification of the posterior cul-de-sac or enterocele. The enterocele was closed without opening it. Traction of the cervix tensioned the uterosacral ligament (USL). The USLs were identified by palpation at hours 4 and 8 in relation to the cervix.

Both USLs were grasped with Allis forceps; a suture was placed, approximating the USLs from A to B (Figure 4). Additional support was provided by a 2<sup>nd</sup> approximating suture as required. VIDEO native tissue USL repair: <https://www.youtube.com/watch?v=MGLdYHtqxzg>

Following plication, a 1 cm diameter tunnel for the introduction of the prosthetic material was made between the vaginal skin and the uterosacral ligaments by dissection backwards along the direction of both USLs.

A 10 cm long prosthetic material strip was created. One end of the tape was grasped with a Crile forceps and inserted into the tunnel made in the fascia. The procedure was repeated on the contralateral side. The vaginal wall was closed with a running suture of long-lasting absorbable material.

### Statistical analysis

For continuous variables location and dispersion statistics like mean, standard deviation, minimum, maximum etc. were calculated, whereas for nominal or categorical variables, absolute and relative frequencies, cure rates etc. were calculated. Differences between symptoms at different times were only investigated on a descriptive and explorative manner. The data was tabulated and processed with R for Windows version 3.6.2.

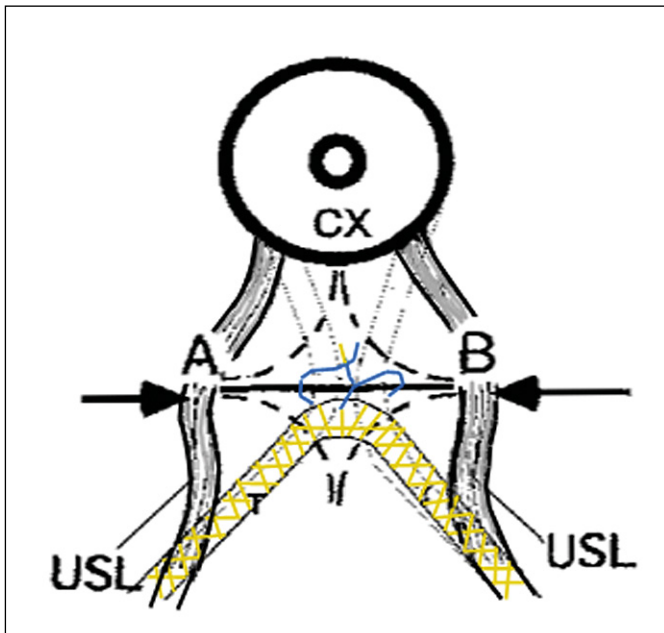
### Statistical note

(AY) "It is to be noted here that the present study as a 'proof of concept' study is not and cannot be, a power- and hypotheses-based study".

**VIDEO 1.** <https://youtu.be/aJDPOELZZfc> shows the first part of the operation, native tissue CL plication and pubocervical fascial re-attachment. The tape was added later.

**VIDEO 2.** <https://youtu.be/0kHudBwgnWs> shows the first part of the operation, native tissue USL pli-





**Figure 4.** Uterosacral ligament/rectovaginal fascia repair by tension-free tape. Schematic view looking into the vagina. A and B = uterosacral ligaments (USL); A 5 cm long transverse full thickness incision is made between A and B, 3–4 cm below the cervix (CX) and opened out. USLs (A&B) are approximated. Following this, the tape (T) is inserted tension-free along the length of the USLs.

cation and rectovaginal fascial re-attachment. The tape was added later.

## RESULTS

In all, 40 interventions were performed in 15 patients with ligament reconstruction using the described techniques, Figs 2–4. We accounted by surgical procedures and not by number of operated patients. There were 15 patients, aged between 40 and 83 years, with pelvic organ prolapse II or III, Table 1, and (variously) with symptoms of stress urinary in-

**Table 1.** Technique for reconstruction of pubourethral, cardinal and uterosacral ligaments as a treatment of dysfunctions of the pelvic floor. Characteristics of the sample

Variables	Statistics (n)	Total (%)
n	15	
Age (years)(*)	64 ±12	
Clinical record		
Pelvic pain	6	40.0%
Vulvodynia	2	13.3%
SUI	9	66.6%
Nocturia	11	73.3%
POPQ		
POPQ I	2	13.3%
POPQ II	6	40.0%
POPQ III	7	46.7%
Technique		
Uterosacral	15	100.0%
Cardinal	15	100.0%
Pubourethral	10	66%

(\*) media ± standard deviation; SUI – stress urinary incontinence; POPQ – pelvic organ prolapse quantifications system

continence, urge incontinence and/or nocturia, pelvic pain and vulvodynia, Table 2. Uterosacral, cardinal, or pubourethral reconstruction was performed in 15, 15, and 10 cases, respectively. Two of the 15 patients had undergone prior hysterectomy.

There were no significant intraoperative or immediate postoperative complications. Time spent in hospital was 24 hours. All patients were discharged the day after surgery.

Postoperative follow-up was recorded quarterly up to 1 year, describing the percentage of appearance of new symptoms and the cure of the older symptoms (Table 2). Resolution of baseline symptoms one year after surgery for prolapse, stress urinary incontinence, urinary urgency, pelvic pain, and vulvodynia was between 66% and 100%.

Of 6 patients with preoperative pelvic pain 4 were resolved at 12 month review. We registered one de novo case of pelvic pain. Severe vulvodynia (n = 2) in women with minor prolapse was cured in both with ‘tension-free’ CL/USL repair.

**Table 2.** Technique for reconstruction of pubourethral, cardinal and uterosacral ligaments as a treatment of dysfunctions of the pelvic floor. Symptoms resolution after the procedure

Symptoms	Preoperative presence of initial symptoms		Postoperative absence of initial symptoms		% of resolution	p
	n	%	n	%		
Pain	6	40.0	2	13.3	66.6	0.033
Vulvodynia	2	13.3	2	13.3	100.0	N/A
SUI	10	66.6	7	46.6	70.0	0.033
Nocturia	11	73.3	9	60.0	81.8	0.002
Prolapse	13	86.7	11	73.3	84.6	0.001

There were no intraoperative complications. All patients passed urine postoperatively and were discharged the following day. There were no erosions or other tape complications at 12 months review. However, one midurethral sling patient presented with an erosion at 3 years. This was treated by painless removal of the excised segment as an office procedure.

### 3-year results

Eight patients out of the initial 15 were evaluated at 3 years. Their preoperative symptoms were: pelvic pain in 4 patients, vulvodynia in 2 patients, stress urinary incontinence in 6 patients, urinary urgency in 8 patients, POPQ I in 1 patient (surgery for vulvodynia with minimal POP), POPQ II in 3 patients, POPQ III in 4 patients. Interventions were: reconstruction of uterosacral and cardinal ligament in all 8 patients and reconstruction of puburethral ligament in 6 patients. Symptom cure at 3 years: pelvic pain: 2/4, vulvodynia 2/2, SUI 4/6; urinary urgency 6/8. Anatomic findings: POPQ I: 6 patients, POPQ II: zero patients, POP III: 2 patients. It is important to note that one of the patients with symptoms of severe stress urinary incontinence requiring the use of large daily towels was entirely cured, suggesting, perhaps, that the 'tension-free' tape approach as performed by us for SUI may be valid even for very severe symptomatic cases.

## DISCUSSION

This work seems to have fulfilled its original aim, to provide a low-cost method to create the new collagen essential for POP and incontinence in older women in poor countries. The cost is no more than EUR 3–4 per sling instead of up to EUR 800 for a kit. Furthermore, the anatomical and symptom cure results, albeit in small numbers, were not so far inferior to those of more sophisticated (and far more expensive) single incision kits [8].

This publication is part of a PhD study approved by Universidad Central de Venezuela. It is unfortunate that after completion of operations on the 15 patients reported here, no further surgery was possible because of the collapse of the Venezuelan economy and the health system itself. Consequently, our numbers are small, requiring our study to be transformed to a 'proof of concept'.

### How easily learnt is this method?

The data presented in fact constitutes SP's learning curve in its entirety.

Our view is that it is easily performed by any competent vaginal surgeon. It is a matter of locating CLs and USLs, plicating them and laying a 10 cm tape across the anatomical position of the repaired ligaments 'tension-free'. These were the first ever 15 patients operated on by the 1<sup>st</sup> author (SP) using this method. Given this proviso, the results in our view are not so far inferior to more sophisticated and expensive tape methods [4–9].

Are ligament repairs alone sufficient to cure major prolapse? Yes. Our methodology is conceptually similar to the large multicenter ligament repair only study which reported 90% anatomical cure at 12 months for mostly 3<sup>rd</sup>/4<sup>th</sup> degree POPQ prolapse [8]. Our data, though only a 'proof of concept' are far superior to the very low cure rates for POP surgeries reported by the vagina-based surgeries of the PROSPECT trial [2].

A historical perspective is that the CL/USL 'tension-free' technique could be described as a more modern and less invasive version than the classical Fothergill method [14], with, (importantly) the addition of tapes [11] to create new collagen to reinforce CL/USLs.

### Is a tape necessary?

The short answer for post-menopausal women is 'yes'. The poor results of the PROSPECT trial, 80% failure at 12 months [2] after vaginal repair, can be explained by collagen breakdown after the menopause and excretion as OH proline [15]. In contrast, CL/USL slings create new collagen and achieve high anatomical and symptom cure rates [4–9], even 5 years after surgery [9].

The recent banning of all mesh kits (including tape sling kits) for prolapse surgery has seemingly deprived American, European and other surgeons of any possibility to help older women with major symptoms and prolapse with ligament-based surgery [4–9]. We believe that the 'tension-free' tape method we used can provide a safe, easily learnt, legal alternative to [4–9] to help the older group of women most in need of this methodology. Our method uses the same mesh as a commercial midurethral [10] and other slings [4–9], except that the tape was cut from an FDA approved mesh sheet with scissors, not the laser still used for commercial kits slings. The FDA ban is only on commercial kits. It has always been within the province of an individual surgeon to use any FDA or CE approved product (in this case the mesh from which the tape is cut) for an individual condition (e.g., prolapse or incontinence), in an individual patient, for specific individual indications which are supported by relevant data.

Ethics and safety our surgical methodology is virtually identical with that of the MUS, literally a 'reverse TVT'. There were no erosions or mesh complications in our 40 implants at 12 months. We attribute this to the mesh itself (3<sup>rd</sup> generation lightweight microporous mesh), the very small amount of mesh implanted, (a 1 cm x 10 cm strip of tape), but, also, importantly, to the fact 'that no significant amount of mesh was inserted behind the vaginal membrane' [16]. The amount of mesh in contact with the vagina was miniscule.

Mesh sheets may cause problems from shrinkage, pain from trapping of the nerve in contracting scar tissue from the mesh and interfering with the vaginal elasticity necessary for normal bladder function [16] which may result in massive uncontrollable urine loss from the tethered vagina syndrome [17]. Such complications are rarely if ever seen with slings, as slings have very little contact with the vagina. They attach the organs directly to the skeleton [16]. We had no such complications.

Worthy of comment were two patients with severe vulvodynia cured by CL/USL plication and tension-free tapes. In both cases, the pain was relieved by the speculum test reported by Wu et al. [18]. They had only slight prolapse, hardly 1<sup>st</sup> degree. Though not definitive, it serves as very minor confirmation of an important Integral Theory prediction: symptoms of bladder, bowel and pain dysfunction may occur with minimal prolapse [19].

### The importance of a sling for long-term cure

Collagen is the main structural component of ligament/fascia [12]. Collagen degenerates after the

menopause at twice the normal rate [15], which explains the increasing incidence of osteoporosis, fractures, prolapse etc. in older woman. A tape creates a neocollagenous ligament [11]. Whereas our data was insufficient to draw any conclusions, there is strong data from related sling operations indicating this may be so: 17 year data for the midurethral sling [20] and 5 year data for CL/USL slings [9]. In contrast, the PROSPECT study whether native tissue vagina or mesh augmented, gives very poor results for POP, greater than 80% failure at 6 months [2].

## CONCLUSIONS

Though reduced to a 'proof of concept', our results may be sufficient to provide in time, an alternative individual pathway for surgeons wishing to provide more certainty to a prolapse repair than 'native tissue' ligament repair for an individual patient, especially those with poor health services. The method questions whether expensive mesh kits are really necessary: our data though small, and comprising only the first author's (SP) learning period, was within 15 percentage points of the more sophisticated, more precise, more expensive sling kits. Intraoperative complications were low with no tape erosions at 12 months. Clearly, further validation with larger prospective and comparative trials is required

### CONFLICTS OF INTEREST

The authors declare no conflicts of interest.

### CONTRIBUTIONS PLANNING

PP SP; Surgery SP LL; Figures PP; Statistics AY Discussion, writing: SP, LL, PP, AY.

## References

- Abrams P, Cardozo L, Fall M, et al. The Standardization of Terminology of Lower Urinary Tract Function: Report from the Standardisation Sub-Committee of the International Continence Society. *Neurourol Urodyn.* 2002; 21: 167-178.
- Glazener CMA, Breeman S, Elders S, et al. Mesh, graft, or standard repair for women having primary transvaginal anterior or posterior compartment prolapse surgery: two parallel-group, multicentre, randomised, controlled trials (PROSPECT). *Lancet.* 2016; 389: 381-392.
- DeLancey JO. Anatomic aspects of vaginal eversion after hysterectomy. *Am J Obstet Gynecol.* 1992; 166: 1717-1724.
- Petros PE. New ambulatory surgical methods using an anatomical classification of urinary dysfunction improve stress, urge and abnormal emptying. *Int Urogynecol J Pelvic Floor Dysfunct.* 1997; 8: 270-277.
- Sekiguchi Y, Kinjo M, Maeda Y, Kubota Y. Reinforcement of suspensory ligaments under local anesthesia cures pelvic organ prolapse: 12-month results. *Int Urogynecol J.* 2014; 25: 783-789.
- Shkarupa D, Kubin N, Pisarev A, Zaytseva A, Shapovalova E. The hybrid technique of pelvic organ prolapse treatment: apical sling and subfascial colporrhaphy. *Int Urogynecol J.* 2017; 28: 1407-1413.
- Wagenlehner F, Muller-Funogea I-A, et al. Vaginal apical prolapse repair using two different sling techniques improves chronic pelvic pain, urgency and nocturia – a multicentre study of 1420 patients. *Pelvipereineology.* 2016; 35: 99-104.
- Liedl B, Inoue H, Sekiguchi Y, et al. Is overactive bladder in the female surgically curable by ligament repair? *Cent European J Urol.* 2017; 70: 53-59.
- Inoue H, Kohata Y, Fukuda T, et al. Repair of damaged ligaments with tissue fixation system minisling is sufficient to cure major prolapse in all three compartments: 5-year data *J Obstet Gynaecol Res.* 2017; 43: 1570-1577.
- Ulmsten U, Petros P. Intravaginal slingplasty (IVS): an ambulatory surgical procedure for treatment of female

- urinary incontinence. *Scand J Urol Nephrol*. 1995; 29: 75-82.
11. Petros PE, Ulmsten U, Papadimitriou J. The Autogenic Neoligament procedure: A technique for planned formation of an artificial neo-ligament. *Acta Obstet Gynecol Scand Suppl*. 1990; 153: 43-51.
  12. Petros PE, Ulmsten U. An Integral Theory of female urinary incontinence. *Acta Obstet Gynecol Scand Suppl*. 1990; 69: 1-79.
  13. Yamada H. Aging rate for the strength of human organs and tissues. *Strength of Biological Materials*, Williams & Wilkins Co, Balt. (ed) Evans FG. 1970; pp. 272-280.
  14. Fothergill WE. Pathology & the operative treatment of displacements of the pelvic viscera. *BJOG*. 1907; 13: 410-419.
  15. Miyake M, Takeda N, Fukunaga M. Urinary excretion of type I collagen crosslinked N-telopeptides in Healthy Japanese adults: Age- and sex-related changes and reference. *Bone*. 1995; 17: 335-339.
  16. Petros PEP, Liedl B, Gold D. Should surgeons continue to implant mesh sheets behind the vagina? *Int Urogynecol J*. 2018; 29: 777-779.
  17. Goeschen K, Müller-Funogea A, Petros P. Tethered vagina syndrome: cure of severe involuntary urinary loss by skin graft to the bladder neck area of vagina. *Pelvipерineology*. 2010; 29: 100-102.
  18. Wu Q, Luo L. Petros PEP. Case report: Mechanical support of the posterior fornix relieved urgency and suburethral tenderness. *Pelvipерineology*. 2013; 32: 55-56.
  19. Liedl B, Inoue H, Sekiguchi Y, Darren Gold, et al. Update of the Integral Theory and System for Management of Pelvic Floor Dysfunction in Females *European J of Urology EURSUP-738*. *Eur Urol Suppl*. 2018; 17: 100-108.
  20. Nilsson CG, Palva K, Aarnio R, et al. Seventeen years' follow-up of the tension-free vaginal tape procedure for female stress urinary incontinence. *Int Urogynecol J*. 2013; 24: 1265-1269. ■