

Clinical Outcomes After Medial Patellofemoral Ligament Reconstruction With Suture Fixation of the Gracilis Tendon via Transosseous Tunnels

Hangzhou Zhang,^{*†} Mao Ye,[†] MD, and Qingwei Liang,[†] MD

Investigation performed at the Department of Orthopaedics, Joint Surgery, and Sports Medicine, The First Affiliated Hospital of China Medical University, Shenyang, People's Republic of China

Background: Several fixation methods have been introduced in medial patellofemoral ligament (MPFL) reconstruction. However, the optimal management of patients with recurrent patellar dislocation remains controversial.

Purpose: To present a case series with a minimum 2-year follow-up of 29 patients with recurrent patellar dislocation who underwent a new transosseous suture fixation technique for MPFL reconstruction.

Study Design: Case series; Level of evidence, 4.

Methods: From January 2014 through February 2016, a total of 29 patients with recurrent patellar dislocation for which the MPFL was reconstructed with transosseous suture patellar fixation were studied. All patients were available for follow-up (mean, 37.52 months; range, 26-48 months). The patellar attachment was fixed by transosseous patellar sutures. The International Knee Documentation Committee (IKDC) subjective knee score, Kujala score, Tegner score, range of motion, congruence angle, patellar tilt angle, and complications were assessed both pre- and postoperatively.

Results: No recurrent dislocation was observed in any of the 29 patients for a minimum of 2 years. All outcome scores improved significantly from preoperatively to postoperatively: the average IKDC subjective knee evaluation score from 53 to 87, Kujala from 54 to 90, Lysholm from 50 to 89, and Tegner from 3 to 5 ($P < .001$ for all). The congruence angle significantly decreased from 22° preoperatively to -3° postoperatively, and the patellar tilt angle (Merchant) decreased from 23° preoperatively to 5° postoperatively ($P < .001$ for both). In total, 25 patients (25/29; 86.21%) were completely pain-free when performing activities of daily living at the last follow-up, and 27 patients (93.1%) rated themselves as very satisfied or satisfied with the results.

Conclusion: In patients with chronic recurrent patellar dislocation, transosseous patellar suture fixation for MPFL reconstruction can significantly improve patellar stability and achieve good results at short-term follow-up.

Keywords: patellar instability; MPFL reconstruction; transosseous suture fixation; patellar fracture

*Address correspondence to Hangzhou Zhang, Department of Orthopaedics, Joint Surgery, and Sports Medicine, First Affiliated Hospital of China Medical University, 155 Nanjing North Street, Shenyang 110001, Liaoning Province, People's Republic of China (email: zhanghz1000@sina.com).

[†]Department of Orthopaedics, Joint Surgery, and Sports Medicine, First Affiliated Hospital of China Medical University, Shenyang, People's Republic of China.

Final revision submitted August 29, 2019; accepted October 10, 2019.

The authors declared that there are no conflicts of interest in the authorship and publication of this contribution. AOSSM checks author disclosures against the Open Payments Database (OPD). AOSSM has not conducted an independent investigation on the OPD and disclaims any liability or responsibility relating thereto.

Ethical approval for this study was obtained from the First Affiliated Hospital of China Medical University (2017-114-2).

The Orthopaedic Journal of Sports Medicine, 8(2), 2325967119900373

DOI: 10.1177/2325967119900373

© The Author(s) 2020

The medial patellofemoral ligament (MPFL) is the primary restraint for lateral patellar translation, and the ligament is almost always torn in cases of patellar dislocation.^{1,5,6} MPFL reconstruction is an effective treatment for preventing dislocation or persistent patellar instability.^{3,6,17,26,28,30} Several different surgical techniques for MPFL reconstruction have been described[‡]; most of these techniques use bone tunnels,^{4,11,12,18,21,23,31} interference screws,^{9,25} or anchors for graft fixation of the patella.^{8,10,13-16,27,29} No clinical evidence is available to support one technique over another, but some disadvantages have been detected from the clinical results, such as nonanatomic MPFL reconstruction, exorbitant charges, and postoperative complications (recurrent instability, patellofemoral pain, patellar

[‡]References 2, 4, 7, 9-12, 14, 16, 18, 23, 27, 31.

fractures, and loss of flexion). In particular, passing the reconstructed tendon graft through the patellar tunnels presents an unacceptably high risk of postoperative patellar fractures after MPFL reconstruction due to the use of transverse patellar tunnels.^{4,13,18,21,28,31}

The transosseous suture technique is commonly used as an implant-free technique to repair ruptures of the patellar tendon or quadriceps tendon. The first description in the English-language literature of transosseous sutures for MPFL reconstruction was reported in 2009 by Ahmad et al¹ (who used the plus Bio-Tenodesis screw to fix the graft at the patellar site). In the past decade, however, no clinical studies describing the use of transosseous sutures for MPFL reconstruction have been conducted.

Herein, present results with a minimum 2-year follow-up of patients with recurrent patellar dislocation who underwent MPFL reconstruction with the transosseous suture fixation technique. We hypothesized that patellar stability would be restored after MPFL reconstruction with this technique.

METHODS

This study was approved by the ethics committee of our hospital. Informed consent was obtained from each patient enrolled in this study.

Between January 2014 and February 2016, a total of 32 patients underwent MPFL reconstruction for recurrent patellar dislocation. We excluded 2 patients with increased tibial tuberosity–trochlear groove (TT-TG) distances (>20 mm) because additional TT transfer was performed in these 2 patients. In 1 patient with a valgus deformity of the knee, an additional high tibial osteotomy was performed, and this patient was also excluded. The resulting cohort consisted of 29 patients: 21 females and 8 males. The inclusion criteria were symptomatic patients who had experienced at minimum 2 lateral patellar dislocations and episodes of recurrent subluxation, had no other anatomic risk factors, and had a minimal postoperative follow-up of 2 years. The exclusion criteria were as follows: (1) requirement for tibial tubercle osteotomy, (2) active infection, (3) malignancy, (4) TT-TG greater than 20 mm, (5) severe trochlear dysplasia (Dejour type B to D), (6) patellofemoral chondral injuries of grade III or IV, (7) patella alta (Insall-Salvati ratio >1.2), (8) skeletal immaturity, and (9) previous surgery on the affected knee. Patient demographics are listed in Table 1. No patients were lost during follow-up.

Preoperatively, examination, radiography, and magnetic resonance imaging (MRI) were performed to confirm the diagnosis of lateral patellar instability and to identify the location and extent of the MPFL injury.

Surgical Technique

Figure 1 illustrates the MPFL reconstruction technique using transosseous patellar tunnels with gracilis tendon suture fixation. Arthroscopic investigation was routinely performed to evaluate and address any intra-articular lesions in the knee. A lateral retinacular release was

TABLE 1
Patient Demographics

Variable	Value
Age at time of surgery, y, mean ± SD	27.35 ± 5.81
Follow-up, mo, mean ± SD	37.52 ± 6.52
Male, n	8
Female, n	21
Tibial tuberosity–trochlear groove distance, cm, median ± SD (range)	1.51 ± 0.30 (1.1-2.0)

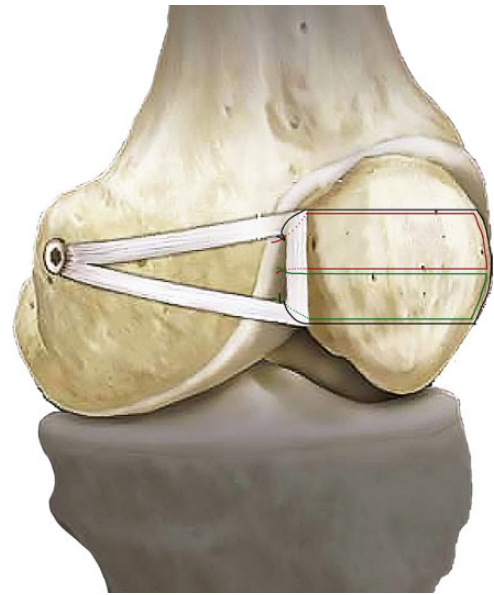


Figure 1. A schematic diagram of the anatomic reconstruction of the medial patellofemoral ligament with the transosseous tunnel repair technique using 3 sutures at the medial border of the patella.

performed on those patients with tight lateral structures through use of a banana knife.

The gracilis autograft tendon was harvested from the patient's ipsilateral leg with a tendon stripper; the 2 free ends of the tendon were sutured with No. 2 Ethibond suture (Ethicon Inc). Then, using a 2- to 3-cm medial parapatellar incision, the surgeon exposed the medial face of the patella. A bony trough was made in the proximal two-thirds of the medial border of the patella with nucleus forceps or rongeurs (Figure 2A). For the transosseous suture technique (Figure 1), 3 transpatellar tunnels were drilled by use of an eyelet-passing pin (1.25-2 mm). First, the superior tunnel was placed near the superior aspect of the medial patellar border, and the inferior tunnel was placed at the proximal two-thirds of the medial patellar border. The central tunnel was drilled last. Guide pins were placed across the patella, parallel to the coronal plane of the patella. Using an eyelet-passing pin, the surgeon then passed three No. 2 FiberWire sutures (Arthrex Inc) subcutaneously through the 3 patellar tunnels as closely as possible to the bone, using surgical

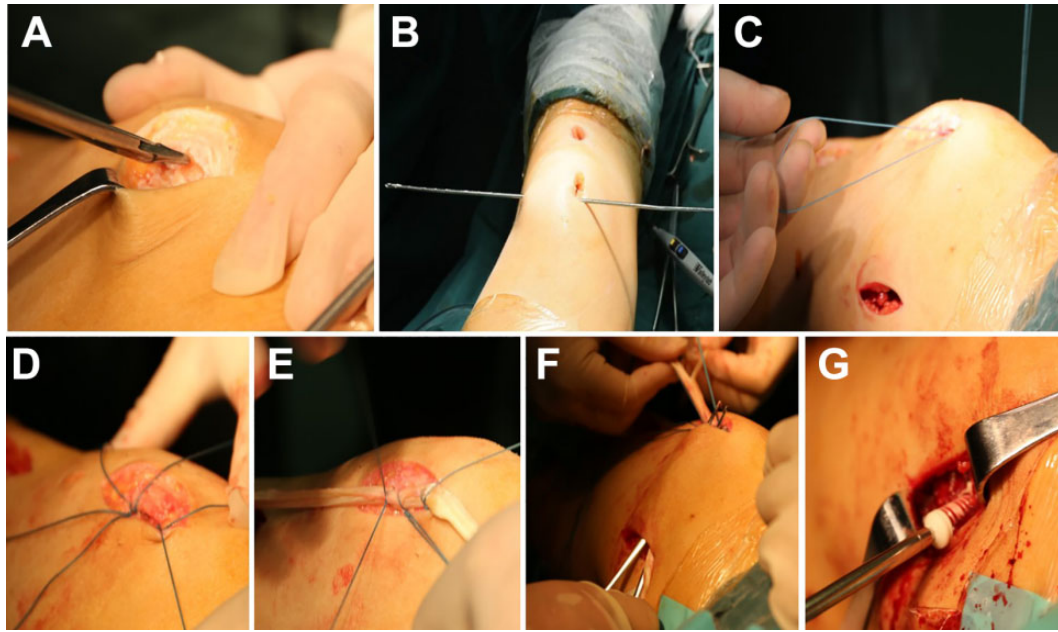


Figure 2. Surgical procedure. (A) A bony trough was made in the proximal two-thirds of the medial border of the patella. (B) An eyelet-passing pin was used to drill transosseous holes placed 8 to 12 mm apart in the medial trough. The transpatellar tunnels were parallel to the coronal plane of the patella. (C) FiberWire sutures were passed through the 3 patellar tunnels. (D, E) The central portion of the autograft was then attached to the bony trough and fixed with sutures tied to the patella. (F) Passage of the transplant. The 2 ends of the graft were passed from the patellar incision to the femoral incision through a soft tissue tunnel in a looped fashion. (G) Femoral fixation. The reconstructed medial patellofemoral ligament was fixed with interference screws in the femoral tunnel.

curved forceps, to exit via the lateral patellar skin incision (Figure 2, B and C), taking care not to disrupt the articular surface and anterior patellar cortex of the patella. The gracilis tendon was laid into the newly created bony trough and fixed with sutures under slight tension to achieve complete tendon-to-bone contact at the site of the medial patellar attachment (Figure 2, C and D).

Another 2- to 3-cm skin incision was made along the adductor magnus tendon. The medial femoral condyle was exposed, and the adductor tubercle was identified. Then, an interval between layers 2 (vastus medialis obliquus) and 3 (capsule) was developed by blunt dissection using a curved clamp, and the graft was passed through this soft tissue tunnel from the patellar incision to the femoral incision in a looped fashion (Figure 2F).

The femoral insertion site was then identified under fluoroscopy as described by Schöttl et al²⁴ on a true lateral knee view (1 mm anterior to the posterior cortex extension line, 2.5 mm distal to the posterior origin of the medial femoral condyle, and proximal to the level of the posterior point of the Blumensaat line), and a guide pin was placed at this site. The guide pin was then overreamed to the femur with a reamer equal to the diameter of the gracilis graft with a depth of approximately 30 mm. The graft ends were passed into the femoral tunnel with the aid of a passing suture via an eyelet-passing pin. Patellar tracking and graft tension were evaluated arthroscopically through the arc of motion. When the lateral patellar edge was positioned in line with

the lateral trochlear border in 30° of flexion, femoral fixation was performed with a bioresorbable interference screw (Milagro; DePuy Mitek) (Figure 2G) with the knee at 30° of flexion. Care was taken not to overstrain the reconstruction, and increased contact pressure in the patellofemoral joint was avoided. The wound was closed in layers.

Postoperative Treatment

A hinged knee brace, used postoperatively, was locked in full extension for the first 2 weeks. Pain and swelling control and leg-raising exercises, as well as quadriceps muscle training, were initiated immediately postoperatively with crutch support. Weightbearing was allowed as tolerated in the knee brace locked in extension beginning at 2 weeks postoperatively. From 2 to 6 weeks, the knee was permitted a 0° to 60° range of motion (ROM). After 6 weeks postoperatively, knee flexion was allowed to reach its full ROM, and the crutches and knee brace could be discontinued. Controlled sports activities were performed from 3 months postoperatively, and full activity was allowed 6 to 12 months postoperatively if patients demonstrated clinical stability.

Evaluation

Patients were evaluated both preoperatively and postoperatively through use of the International Knee Documentation Committee (IKDC) subjective knee score, the Kujala

score, and the Tegner score. ROM and complications were also assessed both preoperatively and postoperatively. A computed tomography (CT) scan of the patient's knee was used to assess the congruence angle and patellar tilt angle (Merchant) preoperatively and postoperatively.⁸ In all patients, trochlear dysplasia was evaluated by MRI. Severe trochlear dysplasia was defined as the presence of a dome-shaped chondral surface of the proximal trochlea on transverse MRI scans. Clinical data also included recurrent subluxation or dislocation at follow-up for all patients. The follow-up evaluations were performed by the same experienced examiner (M.Y.), who was not involved in the treatment of these patients through clinic visits. All patients completed standardized outcome questionnaires and postoperative radiographs at 3, 6, 12, and 24 months and then annually thereafter.

Statistical Analysis

Statistical analysis was performed with SPSS software (SPSS Inc). Paired *t* tests were used to compare preoperative and postoperative values of the ROM, patellar tilt angle, and congruence angle. The Wilcoxon rank test was used to compare preoperative and postoperative IKDC, Kujala, and Tegner scores. Differences of 10 points or more in the subjective IKDC score and Kujala score were deemed clinically important. In all analyses, *P* < .01 indicated a statistically significant difference.

RESULTS

All 29 patients were available for minimum 2-year follow-up (mean, 37.52 months; range, 26-48 months), performed in December 2017. Recurrent dislocation was not observed in any of the patients at the last follow-up. The congruence angle and patellar tilt angle decreased significantly from pre- to postoperatively (*P* < .001 for both). Significant improvements were also noted in the mean IKDC score, Kujala score, and Tegner score (*P* < .001 for all) (Table 2).

Postoperatively, subjective patient assessments revealed that 26 (89.21%) patients were completely pain-free when performing daily life activities, and 27 patients (93.1%) rated themselves as very satisfied or satisfied with the results. The postoperative clinical outcomes after surgery agreed with our hypothesis.

At the December 2017 follow-up, we found that 89.66% of patients had full ROM of the affected knee. We noted that 3 patients had a lack of flexion of 10° to 20° compared with the contralateral normal knee at the last follow-up (the loss of flexion led to relatively lower Kujala scores for these 3 patients: 76, 79, and 81).

No intraoperative complications occurred in our study. We noted that 1 patient had postoperative tenderness on the femoral side at the screw position in the medial femoral condyle within the first 3 months. This patient was treated by a single injection of corticosteroid and ropivacaine; the symptoms improved immediately. Twenty-seven patients (93.1%) rated themselves as very satisfied or satisfied with the results.

TABLE 2
Comparison of Preoperative and Postoperative Outcome Parameters^a

Parameter	Follow-up		<i>P</i>
	Preoperative	December 2017	
Clinical scores			
Kujala	54.24 ± 11.94	89.55 ± 7.03	<.001
IKDC	53.03 ± 10.26	87.41 ± 8.24	<.001
Tegner	3.28 ± 1.07	4.97 ± 1.35	<.001
Radiological evaluation			
Congruence angle, deg	21.69 ± 5.85	-3.36 ± 2.92	<.001
Patellar tilt angle (Merchant), deg	22.97 ± 6.46	4.79 ± 3.86	<.001
Redislocation, %	100	0	—

^aValues are expressed as mean ± SD unless otherwise noted. IKDC, International Knee Documentation Committee score.

DISCUSSION

The most important finding of the present study was that the patellar stability of the knee was restored with our surgical procedure in patients with recurrent patellar dislocation. Most patients had achieved good results of the knee at the December 2017 follow-up. In this study of 29 patients with MPFL reconstruction, no patients experienced redislocation. The CT measurements showed good patellofemoral congruence without any redislocation.

Reconstruction of the MPFL has become a useful procedure for restoring chronic patellar stability.^{2,6,26,28,30} However, the optimal surgical treatment for chronic patellar instability remains controversial. In general, in previous studies, clinical results of these MPFL reconstruction techniques have been mostly favorable (Table 3).

Many authors have introduced bone tunnel techniques that entail looping the reconstructed graft through patellar bone tunnels.^{3,4,9,12,18,21,23,31} However, a specific complication of this technique is the possibility of intraoperative or postoperative patellar fracture, which seems to be related to the use of bone tunnels at the patella acting as stress risers or to the disturbance of the anterior patellar cortex during drilling of the tunnels.^{4,13,18-21,23,31} The diameter of the bone tunnel for these techniques is variable and ranges from 3 to 7.5 mm.^{2,4,9,12,18-21,23,31} In a cadaveric study, Bonazza et al² reported that transosseous patellar tunnels (diameter of 5.5 mm in that study) for MPFL reconstruction that breached the anterior cortex were more likely to fracture during longitudinal load than those that did not breach the anterior cortex. Parikh and Wall²⁰ reported 4 patellar fractures after MPFL reconstruction using patellar bone tunnel techniques. The most important finding of those reports was the high risk of patellar fractures due to the use of transverse patellar tunnels.^{13,18,23,28,31}

The first description in the English-language literature for transosseous sutures for MPFL reconstruction was reported by Ahmad et al¹ (who performed single-bundle MPFL reconstruction). In the current study, we changed our operative technique to use transosseous sutures in the patella rather than looping an autogenous tendon graft

TABLE 3
Literature Review^a

Lead Author	No. of Patients	Patellar Fixation	Graft	Follow-up, mo	Redislocation Rate, %	IKDC Score	Kujala Score
Lippacher ¹¹	72	V-shaped bone tunnel	GT	24.8	2.94	79.8	87.5
Neri ¹⁶	90	Suture anchors	GT	24.3	0	73.9	86.2
Lin ¹⁰	18	Suture anchors	GT	35	0	NR	95.2
Christiansen ⁴	44	Transverse patellar tunnels	GT	22	2.27	NR	84
Matthews ¹²	25	Longitudinal patellar tunnel	GT or ST	31	0	NR	87
Monllau ¹⁴	36	Suture anchors	GT	37.6	0	85	90
Current study	29	Transosseous sutures	GT	37.5	0	87.4	89.6

^aGT, gracilis tendon; IKDC, International Knee Documentation Committee; NR, not reported; ST, semitendinosus tendon.

through 2 transverse bone tunnels or using fixation by suture anchors, so as to reduce the risk of postoperative patellar fracture. In our transosseous suture technique, the diameter of the bone tunnel was not more than 2 mm; thus, we avoided the nonnegligible risk of weakening or even fracturing the patella that is associated with traditional, larger patellar tunnels (3-7.5 mm). The suture anchor fixation technique theoretically has a lower incidence rate of iatrogenic patellar fracture than the traditional bone-tunnel fixation techniques. However, in a cadaveric study, Mountney et al¹⁵ showed that suture anchors failed at a mean load of 142 N, which is significantly weaker than the failure load of the native MPFL (208 N). From a biomechanical point of view, patellar fixation with transosseous sutures is stronger than suture anchor fixation, interference screws, and transverse tunnels.^{22,31} This technique may reduce the risk of intraoperative or postoperative patellar fracture.

This study had the following strengths: First, the transosseous suture technique for MPFL reconstruction allows placement in tunnels with smaller diameters than traditional patellar tunnel techniques, preserving more bone, and theoretically minimizes the risk of patellar fracture. Second, the remarkable advantage of the transosseous suture technique for MPFL reconstruction is cost, which is far lower than the cost of suture anchors or other devices, such as suspension buttons, biodegradable screws, and metallic anchors. At our institution, the cost for 2 suture anchors for suture MPFL reconstruction is approximately US\$800. The transosseous suture technique requires three No. 2 FiberWire sutures at a cost of approximately US\$100.

This study has several limitations. First, we included only 29 patients with short-term clinical results after MPFL reconstruction. Future studies should include more patients with long-term clinical outcomes after MPFL reconstruction for chronic patellar instability. Second, inherent limitations of the study included the lack of a control group (eg, other MPFL reconstructive techniques). In future work, we will add a control group (such as a suture anchor group).

CONCLUSION

The results of this study suggest that transosseous patellar suture fixation for MPFL reconstruction is easy and effective and provides good results.

REFERENCES

- Ahmad CS, Brown GD, Shubin Stein BE. The docking technique for medial patellofemoral ligament reconstruction: surgical technique and clinical outcome. *Am J Sports Med.* 2009;37(10):2021-2027.
- Bonazza NA, Lewis GS, Lukosius EZ, et al. Effect of transosseous tunnels on patella fracture risk after medial patellofemoral ligament reconstruction: a cadaveric study. *Arthroscopy.* 2018;34(2):513-518.
- Buckens CFM, Saris DBF. Reconstruction of the medial patellofemoral ligament for treatment of patellofemoral instability: a systematic review. *Am J Sports Med.* 2010;38:181-188.
- Christiansen SE, Jacobsen BW, Lund B, et al. Reconstruction of the medial patellofemoral ligament with gracilis tendon autograft in transverse patellar drill holes. *Arthroscopy.* 2008;24:82-87.
- Conlan T, Garth WP Jr, Lemons JE. Evaluation of the medial soft-tissue restraints of the extensor mechanism of the knee. *J Bone Joint Surg Am.* 1993;75:682-693.
- Fithian DC, Paxton EW, Stone ML, et al. Epidemiology and natural history of acute patellar dislocation. *Am J Sports Med.* 2004;32:1114-1121.
- Hapa O, Akşahin E, Özden R, et al. Aperture fixation instead of transverse tunnels at the patella for medial patellofemoral ligament reconstruction. *Knee Surg Sports Traumatol Arthrosc.* 2012;20:322-326.
- Inoue M, Shino K, Hirose H, Horibe S, Ono K. Subluxation of the patella: computed tomography analysis of patellofemoral congruence. *J Bone Joint Surg Am.* 1988;70(9):1331-1337.
- Lenschow S, Schliemann B, Gestring J, et al. Medial patellofemoral ligament reconstruction: fixation strength of 5 different techniques for graft fixation at the patella. *Arthroscopy.* 2013;29:766-773.
- Lin KY, Lu YC, Renn JH. The double-pulley technique for anatomical double-bundled medial patellofemoral ligament reconstruction. *Injury.* 2015;46:1619-1624.
- Lippacher S, Dreyhaupt J, Williams SR, et al. Reconstruction of the medial patellofemoral ligament: clinical outcomes and return to sports. *Am J Sports Med.* 2014;42:1661-1668.
- Matthews JJ, Schranz P. Reconstruction of the medial patellofemoral ligament using a longitudinal patellar tunnel technique. *Int Orthop.* 2010;34:1321-1325.
- Mikashima Y, Kimura M, Kobayashi Y, et al. Clinical results of isolated reconstruction of the medial patellofemoral ligament for recurrent dislocation and subluxation of the patella. *Acta Orthop Belg.* 2006;72:65-71.
- Monllau JC, Masferrer-Pino À, Ginovart G, et al. Clinical and radiological outcomes after a quasi-anatomical reconstruction of medial patellofemoral ligament with gracilis tendon autograft. *Knee Surg Sports Traumatol Arthrosc.* 2017;25:2453-2459.
- Mountney J, Senavongse W, Amis AA, et al. Tensile strength of the medial patellofemoral ligament before and after repair or reconstruction. *J Bone Joint Surg Br.* 2005;87:36-40.

16. Neri T, Philippot R, Carnesecchi O, et al. Medial patellofemoral ligament reconstruction: clinical and radiographic results in a series of 90 cases. *Orthop Traumatol Surg Res.* 2015;101:65-69.
17. Nomura E, Inoue M, Osada N. Anatomical analysis of the medial patellofemoral ligament of the knee, especially the femoral attachment. *Knee Surg Sports Traumatol Arthrosc.* 2005;13:510-515.
18. Panni AS, Alam M, Cerciello S, et al. Medial patellofemoral ligament reconstruction with a divergent patellar transverse 2-tunnel technique. *Am J Sports Med.* 2011;39:2647-2655.
19. Parikh SN, Nathan ST, Wall EJ, et al. Complications of medial patellofemoral ligament reconstruction in young patients. *Am J Sports Med.* 2013;41:1030-1038.
20. Parikh SN, Wall EJ. Patellar fracture after medial patellofemoral ligament surgery: a report of five cases. *J Bone Joint Surg Am.* 2011;93:e97.
21. Ronga M, Oliva F, Longo UG, et al. Isolated medial patellofemoral ligament reconstruction for recurrent patellar dislocation. *Am J Sports Med.* 2009;37:1735-1742.
22. Russ SD, Tompkins M, Nuckley D, et al. Biomechanical comparison of patellar fixation techniques in medial patellofemoral ligament reconstruction. *Am J Sports Med.* 2015;43:195-199.
23. Schiphouwer L, Rood A, Tigchelaar S, et al. Complications of medial patellofemoral ligament reconstruction using two transverse patellar tunnels. *Knee Surg Sports Traumatol Arthrosc.* 2017;25:245-250.
24. Schöttle PB, Fucentese SF, Romero J. Clinical and radiological outcome of medial patellofemoral ligament reconstruction with a semitendinosus autograft for patella instability. *Knee Surg Sports Traumatol Arthrosc.* 2005;13:516-521.
25. Schöttle PB, Hensler D, Imhoff AB. Anatomical double-bundle MPFL reconstruction with an aperture fixation. *Knee Surg Sports Traumatol Arthrosc.* 2010;18:147-151.
26. Schöttle PB, Schmeling A, Romero J, et al. Anatomical reconstruction of the medial patellofemoral ligament using a free gracilis autograft. *Arch Orthop Trauma Surg.* 2009;129:305-309.
27. Schöttle PB, Schmeling A, Rosenstiel N, et al. Radiographic landmarks for femoral tunnel placement in medial patellofemoral ligament reconstruction. *Am J Sports Med.* 2007;35:801-804.
28. Shah JN, Howard JS, Flanigan DC, et al. A systematic review of complications and failures associated with medial patellofemoral ligament reconstruction for recurrent patellar dislocation. *Am J Sports Med.* 2012;40:1916-1923.
29. Song SY, Kim IS, Chang HG, et al. Anatomic medial patellofemoral ligament reconstruction using patellar suture anchor fixation for recurrent patellar instability. *Knee Surg Sports Traumatol Arthrosc.* 2014;22:2431-2437.
30. Stephen JM, Kaider D, Lumpaopong P, et al. The effect of femoral tunnel position and graft tension on patellar contact mechanics and kinematics after medial patellofemoral ligament reconstruction. *Am J Sports Med.* 2014;42:364-372.
31. Thaanat M, Erasmus PJ. Recurrent patellar dislocation after medial patellofemoral ligament reconstruction. *Knee Surg Sports Traumatol Arthrosc.* 2008;16:40-43.