

Prevalence of Os Acromiale in Thai Patients With Shoulder Problems

A Magnetic Resonance Imaging Study

Peemawat Phanichwong,* MS, Adinun Apivatgaroon,*[†] MD, and Waraporn Srikhum Boonsaeng,[‡] MD

Investigation performed at Thammasat University, Khlong Nueng, Thailand

Background: Os acromiale is an anatomic variant in which the acromial ossification center fails to fuse. It may lead to painful shoulder conditions and surgical intervention may be required for treatment. The prevalence of os acromiale in South Koreans (0.7%) has previously been the representative number for the Asian population, and it is lower than that in the Black and White populations.

Purpose: To determine the prevalence of os acromiale in Thai patients with shoulder disabilities who underwent magnetic resonance imaging (MRI).

Study Design: Cross-sectional study; Level of evidence, 3.

Methods: We retrospectively reviewed the MRI scans of patients with shoulder disabilities between January 2019 and May 2021 at a single institution. The relationship of sex, age, and shoulder diagnosis to the presence of os acromiale was then analyzed.

Results: A total of 940 MRI scans in 848 patients were evaluated, of which 20 shoulders were detected to have os acromiale, a prevalence of 2.13%. The mean age of the patients was 60.25 years, with 60% being female and 40% male. Of the 20 os acromiale cases, 17 (85%) were preacromiale, 1 (5%) mesoacromiale, and 2 (10%) meta-acromiale. The associated diagnoses were as follows: 75%, full-thickness rotator cuff (RC) tear; 10%, partial-thickness RC tear; 5%, RC tendinopathy with symptomatic os acromiale; 5%, anterior shoulder instability with full-thickness RC tear; and 5%, frozen shoulder. Age, sex, and associated shoulder disability were not associated with the presence of os acromiale.

Conclusion: In Thai patients with shoulder problems who required MRI evaluation, the prevalence of os acromiale was 2.13%. This is lower than the prevalence from other ethnic groups but slightly higher than that from the same ethnic group (Korea). There was no relation between the presence of os acromiale and shoulder pain, regardless of diagnosis.

Keywords: os acromiale; shoulder pain; prevalence; MRI shoulder

Os acromiale is an anatomic variant of the shoulder in which any of the ossification centers of the acromion fail to fuse.^{6,11} It can occur naturally in any population, and it can cause pain at the unfused site. When the patient has shoulder pain and/or tenderness at the os acromiale, the condition is known as symptomatic or painful os acromiale syndrome, and surgical intervention may be required as a form of treatment.^{9,19} The clinical importance of os acromiale is its correlation with rotator cuff (RC)-related pain, as it theoretically increases subacromial motion and impingement owing to the mobility of the unfused fragments. Os acromiale may also increase the risk of RC tear,^{2,9,20} although this correlation is still controversial.^{17,22}

Os acromiale occurs when the acromion process is detached from the body of the scapula because the apophyses failed to fuse with the basiacromion. The condition can be separated into 3 subgroups based on the location of the lesion: preacromion, mesoacromion, and meta-acromion (Figure 1).^{8,11} The diagnosis of os acromiale requires an imaging modality to visualize the lesion, including plain radiographs of the shoulder (anteroposterior, supraspinatus outlet, and transaxillary views), magnetic resonance imaging (MRI), and computed tomography (CT). The latter 2 options could be done in adjunct to plain radiographs to help identify the presence of os acromiale. MRI and CT are favorable imaging options to help identify associated underlying shoulder pathologies because of their ability to extensively view shoulder anatomy. Some studies^{14,18} consider MRI to be the gold standard technique to identify the presence of os acromiale.

The Orthopaedic Journal of Sports Medicine, 10(2), 23259671221078806

DOI: 10.1177/23259671221078806

© The Author(s) 2022

This open-access article is published and distributed under the Creative Commons Attribution - NonCommercial - No Derivatives License (<https://creativecommons.org/licenses/by-nc-nd/4.0/>), which permits the noncommercial use, distribution, and reproduction of the article in any medium, provided the original author and source are credited. You may not alter, transform, or build upon this article without the permission of the Author(s). For article reuse guidelines, please visit SAGE's website at <http://www.sagepub.com/journals-permissions>.

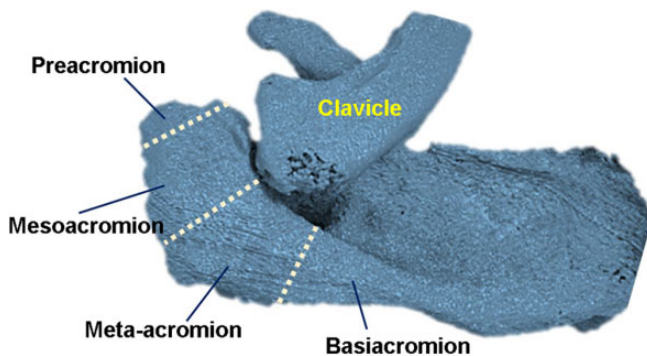


Figure 1. Three-dimensional model of the left shoulder shows the preacromion, mesoacromion, meta-acromion, and basiacromion. A failure of any of the first 3 to fuse to the basiacromion results in an os acromiale.

The prevalence of os acromiale reportedly ranges from 0.7% to 49%,^{10,21} and its presence has been associated with subacromial impingement and RC tear.^{8,10,15,21} Only 0.7% of the Korean population has this anatomic variant.¹⁰ This is lower than in any other population previously studied. Because there is a lack of information about os acromiale in Thai and other Asian populations, we aimed to determine the prevalence of os acromiale in Thai patients with shoulder problems using MRI.

METHODS

All study procedures that involved human participants were performed in accordance with the ethical standards of our institution. We retrospectively reviewed the MRI of patients with shoulder disabilities who presented to Thammasat University Hospital to determine the presence of os acromiale. Imaging was performed between January 2019 and May 2021. The associated shoulder diagnosis and demographic data were collected and evaluated for correlation with the presence of os acromiale.

Inclusion criteria were Thai patients >18 years old who required MRI to investigate their shoulder disability. Exclusion criteria were images with conditions that interfered with the assessment of os acromiale (eg, acromion fractures, severe arthropathy with significant destruction of the acromion, active osteolysis of acromion from tumors or infections, poor-quality MRI, and repeated MRI).

A total of 1024 shoulder MRI scans from 931 patients were analyzed and 84 scans and 83 patients were excluded; therefore, 940 MRI studies from 848 patients were examined. The flowchart of the study is shown in Figure 2.

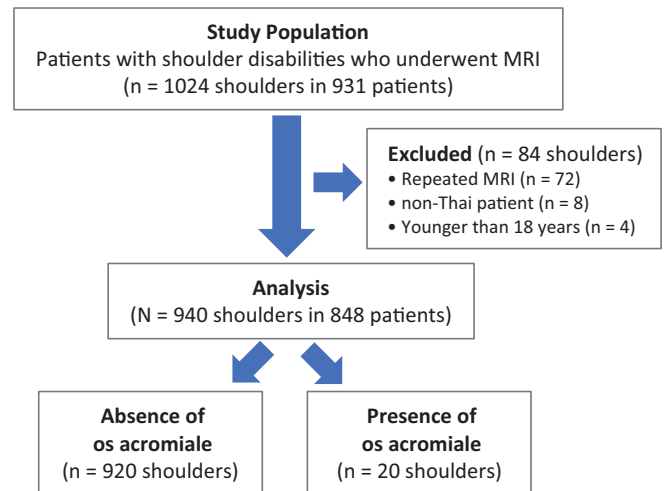


Figure 2. Study flowchart. MRI, magnetic resonance imaging.

Sample Size Calculation

The mobile application n4Studies (Version 1.4.2) was used to find the sample size for this study via an infinite population proportion. The formula and parameters are in reference to a study in which CT scans of the shoulder were performed, showing that 1 in 108 was identified with os acromiale.¹ This translates to a proportion of 0.00925. With this parameter in mind, the minimum sample size for this study was calculated as 609 to be statistically significant.

Data Collection and Evaluation

The process of reviewing the MRI scans required a picture archiving and communication system workstation. Images were based on axial T1-, coronal T2-, and sagittal T1-weighted sequences performed on 1.5- or 3-T magnets to identify the presence of os acromiale. Axial, coronal, and sagittal T2-weighted fat saturation images were also used to evaluate the associated pathology of the shoulder. All MRI scans were systematically reviewed and evaluated by a fellowship-trained sports medicine orthopaedist (A.A.). Information regarding the patient's sex, age, affected side, and associated shoulder diagnosis was obtained from the hospital database. Examples of os acromiale on MRI scans are shown in Figure 3.

The presence of os acromiale was determined by reviewing the patient's history, physical examination, plain radiographs, and MRI. Shoulders with a definite presence of os acromiale and borderline cases were reevaluated both by

[†]Address correspondence to Adinun Apivatgaroon, MD, Department of Orthopedics, Faculty of Medicine, Thammasat University, Khlong Nueng, 12120 Thailand (email: adino_ball@yahoo.com).

^{*}Department of Orthopedics, Faculty of Medicine, Thammasat University, Khlong Nueng, Thailand.

[‡]Department of Radiology, Faculty of Medicine, Thammasat University, Khlong Nueng, Thailand.

Final revision submitted November 10, 2021; accepted November 29, 2021.

The authors declared that there are no conflicts of interest in the authorship and publication of this contribution. AOSSM checks author disclosures against the Open Payments Database (OPD). AOSSM has not conducted an independent investigation on the OPD and disclaims any liability or responsibility relating thereto.

Ethical approval for this study was obtained from the Thammasat University Faculty of Medicine (No. MTU-EC-OT-0-176/64).

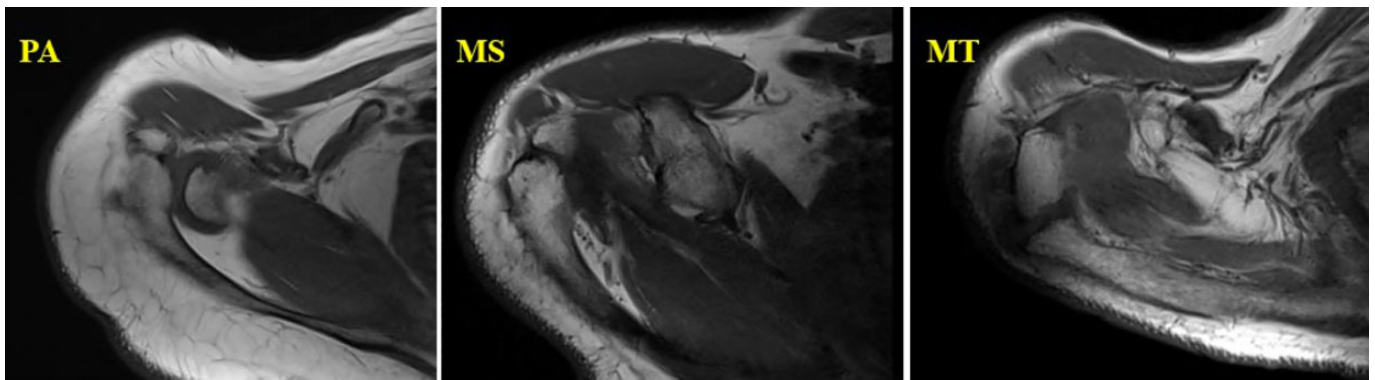


Figure 3. Examples of the 3 types of os acromiale on T1-weighted magnetic resonance imaging of the right shoulder: axial view. MS, mesoacromion; MT, meta-acromion; PA, preacromion.

the previous reviewer and a fellowship-trained musculoskeletal radiologist (W.S.B.), and agreement between the specialists was used as confirmation. The resulting definite cases were then classified into subtypes of os acromiale. Hence, the reliability of the readings depended on 2 factors: the quality of the MRI scans and the level of experience of each practitioner in reading the scans.

Statistical Analysis

The number of cases and the associated shoulder diagnosis are reported in numbers and percentages, while sex and age are reported as mean \pm SD. The relationship between the patient's sex, age, associated diagnosis, and affected side and the presence of os acromiale was evaluated with the Fisher exact test. Using the kappa coefficient (κ),¹² the interrater reliability of the 2 MRI reviewers was calculated from a sample of 450 of the 940 MRI scans, in which $\kappa < 0.00$ was considered poor strength of agreement; 0.00 to 0.20, slight; 0.21 to 0.40, fair; 0.41 to 0.60, moderate; 0.61 to 0.80, substantial; and 0.81 to 1.00, almost perfect. Statistical analysis was conducted using STATA Version 14.2.

RESULTS

The mean age of the study population ($N = 848$) was 60.25 ± 12.67 years, and 20 of the 940 shoulders were determined to have os acromiale. The interrater reliability between the fellowship-trained sports medicine orthopaedist (A.A.) and the fellowship-trained musculoskeletal radiologist (W.S.B.) indicated almost-perfect agreement for determining the presence of os acromiale ($\kappa = 0.859$; $P < .05$).

The 940 shoulders were divided into 10 groups according to their associated diagnoses: shoulder osteoarthritis, RC-related pain, instability and labral injury, frozen shoulder, acromioclavicular joint arthritis, calcific tendinitis, trauma to the shoulders, infection and inflammation around the shoulder, tumor-related conditions, and miscellaneous (medial scapular wing, osteonecrosis of humeral head). RC-related pain covered 78.83% of the study population. The affected side was 55% right and 45% left, while the

sex distribution was 61.91% female and 38.09% male for the entire population. All associated diagnoses are shown in Table 1.

The prevalence of os acromiale in this study population was 2.13% (20 shoulders in 940 shoulders); 17 of 20 (85%) were preacromiale, 1 (5%) mesoacromiale, and 2 (10%) meta-acromiale. The age ($P = .71$), affected side ($P > .99$), and sex ($P = .86$) did not show statistical significance in relation to the presence of os acromiale. The associated shoulder diagnoses in the cases with os acromiale were full-thickness RC tear (75%), partial-thickness RC tear (10%), RC tendinopathy with symptomatic os acromiale (5%), anterior shoulder instability with full-thickness RC tear (5%), and frozen shoulder (5%). Only 1 shoulder in 20 was diagnosed with symptomatic os acromiale, since other possible diagnoses were ruled out and the patient showed significant pain relief after a steroid was injected directly into the os acromiale. Details regarding the associated diagnoses and treatment for these patients are summarized in Table 2. There was no association between the presence of os acromiale and shoulder disability, regardless of the diagnosis ($P > .99$ [Fisher exact test]; Cramer $V = 0.05$).

DISCUSSION

The prevalence of os acromiale is different among studies since it depends on the ethnicity of the population and the methodology of the study. Reported prevalence ranges from 0.7% to 49%.^{3-5,7,10,13,16,21} The prevalence of os acromiale in Thailand is relatively low: 2.13% in patients with shoulder symptoms, as found by this MRI analytic study. With the prevalence determined from previous studies of other East Asian population, this research proves that the prevalence of os acromiale in an Asian population is lower than in other ethnicities—for example, 0.7% in South Korea¹⁰ (plain radiographs with or without MRI) and 0.9% in Thailand¹ (plain radiographs with 3-dimensional CT). Literature examination regarding the prevalence of os acromiale across various population is summarized in Table 3.

TABLE 1
Associated Diagnoses for All Shoulders (N = 940)^a

Associated Diagnosis	No. or No. (%)	No. With Os Acromiale
Shoulder OA	30 (3.19)	0
OA shoulder	13	0
OA with RC tear	2	0
OA with partial RC tear	6	0
Second OA shoulder	9	0
RC-related pain	741 (78.83)	18
RC syndrome, subacromial/subdeltoid bursitis	103	0
Partial-thickness RC tear	324	2
Full-thickness RC tear	313	15
RC syndrome with symptomatic os acromiale	1	1
Instability and labral injury	54 (5.74)	1
Anterior shoulder instability	31	0
Anterior shoulder instability and RC tear	1	1
Labral injury	1	0
Lock anterior shoulder dislocation	4	0
Posterior shoulder instability	1	0
Multi-directional instability	4	0
SLAP lesion	12	0
Frozen shoulder	39 (4.15)	1
Frozen shoulder	26	1
Frozen shoulder with partial RC tear	13	0
AC joint arthritis	2 (0.21)	0
Calcific tendinitis	16 (1.7)	0
Shoulder trauma	16 (1.7)	0
High-grade AC joint injury	4	0
Fracture proximal humerus	1	0
Greater tuberosity fracture nondisplaced	8	0
Proximal humerus fracture with RC tear	2	0
Scapula and glenoid fracture	1	0
Infection and inflammation around the shoulder	23 (2.45)	0
Inflammatory arthritis/synovitis	12	0
Rheumatoid arthritis	2	0
Pyomyositis	2	0
Septic shoulder	6	0
Chronic osteomyelitis of scapular body	1	0
Tumor-related conditions	16 (1.7)	0
Bone tumor of proximal humerus	2	0
Metastasis of proximal humerus	1	0
Soft tissue mass around the shoulder	13	0
Miscellaneous	3 (0.32)	0
Medial scapular wing	2	0
Osteonecrosis of humeral head	1	0
Total	940 (100)	20

^aAC, acromioclavicular; OA, osteoarthritis; RC, rotator cuff; SLAP, superior labrum anterior to posterior.

In terms of the diagnosis in relation to the presence of os acromiale, the RC-related pain group (90%) had the highest proportion vs the others (shoulder instability, 5%; frozen shoulder, 5%), but there was no statistical significance as

suggested by Fisher exact analysis. This finding is in agreement with other studies.^{1,10,15} Moreover, in patients with RC-related pain, only 1 out of nearly a thousand had been diagnosed with symptomatic os acromiale by the history of pain at the acromial region and marked tenderness at the unfused acromion, with the presence of os acromiale in the transaxillary radiograph and MRI scans. This patient required intervention to manage the painful symptoms. These findings suggest that os acromiale is rarely problematic.

Previous studies mainly used skeletal specimens and radiographic evaluation to detect os acromiale; however, with access to advanced imaging modalities, this study used MRI for detection since it is deemed the more reliable method. Nevertheless, despite using arguably the most sensitive modality for detection, the prevalence of os acromiale is still relatively low. This study's prevalence is similar to that from an MRI study in Italy, which had a 3.4% prevalence of os acromiale.¹⁵

Similar to other studies, the sex and affected side were not related to the presence of os acromiale.^{10,15} In this study, only 3 of 20 patients with os acromiale had MRI performed for both shoulders. Since these data are minimal, the presence of bilaterality of os acromiale could not be determined.

The proportion of os acromiale types showed 85% pre-acromiale, 5% mesoacromiale, and 10% meta-acromiale. This finding is different from many studies since they generally had lesser proportions of preacromion morphology.^{10,15,21} Ossification of the coracoacromial ligament and fracture of the acromial spur may lead to misdiagnosis because they can appear to mimic os acromiale. Initially for this study, a fellowship-trained sports medicine orthopaedist (A.A.) reviewed all the MRI scans and reported that 15 shoulders were detected with os acromiale while 14 shoulders were still undetermined. Subsequently, all 29 shoulder MRI scans were reviewed again with the assistance of a fellowship-trained musculoskeletal radiologist who had 10 years of experience in this field (W.S.B.). The reviewers agreed to rule out 9 of the 29 cases since they were deemed to have ossification of the coracoacromial ligament rather than true os acromiale, concluding that 20 of the 29 cases truly had os acromiale. In the current study, the interrater reliability of os acromiale detection indicated almost-perfect agreement ($\kappa = 0.859$) between the reviewers.

There are limitations to this study. First, the retrospective nature may increase the chance of bias. Second, all MRI scans were initially assessed by a single reviewer, who selected the possible cases to be reevaluated by the first reviewer (orthopaedist) and another experienced radiologist. In some cases, it was difficult to differentiate between ossified coracoacromial ligament and os acromiale; therefore, agreement was based on verbal discussion between the reviewers, which can be subjective. Finally, the MRI studies had selection bias since only the patients with shoulder problems required MRI for investigation, meaning that the study population does not represent the general population.

TABLE 2
Treatment Details of the Patients With Os Acromiale^a

No.	Sex	Age, y	Type	Side	Associated Diagnosis	Treatment
1	M	59	PA	L	Medium full-thickness RC tear	Nonoperative
2	F	62	PA	L	Small full-thickness RC tear	Nonoperative
3	M	84	PA	L	Massive full-thickness RC tear	Nonoperative
4	F	63	PA	R	Partial-thickness RC tear, low grade, bursal side	Nonoperative
5	F	67	PA	R	Medium full-thickness RC tear	RC repair
6	M	67	PA	L	Massive full-thickness RC tear	Nonoperative
7	M	74	PA	L	Massive full-thickness RC tear	Nonoperative
8	F	63	PA	R	Massive full-thickness RC tear	Schedule for RTSA
9	F	67	PA	L	Large full-thickness RC tear	Nonoperative
10	F	62	PA	R	Medium full-thickness RC tear	RC repair
11	F	63	PA	L	Massive full-thickness RC tear	Nonoperative
12	F	48	PA	R	Frozen shoulder	Nonoperative
13	F	68	PA	R	Massive full-thickness RC tear	RTSA
14	F	69	PA	R	Small full-thickness RC tear	Nonoperative
15	F	54	PA	L	Partial-thickness RC tear, low grade, articular side	Nonoperative
16	M	72	PA	R	Large full-thickness RC tear	Nonoperative
17	M	63	PA	R	Anterior shoulder instability with small full-thickness RC tear	Bankart repair and RC repair
18	M	67	MS	R	Medium full-thickness RC tear	Schedule for RC repair
19	F	57	MT	L	RC syndrome with symptomatic os acromiale	Steroid injection into os acromiale
20	M	73	MT	R	Massive full-thickness RC tear	Nonoperative

^aF, female; L, left; M, male; MS, mesoacromion; MT, meta-acromion; PA, preacromion; R, right; RC, rotator cuff; RTSA, reverse total shoulder arthroplasty.

TABLE 3
Studies Examining the Prevalence of Os Acromiale Across Various Ethnic Populations^a

Study (Year)	Population	Methodology	Sample Size	Os Acromiale, %
Grasso (1992) ⁷	Italian	Radiographs and CT	398	9.5
Edelson (1993) ⁶	Israeli	Skeletal specimens	270	8.2
Nicholson (1996) ¹³	Black and White	Skeletal specimens	210	8.0
Sammarco (2000) ¹⁶	Black: White	Skeletal specimens	355:843	13.2: 5.8
Case (2006) ⁴	Danish: South African	Skeletal specimens	532:494	7.7: 18.2
Coskun (2006) ⁵	Turkish	Skeletal specimens and radiographs	90	1.0
Burbank (2007) ³	Not described	Radiographs	93	6.5
Kumar (2013) ¹⁰	Korean	Radiographs and MRI (some cases)	1568	0.7
Rovesta (2017) ¹⁵	Italian	MRI	1042	3.4
Apivatgaroon (2020) ¹	Thai	Radiographs and 3D-CT	108	0.9
Present study	Thai	MRI	940	2.13

^a3D, 3-dimensional; CT, computed tomography; MRI, magnetic resonance imaging.

CONCLUSION

The findings of the current study indicated that in Thai patients with shoulder problems who required MRI evaluation, the prevalence of os acromiale was 2.13%. This is lower than the prevalence of the general population from other ethnic groups but slightly higher than that from the same ethnic group (Korea). There was no relation between the presence of os acromiale and shoulder pain, regardless of diagnosis.

ACKNOWLEDGMENT

The authors thank the Department of Orthopaedics, Faculty of Medicine, Thammasat University, and Thammasat University Hospital, for the kind support.

REFERENCES

1. Apivatgaroon A, Tharakulphan S, Kongmalai P, Chernchujit B. The acromion in supraspinatus outlet and Rockwood caudal tilt views from three-dimensional computed tomography scan of the shoulder. *Asia Pac J Sports Med Arthrosc Rehabil Technol.* 2020;20:12-16.
2. Boehm TD, Rolf O, Martetschlaeger F, Kenn W, Gohlke F. Rotator cuff tears associated with os acromiale. *Acta Orthop.* 2005;76(2):241-244.
3. Burbank KM, Lemos MJ, Bell G, Lemos DW. Incidence of os acromiale in patients with shoulder pain. *Am J Orthop (Belle Mead NJ).* 2007;36:153-155.
4. Case DT, Burnett SE, Nielsen T. Os acromiale: population differences and their etiological significance. *Homo.* 2006;57(1):1-18.
5. Coskun N, Karaali K, Cevikol C, Demirel BM, Sindel M. Anatomical basics and variations of the scapula in Turkish adults. *Saudi Med J.* 2006;27(9):1320-1325.
6. Edelson JG, Zuckerman J, Hershkovitz I. Os acromiale: anatomy and surgical implications. *J Bone Joint Surg Br.* 1993;75(4):551-555.

7. Grasso A. The incidence and role of the os acromiale in the acromiohumeral impingement syndrome. *Radiol Med*. 1992;84(5):567-570.
8. Hurst SA, Gregory TM, Reilly P. Os acromiale: a review of its incidence, pathophysiology, and clinical management. *EFORT Open Rev*. 2019;4(8):525-532.
9. Hutchinson MR, Veenstra MA. Arthroscopic decompression of shoulder impingement secondary to os acromiale. *Arthroscopy*. 1993;9(1):28-32.
10. Kumar J, Park WH, Kim SH, Lee HI, Yoo JC. The prevalence of os acromiale in Korean patients visiting shoulder clinic. *Clin Orthop Surg*. 2013;5(3):202-208.
11. Macalister A. Notes on acromion. *J Anat Physiol*. 1893;27:1-51.
12. McHugh ML. Interrater reliability: the kappa statistic. *Biochem Med (Zagreb)*. 2012;22(3):276-282.
13. Nicholson GP, Goodman DA, Flatow EL, Bigliani LU. The acromion: morphologic condition and age-related changes. *A study of 420 scapulas*. *J Shoulder Elbow Surg*. 1996;5:1-11.
14. Park JG, Lee JK, Phelps CT. Os acromiale associated with rotator cuff impingement: MR imaging of the shoulder. *Radiology*. 1994;193(1):255-257.
15. Rovesta C, Marongiu MC, Corradini A, Torricelli P, Ligabue G. Os acromiale: frequency and a review of 726 shoulder MRI. *Musculoskeletal Surg*. 2017;101(3):201-205.
16. Sammarco VJ. Os acromiale: frequency, anatomy, and clinical implications. *J Bone Joint Surg Am*. 2000;82:394-400.
17. Spiegl UJ, Millett PJ, Josten C, Hepp P. Optimal management of symptomatic os acromiale: current perspectives. *Orthop Res Rev*. 2018;10:1-7.
18. Uri DS, Kneeland JB, Herzog R. Os acromiale: evaluation of markers for identification on sagittal and coronal oblique MR images. *Skelet Radiol*. 1997;26:31-34.
19. Viner GC, He JK, Brabston EW, Momaya A, Ponce BA. Os acromiale: systematic review of surgical outcomes. *J Shoulder Elbow Surg*. 2020;29(2):402-410.
20. Wright RW, Heller MA, Quick DC, Buss DD. Arthroscopic decompression for impingement syndrome secondary to an unstable os acromiale. *Arthroscopy*. 2000;16(6):595-599.
21. Yammine K. The prevalence of os acromiale: a systematic review and meta-analysis. *Clin Anat*. 2014;27(4):610-621.
22. You T, Frostick S, Zhang WT, Yin Q. Os acromiale: reviews and current perspectives. *Orthop Surg*. 2019;11(5):738-744.