

Received: 2015.08.05
Accepted: 2015.10.13
Published: 2016.01.11

ISSN 1941-5923
© Am J Case Rep, 2016; 17: 18-22
DOI: 10.12659/AJCR.895560

The Forgotten One: Lemierre's Syndrome Due to Gram-Negative Rods *Prevotella* Bacteremia

Authors' Contribution:
Study Design A
Data Collection B
Statistical Analysis C
Data Interpretation D
Manuscript Preparation E
Literature Search F
Funds Collection G

A **Priyanka Wani**
B **Nishaal Antony**
B **Miraie Wardi**
F **Carlos E. Rodriguez-Castro**
E **Mohamed Teleb**

Department of Internal Medicine, Paul L. Foster School of Medicine, Texas Tech University Health Science Center, El Paso, Texas, U.S.A.

Corresponding Author: Mohamed Teleb, e-mail: mohamed.teleb@ttuhsc.edu
Conflict of interest: None declared

Patient: Male, 22
Final Diagnosis: Lemierre's syndrome
Symptoms: Dyspnea • chest pain • swelling
Medication: —
Clinical Procedure: Thoracentesis
Specialty: Infectious Diseases

Objective: Rare co-existence of disease or pathology

Background: Lemierre's syndrome (LS) is a rare syndrome caused by an acute oropharyngeal infection with metastatic spreading. It was described in 1939 as jugular vein septic thrombophlebitis associated with retropharyngeal infection. Different organisms can cause LS, such as *Fusobacterium* species, *Peptostreptococcus*, group B and C, *Streptococcus*, *Staphylococcus*, and *Enterococcus* species, but the most commonly isolated pathogen is *Fusobacterium necrophorum*, a common oral flora. Management depends on the initial presentation, type of pathogen isolated, and proper selection of antibiotics.

Case Report: We report a case of a 22-year-old man with no past medical history, who presented with left jaw pain and progressive left facial area swelling associated with dyspnea. A final diagnosis of LS was made based on criteria of computed tomography (CT) of the neck and the clinical symptoms. The patient was started on broad-spectrum antibiotics. Subsequent imaging of the chest showed pleural effusion with septic emboli. He underwent thoracentesis and chest tube placement. Final blood cultures were remarkable for gram-negative rods – *Prevotella* anaerobes – which supported the diagnosis of LS. His condition improved, including the dyspnea, and he was discharged on the proper antibiotics coverage with outpatient follow-up.

Conclusions: LS is a rare condition associated with metastatic infection spreading. This syndrome can be associated with further complications, such as pleural effusions and/or empyemas. Early recognition is important to prevent fatal complications and provide adequate antibiotics coverage. We report only the third case in the medical literature of *Prevotella*-induced LS with a secondary complication of pleural effusion.

MeSH Keywords: Gram-Negative Anaerobic Bacteria • Lemierre Syndrome • *Prevotella*

Full-text PDF: <http://www.amjcaserep.com/abstract/index/idArt/895560>



1189



2



3



21



Background

Jugular vein septic thrombophlebitis, also known as LS, is an extremely rare complication that stems most commonly from an acute oropharyngeal infection with retropharyngeal extension and metastatic spread. The condition was first described in 1936 by Andre Lemierre in a 20-patient case series in which he reported similarly grouped oral, gastroenterological, and genitourinary flora that proliferated and disseminated, causing septic embolic phenomena [1,2]. The incidence of this condition is approximately 0.8 persons per million per year, with an estimated mortality rate of up to 24% [3]. Previously, this syndrome had a mortality rate of 32–90% in the pre-antibiotic era, but the incidence and mortality have since diminished with increased use of antibiotics [4]. The most commonly isolated pathogen is *Fusobacterium necrophorum*, a common oral flora. The remaining pathogens include *Fusobacterium* species, *Peptostreptococcus*, Group B and C. *Streptococcus*, *Staphylococcus*, and *Enterococcus* species [5].

Case Report

A 22-year-old man with no significant past medical history presented to the emergency department with a 1-week history of left jaw pain with progressive swelling of the left facial area and dyspnea. He was previously evaluated in an urgent care clinic and was given antibiotics, without improvement. Other associated symptoms were left-sided pleuritic chest pain and subjective fever, and chills with malaise. His social history was unremarkable. The physical examination showed normal vital signs, gingival bleeding, lymphadenopathy, and chest tenderness to palpation on left 6 and 7 ribs. There was also increased tactile vocal fremitus and decreased breath sounds on the left side of the chest.

Initial laboratory findings are illustrated in Table 1. The chest x-ray showed left lower lobe consolidation with small pleural effusion (Figure 1). A diagnosis of odontogenic infectious process was initially made, with possible disseminated intravascular coagulation (DIC). On further evaluation, a peripheral blood smear was negative for schistocytes, and other laboratory findings were unremarkable for DIC picture. Given the physical findings, a CT neck was done, which was remarkable for thrombosis of left external jugular veins and pterygoid venous plexus extending into the internal jugular veins, with left submandibular lymphadenopathy (Figure 2). No evidence of fluid collection was noted, ruling out the possibility of an abscess. Additionally, a CT chest was obtained to further evaluate the left consolidation noted on the x-ray. It was remarkable for large left pleural effusion with pleural thickening and multiple pulmonary nodules in both lungs, with some cavitation representing possible septic emboli (Figure 3). The clinical presentation and imaging data led to the diagnosis of LS.

Table 1. Initial laboratories.

Lab	Value
WBC	23,660 per mm ³ (Differential: Neutrophils: 76%, Bands: 14%, Lymphocytes: 3%)
Hemoglobin	13.8 g/dL
Hematocrit	38.9%
Platelets	10,000 per mm ³
Electrolytes	Unremarkable
Renal panel	BUN: 41 mg/dL; Cr: 1.47 mg/dL
Liver transaminases	Unremarkable
Coagulation panel	PT: 18.8 sec INR: 1.5 PTT: 3.4 sec
Urine toxicology	Negative
Sedimentation rate	40 mm/hr
C-reactive protein	29.10 mg/dL
HIV	Negative

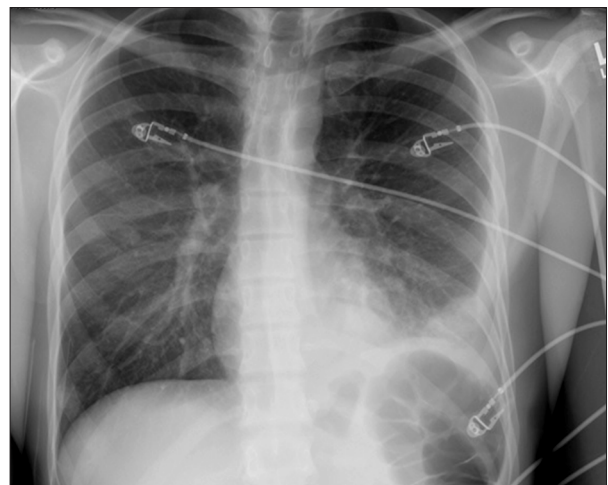


Figure 1. Left lobe consolidation with small pleural effusion.

Initially, the patient was started on ampicillin-sulbactam and received platelets transfusion for low platelets. Once stabilized, he underwent thoracentesis for left pleural effusion, which was revealed to be an exudate process, as illustrated in Table 2. A pigtail catheter was placed to drain the pleural effusion. Blood cultures came back positive for *Prevotella* anaerobes. The patient was then treated with intravenous cefepime 2 gram every 24 hours and oral clindamycin 450 mg every 6 hours for 2 weeks and 5 days, respectively. He remained afebrile, with negative follow-up blood cultures and was discharged with outpatient care.

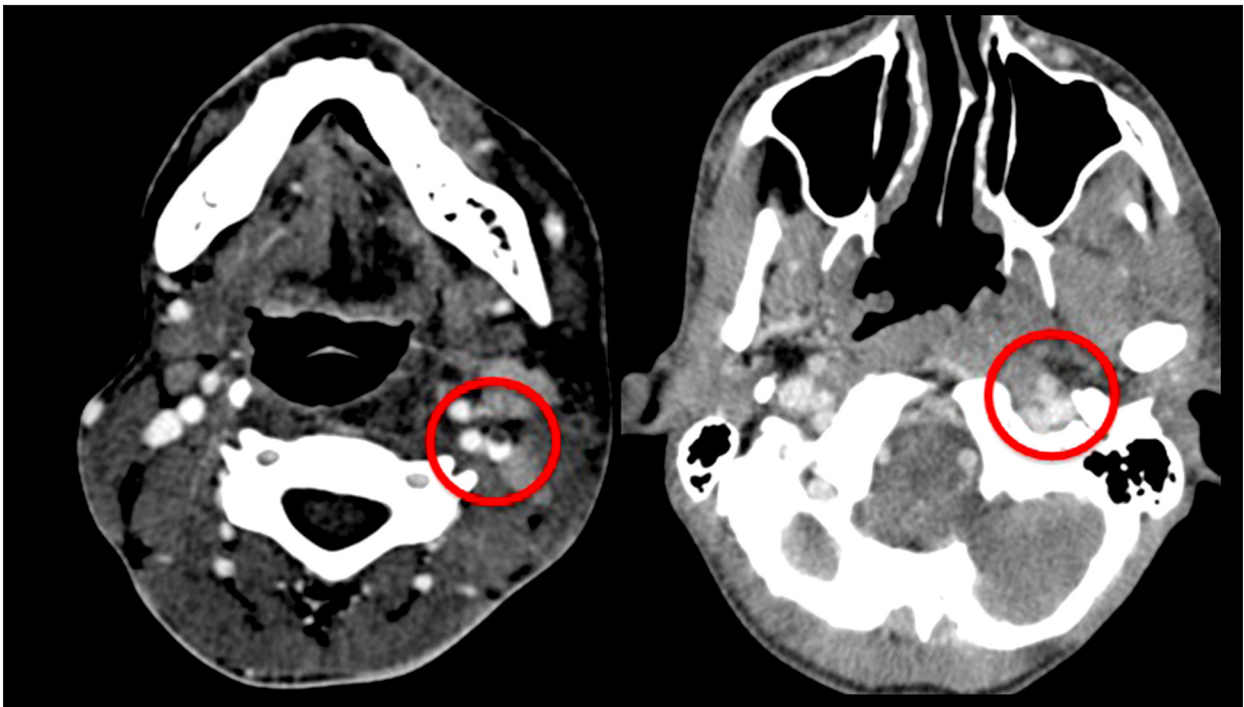

Figure 2. CT of the head and neck showing thrombosis of the left pterygoid venous plexus leading to internal jugular vein filling defect.

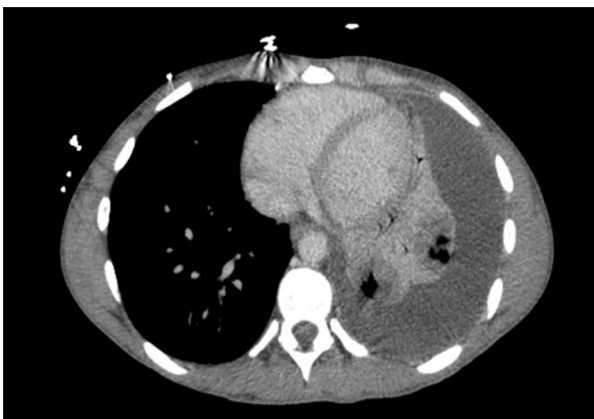

Figure 3. CT chest showing large pleural effusion on left representing empyema. Multiple pulmonary nodules showing cavitation are probably septic emboli.

Discussion

Since Andre Lemierre first published his case series in 1936, there have been less than 160 published cases of LS, with almost one-third documented after 1988 [6]. LS is a rare complication characterized by thrombosis of the internal jugular vein and isolation of anaerobic pathogens from either the blood or an abscess [7,8]. In many cases the patients also develop a septic-like clinical picture with frequent pulmonary involvement [8]. Gupta et al. presented an interesting case of LS induced by *Streptococcus intermedius* secondary to gingival

Table 2. Pleural fluid analysis.

Lab	Value
Color/appearance	Orange, turbid
WBC	23,990 per mm ³
RBC	10,000 per mm ³
Seg %	41%
Lymph %	34%
Mono %	15%
Other %	10%
Glucose	<1 mg/dL
Protein (PF)	3.5 G/DL
LDH (PF)	>4000 Unit/L
Protein (serum)	4.8 G/DL
LDH (serum)	186 Unit/L

scraping [2]. Our patient presented with *Prevotella*-induced jugular vein thrombosis. In an extensive review of the literature, only 2 other similar cases have been reported [9].

Among the vast majority of the normal oral anaerobic bacteria, *Prevotella* and *Fusobacterium* are important source of infection. Mosca et al. assessed the antimicrobial profile of 55 cases of periodontal gram-negative bacteremia. The study showed 39 strains of *Prevotella* and 16 strains of *Fusobacterium*. Furthermore, most of the *Prevotella* stains were susceptible to amoxicillin-clavulanic acid, metronidazole, and doxycycline [10]. A prospective observational study was done in Athens, Greece to determine the epidemiology and microbiological features of various anaerobes. It was noted that *Bacteroids* were isolated from intra-abdominal, whereas *Prevotella* was isolated from respiratory tract [11].

Although the pathogenesis of *Fusobacterium* is complex, it has been speculated that its leukotoxin and endotoxin, as well as its ability to aggregate platelets, are the primary virulence factors in establishing and overcoming host defenses [12,13]. These virulence factors, along with the septic pro-coagulant cascade, have been attributed to its ability to develop associated septic thrombi. Deficiencies in host factors, such as thrombophilias, increase the likelihood of septic spread [14]. However, at this time there are no studies specifically looking at specific virulence factors of *Prevotella* regarding thrombus formation. We surmise that both anaerobic species may have similar and overlapping factors, which would explain its continued virulence [15].

Most patients with LS present with a pharyngitis-like picture with associated fever, chills, rigors, dysphagia, neck discomfort, and malaise [16]. Other pulmonary symptoms such as dyspnea, cough, pleuritic-pain, and hemoptysis have been reported [17]. A high clinical suspicion for LS should exist when patients have continued pharyngitis symptoms after a standard course of antibiotics or when a pharyngitis-like illness is associated with pulmonary symptoms [17]. Chest radiographs may demonstrate non-specific opacities in the event of pulmonary involvement, with up to 15% of cases developing empyemas.

References:

1. Lemierre A: On certain septicemias due to anaerobic organisms. *Lancet*, 1936; 227(5874): 701–3
2. Gupta S, Merchant S: S. Lemierre's Syndrome: Rare, but life threatening – a case report with *Streptococcus intermedius*. *Case Rep Med*, 2012; 2012: 624065
3. Hagelskjaer LH, Prag J, Malczynski J, Kristensen JH: Incidence and clinical epidemiology of necrobacillosis, including Lemierre's syndrome, in Denmark 1990–1995. *Eur J Clin Microbiol Infectious Dis*, 1998; 17(8): 561–65
4. Kristensen LH, Prag J: Human necrobacillosis, with emphasis on Lemierre's syndrome. *Clin Infect Dis*, 2000; 31(2): 524–32
5. Karkos PD, Asrani S, Karkos CD et al: Lemierre's syndrome: a systematic review. *Laryngoscope*, 2009; 119(8): 1552–59
6. Moore BA, Dekle C, Werkhaven J: Bilateral Lemierre's syndrome: a case report and literature review. *Ear Nose Throat J*, 2002; 81(4): 234–36, 238–40, 242 passim
7. Mutyala K, Mcgrath EJ, Davalos MC et al: External jugular vein thrombosis in an adolescent with lemierre syndrome. *Consultant for Pediatrics* 360, 2012; 11, Vol 10 [e-pub]
8. Wright WF, Shiner CN, Ribes JA: Lemierre syndrome. *South Med J*, 2012; 105(5): 283–88
9. Westhout F, Hasso A, Jalili et al: Lemierre syndrome complicated by cavernous sinus thrombosis, the development of subdural empyemas, and internal carotid artery narrowing without cerebral infarction: Case report. *J Neurosurg*, 2007; 106(Suppl.1): 53–56
10. Mosca A, Miragliotta M: Antimicrobial profiles of *Prevotella* spp and *Fusobacterium nucleatum* isolated from periodontal infections in a selected area of southern Italy. *Int J Antimicrobial Agents*, 2007; 30: 521–24
11. Papaparaskevas J, Kastsandri A, Pantazatou A: Epidemiological characteristics of infections caused by *Bacteroids*, *Prevotella* and *Fusobacterium* species: A Prospective observational study. *Anareobe*, 2011; 17: 113–17

Depending on the clinical presentation, an ultrasound of the neck or CT of the head and neck will demonstrate a unilateral internal jugular vein thrombus in up to 70% of cases [17,18]. Concomitant positive blood or oropharyngeal abscess cultures increase the likelihood of the diagnosis.

Management of LS should include possible surgical drainage of an abscess or fluid collection if found. Secondary complications such as empyemas or pneumothoraxes should be managed by chest tube placement [18]. Although it is an uncommon complication, esophageal perforation can occur secondary to misplacement of a nasogastric tube (NGT). Most misplacements are intracranial or endotracheal [19]. NGT placements are commonly used in hospitals to deliver nutrition. Early detection and surgical intervention reduces morbidity and mortality. Unlike our case, the patient had no indications for NGT. Empiric therapy with a third-generation B-lactamase inhibitor such as ceftriaxone plus anaerobic coverage with metronidazole would provide sufficient initial coverage. Duration of therapy is generally 4-6 weeks of intravenous antibiotics to allow for penetration into fibrin clots [18]. There is insufficient evidence to support the use of anticoagulation in septic thrombi except in cases of thrombi that persist despite aggressive medical therapy [20,21].

Conclusions

LS is a rare complication of bacterial oropharyngeal infection seen mostly in young healthy individuals with metastatic spreading. The diagnosis largely depends on patient history, signs, and symptoms. Imaging studies such as CT scan can display the thrombus or filling defect in the internal jugular vein. Some of the complications seen in LS are septic emboli, pleural effusion, and DIC. A high level of suspicion should be raised by other less common organisms to prevent deterioration of the condition if not covered by adequate antibiotics.

12. Tan ZL, Nagaraja TG, Chengappa MM: *Fusobacterium necrophorum* infections: virulence factors, pathogenic mechanism and control measures. *Vet Res Commun*, 1996; 20(2): 113–40
13. Forrester LJ, Campbell BJ, Berg JN, Barrett JT: Aggregation of platelets by *Fusobacterium necrophorum*. *J Clin Microbiol*, 1985; 22: 245–49
14. Riordan T: Human infection with *Fusobacterium necrophorum* (*Necrobacillosis*), with a focus on Lemierre's syndrome. *Clin Microbiol Rev*, 2007; 20(4): 622–59
15. Duerden BI: Virulence factors in anaerobes. *Clin Infect Dis*, 1994; 18(4): S253–59
16. Chirinos JA, Lichtstein AD, Garcia J, Tamariz LJ: The evolution of Lemierre syndrome: report of 2 cases and review of the literature. *Medicine*, 2002; 81(6): 458–65
17. Lemierre A, Meyer A, Laplane R: Les septicémies à bacille de Pfeiffer. *Ann de Méd*, 1936; 39; 97 [in French]
18. Riordan T, Wilson M: Lemierre's syndrome: more than a historical curiosa. *Postgrad Med J*, 2004; 80(944): 328–34
19. Isik, A, Firat D, Peker Kemal: A case report of esophageal perforation: Complication of nasogastric tube placement. *Am J Case Rep*, 2014; 15: 168–71
20. Bach MC, Roediger JH, Rinder HM: Septic anaerobic jugular phlebitis with pulmonary embolism: problems in management. *Rev Infect Dis*, 1988; 10(2): 424–27
21. Hoehn KS: Lemierre's syndrome: The controversy of anticoagulation. *Pediatrics*, 2005; 115(5): 1415–16