



## CASE REPORT

# Cutaneous manifestations of COVID-19 among healthcare workers: A Case report and literature review

Youssefi Imen<sup>1</sup>  | Najla Mechergui<sup>1,2</sup> | Nouredine Litaïem<sup>2,3</sup>  | Imen Youssef<sup>1,2</sup> | Soumaya Gara<sup>3</sup>  | Faten Zeglaoui<sup>2,3</sup> | Soumaya Rammeh<sup>2,4</sup> | Nizar Ladhari<sup>1,2</sup>

<sup>1</sup>Department of Occupational Health, Charles Nicolle Hospital, Tunis, Tunisia

<sup>2</sup>Faculty of Medicine of Tunis, University of Tunis El Manar, Tunisia

<sup>3</sup>Department of Dermatology, Charles Nicolle Hospital, Tunis, Tunisia

<sup>4</sup>Department of Pathology, Charles Nicolle Hospital, Tunis, Tunisia

## Correspondence

Youssefi Imen, Department of Occupational Health, Charles Nicolle Hospital, Tunis, Tunisia.  
Email: docteur.youssefi1990@gmail.com

## Funding information

None.

## Abstract

Common clinical features of COVID-19 are increasingly known but cutaneous manifestations are rarely described among healthcare workers. A review of cutaneous manifestations of COVID-19 especially among healthcare workers (HCW) is thus required. The aim of our current study was to provide a comprehensive review of cutaneous manifestations of COVID-19 among HCW through six case reports and a literature review. We conducted a literature search for cases reports, original and review articles using PubMed and the Google search engines. We included the written English studies that mentioned cutaneous symptoms during COVID-19 infection. In addition to the review, 6 cases were collected among the HCW working at the Charles Nicolle Hospital of Tunis from September 2020 to January 2021. In our review, we included 17 articles in addition to our six cases. The type of papers was case series and case reports in respectively 8 and 9 studies. Skin manifestations were reported in two studies including two HCW, in addition to our series of six HCW. Skin manifestations were chilblain-like lesions (44.5%), a generalized macular or maculopapular exanthem (32.1%), a papulovesicular rash and chicken pox-like vesicles (11.5%), painful acral red–purple papules (4.6%), urticaria (2.8%), purpuric or petechial lesions (2.3%), and livedo reticularis lesions (0.45%). Of the 218 cases, 203 cases have reported the location of lesions. The very great majority of lesions were found on the trunk, hands, and feet. Fifty-one patients (23.4%) experienced lesions on the trunk. The time of onset of cutaneous lesions was variable. At the diagnosis or the onset of COVID-19 symptoms, 8.3% (18/218) of patients presented with cutaneous lesions. After the onset of respiratory symptoms or COVID-19 diagnosis, 36.7% (80/218) of patients presented with cutaneous lesions. Of the 197 cases with reported healing times, healing times were up to 24 days. COVID-19 has been associated with different cutaneous manifestations, likely of varying pathophysiology and severity, some preceding COVID-19 symptomatology and others occurring during active disease or later in the course. Thus, heightened awareness and timely recognition of cutaneous manifestations in COVID-19 are important for occupational physicians treating HCW with COVID-19.

This is an open access article under the terms of the Creative Commons Attribution-NonCommercial-NoDerivs License, which permits use and distribution in any medium, provided the original work is properly cited, the use is non-commercial and no modifications or adaptations are made.

© 2022 The Authors. *Clinical Case Reports* published by John Wiley & Sons Ltd.

**KEYWORDS**

COVID-19, cutaneous manifestations, healthcare workers

## 1 | INTRODUCTION

COVID-19 infection initially reported in Wuhan, China,<sup>1</sup> has been spread all over the world. As of July 7, 2021, COVID-19 has been diagnosed in more than 184 million people worldwide.<sup>2</sup> Its rapid spread across geographical borders leading to a pandemic can be explained by several factors such as the high rate of infectivity and transmission from asymptomatic persons.<sup>3</sup> The World Health Organization (WHO) has declared the COVID-19 outbreak as a Public Health Emergency of International Concern. COVID-19 pandemic still represents a great challenge for healthcare workers (HCW) around the world.<sup>4</sup>

Healthcare workers are first-line fighters against COVID-19. They may experience symptoms ranging from influenza-like illness to life-threatening respiratory distress.<sup>5</sup> Apart from pulmonary involvement, it is interesting to note that multiple extrapulmonary manifestations associated with COVID-19 infection have been reported including skin manifestations. Common clinical features of COVID-19 are increasingly known but cutaneous manifestations are rarely described among healthcare workers. A review of cutaneous manifestations of COVID-19 among healthcare workers (HCW) is thus required.

The aim of our current study was to provide a comprehensive review of cutaneous manifestations of COVID-19 among HCW through six case reports and a literature review.

## 2 | METHODS

We conducted a literature search for cases reports, original and review articles published from the beginning of the COVID-19 pandemic until January 2021, using PubMed and the Google search engines. In our study, we used these key search words "cutaneous," "skin," and "dermatology" in combination with "coronavirus," "COVID-19," and "SARS-CoV-2." A manual search of reference lists of some relevant articles was performed. We excluded the studies that did not mention skin lesions.

We extracted the socio-demographic and clinical data from the included studies. Socio-demographic data were mainly the number of cases, age, gender, and status for COVID-19. The clinical data were mainly the description of the cutaneous lesions, its location, onset and healing time, and associated signs. The occupation was extracted

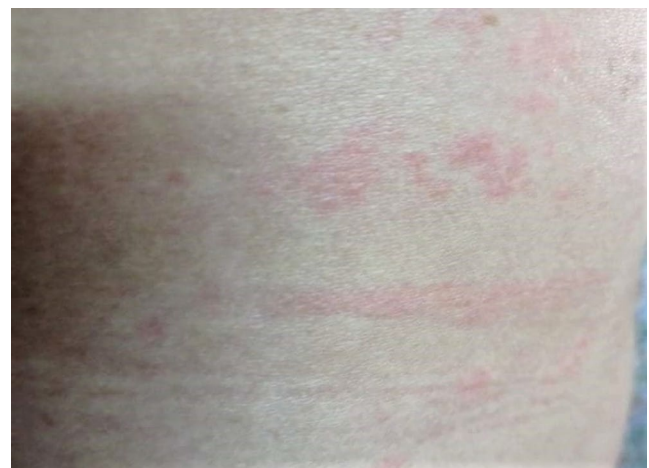from these studies when mentioned. In addition to the review, 6 cases were collected among the HCW working at the Charles Nicolle Hospital of Tunis from September 2020 to January 2021.

## 3 | RESULTS

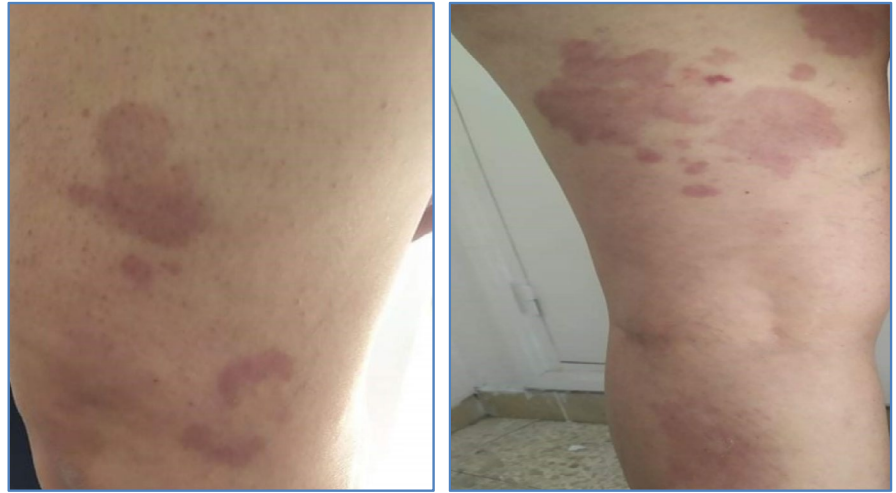### 3.1 | Case presentation

#### 3.1.1 | Case 1

A 45-year-old nurse with a history of spontaneous pneumothorax, with no previous medication, or previous adverse drug reactions, presented to the occupational medicine department with a fever, a productive cough, asthenia, and body ache with no suspicious contact of COVID-19. The COVID-19 infection was confirmed by a positive RT-PCR on November 5, 2020. Anosmia, headaches, and dizziness occurred between Day 2 and Day 13 of the infection. The patient was treated with antibiotics based on azithromycin and a third-generation cephalosporin, combined with vitamins and preventive heparin therapy. The clinical course was marked by the appearance at Day 10 of an erythematous and pruritic cutaneous rash on the trunk and limbs with buccal ulcers without fever or signs of hemorrhages of the mucous membranes (Figure 1). Clinical improvement of the rash was noted after taking corticosteroid injections for 5 days. The nurse returned to work after 25 days of the infection with a dry sequelae cough.

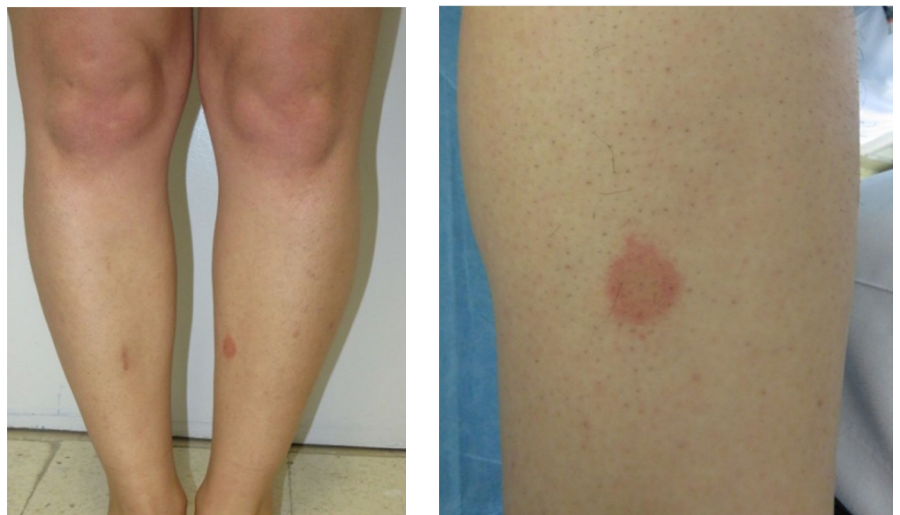


**FIGURE 1** Case 1: Cutaneous rash on the limbs on Day 10 of COVID-19 infection



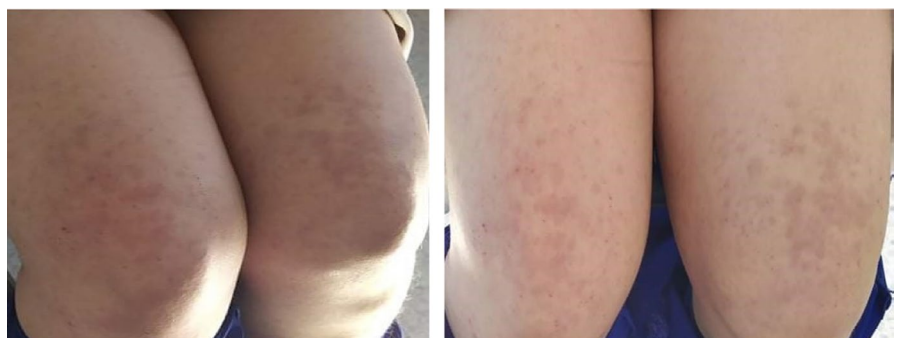**FIGURE 2** Case 2: Erythematous and pruritic herpetiform rash on the limbs one month after COVID-19 infection

**(A)**



**(B)**

**FIGURE 3** Case 3: (A) Non necrotic purpura on the legs on Day13 of COVID-19 infection (B) Histologic picture of a necrotizing neutrophilic leukocytoclastic vasculitis



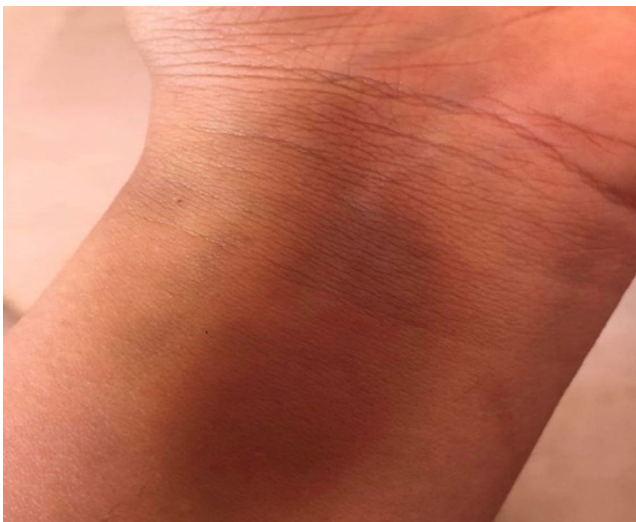**FIGURE 4** Case 4: Pruritic rash on the limbs on Day 10 COVID-19 infection

### 3.1.2 | Case 2

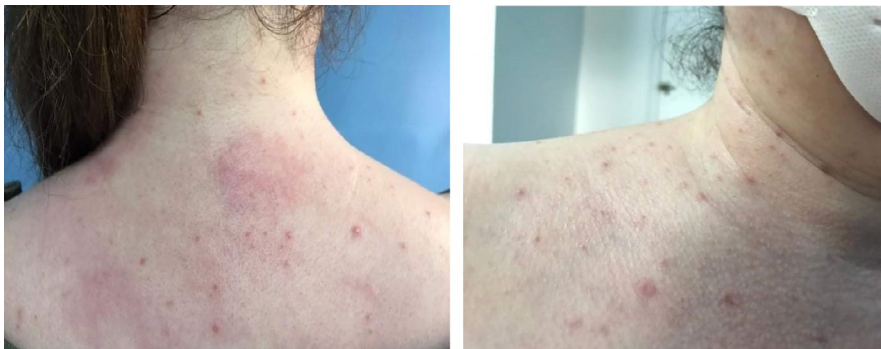A 44-year-old physiotherapist with a history of high blood pressure, paracetamol-drugged hepatitis, and an operated thyroid nodule tested positive to COVID-19 on October 7, 2020, with symptoms of ageusia, anosmia, and fever. She was treated with vitamin therapy and antibiotics based on azithromycin. Diarrhea and dizziness appeared, respectively, at Day 2 and Day 6 of the clinical evolution. She returned to work on October 20th with only hyposmia. One month later, on November 25, the patient reconsulted for an erythematous and pruritic herpetiform rash on the limbs and the abdomen without fever or other associated signs or medication use (Figure 2). A progressive and spontaneous improvement of the cutaneous lesions appeared after one week.

### 3.1.3 | Case 3

A 57-year-old midwife with a history of hypertension was tested COVID-19 positive on September 25, 2020, a sample



**FIGURE 5** Case 5: Ecchymotic plaque on the forearm on Day 15 of COVID-19 infection



**FIGURE 6** Case 6: Maculopustular eruption on the neck and chest on Day 8 of COVID-19 infection

indicated for body aches, asthenia, and headaches with a suspicious contact. She was treated with vitamin therapy for 10 days, combined with azithromycin for 06 days. She received preventive heparin therapy for 4 days. On Day 13 of the infection, the patient reported cutaneous lesions.

These lesions were objectified at the return-to-work medical examination. There was non-necrotic purpura (1–2 cm) on the legs and lower back, with no mucous lesions or fever. There were recurrent attacks that spontaneously resolved after 5–7 days. The patient was referred for further explorations. Skin biopsy showed a "necrotizing neutrophilic leukocytoclastic vasculitis" (Figure 3). Blood tests were normal, and immunological tests were requested. The patient was not put under corticoid or immunosuppressive treatment. The clinical evolution was marked by remission of cutaneous manifestations observed about two months after the onset of the disease around December 5, 2020.

### 3.1.4 | Case 4

A 32-year-old neonatology technician with no notable history presented on October 6, 2020, with fever, cough, shortness of breath, and body aches. The nasopharyngeal swab confirmed COVID-19 infection on October 7th. The patient was put under azithromycin for 9 days combined with a third-generation cephalosporin and vitamin therapy. On October 16th, 10 days after, the patient reported the appearance of cutaneous lesions, which were confirmed at the return-to-work medical examination on October 20. There was a pruritic rash on the lower limbs and the elbows, which improved after five days of antihistaminic treatment (Figure 4).

### 3.1.5 | Case 5

A 33-year-old doctor, with no notable antecedents, was tested positive for SARS-CoV-2 on December 9, 2020, by a nasopharyngeal swab indicated for suggestive symptomatology of fever with anosmia and contact with a positive

TABLE 1 Characteristics and cutaneous manifestations of COVID-19 in our six reported cases published

Author, Publication year	Region	Patients with skin signs (n)	Age, Gender, Occupation	Suspected or confirmed COVID-19	Cutaneous Manifestations						
					Signs (n)	Location	Timing	Healing duration	Associated symptoms	Correlation of COVID-19 severity with skin lesions	Treatments for COVID-19 Infection
Youssfi J et al, 2021	Tunisia	6 HCW	Mean 43.5, 6F, NR	C	Case 1: erythematous and pruritic cutaneous rash and buccal ulcers Case 2: erythematous and pruritic herpetiform rash Case 3: nonnecrotic purpura Case 4: pruritic rash Case 5: ecchymotic plaque Case 6: pruritic maculopustular eruption	Trunk and limbs Limbs and abdomen Legs, lower back Elbows, legs Forearm chin, neck and upper chest	At day 10 after onset One month after onset On day 13 after onset At day 10 after onset At day 15 after onset At day 8 after onset	5 days 7 days 7 days 5 days 7 days 7 days	Mild pruritus Mild pruritus None Mild pruritus None Mild pruritus	NR NR Yes NR NR NR	Corticosteroids None None Antihistaminic None None

Abbreviations: C, confirmed case; F: female; HCW, healthcare worker; NR, not reported.

TABLE 2 Characteristics and cutaneous manifestations of COVID-19 cases published in scientific literature

Author, Publication Year	Region	Patients with Skin Signs (n)	Age, Gender, Occupation	Suspected or Confirmed COVID-19	Cutaneous Manifestations
					Signs (n)
Gianotti, 2020 <sup>6</sup>	Italy	5	Case 1, 2, 4, 5: NR, NR Cas 3: NR, M; NR	Cas 1-5: C	Case1: Exanthema Case2: Purpuric maculopapulo-vesicular rash Case3: Papular erythematous exanthema Case 4 et 5: Diffuse maculopapular eruption clinically suggestive for Grover disease
Recalcati, 2020 <sup>7</sup>	Italy	18	NR	C	Erythematous rash (14), Widespread urticaria (3), chickenpox-like vesicles (1)
Parhar 2020 <sup>14</sup>	USA	1	36, F, NR	C	Diffuse erythematous vesicular rash
Quintana-Castanedo, 2020 <sup>15</sup>	Spain	1	61, M, HCW	C	Urticarial rash consisting of confluent, edematous, and erythematous papules
Marzano, 2020 <sup>8</sup>	Italy	22	Median age 60, 16 M/6F, NR	C	Varicella-like papulovesicular exanthem
Zhang 2020 <sup>9</sup>	China	7	Median age of 59, 4 M/3F, NR	C	Acro-ischemia presentations including finger/toe cyanosis, skin bulla and dry gangrene
Fernandez-Nieto 2020 <sup>10</sup>	Spain	132	Mean 19.9, 71 M, 61F, NR	19 S, 2C	Chilblain-like lesions (n = 95) Erythema multiforme-like (n = 37)
Boostani, 2020 <sup>16</sup>	Iran	1	37, M, NR	S	Widespread maculopapular pigmented and crusted plaques
Najarian 2020 <sup>17</sup>	USA	1	58, M, NR	C	Morbilloform exanthem
Jimenez-Cauhe 2020 <sup>18</sup>	Spain	1	84, F, NR	C	Erythematopurpuric, millimetric, coalescing macules
Alramthan 2020 <sup>11</sup>	Qatar	2	Case 1: 27, F Case 2: 35, F, NR	C	Case 1, 2: Acral ischemic lesions presenting as red-purple papules
Mahé 2020 <sup>19</sup>	France	1	64, F, NR	C	Erythematous rash
Hunt 2020 <sup>20</sup>	USA	1	20, M, NR	C	Diffuse, morbilliform, maculopapular, and nonpruritic rash
Estébanez 2020 <sup>21</sup>	Spain	1	28, F, NR		Pruritic lesions/ Confluent erythematous-yellowish papules
Henry 2020 <sup>27</sup>	France	1	27, F, HCW	C	Disseminated erythematous plaques eruption, urticaria

Location	Timing	Healing Duration	Associated Symptoms	Correlation of COVID-19 Severity with Skin Lesions	Treatments for COVID-19 Infection
Case 1: Trunk and limbs Case 2: NR Case 3, 4 et 5: Trunk	NR	NR	NR	NR	NR
Trunk	8 developed at onset, 10 after hospitalization	Healed within a few days	Little to no itching	No correlation	NR
Trunk, upper extremities and groin.	At onset	7 days	NR	No correlation	topical triamcinolone
Thighs, arms, and forearms	At onset	7 days	mild pruritus.	No correlation	oral antihistamine
Trunk, limbs	Median latency: 3 days (range of -2 to 12 days)	Median duration 8 days (range 4 to 15 days)	Itching (n = 9)	NR	NR
Extremities	Median time 19 days (11-23)	NR	NR	NR	Low molecular weight heparin treatment
Hands (n = 41) Feet (n = 108)	latency time of 9.2 days (n = 16), at the onset (n = 3)	Mean duration 8.7 days (range, 2-24 days).	NR	NR	NR
Limbs Trunk	Few days after onset	NR	Sensorimotor polyradiculoneuropathy	NR	Immunoglobulin
Legs, thighs, forearms, arms, shoulders, back, chest, abdomen	Three days before onset	6 days	Cough and legs pain	NR	Triamcinalone 0.1%
Flexural periaxillary regions	3 days of hospitalization, 11 days since onset	NR	Pneumonia	Unlikely	hydroxychloroquine, lopinavir ritonavir,
Case 1, 2: Dorsal aspect of fingers bilaterally	NR	NR	NR	NR	NR
Axillary folds trunk antecubital fossa	Four days after onset	9 days	Fever	Yes	Paracetamol
Trunk and extremities sparing the face	Along with fever, before diagnosis	NR	NR	NR	NR
Heel	13 days after being diagnosed	10 days	Lesions persisted and became erythematous plaques that were both hardened and pruritic	Yes	Paracetamol
Face, hand and feet (acral involvement)	48 hours before onset of respiratory symptoms	NR	Pruritis	NR	Paracetamol and antihistamines

(Continues)

TABLE 2 (Continued)

Author, Publication Year	Region	Patients with Skin Signs (n)	Age, Gender, Occupation	Suspected or Confirmed COVID-19	Cutaneous Manifestations
					Signs (n)
Bouaziz 2020 <sup>12</sup>	France	14	NR	C	exanthema (n = 4), chicken pox-like vesicles (n = 2), cold urticaria (n = 1), violaceous macules with “porcelain-like” appearance (n = 1), livedo (n = 1), nonnecrotic purpura (n = 1), necrotic purpura (n = 1), chilblain appearance with Raynaud’s phenomenon (n = 1), chilblain-like lesions (n = 1), eruptive cherry angioma (n = 1)
Tammaro 2020y <sup>13</sup>	Spain, Italy	3	NR	C	Case 1, 2: isolated herpetiform lesions (vesicles surrounded by erythematous halos) Case 3: numerous vesicular isolated lesions

Abbreviations: C, confirmed case; F, female; HCW, healthcare worker; M, male; NR, not reported; S, suspected case.

case. The clinical evolution was favorable under medical treatment. On December 23rd, 15 days after the infection, the patient reported a spontaneous cutaneous lesion on the left forearm with no fever, which was objectified at the medical check-up on December 25th. It was a well-limited superficial ecchymotic plaque of 07 cm long on the anterior face of the lower third of the left forearm which has spontaneously regressed after one week (Figure 5).

### 3.1.6 | Case 6

A 50-year-old medical secretary, with no notable antecedents, was tested positive for SARS-CoV-2 on January 18, 2021, by a nasopharyngeal swab indicated for suggestive symptomatology of fever, cough, andodynophagia with no suspicious contact with a positive case. The clinical evolution was favorable under medical treatment. On January 23rd, 8 days after the onset, the patient presented with spontaneous pruritic maculopustular eruption on the chin, neck, and upper chest with lower back pain without fever. Cutaneous lesions have spontaneously regressed after one week (Figure 6).

Table 1 summarizes the characteristics and cutaneous manifestations of COVID-19 in our six reported cases.

## 4 | REVIEW OF LITERATURE

Seventeen articles were selected for this review. There are 8 case series,<sup>6-13</sup> and 9 case reports.<sup>14-21</sup> The mean age was

49.8 years (20; 84). The gender was not reported in 17.9% of cases. In the other cases that mentioned the gender, sex ratio was 1.15.

COVID-19 infection was confirmed in 90.8% of cases. Skin manifestations among HCW were reported in two studies including two physicians,<sup>19,21</sup> in addition to our series of six HCW.

Table 2 summarizes the characteristics and cutaneous manifestations of COVID-19 cases published in scientific literature.

Skin manifestations were chilblain-like lesions (44.5%), a generalized macular or maculopapular exanthem (32.1%), a papulovesicular rash and chicken pox-like vesicles (11.5%), painful acral red–purple papules (4.6%), urticaria (2.8%), purpuric or petechial lesions (2.3%), and livedo reticularis lesions (0.45%). Of the 218 cases, 203 cases have reported the location. The very great majority of lesions were found on the trunk, hands, and feet. Fifty-one patients (23.4%) experienced lesions on the trunk. The time of onset of cutaneous lesions in relation to the onset of symptoms was variable. At the diagnosis or the onset of COVID-19 symptoms, 8.3% (18/218) of patients presented with cutaneous lesions. After the onset of respiratory symptoms or COVID-19 diagnosis, 36.7% (80/218) of patients presented with cutaneous lesions. The timeline of the appearance of the skin lesions was not mentioned in 55% of cases. Healing times were up to 24 days in 197 cases.

The severity of cutaneous lesions was not correlated with COVID-19 severity in 99% of cases. Only two studies by Mahé<sup>19</sup> and Estébanez<sup>21</sup> reported on the possible



Location	Timing	Healing Duration	Associated Symptoms	Correlation of COVID-19 Severity with Skin Lesions	Treatments for COVID-19 Infection
NR	Few days after onset	From 10 to 21 days	NR	NR	NR
Case 1, 2: Trunk Case 3: Back	Case 1, 2: during the inpatient stay Case 3: 8 days after onset	NR	Mild pruritus	NR	NR

association between skin lesion severity and COVID-19 in 2 patients. Overall, histological findings were not reported. In our series, we have histological findings that may be related to the COVID infection in one patient.

## 5 | DISCUSSION

Skin manifestations of the COVID-19 are not frequent as compared to the common clinical features such as shortness of breath, cough, and grippal syndrome.<sup>22</sup> In our study, we summarized the characteristics of cutaneous manifestations of COVID-19 cases published in scientific literature in addition to our case series (Table 1). We wished to characterize these manifestations, particularly among HCW for further diagnostic and prognostic value because cutaneous manifestations of COVID-19 have been increasingly reported worldwide. Skin manifestations were reported in 8 case reports and 9 case series.

In this review, 44.5% (97/218) of patients presented with chilblain-like lesions. In a previous review by Tan et al,<sup>23,24</sup> the most common COVID-19 skin manifestations in the USA and Europe were the chilblain-like lesions. There was only 1 case reported in Asia. Rash containing macules and papules was the second cutaneous manifestation of COVID-19. However, rashes containing macules and papules were not specific to COVID-19, and there were reports of misdiagnosed cases of COVID-19 in patients with rash containing macules and papules.<sup>20</sup>

In the study by Recalcatti et al,<sup>7</sup> 20.4% (18/88) of COVID-19 patients had developed skin manifestations. These manifestations were erythematous rash (77.8%), urticaria (16.7%), and vesicle formation (5.6%). These findings are nearly similar to our results.

Skin manifestations may aid in timely diagnosis of the COVID-19 infection even in the asymptomatic cases with no respiratory or common symptoms. We found that at the onset of the infection, 8.3% (18/218) of patients presented with cutaneous lesions.

In order to prevent the misdiagnosis of the COVID-19 signs, doctors' awareness of the skin lesions related to COVID-19 infection must be raised.<sup>22</sup> Furthermore, skin lesions may have several outcomes on the professional quality of life of HCW. Having new manifestations of the COVID-19 infection can lead to frequent consultations seeking care and treatment so that frequent absenteeism. Also, HCW may wonder if they could be assisted with compensation of their skin lesions as sequellae of the COVID-19 occupational disease.

Visible skin lesions present on exposed body parts may induce fear, disgust, aversion, or even intolerance<sup>23,24</sup>. Furthermore, some people with limited awareness of skin lesions after COVID-19 infection believe that the disease still contagious, which may eventually contribute to the social isolation of persons with skin lesions. HCW with skin lesions may be subject to segregation and stigmatization, especially if the lesions are visible on the face and exposed body areas.

Polymorphous cutaneous manifestations could reflect diverse interactions with the skin such as direct viral action in infected cells, hypercoagulability, and immune system hyperactivity.<sup>24</sup> The mechanisms of COVID-19 cutaneous lesions are not yet well known. Some studies have linked the cutaneous symptoms to a primary infection of the skin itself. In other theories, skin disturbances are seen as a secondary consequence after the respiratory infection. Suchonwanit et al reported that the late-onset of lesions may be related mainly to thrombotic vasculopathy and vasculitis.<sup>25</sup> Moreover, Litaïem et al reported a case in Tunisia of a 39-year-old female patient diagnosed with COVID-19 infection, and 18 days after hydroxychloroquine (600 mg daily) initiation, she developed a cephalocaudal spread of erythematous and pustular plaques. The Acute Generalized Exanthematous pustulosis (AGEP) was diagnosed. Skin lesions were significantly improving after hydroxychloroquine withdrawal. They hypothesize that pustular eruptions occurring in COVID-19 patients are more likely to support drug-related origin.<sup>26</sup> Gianotti et al described the histopathology of skin COVID-19 lesions with a spectrum of findings that ranged from mild spongiosis of the epithelial layer to the important situation of vasculitis and extravasation of red blood cells.<sup>6</sup> The scientific understanding of cutaneous manifestations in patients with COVID-19 is still evolving.

We believe that this work is the first study describing cutaneous manifestations of COVID-19 among HCW. However, several limitations must be considered. Due to evolving literature and language-related exclusion criteria, this paper only examines 218 cases. The inclusion of our cases was limited because of the low declaration by the patients and the quarantine restrictions. Moreover, publication bias was encountered. Drug side effects not mentioned in most of the studies must be taken into account. Also, occupation was not mentioned in several cases.

Further studies are still required to understand the mechanism and the link between skin lesions and COVID-19. So that prospective studies based on clinical and histological confrontations are needed.<sup>12</sup>

## 6 | CONCLUSIONS

In summary, COVID-19 has been associated with different cutaneous manifestations, likely of varying pathophysiology and severity, some preceding COVID-19 symptomatology and others occurring during active disease or later in the course. Given the evolving state of evidence, occupational physicians should be aware of the variety of skin manifestations related to COVID-19 among healthcare

workers. Thus, heightened awareness and timely recognition of dermatologic findings in COVID-19 are important for occupational physicians treating HCW with COVID-19. Further studies are still required to understand the mechanism and the link between skin lesions and COVID-19. So that prospective studies based on clinical and histological confrontations are needed.

## ACKNOWLEDGMENTS

None.

## CONFLICT OF INTEREST

No potential sources of conflict of interest are declared.

## AUTHOR CONTRIBUTIONS

I. Youssfi, N. Mechergui, N. Litaïem, and S. Gara have made substantial contributions to conception and design, the acquisition of data, analysis and interpretation of data; N. Mechergui, N. Litaïem, and I. Youssef have been involved in drafting the manuscript and revising it critically for important intellectual content; F. Zeglaoui, S. Rammeh, and N. Ladhari have given final approval of the version to be published. I. Youssfi agreed to be accountable for all aspects of the work in ensuring that questions related to the accuracy or integrity of any part of the work are appropriately investigated and resolved.

## ETHICAL APPROVAL

All patients gave their oral consent for publication of their clinical pictures.

## CONSENT

Written informed consent was obtained from patients to publish this report in accordance with the journal's patient consent policy.

## DATA AVAILABILITY STATEMENT

Data are available on request from the authors.

## ORCID

Youssfi Imen  <https://orcid.org/0000-0001-6068-887X>

Noureddine Litaïem  <https://orcid.org/0000-0002-9640-5613>

Soumaya Gara  <https://orcid.org/0000-0003-4477-9581>

## REFERENCES

1. Guo Y-R, Cao Q-D, Hong Z-S, et al. The origin, transmission and clinical therapies on coronavirus disease 2019 (COVID-19) outbreak – an update on the status. *Mil Med Res*. 2020;7:11.
2. Template: COVID-19 pandemic data [Internet]. In: Wikipedia. 2021 [cited July 07, 2021]. Available from: [https://en.wikipedia.org/w/index.php?title=Template:COVID19\\_pandemic\\_data&oldid=1032429307](https://en.wikipedia.org/w/index.php?title=Template:COVID19_pandemic_data&oldid=1032429307)

3. Han Y, Yang H. The transmission and diagnosis of 2019 novel coronavirus infection disease (COVID-19): a Chinese perspective. *J Med Virol*. 2020;92:639-644.
4. Coronavirus (COVID-19) events as they happen [Internet] [cited Jan 28, 2021]; Available from: <https://www.who.int/emergencies/diseases/novel-coronavirus-2019/event-s-as-they-happen>
5. Zhai P, Ding Y, Wu X, Long J, Zhong Y, Li Y. The epidemiology, diagnosis and treatment of COVID-19. *Int J Antimicrob Agents*. 2020;55:105955.
6. Gianotti R, Zerbi P, Dodiuk-Gad RP. Clinical and histopathological study of skin dermatoses in patients affected by COVID-19 infection in the Northern part of Italy. *J Dermatol Sci*. 2020;98:141-143.
7. Recalcati S. Cutaneous manifestations in COVID-19: a first perspective. *J Eur Acad Dermatol Venereol*. 2020;34:e212-e213.
8. Marzano AV, Genovese G, Fabbrocini G, et al. Varicella-like exanthem as a specific COVID-19-associated skin manifestation: multicenter case series of 22 patients. *J Am Acad Dermatol*. 2020;83:280-285.
9. Zhang Y, Cao W, Xiao M, et al. Clinical and coagulation characteristics of 7 patients with critical COVID-2019 pneumonia and acro-ischemia. *Zhonghua Xue Ye Xue Za Zhi*. 2020;41:E006.
10. Fernandez-Nieto D, Jimenez-Cauhe J, Suarez-Valle A, et al. Characterization of acute acral skin lesions in nonhospitalized patients: a case series of 132 patients during the COVID-19 outbreak. *J Am Acad Dermatol*. 2020;83:e61-e63.
11. Alramthan A, Aldaraji W. Two cases of COVID-19 presenting with a clinical picture resembling chilblains: first report from the Middle East. *Clin Exp Dermatol*. 2020;45(6):746-748.
12. Bouaziz JD, Duong TA, Jachiet M, et al. Vascular skin symptoms in COVID-19: a French observational study. *J Eur Acad Dermatol Venereol*. 2020;34:e451-e452.
13. Tammara A, Adebajo G, Parisella FR, Pezzuto A, Rello J. Cutaneous manifestations in COVID-19: the experiences of Barcelona and Rome. *J Eur Dermatol Venereol*. 2020;34(7):e306-e307.
14. Parhar G, Kalaji W, Sargi J, Adarkwah O, Zaman K, Gerolemou L. A case of erythematous and vesicular rash in a critically ill patient admitted with SARS-COV2: viral or multi-drug effect? *Chest*. 2020;158:A719.
15. Quintana-Castanedo L, Feito-Rodríguez M, Valero-López I, Chiloeches-Fernández C, Sendagorta-Cudós E, Herranz-Pinto P. Urticarial exanthem as early diagnostic clue for COVID-19 infection. *JAAD Case Rep*. 2020;6:498-499.
16. Boostani R, Talab FR, Meibodi NT, Zemorshidi F. COVID-19 associated with sensorimotor polyradiculoneuropathy and skin lesions: a case report. *J Neuroimmunol*. 2020;350:577434.
17. Najarian DJ. Morbilliform exanthem associated with COVID-19. *JAAD Case Rep*. 2020;6:493-494.
18. Jimenez-Cauhe J, Ortega-Quijano D, Prieto-Barrios M, Moreno-Arrones OM, Fernandez-Nieto D. Reply to « COVID-19 can present with a rash and be mistaken for dengue »: petechial rash in a patient with COVID-19 infection. *J Am Acad Dermatol*. 2020;83:e141-e142.
19. Mahé A, Birckel E, Krieger S, Merklen C, Bottlaender L. A distinctive skin rash associated with coronavirus disease 2019? *J Eur Acad Dermatol Venereol*. 2020;34:e246-e247.
20. Hunt M, Koziatek C. A case of COVID-19 pneumonia in a young male with full body rash as a presenting symptom. *Clin Pract Cases Emerg Med*. 2020;4:219-221.
21. Estébanez A, Pérez-Santiago L, Silva E, Guillen-Climent S, García-Vázquez A, Ramón MD. Cutaneous manifestations in COVID-19: a new contribution. *J Eur Acad Dermatol Venereol*. 2020;34(6):e250-e251.
22. Sachdeva M, Gianotti R, Shah M, et al. Cutaneous manifestations of COVID-19: report of three cases and a review of literature. *J Dermatol Sci*. 2020;98:75-81.
23. Tan SW, Tam YC, Oh CC. Skin manifestations of COVID-19: a worldwide review. *JAAD Int*. 2021;2:119-133. doi:10.1016/j.jdin.2020.12.003
24. ResearchGate [Internet] [cited 2021 Jul 7]; Available from: [https://www.researchgate.net/publication/339776846\\_Stigmatization\\_and\\_Quality\\_of\\_Life\\_in\\_Patients\\_with\\_Psoriasis/link/5e66728e4585153fb3cf48ad/download](https://www.researchgate.net/publication/339776846_Stigmatization_and_Quality_of_Life_in_Patients_with_Psoriasis/link/5e66728e4585153fb3cf48ad/download)
25. Suchonwanit P, Leerunyakul K, Kositkuljorn C. Cutaneous manifestations in COVID-19: lessons learned from current evidence. *J Am Acad Dermatol*. 2020;83:e57-60.
26. Litaïem N, Hajlaoui K, Karray M, Slouma M, Zeglaoui F. Acute generalized exanthematous pustulosis after COVID-19 treatment with hydroxychloroquine. *Dermatol Ther*. 2020;33:e13565.
27. Henry D, Ackerman M, Sancelme E, Finon A, Esteve E. Urticarial eruption in COVID-19 infection. *J Eur Acad Dermatol Venereol*. 2020;34:e244-e245.

**How to cite this article:** Imen Y, Mechergui N, Litaïem N, et al. Cutaneous manifestations of COVID-19 among healthcare workers: A Case report and literature review. *Clin Case Rep*. 2022;10:e05571. doi:[10.1002/ccr3.5571](https://doi.org/10.1002/ccr3.5571)