


Contents lists available at [ScienceDirect](https://www.sciencedirect.com)

Respiratory Medicine Case Reports

journal homepage: www.elsevier.com/locate/rmcr

Case Report

Severe COVID-19 disease in a 2nd trimester pregnancy: Successful ECMO and mechanical ventilation management

Barinder S. Hansra^{a,*}, Vidya K. Rao^b, Melissa A. Vogelsong^b, Stephen J. Ruoss^c^a Division of Cardiology and Department of Critical Care Medicine, University of Pittsburgh Medical Center, Pittsburgh, PA, 15213, USA^b Division of Anesthesia, Perioperative and Pain Medicine, Stanford University Medical Center, Stanford, CA, 94305, USA^c Division of Pulmonary, Allergy, and Critical Care Medicine, Stanford University Medical Center, Stanford, CA, 94305, USA

ARTICLE INFO

Keywords:

Venovenous ECMO
 Acute respiratory distress syndrome
 COVID-19
 Pregnancy
 Lung protective ventilation

ABSTRACT

Extracorporeal membrane oxygenation (ECMO) is an invasive support strategy for cardiac, respiratory, or combined cardiorespiratory failure. ECMO has become increasingly utilized in patients with severe respiratory failure due to COVID-19 infection. To our knowledge there is no report of successful ECMO utilization in second trimester of pregnancy leading to a successful outcome. We present a case of severe COVID-19 infection in a patient causing respiratory failure in the second trimester pregnancy. With diligent utilization of ECMO and mechanical ventilation we were able to support the patient's respiratory needs to allow her pregnancy to continue. Ultimately, the patient underwent successful caesarean section in the third trimester. This case highlights excellent lung injury protection and lung recovery can be achieved through optimal utilization of ECMO support together with a careful and closely monitored lung protective ventilation strategy, even while also supporting the patient through the increasing metabolic circumstances of a progressing pregnancy.

Abbreviations

ARDS acute respiratory distress syndrome
 COVID-19 coronavirus disease 2019
 ICU intensive care unit
 MFM maternal fetal medicine
 ΔP driving pressure (Pplat-PEEP)
 TEE transesophageal echocardiogram
 VV-ECMO venovenous-extracorporeal membrane oxygenation
 Tidal Volume VT

* Corresponding author.

E-mail address: hansrabs@upmc.edu (B.S. Hansra).

@rickyhansra (B.S. Hansra).

<https://doi.org/10.1016/j.rmcr.2022.101721>

Received 18 March 2022; Received in revised form 21 May 2022; Accepted 25 July 2022

Available online 10 August 2022

2213-0071/© 2022 The Authors. Published by Elsevier Ltd. This is an open access article under the CC BY-NC-ND license (<http://creativecommons.org/licenses/by-nc-nd/4.0/>).

1. Case presentation

A 34 year-old gravida 5, para 3 woman with past medical history of hypertension had new symptoms onset in late January 2021 at approximately 20.5 weeks gestation with dyspnea, dry cough, malaise and myalgias (Day 0, see Fig. 2 for clinical timeline). Outpatient clinical nasal swab RT-PCR testing revealed SARS-CoV-2. Due to lack of availability of COVID vaccine, she was non-vaccinated. Approximately nine to ten days after initial symptoms onset, the patient presented to an outside community hospital emergency department (ED) with worsening dyspnea and tachypnea. With significant hypoxemia in the ED, she was placed on high-flow nasal cannula oxygen support and was admitted to the community hospital. She was treated with ceftriaxone and azithromycin given concerns of superimposed community acquired pneumonia and was also started on dexamethasone; remdesivir was not prescribed given her gravid status. Over the five days in the outside hospital medical intensive care unit (MICU), she had evolving hypoxemic respiratory failure in the context of her second-trimester pregnancy and on day 14 of disease course she was intubated and then transferred on the same day (22^{5/7} weeks gestation) to Stanford Health Care hospital COVID-19 medical ICU.

The patient was placed on lung-protective ventilation strategy with volume-cycle assist-control (VC-AC) mechanical ventilation mode, with initial ventilator settings including tidal volume (VT) 360–380 mL, PEEP 16 cmH₂O, FiO₂ 0.60, respiratory rate 30 and a target lung driving pressure (P_{plat}-PEEP, Δ P) of ≤ 15 cmH₂O. Her sedation strategy utilized IV hydromorphone, dexmedetomidine, and propofol which was initially successful. The patient was also started on inhaled nitric oxide and was placed in the prone position. Although pronation was initially helpful in improving gas exchange, subsequent pronation after the first trial did not improve gas exchange, which worsened together with progressive infiltrates on chest radiographs (Fig. 1) and worsening lung compliance. Lung driving pressure (Δ P) had increased from 18 cmH₂O to 25 cmH₂O, and efforts to avoid increased lung stress resulted in mounting hypercapnia with a PaCO₂ of 60 mmHg up to 75 mmHg despite increased ventilator respiratory rate to 36. Oxygenation was adequate with a PaO₂ greater than 60 mmHg on FiO₂ of 0.80–0.90, but mounting hypercapnia signaled progressive failure of mechanical ventilation. Ventilator settings at this point were VC-AC mode, VT 300mL, PEEP 14–16 cmH₂O, ventilator rate 36, FiO₂ 0.9; achieved Δ P was 24–25 cmH₂O. Arterial blood gas testing revealed a pH 7.27, PaCO₂ 75 mmHg, and PaO₂ of 88 mmHg. A multidisciplinary discussion involving the medical ICU, cardiothoracic surgery teams, the maternal and fetal medicine (MFM) service, and patient's husband was held, and the decision was made to initiate VV-ECMO support for her severe and worsening overall lung function in the face of her early second trimester pregnancy and anticipated substantially increased metabolic needs over the period of added gestation to get the patient to the point where she might have a viable fetus. MFM was stressed over fetal viability at that point. On day 18 of disease course (23^{4/7} weeks gestation), she was transferred to the cardiovascular ICU (CVICU) for initiation of ECMO support.

On the day of transfer to the CVICU, VV-ECMO was initiated with a 25F drainage cannula inserted into a proximal IVC position via the right femoral vein, and an 18F return cannula into the SVC via the right internal jugular vein, with no complications; cannula position was verified by transesophageal echocardiography (TEE).

With the patient on VV-ECMO support, mechanical ventilation was adjusted with a very low volume and pressure protective strategy. For the initial two weeks of ECMO, the patient was sedated very heavily to control for agitation and delirium, and was on pressure-cycle assist-control (PC-AC) mode, with inspiratory pressure (PIP) 25 cmH₂O and PEEP 12 cmH₂O, for achieved Δ P of ~ 13 cmH₂O. In order to better reduce and control Δ P and lung protection, mechanical ventilation mode was changed to VC-AC at two weeks of ECMO support, with VT 120 mL, PEEP 12 cmH₂O, ventilator rate 10, and FiO₂ 0.60 (with subsequent further FiO₂ reduction). This produced a Δ P of 8–12 cm H₂O. The patient's lung compliance at time of initiation of ECMO was 5–6 mL/cmH₂O. Subsequent daily respiratory management included monitoring Δ P and lung compliance, and adjusting VT and PEEP to optimize low Δ P and support VT as needed in order to minimize added lung injury. Lung compliance remained in the range of 10–12 cmH₂O through at least the first two weeks of ECMO support. Notably, while the patient's CXR radiographic pattern improved around day 36 of disease course (Fig. 1), lung compliance was slower to improve than the radiographs. With continued emphasis on monitoring Δ P and regular assessment of lung compliance, we provided increasing VT as lung compliance improved, particularly in later phases of her ECMO and ICU course. The patient's initial VT of 120 mL was maintained for 6 days. On ECMO day 20 we increased the VT to 250 mL and to 300 mL by ECMO day 25. Lung compliance was improved by ECMO day 25, though still notably abnormal at 15–18 mL/cmH₂O, with Δ P remaining below 15 cmH₂O (Table 1).

Through the 50 days of ECMO support, the patient's ECMO blood flow ranged from 3 to 4.5 L/min. Oxygenator sweep gas O₂ fraction (F_DO₂) was set at 1.0, and sweep gas flow ranged from 2 to 30 L/min, with successive increase in ECMO sweep gas flow over the course of her increasing duration pregnancy, growing metabolic rate, and ongoing ECMO support.

Systemic anticoagulation was initiated concurrent with the institution of ECMO and continued throughout her ECMO course, with exception of the period around her caesarean section delivery (Fig. 2). Argatroban was used initially due to initial concerns for heparin-induced thrombocytopenia (excluded by subsequent testing), and continued per cannulating surgeon preference until later in gestation when fetal viability and the potential for cesarean section delivery had increased, at which point her continuous anticoagu-

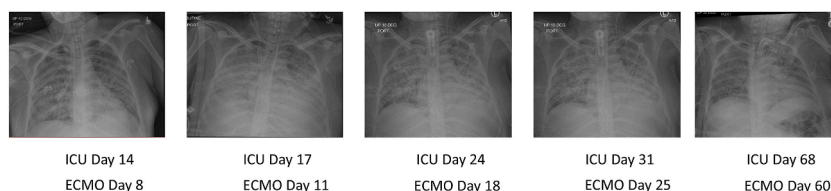
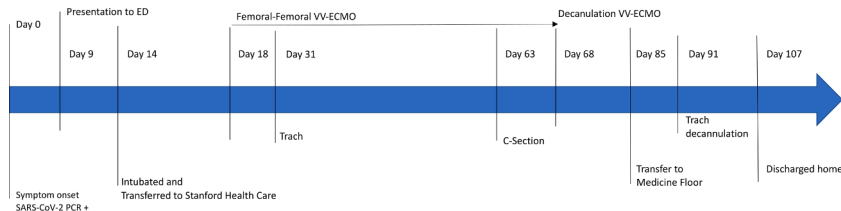


Fig. 1. Sequential chest radiographs during intensive care course while on ECMO.

Table 1

Ventilation strategy. PC-AC = Pressure Control Assist Control, VC-AC = Volume Control Assist Control.

| Time | Mode | VT | PEEP | Peak Inspiratory Pressure | Transpulmonary Pressure | Lung Compliance |
|-----------|-------|-------|------|---------------------------|-------------------------|-----------------|
| Day 14–23 | PC-AC | | 12 | 28–30cmH2O | | 5–6cmH2O |
| Day 24 | VC-AC | 120mL | | | 10–12cmH2O | 10–12cmH2O |
| Day 38 | VC-AC | 250mL | 12 | | | |
| Day 42 | VA-AC | 300mL | 12 | | 15–18cmH2O | 15–18cmH2O |

**Fig. 2.** Patient timeline. VV-ECMO = venovenous-extracorporeal membrane oxygenations, Trach = tracheostomy, C-section = cesarean section.

lation regimen was changed to heparin. Heparin infusion was stopped 6 hours before delivery of the fetus by cesarean section, then resumed approximately 18 hours after the caesarean section delivery. She then developed new anemia together with some abdominal distension and was then taken back to the operating room for surgical exploration, peritoneal washout and ligation of inferior epigastric arterial branch bleeding that had caused the hemoperitoneum. No further bleeding was encountered and she was resumed on heparin anticoagulation without added complication.

On February 24th, 2021 (day 31 of disease course. ECMO day 13) the patient underwent percutaneous tracheotomy with a #8 Shiley tracheotomy tube. From the onset of the patient's care in the CTICU, concurrent management assistance was available from additional services, including Maternal Fetal Medicine, High-Risk Obstetrics, Obstetrical Anesthesiology, Cardiac Anesthesiology, and CardioThoracic Surgery teams. Weekly meetings for patient and fetal review were held from the start of her admission to the CTICU for ECMO and ICU support, and included members of the CTICU team, High-Risk Obstetrics, Maternal Fetal Medicine and Obstetrical Anesthesiology. Once gestational age had reached 23 weeks, more intensive monitoring was instituted, including daily fetal heart monitoring. Steroids were administered for assistance in fetal lung maturation.

On day 62 of disease course, (ECMO day 45) the patient developed frequent uterine contractions on monitoring without any cervical changes via examination by the MFM team. This was accompanied by minor and short fetal heart rate decrements. Over a subsequent 12 hour period, uterine contractions increased and another multidisciplinary team meeting between ICU and MFM teams was held with the patient's husband to discuss need for caesarean section, which was successfully completed in the OR while being supported on VV-ECMO on day 63. The infant was admitted to the Neonatal ICU (NICU) from the OR. Initial APGAR was 8. He had some mild respiratory distress, and was supported with intermittent non-invasive mask ventilation support. He was negative on all COVID testing. He was discharged from the NICU after two weeks, and was discharged home to his family after an added two weeks in hospital. He is healthy and achieving normal growth and development milestones.

On day 68 since initial symptom onset, after being on ECMO support for 50 days, the patient was successfully weaned off ECMO support and underwent successful decannulation. The ECMO circuit blood was saved in a citrated blood bag and then returned to the patient. On day 69, the patient was transferred to the medical ICU for on-going care, and on day 85 was transferred out of the ICU. She continued to improve, with tracheostomy decannulated on day 91, and she was discharged home on day 107 (Fig. 2); her new son joined the patient at home two weeks later.

On outpatient evaluation two months after hospital discharge, the patient reported improving muscle fatigue and weakness with near normal ambulatory activity level, and no respiratory complaints, including an absence of dyspnea or cough. Added testing at that time included pulmonary testing and chest CT radiography. Pulmonary function test results included: forced vital capacity (FVC) 2.87 L (78% predicted), forced expiratory volume in 1 s (FEV1) 2.5 L (86% predicted with no change after albuterol), FEV1/FVC ratio 0.87, total lung capacity (TLC) 3.63 L (71% predicted), and diffusing capacity for carbon monoxide (DLCO) 15.6 mL/min/mmHg (66% predicted). The accompanying contemporaneous chest CT scan demonstrated minimal anterior and apical linear pleural based scarring in bilateral upper lobes, with full resolution of the previously noted extensive and diffuse ground glass and consolidative parenchymal abnormalities.

2. Discussion

Extracorporeal membrane oxygenation (ECMO) is an invasive support strategy for cardiac, respiratory, or combined cardiorespiratory failure when conventional treatment options have failed [1]. Venovenous-extracorporeal membrane oxygenation (VV-ECMO) has been utilized for patients with severe acute respiratory distress syndrome (ARDS) due to coronavirus disease 2019 (COVID-19) with survival rates similar to those reported for ECMO support of ARDS due to other causes [2]. Given the dramatic changes occurring during pregnancy, particularly immunomodulatory, these patients are at increased susceptibility to respiratory infections and may be a nidus for severe presentations of the disease [3,4]. Published case reports of pregnant women with acute COVID-19 disease who were supported with VV-ECMO describe good outcomes [1,8]. But the published series included multiple peri- and post-partum

women, and none of the reported cases involved women earlier in pregnancy than third trimester gestations, so that the clinical issues, including time frame for requiring support of severe respiratory failure, were of more limited physiological scope and duration [5]. It is thus of substantial and currently unique clinical import that we report herein a second trimester gestation women with severe COVID-19 ARDS requiring mechanical ventilation plus VV-ECMO [6]. This clinical case offers important and unique perspectives into the added complexities of successful and extended duration management of severe respiratory distress from COVID-19 with mechanical ventilation plus VV-ECMO, with focus on the successful efforts to protect against chronic lung injury.

This case is noteworthy in a number of aspects. This represents, to our knowledge, the earliest fetal gestational age where a pregnant woman with severe COVID pneumonia and respiratory failure was supported with mechanical ventilation plus VV-ECMO to successful delivery. And it is the longest reported VV-ECMO course in a pregnant woman where successful maternal as well as fetal outcome were achieved. Very importantly, this case also highlights that excellent lung injury protection and lung recovery can be achieved through optimal utilization of ECMO support together with a careful and closely monitored lung protective ventilation strategy, even while also supporting the patient through the increasing metabolic circumstances of a progressing pregnancy. Our protective ventilation efforts capitalized on not only her concurrent ECMO gas exchange support, but also on the evolved better understanding of the need to monitor lung compliance and delivered driving pressure as we adjusted mechanical ventilation to reduce lung stress, and thus reduce added lung injury over the prolonged period required to achieve resolution of acute SARS-CoV-2 mediated lung injury. Following published data and guidance, we were able to keep ΔP less than 15 cmH₂O [7], and our ventilation strategy focused on limited VT in preference over ventilator frequency to limit mechanically delivered power, as appears to be an optimal strategy in more severe lung injury [8]. When the course of resolution of acute injury is so prolonged, as it was in this clinical circumstance, and has been in other successful COVID ARDS resolution cases, it is yet more important to limit the delivered ventilation power and thus limit added lung injury.

With the patient's 23-week gestation at the time of ECMO initiation, plus the expectation that her severe COVID-19 disease plus the progressive metabolic and gas exchange loads associated with her pregnancy would increase her need for ECMO support over time. Given these considerations, ECMO cannulation utilized a standard femoral venous to right internal jugular venous cannulation configuration, which allowed for optimized ECMO gas exchange for the patient and her pregnancy. ECMO support also anticipated greater O₂ demand and delivery with her pregnancy and the maternal-to-fetal O₂ transfer, where typical maternal O₂ loading is assisted by progesterone-induced ventilatory drive and alkalosis. With her severe respiratory failure, compensation with increased ECMO sweep produced the systemic alkalosis her intrinsic lung function could not achieve, and augmented O₂ loading for optimal systemic and fetal O₂ delivery.

Lastly, our team was cognizant of the proper sedation management to ensure ventilator synchrony but also not harm the growing fetus. Paralytic agents were not used while the patient was intubated. Our MFM team was directly and consistently involved in the patient's care and contributed greatly with recommendations regarding sedation. We avoided any medications either with uncertain or suspected fetal neurotoxicity risks, or drugs known to potentially risk fetal neuro-developmental and/or -functional problems such as phenobarbital and propofol.

3. Conclusion

We experienced a severe case of COVID-19 infection in a pregnant patient requiring VV-ECMO due to severe ARDS. With diligent use of ventilatory management and VV-ECMO support, we were able to have a successful outcome.

Disclosures

None.

Source of funding

None.

Author contributions

All four authors were heavily involved in caring for the patient and preparing this manuscript.

Declaration of competing interest

None of the authors have any conflict of interests to declare for this case report.

References

- [1] J.H. Barrantes, J. Ortoleva, E.R. O'Neil, E.E. Suarez, S. Beth Larson, A.S. Ral, C. Agerstrand, L. Grazioli, S. Chatterjee, M. Anders, Successful treatment of pregnant and postpartum women with severe COVID-19 associated acute respiratory distress syndrome with extracorporeal membrane oxygenation, *Am Soc for Art Int Organ* 67 (2) (2021) 132–136.
- [2] R.P. Barbaro, G. MacLaren, P.S. Boonstra, T.J. Iwashyna, A.S. Slutsky, E. Fan, R.H. Bartlett, J.E. Tonna, R. Hyslop, J.J. Fanning, P.T. Rycus, S.J. Hyer, M.M. Anders, C.L. Agerstrand, K. Hryniewicz, R. Diaz, R. Lorusso, A. Combes, D. Brodie, Extracorporeal life support organization. Extracorporeal membrane oxygenation support in COVID-19: an international cohort study of the extracorporeal life support organization registry, *Lancet* 396 (2020) 1071–1078.
- [3] Y.H. Chen, J. Keller, I.T. Wang, C.C. Lin, H.C. Lin, Pneumonia and pregnancy outcomes: a nationwide population-based study, *Am. J. Obstet. Gynecol.* 207 (4) (2012) <https://doi.org/10.1016/j.ajog.2012.08.023>, 288.e1-288.e2887.
- [4] Center for Disease Control and Prevention (CDC), Data on COVID-19 during pregnancy, Available at: <https://www.cdc.gov/coronavirus/2019-ncov/cases->

- [updates/special-populations/pregnancy-data-on-covid-19.html](https://www.who.int/news-room/updates/special-populations/pregnancy-data-on-covid-19.html), 2021. (Accessed 25 March 2021).
- [5] A.S. Slutsky, V.M. Ranieri, Mechanical ventilation: lessons from the ARDSNet trial, *Respir. Res.* 1 (2) (2000) 73–77, <https://doi.org/10.1186/rr15>.
 - [6] K.M. Douglas, K.M. Strobel, M. Richley, T. Mok, A. de St Maurice, V. Fajardo, A.T. Young, R. Rao, L. Lee, P. Benharash, A. Chu, Y. Afshar, Maternal-neonatal dyad outcomes of maternal COVID-19 requiring extracorporeal membrane support: a case series, *Am. J. Perinatol.* 38 (2021) 82–87.
 - [7] M.B.P. Amato, Mo Meade, A.S. Slutsky, L. Brochard, E.L.V. Costa, D.A. Schoenfeld, T.E. Stewart, M. Briel, Talmor Daniel, A. Mercat, J.C.M. Richard, C.R.R. Carvalho, et al., Driving pressure and survival in the acute respiratory distress syndrome, *N. Engl. J. Med.* 372 (2015) 747–755, <https://doi.org/10.1056/NEJMsa1410639>.
 - [8] E.L.V. Costa, A.S. Slutsky, L.J. Brochard, R. Brower, A. Serpa-Neto, A.B. Cavalcanti, A. Mercat, M. Meade, C.C.A. Morais, E. Goligher, C.R.R. Carvalho, M.B.P. Amato, Ventilatory variable and mechanical power in patients with acute respiratory distress syndrome, *Am. J. Respir. Crit. Care Med.* 204 (3) (2021) 303–311, <https://doi.org/10.1164/rccm.202009-3467OC>.