

[CASE REPORT]

Familial Dysalbuminemic Hyperthyroxinemia that was Inappropriately Treated with Thiamazole Due to Pseudo-thyrotoxic Symptoms

Takahiro Fukaishi, Yoshihiro Sekiguchi and Yoshihito Hara

Abstract:

We herein report the case of a Japanese woman with familial dysalbuminemic hyperthyroxinemia (FDH) who was initially diagnosed with Graves' disease. Direct genomic sequencing revealed a guanine to cytosine transition in the second nucleotide of codon 218 in exon 7 of the albumin gene, which then caused a proline to arginine substitution. She was finally diagnosed with FDH, which did not require treatment. FDH is - superficially - an uncommon cause of syndrome of inappropriate secretion of thyrotropin (SITSH) in Japan. A misdiagnosis of pseudo-hyperthyroidism will lead to inappropriate treatment. Thus, physicians should strongly note the possibility of FDH as a differential diagnosis of SITSH.

Key words: familial dysalbuminemic hyperthyroxinemia (FDH), SITSH, thiamazole

(Intern Med 56: 2175-2180, 2017)

(DOI: 10.2169/internalmedicine.8619-16)

Introduction

Familial dysalbuminemic hyperthyroxinemia (FDH) is a familial autosomal dominant condition that was first reported in 1979 (1, 2). It is caused by an abnormal albumin molecule with an increased affinity for serum thyroxine (T₄), despite the serum albumin level being quantitatively normal. The serum free T₄ (FT₄) and free triiodothyronine (FT₃) levels are falsely increased, while the serum thyrotropin (TSH) levels are normal, similarly to syndrome of inappropriate secretion of TSH (SITSH). As FDH patients are clinically euthyroid and asymptomatic, they do not require treatment.

Some point mutations in the albumin gene are known to cause FDH. Initially, the point mutation in the second nucleotide of codon 218 of the albumin gene, a guanine to adenine substitution, which results in an arginine to histidine substitution (R218H), was reported to cause FDH in 1994 (3). Then, a novel missense mutation, a guanine to cytosine substitution, which resulted in an arginine to proline substitution (R218P), was reported in Japan in 1997 (4). There have been reports of FDH in patients with other novel

missense mutations, such as R218S (arginine to serine), R222I (arginine to isoleucine) and L66P (leucine to proline) (5-7).

FDH is a common cause of euthyroid hyperthyroxinemia, particularly among Caucasians. However, the condition is very rare among Asians including people of Japanese descent. In Japanese individuals, TSH-secreting pituitary adenoma (TSHoma) and resistance to thyroid hormone (RTH) are much more common as causes of SITSH than FDH. However, patients with FDH due to a R218P mutation, which is common among Japanese patients, show relatively higher T₄ and T₃ levels in comparison to patients with FDH due to the R218H mutation that is common among Caucasian patients. Thus, it is thought that the R218P pattern can more easily lead to an erroneous diagnosis than the R218H pattern because most of Japanese physicians are not familiar with FDH. In fact, the number of Japanese case reports of FDH is still limited and a greater number of cases should be accumulated.

We herein report the case of a Japanese woman with FDH that was caused by an R218P mutation in the albumin gene. The patient was initially diagnosed with Graves' disease because she displayed characteristic symptoms and was treated

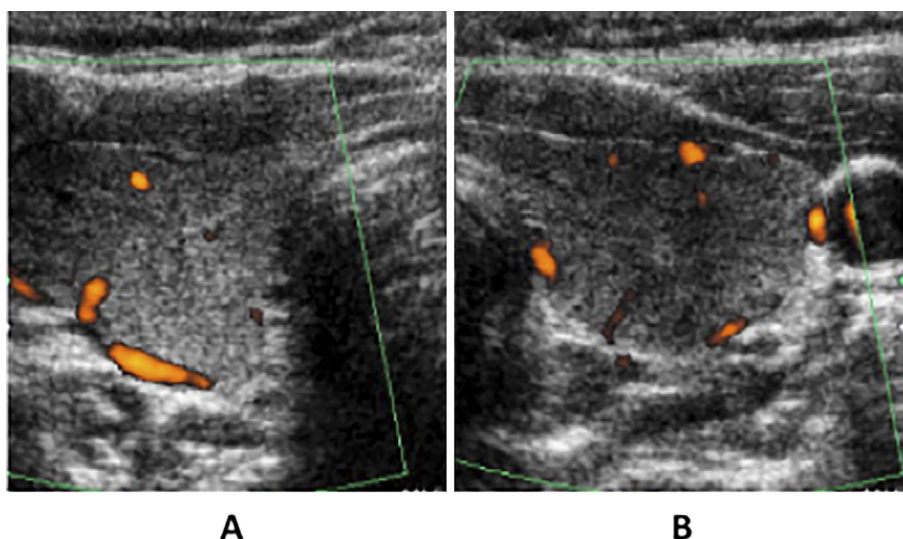


Figure 1. Ultrasonography showing the low blood flow in the thyroid. A: Right lobe, B: Left lobe.

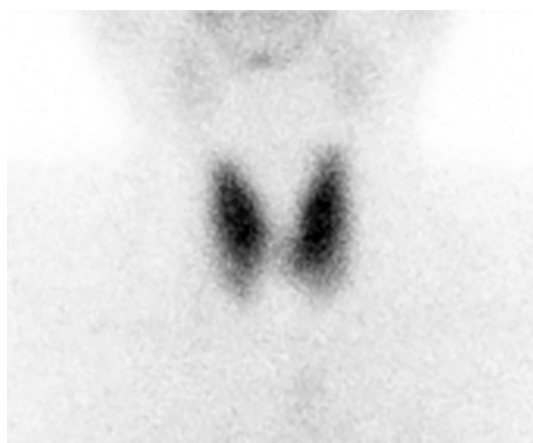

Figure 2. Thyroid ^{99m}Tc scintigraphy showed the normal uptake of technetium into the thyroid (2.2%, normal: 0.5-3.5).

with thiamazole for three months. In order to avoid inappropriate treatment for pseudo-hyperthyroidism (euthyroid hyperthyroxinemia) the differential diagnosis between FDH and other thyroid diseases that show SITSH or hyperthyroidism, including Graves' disease, is very important.

Case Report

A 38-year-old Japanese woman was referred to our hospital with suspected hyperthyroidism. She reported experiencing tremor, insomnia, diarrhea, weight loss and anxiety for approximately one year. As these symptoms had worsened, she visited another hospital, where she was diagnosed with hyperthyroidism. It was then recommended that she visit our hospital.

The patient was born in Saitama prefecture, while her mother was born in Aomori prefecture. She had no family history of thyroid disease. On the other hand, she was almost broken off from her parents and had become alienated from her brother. She denied any major past medical history

but had visited psychiatric hospitals several times due to her family affairs.

Her BMI was 24.6 kg/m^2 ; however, she had lost 12 kg of body weight in one year. Her vital signs were within the normal limits, with the exception of mild tachycardia (93 beats per minute). Her physical findings revealed no exophthalmos, finger tremors, skin wetness, goiter, or thyroid tenderness. An ultrasound examination of the thyroid revealed almost normal findings (volume: 18.5 mL), with the exception of low blood flow, which seemed atypical for Graves' disease (Fig. 1). Laboratory tests revealed mild dyslipidemia and an extremely increased FT4 level ($>8.0 \text{ ng/dL}$, normal: 0.8-1.9), a moderately increased FT3 level (5.0 pg/mL , normal: 2.2-4.1) but a normal TSH level ($0.73 \text{ } \mu\text{IU/mL}$, normal: 0.4-4.0). The patient was negative for all thyroid-associated autoantibodies (data not shown), but her serum thyroglobulin level was slightly increased (196.8 ng/mL). Thyroid ^{99m}Tc scintigraphy revealed the normal uptake of technetium into the thyroid (2.2%, normal: 0.5-3.5) (Fig. 2). These data were not typical for Graves' disease. However, treatment with thiamazole was initiated due to the presence of typical symptoms such as weight loss, tremor, diarrhea and insomnia (Fig. 3). After that, there was no improvement in her thyroid function. Her TSH levels then started to increase to $23.63 \text{ } \mu\text{IU/mL}$. Thiamazole was therefore ceased after three months. Levothyroxine treatment was initiated to treat thiamazole-induced hypothyroidism. Her thyroid function then returned to the initial state. Her symptoms, which were similar to Graves' disease, seemed to be associated with psychiatric problems rather than thyroid dysfunction and she was diagnosed with adjustment disorder. The administration of sulpiride improved her general condition, and the administration of levothyroxine was ceased.

The patient showed an SITSH state but magnetic resonance imaging (MRI) of the pituitary gland revealed no changes; thus, it was unlikely that a TSH-secreting pituitary adenoma had caused SITSH. We then carried out direct

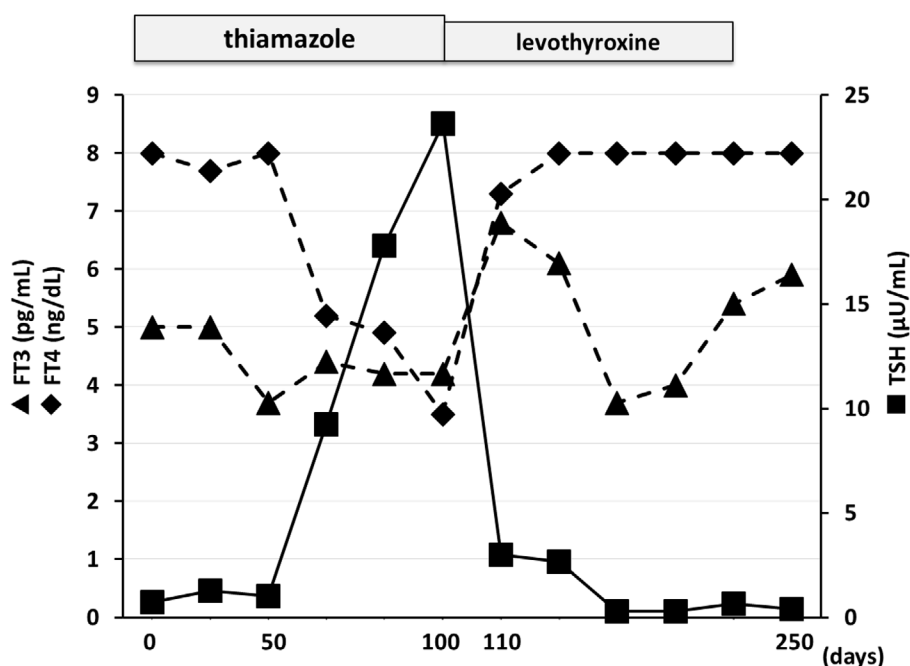


Figure 3. The clinical course of the present case. Values of >8.0 ng/dL are shown as 8.0 ng/dL. FT3: free triiodothyronine, FT4: free thyroxine, TSH: thyrotropin

genomic sequencing studies after obtaining informed consent. Initially, RTH was suspected. Exons 4-10 of her thyroid receptor β (TR β) gene were subjected to direct sequencing, but showed no mutations. Then, FDH was suspected despite the lack of a specific family history. The exons of her albumin gene were subjected to direct sequencing, which revealed a guanine to cytosine transition in the second nucleotide of codon 218 in exon 7. This point mutation, which was heterozygous, then caused a proline to normal arginine substitution (Fig. 4). This point mutation is often seen in FDH patients, particularly in Japanese cases. Thus, we finally reached the diagnosis of FDH. Though her total T4 (TT4) (119 μ g/dL, normal: 4.8-10.5) and total T3 (TT3) (272 ng/dL, normal: 70-176) levels were extremely increased, her T4-binding globulin (TBG) level was normal (22.1 μ g/mL, normal: 12.0-28.0). She had been married, but had no children. As mentioned previously, she was alienated from her other family members, so we could not carry out genomic sequencing for the other members of her family.

Since the end of treatment, she has taken no thyroid-related medications. Her laboratory data continue to show an extreme increase in FT4, a moderate increase in FT3 and normal TSH, but none of her symptoms has been recurrent.

The serum FT3 level was measured by the competitive enzyme immunoassay method with anti-T3 rabbit monoclonal antibodies by an ST AIA-PACK iFT3 kit (TOSOH, Tokyo, Japan) and the serum FT4 level was measured with anti-T4 rabbit monoclonal antibodies by an ST AIA-PACK iFT4 kit (TOSOH, Tokyo, Japan). We did not try to measure these levels using different kits. The serum TSH level was measured by the two-site immunoenzymometric assay method with anti-TSH mouse monoclonal antibodies by an ST AIA-PACK TSH kit (TOSOH, Tokyo, Japan).

The serum TT3 and TT4 levels were measured by the electro-chemiluminescence immunoassay (ECLIA) method with delayed-back titration assays using ECLusys T3 II and T4 II kits, respectively (Roche Diagnostics, Tokyo, Japan) and TgAb, TPOAb and TRAb were by an ECLIA with a competitive immunoassay using the ECLusys anti-TG, anti-TPO and TRAb kits, respectively (Roche Diagnostics, Tokyo, Japan).

Genomic DNA was isolated from white blood cells by the standard method using pronase digestion and phenol-chloroform extraction. Regions including codon 218 in exon 7 of albumin gene were amplified using the 5'-gataagtgttaccatttggcaga-3' and 5'-CATTCCGTGTGGACTTTGGTAA-3' primer and the sequence was determined as previously described.

Discussion

FDH is the most common hereditary disease to cause euthyroid hyperthyroxinemia in Caucasians. The highest prevalence, which occurs in communities of Portuguese or Hispanic origin (8), is estimated to be 1 in 10,000 individuals (6). However, the number of case reports on Japanese FDH patients is limited and the recognition regarding FDH remains low, even among endocrinologists, let alone general physicians. In many cases, FDH patients have been misdiagnosed with hyperthyroidism and anti-thyroid drugs have been erroneously administered, as occurred in the present case (4, 9, 10). In the present case, the patient's TSH level was slightly low but was within normal range; thus, the thyroid function was thought to reflect SITSH rather than hyperthyroidism. It seemed to be atypical for Graves' disease; however, the rate of uptake in thyroid scintigraphy was

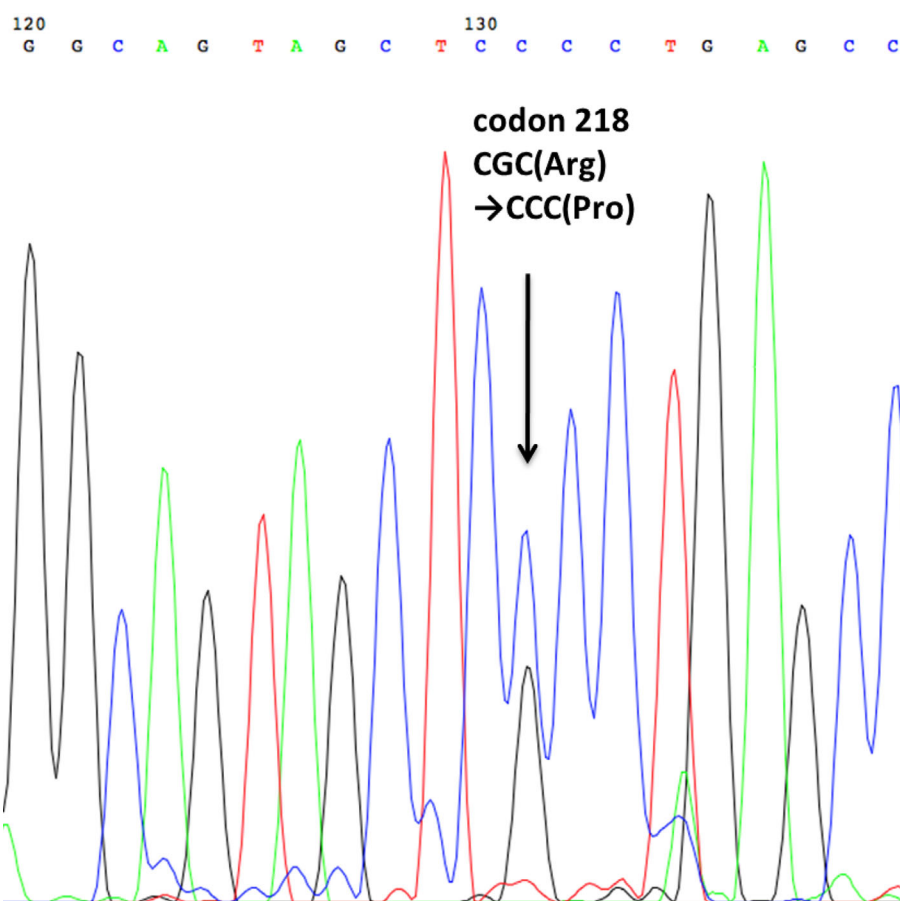


Figure 4. The DNA sequence of exon 7 in the albumin gene of the present case.

Table. 6 Cases of FDH Reported in Japan.

Age (years)	Sex	Origin	TSH (μIU/mL)	FT4 (ng/dL)	FT3 (pg/mL)	TT4 (μg/dL)	TT3 (ng/dL)	Use of anti-thyroid drug	Reference No
32	F	Hokkaido	1.71	>9.3	17.5	182	225	Yes	4
32	F	ND	0.21	5.4	4.2	140	169	Yes	10
29	F	ND	0.86	>7.8	8.9	133	241	No	10
33	F	Aomori	0.53	>12.0	5.9	92	325	No	13
40	M	Aomori	0.74	5.92	5.46	25	232	No	14
38	F	Saitama	0.73	>8.0	5.0	119	272	Yes	Present case
normal range			0.4-4.0	0.8-1.9	2.2-4.1	4.8-10.5	70-176		

FDH: familial dysalbuminemic hyperthyroxinemia, TSH: thyrotropin, FT4: free thyroxine, FT3: free triiodothyronine, TT4: total thyroxine, TT3: total triiodothyronine, F: female, M: male, ND: not determined

within the normal range, despite the patient's hyperthyroxinemia. Moreover, as her accompanying symptoms seemed to be similar to those with thyrotoxicosis, thiamazole was erroneously administered. The common causes of SITSH in Japanese patients are TSHoma and RTH. However, when these diseases are excluded, we should consider FDH in the differential diagnosis of SITSH. Nakamura et al. reported another novel SITSH state, familial dysalbuminemic hypertriiodothyroninemia in 2000 (11). In that case, thiamazole was also administered.

The point mutations in the albumin genes vary in FDH patients in other countries. While the most common mutation, as initially reported by Petersen et al. (3), is R218H, it

has been reported that the mutation can be traced back to one common ancestor (12). However, only four case reports on Japanese patients with FDH (4, 10, 13, 14) have been published thus far (Table). Interestingly, all of the Japanese cases, including the present case have the same point mutation in their albumin gene, R218P. All of the reports were from the east side of Japan (Hokkaido, Tohoku and Kanto district). Osaki et al. pointed out that a large number of FDH patients, including unpublished cases, were from Aomori prefecture (14). In fact, the mother of the present case was also from Aomori prefecture. Thus, there may be also one common ancestor in the Japanese cases. There are some reports of FDH in other Asian countries, including China,

Hong-Kong and Thailand; however, the point mutations in their albumin gene were R218H and L66P; thus, their ancestor may differ from that of the Japanese cases (7, 9, 15). There is only one report of a R218P mutation in another country, in a case that occurred in Switzerland (8); however, considering its geographical distance, it is possible that it was independent from the Japanese cases.

Previous reports have revealed that the patients with a R218P mutation in their albumin gene showed much higher TT4 levels in comparison to patients with R218H mutations because the affinity of albumin for T4 was much higher in FDH patients with R218P. The TT4 level in the present case was 119 µg/dL and was approximately 10-fold higher than the normal upper limit (10.5 µg/dL), which was similar to the previous cases. An increased TT3 level has only been reported in patients with the R218P mutation (8). The TT3 level in the present case was 272 ng/dL, which was 1.6-fold higher than the upper normal limit (176 ng/dL), which was also similar to the previous cases.

The Japanese FDH cases, all of which have R218P mutations, could easily be misdiagnosed as other diseases, such as SITSH and hyperthyroidism including Graves' disease than FDH cases in other countries due to their high serum T4 and T3 levels. Moreover, as the symptoms of our patient were very similar to those of patients with hyperthyroidism due to psychiatric problems, thiamazole was unnecessarily administered.

The autosomal dominant manner of heredity suggests that there are more patients with "latent FDH". In fact, previous reports revealed that most of the family members of the patients were also affected by FDH. FDH is usually detected by chance because it has no accompanying symptoms. In order to avoid unnecessary treatment, both endocrinologists and general physicians should be aware of this condition. In the present case, the patient's hypothyroidism due to thiamazole was reversible. However, a precise diagnosis is crucial because other treatments for hyperthyroidism, such as radioiodine therapy and thyroidectomy, can lead to irreversible hypothyroidism.

In conclusion, we reported the case of a Japanese woman with FDH who had a point mutation of R218P in her albumin gene. The patient presented extreme hyperthyroxinemia due to the high affinity of albumin for T4, similarly to the other Japanese cases. FDH is still not widely known, even among endocrinologists, let alone general physicians. Thus, the condition may be misdiagnosed, which can lead to erroneous treatment that has the potential to cause irreversible hypothyroidism-especially in Japanese cases, in which patients always present extreme hyperthyroxinemia. As FDH has an autosomal dominant manner of heredity, there must be more undiagnosed FDH patients, especially on the eastern side of Japan. We should consider FDH as a differential diagnosis of SITSH.

The authors state that they have no Conflict of Interest (COI).

Acknowledgement

We thank Dr. Yoshitaka Hayashi and Dr. Yoshiharu Murata, Department of Genetics, Research Institute of Environmental Medicine, Nagoya University, Japan for their valuable assistance in the genomic DNA sequencing.

References

- Lee WN, Golden MP, Van Herle AJ, Lippe BM, Kaplan SA. Inherited abnormal thyroid hormone-binding protein causing selective increase of total serum thyroxine. *J Clin Endocrinol Metab* **49**: 292-299, 1979.
- Hennemann G, Docter R, Krenning EP, Bos G, Otten M, Visser TJ. Raised total thyroxine and free thyroxine index but normal free thyroxine. A serum abnormality due to inherited increased affinity of iodothyronines for serum binding protein. *Lancet* **1**: 639-642, 1979.
- Petersen CE, Scottolini AG, Cody LR, Mandel M, Reimer N, Bhagavan NV. A point mutation in the human serum albumin gene results in familial dysalbuminaemic hyperthyroxinaemia. *J Med Genet* **31**: 355-359, 1994.
- Wada N, Chiba H, Shimizu C, Kijima H, Kubo M, Koike T. A novel missense mutation in codon 218 of the albumin gene in a distinct phenotype of familial dysalbuminemic hyperthyroxinemia in a Japanese kindred. *J Clin Endocrinol Metab* **82**: 3246-3250, 1997.
- Greenberg SM, Ferrara AM, Nicholas ES, et al. A novel mutation in the albumin gene (R218S) causing familial dysalbuminemic hyperthyroxinemia in a family of Bangladeshi extraction. *Thyroid* **24**: 945-950, 2014.
- Schoenmakers N, Moran C, Campi I, et al. A novel albumin gene mutation (R222I) in familial dysalbuminemic hyperthyroxinemia. *J Clin Endocrinol Metab* **99**: 1381-1386, 2014.
- Sunthornthepvarakul T, Likitmaskul S, Ngowngarmratana S, et al. Familial dysalbuminemic hypertriiodothyroninemia: a new, dominantly inherited albumin defect. *J Clin Endocrinol Metab* **83**: 1448-1454, 1998.
- Pannain S, Feldman M, Eiholzer U, Weiss RE, Scherberg NH, Refetoff S. Familial dysalbuminemic hyperthyroxinemia in a Swiss family caused by a mutant albumin (R218P) shows an apparent discrepancy between serum concentration and affinity for thyroxine. *J Clin Endocrinol Metab* **85**: 2786-2792, 2000.
- Tang KT, Yang HJ, Choo KB, Lin HD, Fang SL, Braverman LE. A point mutation in the albumin gene in a Chinese patient with familial dysalbuminemic hyperthyroxinemia. *Eur J Endocrinol* **141**: 374-378, 1999.
- Nagano H, Takiguchi T, Nakayama T, et al. Two familial abnormally albuminous hyperthyroxinemia and T4-binding biochemical analysis. *Nihon Naibunpitsu Gakkai Zasshi (Folia Endocrinol Jpn)* **89** (Suppl): 36-39, 2013 (in Japanese).
- Nakamura S, Kajita Y, Ochi Y. Familial dysalbuminemic hypertriiodothyroninemia in a Japanese kindred. *Intern Med* **39**: 50-54, 2000.
- Sunthornthepvarakul T, Angkeow P, Weiss RE, Hayashi Y, Refetoff S. An identical missense mutation in the albumin gene results in familial dysalbuminemic hyperthyroxinemia in 8 unrelated families. *Biochem Biophys Res Commun* **29**: 781-787, 1994.
- Hoshikawa S, Mori K, Kaise N, Nakagawa Y, Ito S, Yoshida K. Artificially elevated serum-free thyroxine levels measured by equilibrium dialysis in a pregnant woman with familial dysalbuminemic hyperthyroxinemia. *Thyroid* **14**: 155-160, 2004.
- Osaki Y, Hayashi Y, Nakagawa Y, Yoshida K, Ozaki H, Fukazawa H. Familial dysalbuminemic hyperthyroxinemia in a Japanese man caused by a point albumin gene mutation (R218P). *Jpn Clin Med* **7**: 9-13, 2016.
- Tiu SC, Choi KL, Shek CC, Lau TC. A Chinese family with fa-

mial dysalbuminaemic hyperthyroxinaemia. Hong Kong Med J 9: 464-467, 2003.

The Internal Medicine is an Open Access article distributed under the Creative Commons Attribution-NonCommercial-NoDerivatives 4.0 International License. To view the details of this license, please visit (<https://creativecommons.org/licenses/by-nc-nd/4.0/>).

© 2017 The Japanese Society of Internal Medicine
Intern Med 56: 2175-2180, 2017