

# Use of Univent tube for intermittent lung isolation during thoracoscopic mediastinal tracheal resection and reconstruction

## A case report

Yabing Zhang, MD, Juan Xin, MD, Ye Ma, MD, Qian Li, MD\*, Bin Liu, MD\*

### Abstract

**Rationale:** Primary tracheal adenoid cystic carcinoma of the trachea primary is a rare neoplasm and commonly misdiagnosed. Lung isolation during surgery and ventilation pose a tremendous challenge to anesthesiologists.

**Patient concerns:** The authors describe a novel technique of lung isolation and ventilation with a Univent tube during thoracoscopic mediastinal tracheal resection and reconstruction in a female patient.

**Diagnoses:** Primary tracheal adenoid cystic carcinoma, nonsmall cell carcinoma.

**Interventions:** In this case, tracheal resection and reconstruction were performed. A bronchial blocker of the Univent tube was used as a guide to manipulate the depth of endotracheal tube.

**Outcomes:** The intermittent 1-lung ventilation was established successfully. The patient recovered uneventfully and discharged after 10 days.

**Lessons:** The advantages of approach include a stable airway management without occupying the contracted space of thoracoscope and no potential risk of trapping or barotraumas.

**Abbreviations:** ACC = adenoid cystic carcinoma, OLV = 1-lung ventilation, VATS = video-assisted thoracic surgery.

**Keywords:** 1-lung ventilation, airway, carcinoma, tracheal neoplasms, Univent tube, video-assisted thoracic surgery

## 1. Introduction

Primary tracheal adenoid cystic carcinoma (ACC) of the trachea primary is a rare neoplasm and commonly misdiagnosed. Surgery was suggested as the only curative treatment option.<sup>[1]</sup> Lung isolation during surgery and ventilation pose a tremendous challenge to anesthesiologists. It is essential to provide adequate ventilation and oxygenation during airway manipulation while providing comfortable surgical field. This report presents the case of video-assisted thoracic surgery (VATS) for adenocarcinoma arising at the mediastinal trachea, during which the patient was applied 1-lung ventilation (OLV) intermittently.

## 2. Case report

A 47-year-old female had suffered from cough and hemoptysis for more than 2 months. She was transferred from another hospital with a chest computed tomography revealing a 24 × 26 mm mass at right rear lateral of the mediastinal trachea and 25 mm above the carina. The mass advanced both intraluminally and mainly extraluminally (Fig. 1A). Bronchial brushing cytology detected thimbleful metatypical epithelial cells suggesting non-small cell carcinoma. Tracheal resection and reconstruction were performed under VATS. Permission from the ethics committee of our hospital (Committee of biomedical ethics of West China Hospital) and written informed consent from the patient for publication were obtained.

Anesthesia was induced with propofol, sufentanil, rocuronium and was uneventful. A 7.5-mm Univent tube (Fuji Systems Corp., Tokyo, Japan) was placed in the trachea above the lesion and the patient's lungs ventilated with an oxygen/air. With the aid of fiberoptic bronchoscopy, the bronchial blocker was positioned correctly at the right main bronchus. After intubation, pressure controlled 2-lung ventilation was performed with inspiratory pressure of 12 cm H<sub>2</sub>O and a respiratory rate of 10 breaths/min. Anesthesia was maintained with a propofol continuous infusion and sufentanil was injected intermittently.

The operation was performed under VATS. Three incisions for access ports were made. During the exposure of the lesion, pressure-controlled OLV was established by inflating the bronchial blocker with inspiratory pressure of 14 cm H<sub>2</sub>O and respiratory rate of 12 breaths/min. The trachea, carina, and right main stem bronchus were exposed for mobilization, and circumferential mobilization was applied only within 1 cm above

Editor: N/A.

YZ, JX, and YM have contributed equally to this research.

The authors have no funding and conflicts of interest to disclose.

Department of Anesthesiology, West China Hospital of Sichuan University, Chengdu, Sichuan, China.

\*Correspondence: Qian Li, Department of Anesthesiology, West China Hospital of Sichuan University, No. 37, Wai Nan Guo Xue Xiang, Chengdu 610041, Sichuan, China (e-mail: sculliqian@foxmail.com).

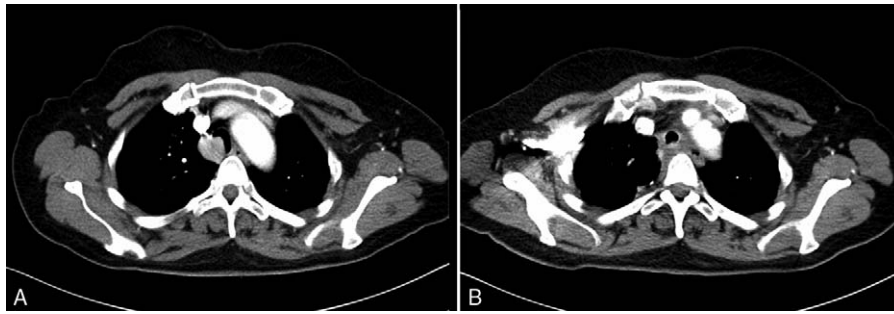
Copyright © 2017 the Author(s). Published by Wolters Kluwer Health, Inc. This is an open access article distributed under the Creative Commons Attribution-NoDerivatives License 4.0, which allows for redistribution, commercial and non-commercial, as long as it is passed along unchanged and in whole, with credit to the author.

Medicine (2017) 96:50(e8945)

Received: 16 September 2017 / Received in final form: 1 November 2017 /

Accepted: 8 November 2017

<http://dx.doi.org/10.1097/MD.0000000000008945>



**Figure 1.** Computed tomography findings. (A) Preoperative computed tomography showed a mass in the lower trachea. (B) Postoperative computed tomography on postoperative day 10 showing neither stenosis nor fistula at the anastomosis.

and below the tumor. Mediastinal lymph nodes were dissected and then sent for pathology. The involved segment of the trachea was resected quickly. A running suture between the upper and distal segments of trachea was primarily performed in an end-to-end fashion. During this period, the main tube was intermittently withdrawn above the proximal incision. When the pulse oxygen saturation ( $SpO_2$ ) was lower than 95%, the main tube was intubated into the distal trachea under the guiding of the bronchial blocker which was left in situ during the intermittent OLV (Fig. 2). Pressure-controlled OLV was intermittently performed with inspiratory pressure of 16 cm  $H_2O$  and respiratory rate of 18 breaths/min. No adverse events were observed and vital signs were maintained well. Oxygenation was monitored by  $SpO_2$  and no hypoxemia ( $SpO_2 < 90\%$ ) was observed. The anastomosis was confirmed to have no air leaks. A drain was placed in the right chest cavity, the operation was finished, and the patient was extubated in the operating room. The patient was kept in a position of head anteflexion until the first postoperative week and her neck extension was restricted during the next week. The patient recovered uneventfully and discharged after 10 days (Fig. 1B). The final pathology report showed ACC with a negative surgical margin and no lymph node metastasis.

### 3. Discussion

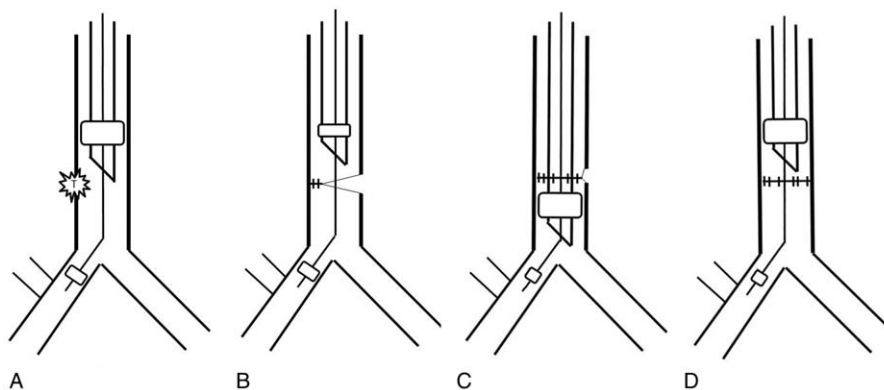
The benefits of thoracoscopic surgery versus thoracotomy include fewer postoperative complications and an earlier return

to full preoperative activities.<sup>[2]</sup> But lung isolation during surgery and a method of ventilation are challenging tasks for anesthesiologists.

To maintain normal gas exchange and secure the safe of patient, we applied intermittent OLV, while the moveable bronchial blocker was used to isolate the right lung and taken as a catheter guide for the tube inserted to the right lung after the tube was withdrawn above the proximal incision.

Different methods in airway management have been reported concerning tracheal or carinal resection.<sup>[3–6]</sup> High-frequency jet ventilation, providing an uninterrupted surgical field, may predispose patients to potential risk of trapping or barotraumas during thoracoscopic carinal resection.<sup>[3,5]</sup> And the procedure would be interrupted by the spray of blood across the operating field.<sup>[7]</sup> Cross-field ventilation has also been described in the surgical literatures as being used in complex tracheal surgeries.<sup>[8]</sup> The cross-field endobronchial tube, which may hinder surgeons' view, may lead the procedure more difficult during VATS tracheoplasty.

The different methods mentioned above may interfere the surgical field and repeated insertion and removal of tube may cause stump injury.<sup>[3,7]</sup> In this case, a bronchial blocker was used as a guide to manipulate the depth of endotracheal tube. Intermittent OLV was established successfully. During intermittent ventilation, the patient was supplied with sufficient oxygenation without trapping or barotraumas. When the main



**Figure 2.** Airway management during the VATS. (A) Initially, with the aid of fiberoptic bronchoscopy, a Univent tube was placed in the trachea above the lesion, and the bronchial blocker was positioned correctly at the right main bronchus. (B) During the running suture, the main tube was withdrawn above the proximal incision. (C) The main tube was intubated into the distal trachea under the guiding of the bronchial blocker for 2-lung ventilation. (D) The anastomosis was completed; the Univent tube was withdrawn above the proximal incision. T = tumor.

tube was withdrawn above the proximal incision, the suturing and tying procedures progressed smoothly. The surgeons have not been interrupted by the spray of blood or hindered by uncomfortable surgical field. At the same time, bronchial blocker is an ordinary clinical option and easy to implement for users. Benefit from all above, with the assist of bronchial blocker as a catheter guide, the patient suffered no stump injury, and the surgery was carried out successfully and uneventfully.

#### 4. Conclusion

Intermittent OLV under the guiding of the bronchial blocker maybe effective during thoracoscopic mediastinal tracheal resection and reconstruction. This approach may provide more stable airway management without occupying the contracted space of thoracoscope and does not cause potential risks of trapping or barotraumas.

#### References

- [1] Macchiarini P. Primary tracheal tumours. *Lancet Oncol* 2006;7:83–91.
- [2] Nakanishi R, Fujino Y, Oka S, et al. Video-assisted thoracic surgery involving major pulmonary resection for central tumors. *Surg Endosc* 2010;24:161–9.
- [3] Chin JH, Lee EH, Choi DK, et al. High frequency jet ventilation of one lung using a bronchial blocker of Univent during carinal resection. *J Korean Med Sci* 2010;25:1083–5.
- [4] Nakanishi K, Kuruma T. Video-assisted thoracic tracheoplasty for adenoid cystic carcinoma of the mediastinal trachea. *Surgery* 2005;137:250–2.
- [5] Nakanishi R, Yamashita T, Muranaka K, et al. Thoracoscopic carinal resection and reconstruction in a patient with mucoepidermoid carcinoma. *J Thorac Cardiovasc Surg* 2013;145:1134–5.
- [6] Smith IJ, Sidebotham DA, McGeorge AD, et al. Use of extracorporeal membrane oxygenation during resection of tracheal papillomatosis. *Anesthesiology* 2009;110:427–9.
- [7] Perera ER, Vidic DM, Zivot J. Carinal resection with two high-frequency jet ventilation delivery systems. *Can J Anaesth* 1993;40:59–63.
- [8] Sehgal S, Chance JC, Steliga MA. Thoracic anesthesia and cross field ventilation for tracheobronchial injuries: a challenge for anesthesiologists. *Case Rep Anesthesiol* 2014;2014:972762.