

THE SUPERFICIAL BRANCH OF THE RADIAL NERVE: A MORPHOLOGIC STUDY

Celso Ricardo Folberg¹

Heitor JR Ulson²

Rodrigo Benedet Scheidt³

ABSTRACT

Objective: Study the morphology of the superficial branch of the radial nerve (SBRN) of the forearms and wrists of fresh adult human cadavers. **Methods:** Twenty three dissections were performed under 3.5x loupe magnification, histological sections of the nerve were obtained in 20 dissections for fascicle identification. **Results:** The SBRN emerged, in average, at 8.65cm proximal to the radial styloid apophysis (RSA) between the Brachioradialis (BR) and Extensor Carpi Radialis Longus (ECRL) tendons. In 6/23 cases the SBRN emerged between an accessory BR tendon and the main BR tendon. The first branch of the SBRN arose at an average of 4.58 cm proximal to the RSA. A branch running across the RSA was found in 7/23 cases. At that level, the average number of branches crossing the wrist was 3.4. A

fascicle count of the nerve and its first branch showed an average of 6.6 and 4.0 fascicles, respectively. **Conclusion:** Our anatomical findings are similar to those in the revised literature and contribute towards a better knowledge of the SBRN. Great caution is required in surgical procedures such as percutaneous bone fixation of the distal 1/3 of the forearm and wrist and particularly, in those susceptible to SBRN injury, as in seven of the 23 cases the SRBN ran directly across the RSA. The authors recommend performing small longitudinal incisions down to the subcutaneous tissue, separating the nerve branches by blunt soft tissue dissection, with a delicate haemostat, before introducing the Kirschner wires (minimally invasive procedures).

Keywords – Radial nerve/anatomy; Fracture fixation, internal; Cadaver

INTRODUCTION

The superficial branch of the radial nerve (SBRN) must be found and protected in surgical approaches to the distal radius and wrist joints. Its anatomical description has been cited in various treaties and atlas of surgical anatomy, although with minor differences between them. Over the last decade, few detailed descriptions of the SBRN and its branches have been published⁽¹⁻⁶⁾. However, numerous cases of intractable pain caused by nerve injuries have been reported⁽⁷⁻¹⁴⁾.

By improving knowledge of the topography, the

anatomical variations, and the number of SBRN fascicles, surgical injuries can be prevented. The objective of this report is to study the anatomy and histology of the SBRN in its trajectory in the topography of the distal radius*.

METHODS

Using a magnifying lens of 3.5x, the forearms and wrists of 23 fresh adult cadavers referred to the autopsy section of the Porto Alegre Institute of Forensic Medicine (IFM) were dissected. There was no history

1 – Master in Surgery; Preceptor, Hand Surgery Group, Department of Orthopedics and Traumatology, Hospital de Clínicas de Porto Alegre, RS

2 – Professor, Department of Orthopedics and Traumatology – Coordinator of the Department of Hand Surgery, Faculdade de Ciências Médicas, Universidade Estadual de Campinas (UNICAMP), SP

3 – Third-year Resident, Orthopedics and Traumatology Clinic, Hospital de Clínicas de Porto Alegre, RS.

Study completed at the Department of Surgery, Federal University of Rio Grande do Sul (UFRGS, Universidade Federal do Rio Grande do Sul), Porto Alegre, and the Department of Orthopedics and Traumatology, UNICAMP, Campinas, SP, Brazil.

Correspondence: Rua Leopoldo Bier, 825 sala 305 – Porto Alegre – RS – Brasil – Cep 90620-100. E-mail: crfolberg@hotmail.com

We declare no conflict of interest in this article

and no evidence of acute or chronic injury in the dissected extremities of 19 men and four women.

Initially, a needle was inserted percutaneously, marking the styloid apophysis of the radius (SAR) for reference measurements, as shown in Figure 1.

The incision was begun distally at the dorsal-radial base of the thumb, going toward Lister's tubercle (LT), extending proximally in a zigzag on the radial aspect of the forearm toward the elbow flexor crease. The SBRN was identified along with the tendons of the brachioradialis muscle (BR) and the extensor carpi radialis longus (ECRL) in the middle third of the forearm and dissected distally to the point of incision, with utmost care to avoid altering its topographical relationships (Figure 2). A caliper (No. 97031748, Mitutoyo®, Brazil) was used to measure the distance from the SAR to the point of emergence of the SBRN, together with the tendons of the BR and ECRL in the middle third of the forearm (Figure 3), and the distance from the SAR to the origin of the first branch of the SBRN (Figure 4). The length of the radius was measured in neutral pronation/supination position from its head to the styloid process using a 30-cm long metal ruler with millimeter markings.

The distance between the dorsal and volar branches that cross the wrist near the SAR and the branch closest to the LT were also identified and measured (Figure 5). The number of BR accessory tendons and the number of SBRN branches crossing the wrist joint at the level of the SAR were also studied.

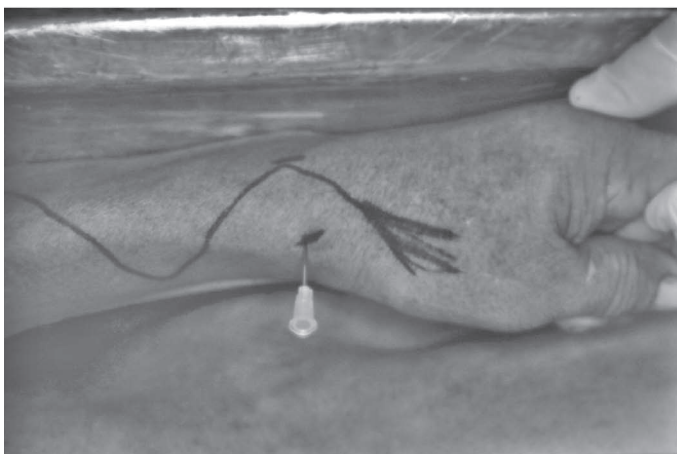

Figure 1 – Marking the skin at the extremity for dissection and placement of the marker pin on the SAR.

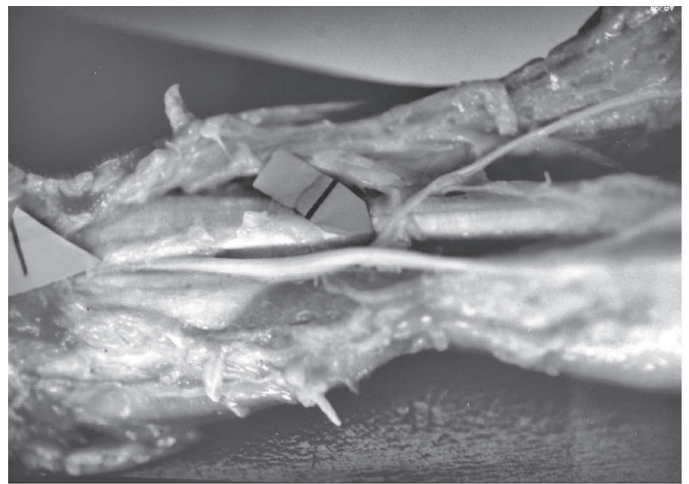


Figure 2 – Left arrow: emergence of the SBRN between the BR and ECRL tendons. Right arrow: the first branch of the SBRN.

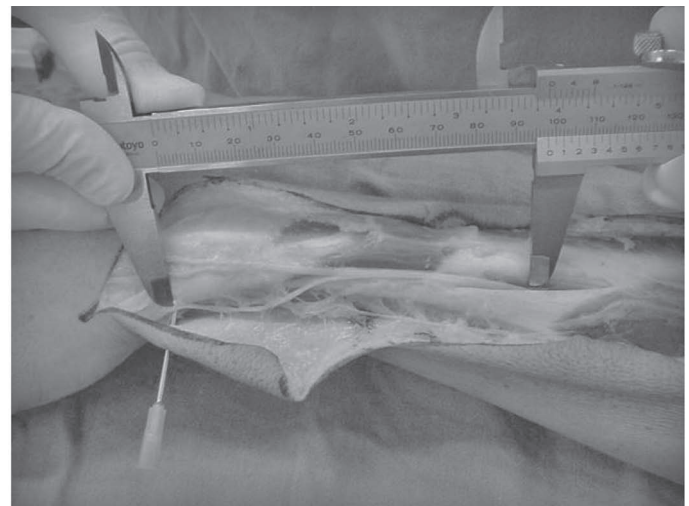


Figure 3 – Measuring the distance between the point of emergence of the SBRN and the SAR with the caliper.

* Folberg, Celso Ricardo. Anatomical and histological study of the superficial branch of the radial nerve in the distal forearm and wrist. Campinas, SP: Universidade Estadual de Campinas, UNICAMP. Faculdade de Ciências Médicas; 2002.

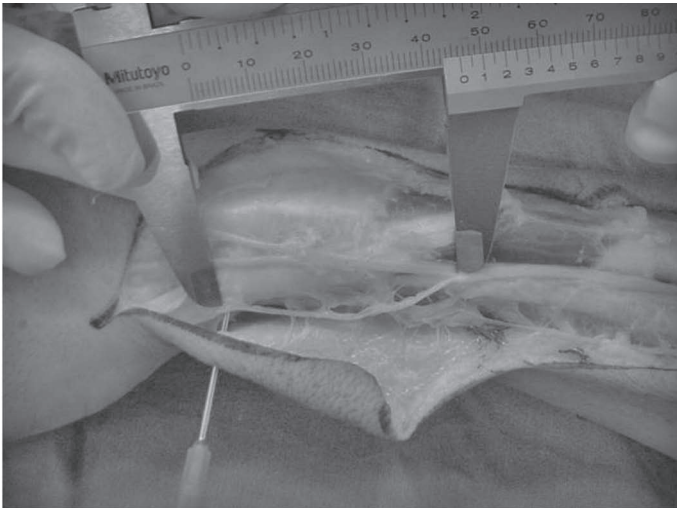


Figure 4 – Measuring the distance between the SAR and the origin of the first branch of the SBRN.

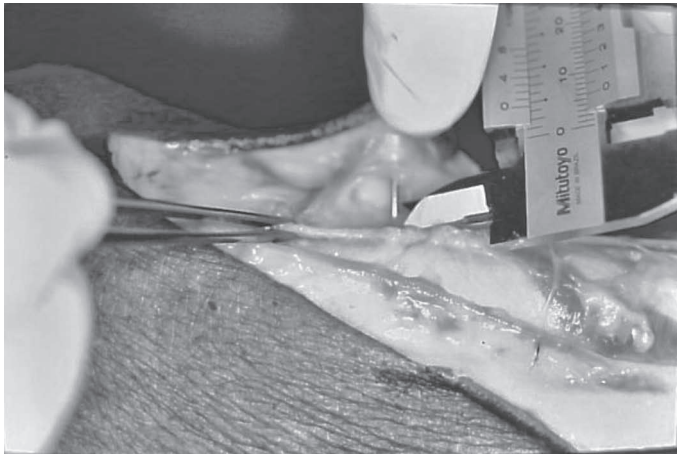


Figure 5 – Measuring the distance between the branch of the SBRN nearest the SAR and the SAR (marked with a needle) with a caliper.

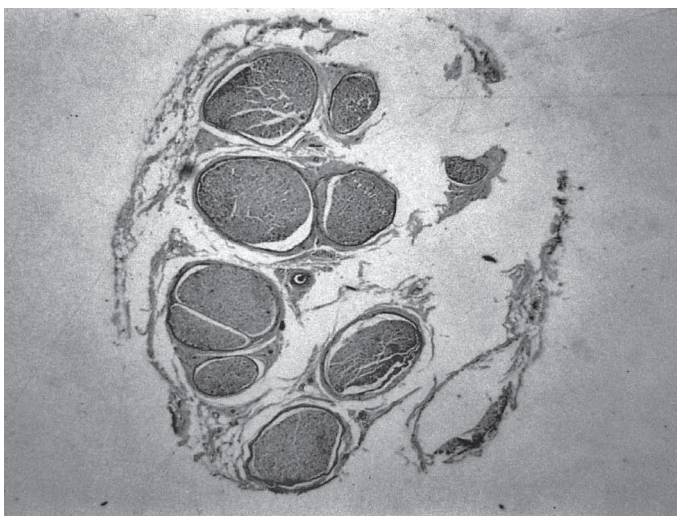


Figure 6 – Histological section of the SBRN at its point of emergence with a view of eight fascicles (hematoxylin-eosin staining).

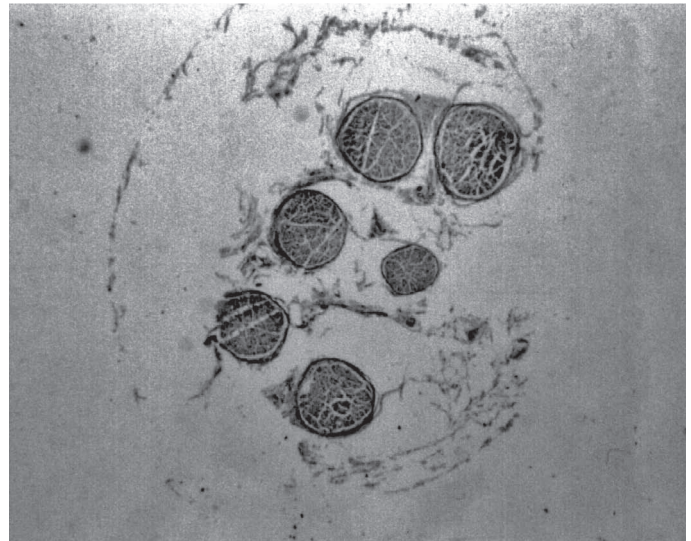


Figure 7 – Histological section of a branch of the SBRN at the height of the wrist with a view of six fascicles (hematoxylin-eosin staining).

RESULTS

We present the results of 23 anatomical dissections and histological analysis of the cross-sections of 20 extremities to study fascicular distribution.

The average length of the radius bone in 23 cases was 23 cm (19.5 cm to 25.9 cm, standard deviation $SD = 1.53$). The SBRN was identified in the middle third of the forearm between the tendons of the brachioradialis (BR) and extensor carpi radialis longus (ECRL) in most dissections, with the exception of six cases (6/23) for which it was identified an accessory tendon to the BR, in which the branch arose between the two tendons of the BR (Figure 8). The point of emergence between the two tendons averaged 8.65 cm proximal to the SAR (5.5 cm to 11.2 cm, $SD = 1.36$ cm); this distance corresponds to 37% of the length of the radius.

The first major branch was almost always identified on the radial side, originating on average 4.5 cm proximal to the SAR (2.0 to 7.9 cm, $SD = 1.39$). On only one occasion a thin branch was identified on the ulnar side originating 0.3 cm proximal to the exit of the first branch of the radial side. In seven cases (7/23), a branch was identified passing directly above the SAR (Figure 9). The nearest branch was on average 0.38 cm from the SAR (0 to 1.2 cm, $SD = 0.34$). In only one case (1/23), a branch was identified directly over Lister's tubercle (LT), and no branches were identified on the ulnar side of the LT.



Figure 8 – The SBRN (left horizontal arrow) emerging from between the accessory (right vertical arrow) and main tendons of the BR.

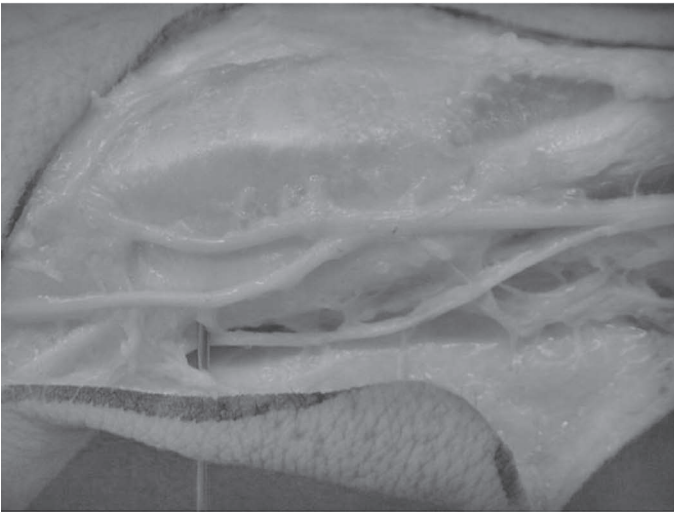


Figure 9 – Photograph showing the SBRN crossing exactly over the SAR, which is marked with a pin.

The average number of branches of the SBRN across the wrist at the level of the SAR was 3.4 (2 to 6, SD = 1.34).

Communication with branches of the lateral cutaneous nerve of the forearm was observed in two extremities.

An average of 6.6 SBRN fascicles (2 to 13, SD = 2.87) (Figure 6) were found at the point of emergence. Four fascicles (2 to 7, SD = 1.64) were found, on average, at the first branch and at the wrist level in all extremities studied; at the second branch, an average of 4.5 fascicles (2 to 11, SD = 2.67) were found in the direction from the radius to the ulna in 20 extremities; in the third branch, in 12 extremities (12/20), the average found was 3.5 (1 to 9, SD = 2.46); at the fourth branch, found in seven of the 20 limbs (7/20), the average was 3.1 fascicles (1 to 5, SD = 1.58);

at the fifth branch, found in five cases (5/20), the average was 3; and at the sixth branch, found in two extremities (2/20), the average was 4 fascicles (2 to 6, SD = 2.82).

The accuracy of the calculations and the results was confirmed by the Komolgorov and Smirnov test ($p < 0.05$ for all results).

DISCUSSION

The wrist and distal forearm are common sites of percutaneous and open surgery, where SBRN injuries may occur, usually with undesirable and sometimes even disastrous results.

Studies have detailed the anatomy of the SBRN with results obtained by means of 20 dissections, while Kuhlmann et al. presented 50 dissected extremities⁽¹⁵⁾. Another study emphasized anatomical details with arthroscopic portal applications⁽¹⁶⁾. Studies of the first extensor compartment draw attention to the use of Kirschner wires in the anatomical snuffbox⁽¹⁷⁻¹⁹⁾. The cutaneous innervation of the dorsal hand with its clinical implications, the anatomical characteristics of the SBRN and the fact that it may be related to forearm compression syndromes highlight the importance of this branch of the radial nerve^(5, 6, 14).

We found the emergence of the SBRN an average of 8.64 cm proximal to the SAR between the BR and ECRL tendons, values similar to those found by other authors, with averages ranging from 7.8 to 9.0 cm^(1-3,5,15,20). Lanzetta et al. clinically reinforced these findings by finding the Tinel sign in the compression syndrome of the SBRN 8.8 cm proximal to the SAR, taking into account that compression occurs in the emergence of this branch between the BR and ECRL tendons⁽²¹⁾. The average distance from the SAR was 4.58 cm on the first branch of the SBRN, which was the same as that found by Leroux et al. and less than that found by Ikiz et al.⁽⁵⁾, Gonzalez et al.⁽¹⁷⁾, Abrams et al.⁽¹⁾, Auerbach et al.⁽²⁾, and Mok et al.⁽⁶⁾, respectively: 4.9, 5.0, 5.1, 5.3, and 5.5 cm.

In the present study, the SBRN was not found emerging through the main tendon of the BR, as reported in two dissections by Abrams et al.⁽¹⁾ However, in six dissections (6/23), we described the SBRN emerging between the accessory tendon of

the BR and its main tendon. This finding was also described by another author in 5% of 143 patients undergoing surgery at this site⁽²⁰⁾. In a previous study, the authors reported the presence of an accessory tendon of the BR in 6% of 150 dissections; however, the SBRN was located between the accessory and main BR tendons in only 3.3% of cases⁽²²⁾. Because we possibly found a higher frequency of accessory tendons of the BR in relation to the study by Turkof et al., the incidence of this anatomical variation is explained^(20, 22). The use of these accessory tendons may be important in varied tendon transfers.

Traditional treaties and atlases of anatomy usually show one or two branches of the SBRN across the wrist at the height of the SAR, a fact partially confirmed by the 50 dissections performed by Kuhlman et al. that identified two branches: the superficial lateral and superficial medial branches. In the present study, we found a range of two to six branches at this level. Auerbach et al. even found a case with 10 branches, but the average was 5.8, a value close to that found by Leroux et al., which was, on average, 5.1 branches from the SBRN at the level of the SAR^(2, 6).

We believe that the greatest clinical relevance of this work is to demonstrate that in seven cases (7/23) at least one branch of the SBRN crossed the wrist precisely over the SAR (Figure 9), a reference place for the insertion of Kirschner wires when performing percutaneous procedures for fractures of the distal radius. An experimental study on the introduction of percutaneous Kirschner wires showed a lesion or displacement of the SBRN in 32% of cases⁽²³⁾. There are many reports in the literature of SBRN injuries at the wrist level^(7-14, 16, 18, 19, 23). Knowledge of the anatomical variations of this nerve and making small longitudinal incisions

with blunt dissection and lateral separation of soft tissue to the bone plane can help prevent this type of injury. It would be preferable to call them minimally invasive procedures and so describe them, as the term percutaneous suggests a blind introduction, with a consequent greater risk of nerve damage. We did not find any other studies in the literature citing the number of fascicles per SBRN branch in the distal forearm. Our results show a normal distribution curve according to the Kolmogorov-Smirnov test. In no case in this study was the number of fascicles of the main nerve equal to the sum of its ramifications, that is, along a nerve there are divisions, migrations, and anastomoses of fascicles that explain our findings.

The number of fascicles found at the location of emergence of the SBRN showed considerable variation, from two to 13 fascicles, with an average of 6.6 and a SD = 2.87. We found no other study in the literature with which to compare this data, and so at this time we can consider 6.6 to be the average number of fascicles of the SBRN.

We believe that more detailed studies of the anatomy of the SBRN will be extremely important to prevent, diagnose, and treat injuries of this nerve.

CONCLUSION

Our anatomical findings are similar to the literature reviewed, promoting an improved understanding of the SBRN. There is need for extreme caution in surgical procedures in the studied area, especially the so-called percutaneous procedures that present SBRN injuries, because in seven of 23 cases, the SBRN passed directly over the SAR. The authors recommend small longitudinal incisions with blunt dissection and lateral separation of soft tissue to the bone plane before introducing Kirschner wires in minimally invasive procedures.

REFERENCES

1. Abrams RA, Brown RA, Botte MJ. The superficial branch of the radial nerve: an anatomic study with surgical implications. *J Hand Surg Am.* 1992;17(6):1037-41.
2. Auerbach DM, Collins ED, Kunkle KL, Monsanto EH. The radial sensory nerve: an anatomic study. *Clin Orthop Relat Res.* 1994;(308):241-9.
3. Leroux M, Harris P, Fowles JV. An anatomic study of the superficial radial nerve and its clinical implications. *Ann Chir.* 1998;52(8):736-43.
4. Ndiaye A, Diop M, Dia A, Seye SI, Sow ML. The sensitive branch of the radial nerve at the inferior third of the forearm and at the wrist. Clinical applications. *Bull Assoc Anat (Nancy).* 1996;80(249):27-30.
5. İkiz ZA, Üçerler H. Anatomic characteristics and clinical importance of the superficial branch of the radial nerve. *Surg Radiol Anat.* 2004;26(6):453-58.
6. Mok D, Nikolis A, Harris PG. The cutaneous innervation of the Dorsal Hand: detailed anatomy with clinical implications. *J Hand Surg Am.* 2006;31:565-74.

7. Arons MS. De Quervain's release in working women: a report of failures, complications and associated diagnoses. *J Hand Surg Am.* 1987;12:540-4.
8. Braidwood AS. Superficial radial neuropathy. *J Bone Joint Surg Br.* 1975;57:380-3.
9. Linscheid RL. Injuries to the radial nerve at the wrist. *Arch Surg.* 1965;91:942-7.
10. Louis DS, Greene TL, Noellert RC. Complications of carpal tunnel surgery. *J Neurosurg.* 1985;62(3):352-6.
11. Sanders RA, Keppel FR, Waldrop JI. External fixation of distal radius fractures: results and complications. *J Hand Surg Am.* 1991;16:385-91.
12. Thrush DN, Belsole R. Radial nerve injury after routine peripheral vein cannulation. *J Clin Anesth.* 1995;7:160-2.
13. Singh S, Trikha P, Twyman R. Superficial radial nerve damage due to Kirschner wiring of the radius. *Injury.* 2005;36:330-2.
14. Dellon AL, Mackinnon SE. Susceptibility of the superficial sensory branch of the radial nerve to form painful neuromas. *J Hand Surg Br.* 1984;9:42-5.
15. Kuhlmann JN, Guerin-Surville H. The superficial branch of the radial nerve. Topographical location. Systematization. *Bull Assoc Anat (Nancy).* 1985;669(207): 331-41.
16. Abrams RA, Petersen M, Botte MJ. Arthroscopic portals of the wrist: an anatomic study. *J Hand Surg Am.* 1994;19:940-4.
17. Gonzalez MH, Sohlberg R, Brown A, Weinzweig N. The first dorsal extensor compartment: an anatomic study. *J Hand Surg Am.* 1995;20:657-60.
18. Leão L. De Quervain's disease: a clinical and anatomical study. *J Bone Joint Surg Am.* 1958;40:1063-70.
19. Steinberg BD, Plancher KD, Idler RS. Percutaneous Kirschner wire fixation through the snuff box: an anatomic study. *J Hand Surg Am.* 1995;20:57-62.
20. Turkof E, Puig S, Choi MS, Zoch G, Dellon AL. The radial sensory nerve entrapped between the two slips of a split brachioradialis tendon: a rare aspect of Wartenberg's syndrome. *J Hand Surg Am.* 1995;20:676-8.
21. Lanzetta M, Foucher G. Entrapment of the superficial branch of the radial nerve. A report of 52 cases. *Int Orthop.* 1993;17:342-6.
22. Turkof E, Puig S, Choi MS, Schilhan R, Millesi H, Firbas W. Superficial branch of the radial nerve emerging between two slips of a split brachioradialis muscle tendon: a variation of possible clinical relevance. *Acta Anat (Basel).* 1994;150(3):232-4.
23. Hochwald NL, Levine R, Tornetta P. The risks of Kirschner-wire placement in the radius: a comparison of techniques. *J Hand Surg Am.* 1997;22:580-4.