



# Narrative review of influence of prosthesis lateralization on clinical outcomes in reverse shoulder arthroplasty: glenoid vs. humerus vs. combined

Piotr Łukasiewicz<sup>^</sup>, Andrew B. Harris<sup>^</sup>, Joel A. Bervell, Edward G. McFarland<sup>^</sup>

Division of Shoulder Surgery, Department of Orthopaedic Surgery, The Johns Hopkins University, Baltimore, MD, USA

*Contributions:* (I) Conception and design: P Łukasiewicz, EG McFarland; (II) Administrative support: JA Bervell, AB Harris; (III) Provision of study materials or patients: EG McFarland; (IV) Collection and assembly of data: P Łukasiewicz, AB Harris, JA Bervell; (V) Data analysis and interpretation: P Łukasiewicz, AB Harris, JA Bervell; (VI) Manuscript writing: All authors; (VII) Final approval of manuscript: All authors.

*Correspondence to:* Edward G. McFarland, MD. Division of Shoulder Surgery, Department of Orthopaedic Surgery, The Johns Hopkins University, 2360 West Joppa Road, Suite 306, 10753 Falls Road, Lutherville, MD 21093, USA. Email: emcfar1@jhmi.edu.

**Background and Objective:** Reverse shoulder arthroplasty has become a common orthopaedic procedure, with a growing number of cases annually for multiple indications, such as rotator cuff arthropathy, osteoarthritis, or fractures of the proximal humerus, to reduce pain and restore shoulder mobility. Prosthesis design and various recent improvements aim to enhance range of motion (ROM) and stability and to limit component loosening and other potential complications. Many of these well-known issues could theoretically be improved by glenoid, humeral, or combined component lateralization. The objective of this article is to provide an up-to-date literature overview, present available options, and discuss the rationale behind lateralization of certain components, as well as their combined impact on outcomes of reverse shoulder arthroplasty.

**Methods:** PubMed and Scopus databases from 2003 to 2023 were searched and screened for studies, including systematic reviews, on the influence of glenoid, humeral, and combined component lateralization that served for narrative review of rationale behind such design.

**Key Content and Findings:** Currently, a number of computer simulations, anatomic studies, and limited clinical references aim to support the rationale behind glenoid augmentation, variable humeral neck-shaft angle (NSA), or humeral tray design.

**Conclusions:** The utility of lateralization has not yet been clinically established. Randomized, long-term clinical outcome studies are still needed to reach a verdict going beyond surgeon preference and case-specific indications.

**Keywords:** Shoulder; reverse arthroplasty; glenoid; humeral component; lateralization

Received: 01 February 2023; Accepted: 05 June 2023; Published online: 14 June 2023.

doi: 10.21037/aoj-23-9

View this article at: <https://dx.doi.org/10.21037/aoj-23-9>

## Introduction

Reverse total shoulder arthroplasty (rTSA) has become a common orthopaedic procedure since introduction of the design proposed by Grammont in the 1980s and the

first United States Food & Drug Administration (FDA) approval in November 2003 for the treatment of rotator cuff arthropathy. Its popularity and incidence grew with its successful application for a myriad of indications, such as glenohumeral arthritis; inflammatory arthritis; massive,

<sup>^</sup> ORCID: Piotr Łukasiewicz, 0000-0003-3826-7221; Andrew B. Harris, 0000-0002-8158-4364; Edward G. McFarland, 0000-0002-1193-4672.

**Table 1** The search strategy summary

Items	Specification
Date of search	May 19, 2023
Databases and other sources searched	PubMed, Scopus
Search terms used	Shoulder, arthroplasty, reverse, lateralization, glenoid, humeral
Timeframe	2003–2023
Inclusion and exclusion criteria	Inclusion criteria: Original article on the topic of lateralization in reverse total shoulder arthroplasty Peer-reviewed article Article written in English Exclusion criteria: Poster or abstract at annual meeting, or master's thesis without subsequent peer-reviewed publication of an article Article written in language other than English
Selection process	Selection conducted independently by first author

irreparable rotator cuff tears; instability; fractures of the proximal humerus; avascular necrosis; glenoid and humeral bone loss; shoulder instability; sequelae of brachial plexus injuries; infections; and revision surgeries (1-8). Analyses of rTSA by Wagner *et al.* (9) using linear and Poisson models demonstrate substantial projected volume increases of 88% and 353%, to an estimated 119,994 and 289,193 procedures, respectively, by the year 2025 in the United States.

Early attempts at a prosthesis in which the sphere was placed on the glenoid side and the socket on the humeral side were associated with glenoid component failure caused by increased stress on the scapular component from a lateralized center of rotation (COR) (10). The later, groundbreaking Grammont prosthesis had a medialized and lowered COR, which reduced stress on, and the subsequent loosening of, the glenoid component. However, it did not prevent other complications, such as scapular notching and limited external and internal rotation.

Lateralization is a design aspect of TSA that continues to be developed and analyzed. Like any design, the use of lateralization of either the glenoid sphere or of the humeral tray and polyethylene can have an effect upon many parameters. This type of implant adaptation has theoretical advantages, such as increased range of motion (ROM), improved stability, and decreased rate of scapular notching. However, lateralization has also been associated with increased shear forces across the baseplate interface,

leading to failure, and increased the stress on the scapula, resulting in acromial stress fractures (11,12). Consequently, the clinical implications of lateralization of the humeral and the glenoid side of rTSA continue to be analyzed both in laboratories and clinically, and long-term outcomes are awaited.

The aim of this article is to provide a narrative review of the rationale behind lateralization of the glenoid side components and lateralization of the humeral components and their effect upon results of rTSA. We present this article in accordance with the Narrative Review reporting checklist (available at <https://aoj.amegroups.org/article/view/10.21037/aoj-23-9/rc>).

## Methods

This narrative review is based on literature review and the authors' expertise in this area. Our literature search was performed in PubMed and Scopus for supporting data, available as of May, 2023, using relevant keywords (*Table 1*). However, this was not a systematic review and does not comprehensively cover all published literature on this topic.

## Discussion

The purpose of rTSA is to eliminate or reduce pain and

to improve function of the shoulder (13). Elements of the prosthesis must replace the worn and defective parts of the glenohumeral joint. Prosthesis construction and design may predispose to dislocations and limited ROM and can be associated with several complications, such as scapular notching, fractures of the acromion, nerve injuries, and loosening of the baseplate (14,15).

Lateralization of the COR was designed to address some of these complications, most notably scapular notching and ROM, although it has been thought potentially to improve external rotation (16,17). Scapular notching, a complication unique to rTSA, usually occurs within 6 months after the procedure (18). It is caused by the humeral component impinging the inferior and posterior part of the neck of the scapula (19-23). In early studies, scapular notching was a prevalent finding in rTSA, but its clinical relevance was unclear (24,25). Subsequent studies of the impact of scapular notching suggested that notching can lead to implant failure. Spiry *et al.* found that, in patients with grade 3 or 4 notching, implant survivorship was 60% at 10 years and 43% at 15 years postoperatively (26). Clinical results measured with patient-reported outcomes (the Constant Score and the American Shoulder and Elbow Surgeons Score) and ROM were, in a meta-analysis of 11 studies by Jang *et al.*, found to be negatively affected (27). However, the authors recognized that their review was limited by deficiencies and variability in the existing literature, which was inconsistent in terms of implant design, especially as it relates to lateralization of the glenoid or different neck-shaft angles (NSAs) of the humeral components in different studies.

Increased lateralization on the glenoid side of rTSA can lead to unwanted effects, such as higher torque and shear forces on the glenoid and, potentially, loosening of the baseplate. Over the years, a number of improvements have been made in attempts to overcome this issue of baseplate loosening. The use of peripheral locking screws in the baseplate has been shown to provide more rigidity to the baseplate-glenoid interface. In one study, there was a 10.6 times greater risk of loosening associated with the use of all peripheral non-locking screws than with locking screws (28,29). In some cases, glenoid sphere disassociation occurred when the sphere was not seated properly on the Morse taper of the baseplate; consequently, some systems provided a central hole in the glenoid sphere where a handle could be screwed into the sphere to verify that it was fully seated on the baseplate. This feature also became important if the baseplate-to-sphere connection needed to be broken when revising the implants. On the humeral side, a major

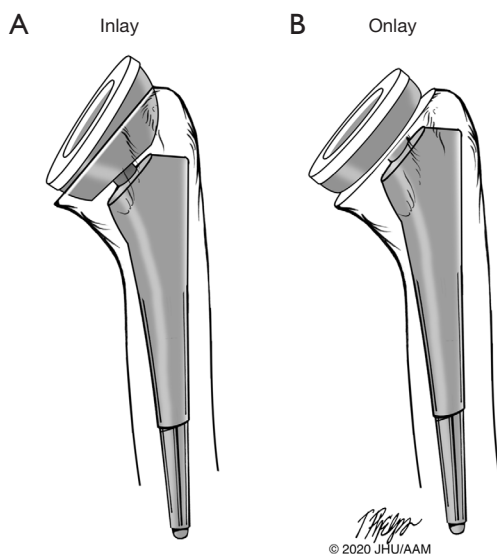
advancement was the realization that the NSA of the baseplate upon the humeral stem was a critical factor, not only in reducing notching, but in reducing the incidence of instability of rTSA (29-31).

### *Glenoid lateralization*

Options that affect lateralization of the glenoid component include the use of a glenosphere design with a lateralized offset, bone grafting the space between the baseplate and the natural glenoid [bony increased offset-reverse shoulder arthroplasty (BIO-RSA)], and use of an augmented glenoid component.

The lateral-offset glenosphere was designed to prevent scapular notching. Glenosphere lateralization also allows a more anatomic placement of the humerus, which may lead to improved tensions of the deltoid and rotator cuff muscles and, consequently, improved strength, lower risk of dislocation, and better ROM, especially external rotation. It is important to note, however, that moving the COR of the glenosphere refers to the sphere and not to the true COR of the glenoid. Most glenoids have substantial bony erosion, making the true COR medialized to begin with, so that a lateralized glenoid component may be bringing the COR of the glenosphere closer to the true COR. Similarly, when conducting studies in which the glenoid is reamed to a flat surface, this cannot technically be called moving the COR medially; rather, the glenoid surface has been moved medially. This distinction makes it difficult, when discussing the COR on the glenoid side, to compare one study with another.

Moving the COR of the rTSA sphere away from the glenoid surface was demonstrated by Gutiérrez *et al.* (32) and confirmed in a cadaveric study by Tashjian *et al.* (33) to be the most important factor in potentially increasing impingement-free abduction. A retrospective review by Werner *et al.* (34) demonstrated that patients with glenoid lateralization of 6–8 mm had significantly improved active internal rotation after 1 year compared with those with less glenoid lateralization. Two studies have shown that glenospheres with a 10-mm offset led to increased ROM without causing impingement (35,36). In a prospective multicenter study, Hasan *et al.* analyzed early results of a reverse shoulder prosthesis of a single design with a lateralized glenosphere and concluded that rTSA with a lateralized glenosphere improves active ROM and patient-assessed function in carefully selected cases of cuff-tear arthropathy and/or pseudoparalysis, as well as in cases of



**Figure 1** Illustrations of inlay (A) and onlay (B) humeral tray design used in reverse shoulder arthroplasty prostheses. The position of the humeral tray in reverse shoulder arthroplasty prostheses is described as an *inlay* when it is recessed within the proximal humerus after reaming and as an *onlay* when the tray rests more prominently on the humeral stem. Illustration: Tim Phelps, MS, FAMI, © 2020 JHU AAM, Department of Art as Applied to Medicine, The Johns Hopkins University School of Medicine. Used by permission.

failed prosthetic shoulder arthroplasty (37). The authors noted that patients with the greatest preoperative active external rotation deficits demonstrated the greatest gains postoperatively with this implant configuration (37).

Another option for lateralizing the surface of the glenoid involves using a concentric or customized glenoid bone graft to make up for medialization of the glenoid sphere design or for moving the glenoid surface laterally. However, performing a bone graft on the native glenoid can be a challenging procedure when there are severe deformations, with reported rates of graft resorption as high as 40% (38,39). Hypothetically, this approach should provide better ROM, less notching, and fewer glenoid component failures.

A retrospective comparative cohort study by Collin *et al.* (40) compared the results of traditional rTSA and BIO-RSA performed by a single surgeon with a single medialized glenoid implant design. Results showed no clinically meaningful improvements in ROM, Constant scores, and scapular notching of BIO-RSA compared with traditional rTSA at 2-year follow-up. Greiner *et al.* (41) compared

the clinical outcomes of bony lateralization of the glenoid using 1-cm autologous bone graft (BIO-RSA) with those of standard rTSA. The lateralized group showed statistically significant improvements in external rotation in patients without major teres minor degeneration. Another study by Athwal *et al.* comparing standard rTSA and BIO-RSA showed no substantial differences in ROM, strength, or validated outcomes scores between the two groups and a significantly lower rate of scapular notching in the BIO-RSA cohort (42).

Augmented baseplates are used mainly in glenoids with bone loss that do not require bone grafting, although in larger glenoid defects it has been suggested that they can be successfully implanted, with complication rates at 5 years equivalent to those in patients without augments (43). Metal augmentation baseplates can also serve as a form of lateralization, as the glenoid will be lateralized in line with the thickness of the baseplate. Van de Kleut *et al.* (44) compared 2-year follow-up results of BIO-RSA and metal-augmented baseplates. The authors did not observe any significant differences between the two groups except for increased active internal rotation in the BIO-RSA group. Levin *et al.* analyzed 171 patients with glenoid bone loss who underwent rTSA with and without augmented baseplates with greater than 5-year follow-up and found improved outcome scores and ROM in patients with augments, with no difference in rate of complications (45). As when the glenoid face is moved laterally with bone grafting, the increased stress on the bone-implant interface may lead to baseplate failure (46). Other concerns regarding augmented glenoid components are cost and that they are not available for use in every currently marketed implant system.

### **Humeral lateralization**

Lateralization of the humeral component can more accurately be called *humeral offset*, which is the angle at which the implant sits to the humeral tray on the surface of the humeral cut, and whether it is recessed more shallowly *vs.* more deeply in the proximal humerus (47) (*Figure 1*). The former is considered a *onlay* humeral tray, and the latter is called an *inlay* humeral tray configuration. Although these terms are commonly used to describe the position of the humeral tray, if an onlay component is placed deeper in the humerus at the time of surgery, it effectively becomes more of an inlay prosthesis biomechanically.

Another feature of the humeral component that has

been shown to have a substantially positive effect on clinical results is the NSA of the humeral tray to the humeral stem. The initial prosthesis designs available on the market had an NSA of 155 degrees, typical of a traditional Grammont design. Although these 155-degree-NSA implants were innovative and provided patients with excellent pain relief, they were associated with high rates of prosthesis instability and scapular notching (30,31,48). For the Grammont style of prosthesis with a large NSA and a medialized glenoid component, the instability rate has been shown to be as high as 17% and the notching rate as high as 72% (30).

An implant with an NSA of 135 degrees was subsequently developed, but its lateralized glenoid sphere had a high glenoid failure rate of 12% (49). A cadaveric study by Giles *et al.* (50) demonstrated that humeral lateralization was the only parameter that improved joint and muscle loading but glenosphere lateralization resulted in increased loads, and that overstuffing with polyethylene inserts that are too thick should be avoided.

Gutiérrez *et al.* (32) noted that an NSA of 130° had the largest impact on decreasing the adduction deficit. A smaller NSA would in theory allow for a better ROM by preventing the humeral component from striking the glenoid rim and the rest of the scapula, although scapular notching occurs mostly in external rotation (51). Gobezie *et al.* (52) compared humeral inclinations of 135° and 155° in a randomized controlled trial of 100 primary reverse shoulder arthroplasties. Major findings of the study were no differences in postoperative forward flexion or external rotation after rTSA using humeral inclinations of 135° and 155° with a neutral glenosphere, but there was a higher incidence of scapular notching in the 155° group. The authors noted that the lack of improvement in external rotation and the 21% rate of scapular notching in the 135° group may be explained by use of a neutral glenosphere without lateral offset; on this basis they currently use a lateralized glenosphere with a 135° prosthesis in most cases. A systematic review by Erickson *et al.* (53) revealed significantly greater external rotation in the 135° NSA group (33° *vs.* 20.5° in a 155° NSA group).

The impact of positioning of the humeral tray (*Figure 1*) on outcomes of rTSA is a longstanding controversy, and our review identified few studies comparing the outcomes of rTSA procedures for designs differing by tray type only. Meshram *et al.* (54) found no significant differences in patient-reported outcome measures and ROM outcomes, at minimum 2-year follow-up, between inlay and onlay tray

designs in rTSA with a lateralized glenosphere and NSA of 135° for osteoarthritis and glenoid bone deficiency. Polisetty *et al.* (55) reported no differences in clinical outcomes and low rates of scapular notching between onlay- and inlay-style humeral stem prostheses following rTSA with lateralized glenosphere and 135° NSA done at two institutions. Significantly greater improvement in external rotation for the onlay design was reported by Merolla *et al.* (56), but the compared systems also differed in NSA and glenosphere COR location. In a study by Beltrame *et al.* (57), the onlay design resulted in better active external rotation, extension, and adduction; however, this was compared with an inlay tray with a different NSA angle (145° for onlay and 155° inlay), which may also have affected the final outcome. A recent systematic review and meta-analysis by Larose *et al.* (58) showed no clear superiority of inlay or onlay tray design and only subtle differences in patient-reported outcome measures showing improvement for inlay implant and ROM improvement for the onlay implant.

### **Combined lateralization**

Great interest has been shown in the combined lateralization effect of different elements of the prosthesis. Computer templates considering factors that might affect impingement-free ROM showed that the best results came from a combination of a 135° NSA and 5 mm of glenoid lateralization (59). The authors of that study were aware that such configuration would still need clinical verification with consideration of soft tissue balance. A systematic review by Nunes *et al.* (60) showed that while lateralization of rTSA results in similar clinical outcomes, the risk of scapular notching is lower compared with a medialized rTSA. Nelson *et al.* (61), in their 1-year follow-up study, demonstrated a lower incidence of scapular notching and heterotrophic ossification along with a trend for better clinical outcomes for a lateralized design with 6- or 10-mm COR offset and 135° NSA angle than for a Grammont-style design with a 2.5-mm medial COR offset and a 155° NSA. In a recent study by Zitkovsky *et al.* (62), lateralization with a 10-mm lateral offset COR and 135° NSA implant resulted in lower incidence of scapular notching and less likelihood of heterotopic ossification.

Lateralization may lead to some potential complications. Acromial stress fractures occur in about 7% of rTSAs (63). The effect of implant positioning on acromial stresses was demonstrated in a cadaveric study by Wong *et al.* (64); glenosphere lateralization significantly increased stress on

the acromion. Cuff *et al.* (22) reported the 10-year survival rate free of revision for rTSAs with glenoid lateralization as 91%. Because low rates of notching may be attributable to shorter-term follow-up rather than to the few long-term observations available for medialized designs, more long-term studies need to be conducted.

## Conclusions

The current literature supports both traditional and lateralized rTSA designs, which can be successfully used to relieve pain and, to a large extent, restore shoulder function. Every design modification, including lateralization of specific elements, requires additional long-term studies to demonstrate clinical results and raise awareness of potential complications.

## Author commentary

While there have been several biomechanical studies on the effects of lateralization of the glenoid side and the humeral side in rTSA, the effects of these factors upon the clinical result remain inconclusive. In some ways it is reassuring that pain relief and shoulder function are increased regardless of whether the glenoid side or the humeral side is lateralized. Despite computer modeling and other means of estimating ROM with various implants, in the final analysis, none of them can predict the effect of lateralization of the implants because none of the models takes into account soft tissue constraints. The authors of the present review prefer a minimally lateralized glenoid component (2 mm) with a lateralized (*onlay*) humeral component. The primary benefit of a medialized or slightly lateralized glenoid component and a lateralized humerus is that it is the most biomechanically efficient design configuration and maximizes the deltoid abductor moment arm and also increases deltoid wrapping (17,65,66).

This combination of lateralization of either the glenoid or humeral components has several theoretical advantages. First, the subscapularis tendon is not reattached in most cases, and the configuration of the rTSA does not depend upon subscapularis attachment for stability (67). Second, this construct allows the patient more external rotation, as there is no limitation from reattachment of a shortened subscapularis tendon. Increased external rotation theoretically allows the humerus to prevent impingement against the acromion and superior glenoid as the arm is raised and, thus, allows greater elevation of the arm. Finally,

the patient is allowed early ROM without fear of instability because there is no subscapularis repair warranting protection, thus minimizing immobilization.

## Acknowledgments

For editorial assistance, we thank Denise Di Salvo, MS, Sandra Crump, MPH, and Rachel Box, MS, in the Editorial Services group of The Johns Hopkins Department of Orthopaedic Surgery.

*Funding:* None.

## Footnote

*Provenance and Peer Review:* This article was commissioned by the Guest Editor (Prashant Meshram) for the series “Controversies in Shoulder Surgery and Algorithmic Approach to Decision Making” published in *Annals of Joint*. The article has undergone external peer review.

*Reporting Checklist:* The authors have completed the Narrative Review reporting checklist. Available at <https://aoj.amegroups.org/article/view/10.21037/aoj-23-9/rc>

*Peer Review File:* Available at <https://aoj.amegroups.org/article/view/10.21037/aoj-23-9/prf>

*Conflicts of Interest:* All authors have completed the ICMJE uniform disclosure form (available at <https://aoj.amegroups.org/article/view/10.21037/aoj-23-9/coif>). The series “Controversies in Shoulder Surgery and Algorithmic Approach to Decision Making” was commissioned by the editorial office without any funding or sponsorship. EM declares royalties or licenses from Innomed, receives consulting fees and payment from Stryker Corporation. The authors have no other conflicts of interest to declare.

*Ethical Statement:* The authors are accountable for all aspects of the work in ensuring that questions related to the accuracy or integrity of any part of the work are appropriately investigated and resolved.

*Open Access Statement:* This is an Open Access article distributed in accordance with the Creative Commons Attribution-NonCommercial-NoDerivs 4.0 International License (CC BY-NC-ND 4.0), which permits the non-commercial replication and distribution of the article with the strict proviso that no changes or edits are made and the

original work is properly cited (including links to both the formal publication through the relevant DOI and the license). See: <https://creativecommons.org/licenses/by-nc-nd/4.0/>.

## References

- Best MJ, Aziz KT, Wilckens JH, et al. Increasing incidence of primary reverse and anatomic total shoulder arthroplasty in the United States. *J Shoulder Elbow Surg* 2021;30:1159-66.
- Holcomb JO, Hebert DJ, Mighell MA, et al. Reverse shoulder arthroplasty in patients with rheumatoid arthritis. *J Shoulder Elbow Surg* 2010;19:1076-84.
- Kurowicki J, Triplet JJ, Momoh E, et al. Reverse shoulder prosthesis in the treatment of locked anterior shoulders: a comparison with classic reverse shoulder indications. *J Shoulder Elbow Surg* 2016;25:1954-60.
- Anakwenze OA, Zoller S, Ahmad CS, et al. Reverse shoulder arthroplasty for acute proximal humerus fractures: a systematic review. *J Shoulder Elbow Surg* 2014;23:e73-80.
- McFarland EG, Meshram P, Rojas J, et al. Reverse Total Shoulder Arthroplasty without Bone-Grafting for Severe Glenoid Bone Loss in Patients with Osteoarthritis and Intact Rotator Cuff: A Concise 5-Year Follow-up of a Previous Report. *J Bone Joint Surg Am* 2021;103:581-5.
- Sanchez-Sotelo J, Wagner ER, Houdek MT. Allograft-Prosthetic Composite Reconstruction for Massive Proximal Humeral Bone Loss in Reverse Shoulder Arthroplasty. *JBJS Essent Surg Tech* 2018;8:e3.
- Werthel JD, Schoch B, Frankle M, et al. Shoulder Arthroplasty for Sequelae of Obstetrical Brachial Plexus Injury. *J Hand Surg Am* 2018;43:871.e1-7.
- Wagner ER, Chang MJ, Welp KM, et al. The impact of the reverse prosthesis on revision shoulder arthroplasty: analysis of a high-volume shoulder practice. *J Shoulder Elbow Surg* 2019;28:e49-56.
- Wagner ER, Farley KX, Higgins I, et al. The incidence of shoulder arthroplasty: rise and future projections compared with hip and knee arthroplasty. *J Shoulder Elbow Surg* 2020;29:2601-9.
- Boileau P, Watkinson DJ, Hatzidakis AM, et al. Grammont reverse prosthesis: design, rationale, and biomechanics. *J Shoulder Elbow Surg* 2005;14:147S-61S.
- Paszicsnyek A, Jo O, Rupasinghe HS, et al. Factors Influencing Acromial and Scapular Spine Strain after Reverse Total Shoulder Arthroplasty: A Systematic Review of Biomechanical Studies. *J Clin Med* 2022;11:361.
- Haislup BD, Ashmyan R, Johnston PS, et al. Effect of glenosphere lateralization with and without coracoacromial ligament transection on acromial and scapular spine strain in reverse shoulder arthroplasty. *JSES Int* 2022;6:884-8.
- Wall B, Nové-Josserand L, O'Connor DP, et al. Reverse total shoulder arthroplasty: a review of results according to etiology. *J Bone Joint Surg Am* 2007;89:1476-85.
- Wierks C, Skolasky RL, Ji JH, et al. Reverse total shoulder replacement: intraoperative and early postoperative complications. *Clin Orthop Relat Res* 2009;467:225-34.
- Familiari F, Rojas J, Nedim Doral M, et al. Reverse total shoulder arthroplasty. *EFORT Open Rev* 2018;3:58-69.
- Liu B, Kim YK, Nakla A, et al. Biomechanical Consequences of Glenoid and Humeral Lateralization in Reverse Total Shoulder Arthroplasty. *J Shoulder Elbow Surg* 2023;S1058-2746(23)00317-8.
- Cogan CJ, Ho JC, Entezari V, et al. The Influence of Reverse Total Shoulder Arthroplasty Implant Design on Biomechanics. *Curr Rev Musculoskelet Med* 2023;16:95-102.
- Nicholson GP, Strauss EJ, Sherman SL. Scapular notching: Recognition and strategies to minimize clinical impact. *Clin Orthop Relat Res* 2011;469:2521-30.
- Kennon JC, Songy C, Bartels D, et al. Primary reverse shoulder arthroplasty: how did medialized and glenoid-based lateralized style prostheses compare at 10 years? *J Shoulder Elbow Surg* 2020;29:S23-31.
- Zhang M, Junaid S, Gregory T, et al. Impact of scapular notching on glenoid fixation in reverse total shoulder arthroplasty: an in vitro and finite element study. *J Shoulder Elbow Surg* 2020;29:1981-91.
- Läderrmann A, Schwitzguebel AJ, Edwards TB, et al. Glenoid loosening and migration in reverse shoulder arthroplasty. *Bone Joint J* 2019;101-B:461-9.
- Cuff DJ, Pupello DR, Santoni BG, et al. Reverse Shoulder Arthroplasty for the Treatment of Rotator Cuff Deficiency: A Concise Follow-up, at a Minimum of 10 Years, of Previous Reports. *J Bone Joint Surg Am* 2017;99:1895-9.
- Harman M, Frankle M, Vasey M, et al. Initial glenoid component fixation in "reverse" total shoulder arthroplasty: a biomechanical evaluation. *J Shoulder Elbow Surg*. 2005;14:162S-167S.
- Lévigne C, Garret J, Boileau P, et al. Scapular notching in reverse shoulder arthroplasty: is it important to avoid it and how? *Clin Orthop Relat Res* 2011;469:2512-20.
- Friedman RJ, Barcel DA, Eichinger JK. Scapular Notching in Reverse Total Shoulder Arthroplasty. *J Am Acad Orthop Surg* 2019;27:200-9.

26. Spiry C, Berhouet J, Agout C, et al. Long-term impact of scapular notching after reverse shoulder arthroplasty. *Int Orthop* 2021;45:1559-66.
27. Jang YH, Lee JH, Kim SH. Effect of scapular notching on clinical outcomes after reverse total shoulder arthroplasty. *Bone Joint J* 2020;102-B:1438-45.
28. Bitzer A, Rojas J, Patten IS, et al. Incidence and risk factors for aseptic baseplate loosening of reverse total shoulder arthroplasty. *J Shoulder Elbow Surg* 2018;27:2145-52.
29. Chae J, Siljander M, Wiater JM. Instability in Reverse Total Shoulder Arthroplasty. *J Am Acad Orthop Surg* 2018;26:587-96.
30. Huri G, Familiari F, Salari N, et al. Prosthetic design of reverse shoulder arthroplasty contributes to scapular notching and instability. *World J Orthop* 2016;7:738-45.
31. Longo UG, Gulotta LV, De Salvatore S, et al. The Role of Humeral Neck-Shaft Angle in Reverse Total Shoulder Arthroplasty: 155° versus <155°—A Systematic Review. *J Clin Med* 2022;11:3641.
32. Gutiérrez S, Comiskey CA 4th, Luo ZP, et al. Range of impingement-free abduction and adduction deficit after reverse shoulder arthroplasty. Hierarchy of surgical and implant-design-related factors. *J Bone Joint Surg Am* 2008;90:2606-15.
33. Tashjian RZ, Burks RT, Zhang Y, et al. Reverse total shoulder arthroplasty: a biomechanical evaluation of humeral and glenosphere hardware configuration. *J Shoulder Elbow Surg* 2015;24:e68-77.
34. Werner BC, Lederman E, Gobezie R, et al. Glenoid lateralization influences active internal rotation after reverse shoulder arthroplasty. *J Shoulder Elbow Surg* 2021;30:2498-505.
35. Virani NA, Cabezas A, Gutiérrez S, et al. Reverse shoulder arthroplasty components and surgical techniques that restore glenohumeral motion. *J Shoulder Elbow Surg* 2013;22:179-87.
36. Berhouet J, Garaud P, Favard L. Evaluation of the role of glenosphere design and humeral component retroversion in avoiding scapular notching during reverse shoulder arthroplasty. *J Shoulder Elbow Surg* 2014;23:151-8.
37. Hasan SS, Levy JC, Leitze ZR, et al. Reverse shoulder prosthesis with a lateralized glenosphere: early results of a prospective multicenter study stratified by diagnosis. *J Shoulder Elbow Arthroplasty* 2019;3. doi: 10.1177/2471549219844040.
38. Ho JC, Thakar O, Chan WW, et al. Early radiographic failure of reverse total shoulder arthroplasty with structural bone graft for glenoid bone loss. *J Shoulder Elbow Surg* 2020;29:550-60.
39. Mahyilis JM, Puzzitiello RN, Ho JC, et al. Comparison of radiographic and clinical outcomes of revision reverse total shoulder arthroplasty with structural versus nonstructural bone graft. *J Shoulder Elbow Surg* 2019;28:e1-9.
40. Collin P, Liu X, Denard PJ, et al. Standard versus bony increased-offset reverse shoulder arthroplasty: a retrospective comparative cohort study. *J Shoulder Elbow Surg* 2018;27:59-64.
41. Greiner S, Schmidt C, Herrmann S, et al. Clinical performance of lateralized versus non-lateralized reverse shoulder arthroplasty: a prospective randomized study. *J Shoulder Elbow Surg* 2015;24:1397-404.
42. Athwal GS, MacDermid JC, Reddy KM, et al. Does bony increased-offset reverse shoulder arthroplasty decrease scapular notching? *J Shoulder Elbow Surg* 2015;24:468-73.
43. Ghanta RB, Tsay EL, Feeley B. Augmented baseplates in reverse shoulder arthroplasty: a systematic review of outcomes and complications. *JSES Rev Rep Tech* 2023;3:37-43.
44. Van de Kleut ML, Yuan X, Teeter MG, et al. Bony increased-offset reverse shoulder arthroplasty vs. metal augments in reverse shoulder arthroplasty: a prospective, randomized clinical trial with 2-year follow-up. *J Shoulder Elbow Surg* 2022;31:591-600.
45. Levin JM, Bokshan S, Roche CP, et al. Reverse shoulder arthroplasty with and without baseplate wedge augmentation in the setting of glenoid deformity and rotator cuff deficiency—a multicenter investigation. *J Shoulder Elbow Surg* 2022;31:2488-96.
46. Hettrich CM, Permeswaran VN, Goetz JE, et al. Mechanical tradeoffs associated with glenosphere lateralization in reverse shoulder arthroplasty. *J Shoulder Elbow Surg* 2015;24:1774-81.
47. Wright MA, Murthi AM. Offset in Reverse Shoulder Arthroplasty: Where, When, and How Much. *J Am Acad Orthop Surg* 2021;29:89-99.
48. Kempton LB, Balasubramaniam M, Ankersen E, et al. A radiographic analysis of the effects of prosthesis design on scapular notching following reverse total shoulder arthroplasty. *J Shoulder Elbow Surg* 2011;20:571-6.
49. Frankle M, Siegal S, Pupello D, et al. The Reverse Shoulder Prosthesis for glenohumeral arthritis associated with severe rotator cuff deficiency. A minimum two-year follow-up study of sixty patients. *J Bone Joint Surg Am* 2005;87:1697-705.
50. Giles JW, Langohr GD, Johnson JA, et al. Implant Design Variations in Reverse Total Shoulder Arthroplasty



- Influence the Required Deltoid Force and Resultant Joint Load. *Clin Orthop Relat Res* 2015;473:3615-26.
51. Kolmodin J, Davidson IU, Jun BJ, et al. Scapular Notching After Reverse Total Shoulder Arthroplasty: Prediction Using Patient-Specific Osseous Anatomy, Implant Location, and Shoulder Motion. *J Bone Joint Surg Am* 2018;100:1095-103.
  52. Gobezie R, Shishani Y, Lederman E, et al. Can a functional difference be detected in reverse arthroplasty with 135° versus 155° prosthesis for the treatment of rotator cuff arthropathy: a prospective randomized study. *J Shoulder Elbow Surg* 2019;28:813-8.
  53. Erickson BJ, Harris JD, Romeo AA. The Effect of Humeral Inclination on Range of Motion in Reverse Total Shoulder Arthroplasty: A Systematic Review. *Am J Orthop (Belle Mead NJ)* 2016;45:E174-9.
  54. Meshram P, Joseph J, Zhou Y, et al. Lateralized glenosphere reverse shoulder arthroplasty: inlay and onlay designs have similar clinical outcomes in patients with glenohumeral osteoarthritis. *J Shoulder Elbow Surg* 2022;31:747-54.
  55. Polisetty TS, Baessler AM, Levy JC, et al. Onlay versus inlay reverse total shoulder arthroplasty: a retrospective comparison of radiographic and clinical outcomes. *Semin Arthroplasty: JSES* 2021;31:202-8.
  56. Merolla G, Walch G, Ascione F, et al. Grammont humeral design versus onlay curved-stem reverse shoulder arthroplasty: comparison of clinical and radiographic outcomes with minimum 2-year follow-up. *J Shoulder Elbow Surg* 2018;27:701-10.
  57. Beltrame A, Di Benedetto P, Cicuto C, et al. Onlay versus Inlay humeral stem in Reverse Shoulder Arthroplasty (RSA): clinical and biomechanical study. *Acta Biomed* 2019;90:54-63.
  58. Larose G, Fisher ND, Gambhir N, et al. Inlay versus onlay humeral design for reverse shoulder arthroplasty: a systematic review and meta-analysis. *J Shoulder Elbow Surg* 2022;31:2410-20.
  59. Werner BS, Chaoui J, Walch G. The influence of humeral neck shaft angle and glenoid lateralization on range of motion in reverse shoulder arthroplasty. *J Shoulder Elbow Surg* 2017;26:1726-31.
  60. Nunes J, Andrade R, Azevedo C, et al. Improved Clinical Outcomes After Lateralized Reverse Shoulder Arthroplasty: A Systematic Review. *Clin Orthop Relat Res* 2022;480:949-57.
  61. Nelson R, Lowe JT, Lawler SM, et al. Lateralized Center of Rotation and Lower Neck-Shaft Angle Are Associated With Lower Rates of Scapular Notching and Heterotopic Ossification and Improved Pain for Reverse Shoulder Arthroplasty at 1 Year. *Orthopedics* 2018;41:230-6.
  62. Zitkovsky HS, Carducci MP, Mahendraraj KA, et al. Lateralization and Decreased Neck-Shaft Angle Reduces Scapular Notching and Heterotopic Ossification. *J Am Acad Orthop Surg* 2020;28:e1073-80.
  63. Lucasti CJ, Namdari S. Acromial Stress Fractures: A Systematic Review. *Arch Bone Jt Surg* 2019;7:397-401.
  64. Wong MT, Langohr GDG, Athwal GS, et al. Implant positioning in reverse shoulder arthroplasty has an impact on acromial stresses. *J Shoulder Elbow Surg* 2016;25:1889-95.
  65. Parry S, Stachler S, Mahylis J. Lateralization in reverse shoulder arthroplasty: A review. *J Orthop* 2020;22:64-7.
  66. Roche CP, Diep P, Hamilton M, et al. Impact of inferior glenoid tilt, humeral retroversion, bone grafting, and design parameters on muscle length and deltoid wrapping in reverse shoulder arthroplasty. *Bull Hosp Jt Dis (2013)* 2013;71:284-93.
  67. Friedman RJ, Flurin PH, Wright TW, et al. Comparison of reverse total shoulder arthroplasty outcomes with and without subscapularis repair. *J Shoulder Elbow Surg* 2017;26:662-8.

doi: 10.21037/aoj-23-9

**Cite this article as:** Łukasiewicz P, Harris AB, Bervell JA, McFarland EG. Narrative review of influence of prosthesis lateralization on clinical outcomes in reverse shoulder arthroplasty: glenoid *vs.* humerus *vs.* combined. *Ann Joint* 2023;8:24.