

# The epithelioid gastrointestinal stromal tumor with pulmonary metastasis

## A rare case report and literature review

Dan Xu, MM, Xuyong Lin, MD, Xueshan Qiu, MD, PhD\*

### Abstract

**Rationale:** Available literature states that the histological subtype of the gastrointestinal stromal tumor (GIST) with pulmonary metastasis is often spindle cell type. To our knowledge, this is the first report of the GIST with pulmonary metastasis of very uncommon epithelioid subtype.

**Patient concerns:** We report a 63-year-old male presenting with the symptom of bloodstained sputum without obvious inducement. The patient had no chest pain, low back pain, fatigue, fever or night sweats symptoms.

**Diagnoses:** Combined chest digital radiography and the history of the patient who presented with the colon GIST of the epithelioid subtype two years ago that the mass may be a metastasis tumor. Combined with morphological and immunohistochemical staining results, a pathological diagnosis of the GIST with pulmonary metastasis was considered.

**Interventions:** Right lobectomy and partial upper lobectomy were performed.

**Outcomes:** The patient had not experienced any noticeable symptom and recurrent tumors at 6 months follow-up.

**Lessons:** We report a rare case of the GIST with pulmonary metastasis of epithelioid subtype. This case is of great significance to the pathologist's clinical work. For pathologists, if an epithelioid tumor in the lung is found, it is necessary to check whether the gastrointestinal tract also has the tumor, which may be an epithelioid GIST with pulmonary metastasis.

**Abbreviations:** CK = cytokeratin, CK7 = cytokeratin 7, GIST = gastrointestinal stromal tumor, LCA = leukocyte common antigen, NEC = neuroendocrine carcinoma, PDGFR- $\alpha$  = platelet-derived growth factor receptor alpha, SMA = smooth muscle actin, Syn = synaptophysin, TKI = Tyrosine kinase inhibitors, TTF-1 = thyroid transcription factor 1.

**Keywords:** epithelioid, gastrointestinal stromal tumor, mesothelioma, neuroendocrine carcinoma, pulmonary metastasis

### 1. Introduction

Gastrointestinal stromal tumors (GISTs), the most common mesenchymal tissue tumors in the gastrointestinal tract, occur primarily in the elderly over 50 years old patients of either sex.<sup>[1]</sup> GISTs are most commonly present in the stomach (50%–70%) and small intestine (25%–36%), but they also arise in the colon, rectum, appendix (5%–7% together), and esophagus (1%–3%).<sup>[2]</sup> Although most GISTs are localized at presentation, up to

half will recur locally, spread diffusely throughout the serosal surfaces of the abdomen.<sup>[1]</sup> Approximately 10% to 30% of GISTs exhibit metastasis behavior.<sup>[2]</sup> GISTs most often metastasize to the liver (50%–60%) and peritoneum (20%–43%), but they rarely metastasize outside the abdominal cavity, especially the bone and lung (10% together).<sup>[3]</sup> Microscopically GISTs come in 3 different histological subtypes: pure spindle cells type (70%), pure epithelioid type (20%) or mixed morphology type (10%).

Authors checked PubMed and MEDLINE databases for the last 10 years searching for the epithelioid GIST with pulmonary metastasis. To our knowledge, this is the first report of the GIST with pulmonary metastasis of very uncommon epithelioid subtype. Herein, we report this case and review the literature with a special focus on the epithelioid subtype of GIST with metastasis.

### 2. Case report

In October 2018, a 63-year-old male presented with the symptom of bloodstained sputum, low volume and bright red color without obvious inducement. The patient had no chest pain, low back pain, fatigue, fever or night sweats symptoms. Chest digital radiography revealed a mass with a diameter of about 5.2cm was observed in the right middle lobe (Fig. 1). Other clinical examinations were normal. The patient was treated with right lobectomy and partial upper lobectomy. On macroscopic examination, the tumor, approximately 4cm in diameter, was located about 1.5cm away from the hilar bronchus and 0.3cm

Editor: N/A.

The patient provided his informed consent for the publication of this case report. This research was supported by funding from the High School Innovation Team, Liaoning Province, China (No.LT2015029).

The authors declare that there are no conflicts of interest regarding the publication of this paper.

Department of Pathology, the First Affiliated Hospital and College of Basic Medical Sciences, China Medical University, Shenyang, China.

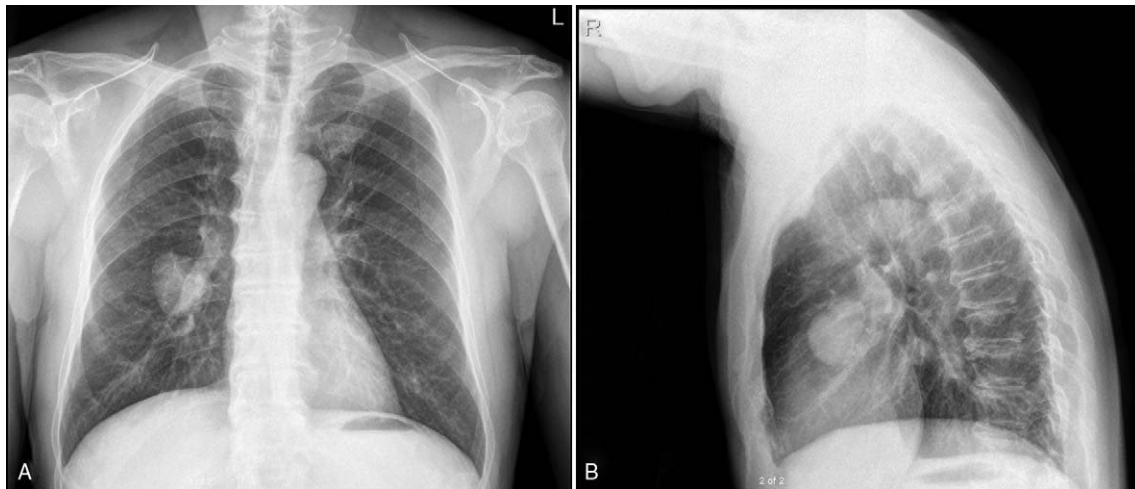
\* Correspondence: Xueshan Qiu, Department of Pathology, the First Affiliated Hospital and College of Basic Medical Sciences, China Medical University, 155 Nanjing Street, Shenyang, China (e-mail: XueshanQiu@hotmail.com).

Copyright © 2020 the Author(s). Published by Wolters Kluwer Health, Inc. This is an open access article distributed under the Creative Commons Attribution License 4.0 (CCBY), which permits unrestricted use, distribution, and reproduction in any medium, provided the original work is properly cited.

How to cite this article: Xu D, Lin X, Qiu X. The epithelioid gastrointestinal stromal tumor with pulmonary metastasis: A rare case report and literature review. *Medicine* 2020;99:9(e19346).

Received: 28 May 2019 / Received in final form: 16 December 2019 / Accepted: 29 January 2020

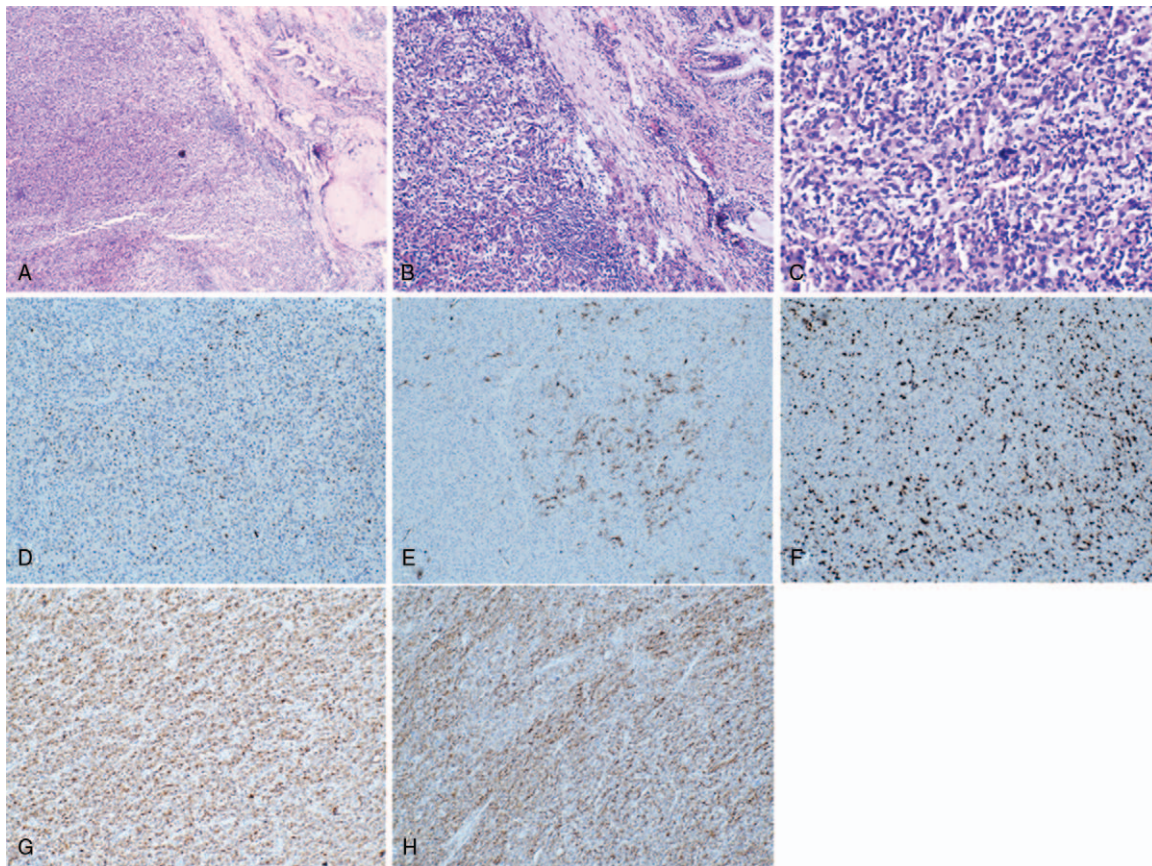
<http://dx.doi.org/10.1097/MD.00000000000019346>



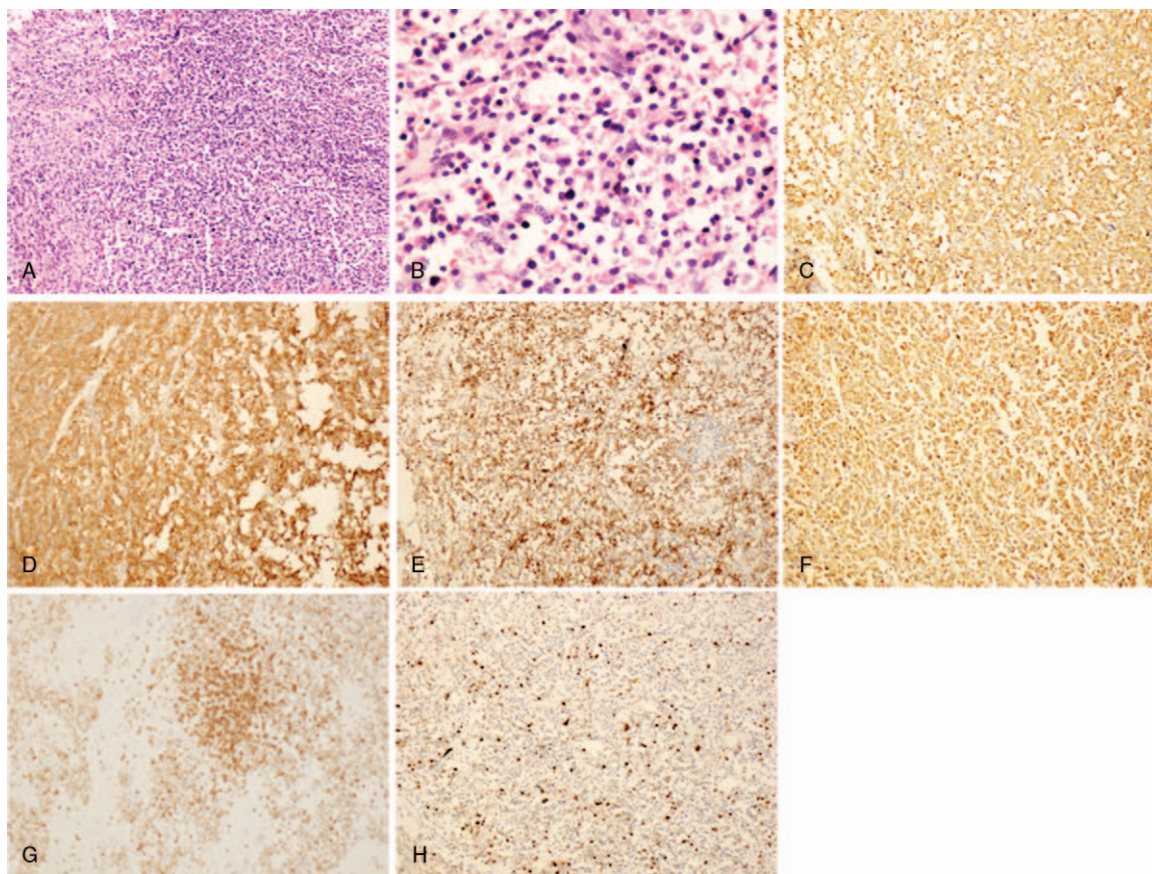
**Figure 1.** Images of chest forward (A) and lateral (B) digital radiography. It revealed bilateral thoracic symmetry and a mass with a diameter of about 5.2 cm was seen in the right middle lobe.

below the pleura. The boundary between the tumor and the surrounding tissue is clear. The tumor was sectioned and stained with H&E for further evaluation (Fig. 2A–C). Light microscopy revealed that tumor cells were epithelioid, round or oval. Immunohistochemical study showed positivity for P63 (scattered

positive), smooth muscle actin (SMA) (multifocal positive) (Fig. 2D–E) and negativity for cytokeratin (CK), CD5/6, synaptophysin (Syn), thyroid transcription factor 1 (TTF-1), cytokeratin 7 (CK7), S-100, P40, CD56, leukocyte common antigen (LCA), Melan-A and SOX10. The Ki67 labeling index



**Figure 2.** Histologic and immunohistologic feature of the mass. H&E showing epithelioid cells in the pulmonary tissue on low power (A, 40×) and high power (B: 100×, C: 400×). Immunohistochemical study showed positivity for P63 (D, 100×), SMA (E, 100×) and the Ki67 labeling index was estimated to be approximately 30% (F, 100×). Immunohistochemical study showed positivity for CD117 (G, 100×), Dog-1 (H, 100×).



**Figure 3.** Histologic and immunohistologic feature of epithelioid gastrointestinal stromal tumor in the transverse colon. H&E showing that tumor cells are round or polygonal, the cytoplasm is rich in eosinophilic or bright on low power (A, 100 $\times$ ) and high power (B, 400 $\times$ ). Immunohistochemical study showed positivity for CD34 (C, 100 $\times$ ), CD117 (D, 100 $\times$ ), SMA (E, 100 $\times$ ), Vimentin (F, 100 $\times$ ), CD3 (G, 100 $\times$ ) and the Ki67 labeling index was estimated to be approximately 10% (H, 100 $\times$ ).

was estimated to be approximately 30% (Fig. 2F). So it excluded adenocarcinoma, and neuroendocrine carcinoma (NEC). However, the diagnosis of the tumor remained uncertain.

A review of the patient's history revealed that, in 2016, the patient presented with the colon GIST with epithelioid type. Microscopy revealed a proliferation of epithelioid cells in the lesion (Fig. 3A-B). Immunohistochemical study showed positivity for CD34, CD117, SMA, Vimentin (weakly positive), CD3 (few positive) and negativity for CK, CD56, Syn, TTF-1, Desmin, S-100, CD20, CDX-2 and Pax5. The Ki67 labeling index was estimated to be approximately 10% (Fig. 3C-H). So for this tumor in the lung, adenocarcinoma and NEC had been excluded, and we considered metastases to the pulmonary as the epithelioid GIST. Therefore, CD117 and Dog-1 staining were performed on lung tumor tissues, and the results showed that CD117 and Dog-1 were positive (Fig. 2G-H), effectively the diagnosis of the epithelioid GIST with pulmonary metastasis. The patient was followed up for 6 months without symptoms and residual/recurrent tumors.

### 3. Discussion

In general, GISTs display 3 different histological subtypes: pure spindle cells type (70%), pure epithelioid type (20%) or mixed morphology type (10%). The spindled, epithelioid and mixed morphology GISTs are reported to be significantly more common

in the small intestine, stomach, and stomach, respectively.<sup>[4,5]</sup> The growth of most GISTs is driven by oncogene mutations in either of two receptor tyrosine kinases: C-KIT (70%–80%) or platelet-derived growth factor receptor alpha (PDGFR- $\alpha$ ) (8%–10%).<sup>[4,6]</sup> No mutants for both genes of GISTs are wild type. Representative genotypes of epithelioid cell type GISTs are C-KIT gene mutants and PDGFR- $\alpha$  gene mutants. Approximately half of epithelioid GISTs are C-KIT gene mutations. In residual half of epithelioid cell type GISTs are PDGFR- $\alpha$  gene mutants.<sup>[7]</sup>

The frequency of C-KIT mutations in epithelioid GISTs may be lower than in spindle cell variants.<sup>[8]</sup> C-KIT mutated GISTs with epithelioid/mixed phenotype are of significantly larger diameters and have significantly higher mitotic counts, high-risk categories and a short disease-free survival compared with their pure spindled type.<sup>[4]</sup> These observations suggest that the spindled type represents the basic growth pattern in C-KIT mutant GISTs, whereas the epithelioid type may represent a secondary growth pattern.<sup>[4]</sup> However, the differences in tumor diameter, mitotic counts, risk categories and disease-free survival between C-KIT mutated GISTs with pure spindled and epithelioid/mixed phenotypes are only observed in gastric GISTs, whereas there are no significant differences comparing tumors with different growth patterns from the small intestine and the colon.<sup>[4]</sup> On the other hand, the predominance histopathologic phenotype of PDGFR- $\alpha$  mutated GISTs displays epithelioid or mixed (predominantly epithelioid) phenotypes.<sup>[4]</sup> However, up-to-date

studies did not reflect on an exact association of PDGFR- $\alpha$  mutant GISTs with a specific histopathologic phenotype.<sup>[8]</sup>

The epithelioid component displays unfavorable histological features (higher cellularity, higher mitotic activity and higher Ki67 index), and is associated with more aggressive clinical course. The presence of an epithelioid/mixed morphology component in GISTs is associated with malignant behavior in GISTs.<sup>[4]</sup>

### 3.1. Literature review

There are only 10 cases reported the epithelioid or mixed morphology type GISTs with metastasis, and the related clinical data of these 10 cases are summarized in the table (Table 1). The age of the 10 patients ranged from 13 to 70, with an average age of 48.7 years with a male to female ratio of 7:3. Two of ten cases the primary site of the tumor are the stomach. The size of the primary tumor ranges from 2 cm to 15 cm, with an average of 6.2 cm. Three cases report the histological of the metastasis tumor is composed of pure epithelioid cells. Others are mixed morphology type. The site of the metastasis tumor is in the abdominal cavity in only two cases and two is in the brain, two is in the bone, one is in the skin, one is in the supraclavicular lymph node, and one is in the lung (this case). There are very few cases of pure epithelioid or the mixed GISTs with metastasis, therefore, the pathologists must pay more attention to the diagnosis of the epithelioid/mixed GIST, especially metastasis to the rare location.

### 3.2. Diagnostic approaches

GISTs manifest a wide range of morphology, from spindle cell to epithelioid. The spindle subtype GISTs is composed of fusiform cells, rod-shaped or long fusiform nucleus. The epithelioid subtype GISTs is composed of uniformly rounded cells with abundant, clear to eosinophilic cytoplasm, and round or oval nuclei. The mixed subtype consists of cells with typical features of either spindle-shaped or epithelioid type.<sup>[8]</sup> To diagnosis GISTs need immunocytochemical markers, as GISTs are not specific in the morphology.

CD117 and Dog-1 are immunocytochemical markers of GISTs characteristic in all cases.<sup>[11]</sup> CD117 overexpression is the most sensitive and highly specific marker of stromal tumors detected in nearly 90% to 95% of cases. Although immunopositive for

CD117 is the most sensitive marker of GISTs with the spindle type, approximately 82% of the epithelioid gastric GISTs show no signs of CD117 expression.<sup>[5]</sup> In cases of epithelioid cell type GISTs with C-KIT gene mutations, CD117 is expressed strongly and diffusely. However, in the epithelioid cell type GISTs with PDGFR- $\alpha$  gene mutants, expression of CD117 is variable. Herein, diagnosis of GISTs with low or almost no CD117 expression may be difficult. Although CD117 and Dog-1 show a very similar expression pattern, Dog-1 may be more clearly positive in some PDGFR- $\alpha$  mutant GISTs, and CD117 may be more clearly positive than Dog-1 in other PDGFR- $\alpha$  mutant GISTs. In addition, Dog-1 and CD34 are expressed in most GISTs. Thus, Dog-1 immunohistochemical may be useful for diagnosis of the epithelioid GISTs with low or almost no CD117 expression.

Other markers such as CD34 and Ki67 are also representative but less specific. About half of epithelioid type GISTs can express CD34. However, the expression of CD34 varies greatly with the anatomical site. CD34 is almost universally positive in GISTs located in esophagus or rectum (95%–100%). CD34 is expressed in 80% to 88% of gastric GISTs. However, CD34-negative epithelioid-type gastric stromal tumors have been shown to be more aggressive.<sup>[5]</sup> Ki-67 labeling index is variable from tumor to tumor. High Ki-67 labeling index and high mitotic counts might predict the high recurrence rate of the GISTs.<sup>[7]</sup> SMA is expressed in only approximately 30% of patients, but is significantly more common in GISTs located in the stomach or small intestine. S-100 should be paid more attention to the diagnosis of GISTs, as it is present in only approximately 5% of patients and is especially common in epithelioid type tumors, the majority of which are more malignant.<sup>[5]</sup> Expression of desmin, ALK, nuclear  $\beta$ -catenin and nuclear STAT6 is not usually detected.

### 3.3. Differential diagnosis

In clinical work, for the different type GISTs, it is necessary for the pathologist to differentiate them from many kinds of tumors, especially the GISTs metastasis to the rare location.

The spindle type GISTs must be distinguished from many kinds of tumors, such as fibromatosis (can be weakly CD117 positive), leiomyoma (beware of intermixed CD117-positive cells), leiomyosarcoma, schwannoma, malignant peripheral nerve sheath

**Table 1**  
Related clinical data of the epithelioid or mixed morphology type GISTs with metastasis cases.

Year	Author	Age/ Sex	Primary GIST			Metastasis GIST			Period of the metastasis	Therapy for the metastasis	Outcome
			Site	Size (cm)	Histology	Site	Size (cm)				
2008	Canda et al <sup>[9]</sup>	32/F	Stomach	8	Epithelioid	Periantral LN	1	At initial diagnosis	Resection+ TKI	NA	
2011	Otto et al <sup>[10]</sup>	13/F	Stomach	8.1	Mixed	Liver; LN	2.2	At initial diagnosis;	Resection+ TKI	NA	
2004	Hughes et al <sup>[11]</sup>	47/M	Jejunal	5	Mixed	Cerebral ;liver	NA	3 years	Resection +TKI	DOD	
2018	Badri et al <sup>[12]</sup>	66/M	NA	NA	Epithelioid	Cerebellar	4	NA	Resection	AWD;12months	
2015	Aktan et al <sup>[13]</sup>	56/M	Small intestine	9	Mixed	Liver Bone	NA	At initial diagnosis 4 months	Resection +TKI	DOD	
2015	Aktan et al <sup>[13]</sup>	70/M	Small intestine	15	Mixed	Liver Bone	NA	At initial diagnosis 5 months	Resection +TKI	DOD	
2011	Otto et al <sup>[10]</sup>	15/F	Stomach	7	Mixed	Liver	4	At initial diagnosis	Resection+ TKI	NA	
2017	Ma et al <sup>[14]</sup>	56/M	Jejunum	2	Mixed	Supraclavicular LN	NA	1yeas	Resection+ TKI	AWD,1 years	
2018	Kim et al <sup>[15]</sup>	69/M	Duodena	NA	Mixed	Skin	1.5	20days	Biopsy+ TKI	AWD,6months	
2019	Xu et al (This case)	63/M	Colon	8	Epithelioid	Lung	4	2years	Resection	AWD;6months	

AWD=alive with disease, DOD=died of disease, F=female, GIST=gastrointestinal stromal tumor, LN=lymph node, M=male, NA=not available, TKI=tyrosine kinase inhibitor.

tumor, inflammatory myofibroblastic tumor, inflammatory fibroid polyp (may have PDGFR- $\alpha$  mutations), solitary fibrous tumor, synovial sarcoma, dedifferentiated liposarcoma, endometrial stromal sarcoma, sarcomatoid carcinoma.<sup>[1]</sup>

The epithelioid type GISTs must be distinguished from many kinds of tumors, such as epithelioid leiomyoma, NEC, malignant mesothelioma, metastatic melanoma and angiosarcoma.<sup>[1]</sup>

Cases of simultaneous occurrence of a GIST with a well-differentiated NEC have been reported at present, and CD117 is positive, so the pathologists need to pay more attention to the differentiation between GISTs and NEC.<sup>[16,17]</sup> In the NEC, immunopositive for CK, CgA, and Syn.<sup>[18]</sup> In the malignant mesothelioma, the immunocytochemical for CK5/6 and EMA are positive, but CD117 is not expression. About 30%-50% of malignant melanoma can express CD117, especially metastatic melanoma. Nevertheless, the expressions of Melan-A, HMB45, and S-100 were positive in malignant melanoma. In the pulmonary epithelioid angiosarcoma, immunopositive for CD31, CD34, and EGR.<sup>[19]</sup>

### 3.4. Treatment and prognostic

Surgical resection of the tumor and the use of tyrosine kinase inhibitors (TKI) drugs are the main methods for the treatment of GISTs.<sup>[3]</sup> While treatment with TKI such as imatinib, sunitinib, and regorafenib are effective in controlling the unresectable disease.<sup>[1]</sup> A surveillance, epidemiology, and end results analysis indicated that patients with GISTs with metastasis had a poorer prognosis than those without.<sup>[20]</sup> Lung metastases and the epithelioid type seemed to be a poor prognostic factor in this patient with GISTs.<sup>[21]</sup>

## 4. Conclusion

We report a case of a 62-year-old man with the epithelioid GIST with pulmonary metastasis manifesting 32 months after surgical resection of the colon GIST for the first time. GISTs rarely metastasize to the lungs. Therefore, GISTs with pulmonary metastasis should be distinguished from various tumors. For pathologists, if an epithelioid tumor in the lung is found, it is necessary to check whether the gastrointestinal tract also has the tumor, which may be an epithelioid GIST with pulmonary metastasis. It is very rare that the epithelioid GISTs with metastasis. Therefore, pathologists must pay more attention to the diagnosis of the epithelioid/mixed GIST, especially metastasis to the rare location.

## Author contributions

**Conceptualization:** Dan Xu, Xuyong Lin, Xueshan Qiu.

**Investigation:** Dan Xu.

**Project administration:** Xueshan Qiu.

**Resources:** Dan Xu, Xuyong Lin.

**Writing – original draft:** Dan Xu.

**Writing – review & editing:** Dan Xu, Xuyong Lin, Xueshan Qiu. Xueshan Qiu orcid: 0000-0002-7647-8110.

## References

- Corless CL. Gastrointestinal stromal tumors: what do we know now? *Mod Pathol* 2014;27(Suppl 1):S1–16.
- Cimen SG, MacDonald F, Cimen S, et al. A gastrointestinal stromal tumour with pulmonary metastases mimicking unilateral gynaecomastia. *BMJ Case Rep* 2013;16:2013.
- Ozan E, Oztekin O, Alacacioglu A, et al. Esophageal gastrointestinal stromal tumor with pulmonary and bone metastases. *Diagn Interv Radiol* 2010;16:217–20.
- Haller F, Cortis J, Helfrich J, et al. Epithelioid/mixed phenotype in gastrointestinal stromal tumors with KIT mutation from the stomach is associated with accelerated passage of late phases of the cell cycle and shorter disease-free survival. *Mod Pathol* 2011;24:248–55.
- Lech G, Korcz W, Kowalczyk E, et al. Giant gastrointestinal stromal tumour of rare sarcomatoid epithelioid subtype: case study and literature review. *World J Gastroenterol* 2015;21:3388–93.
- Penzel R, Aulmann S, Mook M, et al. The location of KIT and PDGFRA gene mutations in gastrointestinal stromal tumours is site and phenotype associated. *J Clin Pathol* 2005;58:634–9.
- Hirota S. Differential diagnosis of gastrointestinal stromal tumor by histopathology and immunohistochemistry. *Transl Gastroenterol Hepatol* 2018;3:27.
- Wasag B, Debiec-Rychter M, Pauwels P, et al. Differential expression of KIT/PDGFR mutant isoforms in epithelioid and mixed variants of gastrointestinal stromal tumors depends predominantly on the tumor site. *Mod Pathol* 2004;17:889–94.
- Canda AE, Ozsoy Y, Nalbant OA, et al. Gastrointestinal stromal tumor of the stomach with lymph node metastasis. *World J Surg Oncol* 2008;6:97.
- Otto C, Agaimy A, Braun A, et al. Multifocal gastric gastrointestinal stromal tumors (GISTs) with lymph node metastases in children and young adults: a comparative clinical and histomorphological study of three cases including a new case of Carney triad. *Diagn Pathol* 2011;6:52.
- Hughes B, Yip D, Goldstein D, et al. Cerebral relapse of metastatic gastrointestinal stromal tumor during treatment with imatinib mesylate: case report. *BMC Cancer* 2004;4:74.
- Badri M, Chabaane M, Gader G, et al. Cerebellar metastasis of gastrointestinal stromal tumor: A case report and review of the literature. *Int J Surg Case Rep* 2018;42:165–8.
- Aktan M, Koc M, Yavuz BB, et al. Two cases of gastrointestinal stromal tumor of the small intestine with liver and bone metastasis. *Ann Transl Med* 2015;3:259–62.
- Ma C, Hao SL, Liu XC, et al. Supraclavicular lymph node metastases from malignant gastrointestinal stromal tumor of the jejunum: A case report with review of the literature. *World J Gastroenterol* 2017;23:1920–4.
- Kim YJ, Lee WJ, Won CH, et al. Metastatic cutaneous duodenal gastrointestinal stromal tumor: a possible clue to multiple metastases. *Ann Dermatol* 2018;30:345–7.
- Ding J, Sun P, Cai XY, et al. Synchronous poorly-differentiated neuroendocrine carcinoma and gastrointestinal stromal tumor of the stomach: a case report with immunohistochemical and molecular genetic analyses of KIT and PDGFRA. *Int J Clin Exp Pathol* 2014;7:9076–80.
- Samaras VD, Foukas PG, Triantafyllou K, et al. Synchronous well differentiated neuroendocrine tumour and gastrointestinal stromal tumour of the stomach: a case report. *BMC Gastroenterol* 2011;11:27.
- Suresh PK, Sahu KK, Pai RR, et al. The prognostic significance of neuroendocrine differentiation in colorectal carcinomas: our experience. *J Clin Diagn Res* 2015;9: EC01–EC04.
- Yang X, Jiang J, Dong X, et al. Correlations between computed tomography and positron emission tomography/computed tomography findings and pathology in 6 cases of pulmonary epithelioid angiosarcoma. *Medicine (Baltimore)* 2018;97:e12107.
- Yang DY, Wang X, Yuan WJ, et al. Metastatic pattern and prognosis of gastrointestinal stromal tumor (GIST): a SEER-based analysis. *Clin Transl Oncol* 2019;21:1654–62.
- Chaudhuri T, Suresh Babu MC, Babu K, et al. Metastatic gastrointestinal stromal tumor: a regional cancer center experience of 44 cases. *South Asian J Cancer* 2017;6:118–21.