









## PRELIMINARY REPORT

# EEG findings in acutely ill patients investigated for SARS-CoV-2/COVID-19: A small case series preliminary report

Aristea S. Galanopoulou<sup>1,2,3,4,5</sup>  | Victor Ferastraoaru<sup>2,3</sup>  | Daniel J. Correa<sup>2,3</sup>  |  
 Koshi Cherian<sup>1,2,3</sup> | Susan Duberstein<sup>1,2,3</sup> | Jonathan Gursky<sup>2,3</sup>  |  
 Rajani Hanumanthu<sup>2,3</sup> | Christine Hung<sup>2,3</sup> | Isaac Molinero<sup>1,2,3</sup>  |  
 Olga Khodakivska<sup>2,3</sup> | Alan D. Legatt<sup>2,3,5</sup> | Puja Patel<sup>1,2,3</sup>  | Jillian Rosengard<sup>2,3</sup> |  
 Elayna Rubens<sup>2,3</sup> | William Sugrue<sup>2,3</sup> | Elissa Yozawitz<sup>1,2,3</sup>  | Mark F. Mehler<sup>2,5,6</sup> |  
 Karen Ballaban-Gil<sup>1,2,3</sup> | Sheryl R. Haut<sup>2,3</sup> | Solomon L. Moshé<sup>1,2,3,4,5,7</sup>  | Alexis Boro<sup>2,3</sup>

<sup>1</sup>Isabelle Rapin Division of Child Neurology, Albert Einstein College of Medicine, Bronx, NY, USA

<sup>2</sup>Saul R. Korey Department of Neurology, Albert Einstein College of Medicine, Bronx, NY, USA

<sup>3</sup>Comprehensive Einstein/Montefiore Epilepsy Center, Albert Einstein College of Medicine, Bronx, NY, USA

<sup>4</sup>Laboratory of Developmental Epilepsy, Albert Einstein College of Medicine, Bronx, NY, USA

<sup>5</sup>Dominick P. Purpura Department of Neuroscience, Albert Einstein College of Medicine, Bronx, NY, USA

<sup>6</sup>Department of Psychiatry and Behavioral Sciences, Albert Einstein College of Medicine, Bronx, NY, USA

<sup>7</sup>Department of Pediatrics, Albert Einstein College of Medicine, Bronx, NY, USA

## Correspondence

Aristea S. Galanopoulou, Saul R. Korey Department of Neurology, Dominick P. Purpura Department of Neuroscience, Isabelle Rapin Division of Child Neurology, Albert Einstein College of Medicine, 1410 Pelham Parkway South, Kennedy Center Rm 306, Bronx NY 10461, USA.  
 Email: aristeia.galanopoulou@einsteinmed.org

## Abstract

**Objective:** Acute encephalopathy may occur in COVID-19-infected patients. We investigated whether medically indicated EEGs performed in acutely ill patients under investigation (PUIs) for COVID-19 report epileptiform abnormalities and whether these are more prevalent in COVID-19 positive than negative patients.

**Methods:** In this retrospective case series, adult COVID-19 inpatient PUIs underwent EEGs for acute encephalopathy and/or seizure-like events. PUIs had 8-channel headband EEGs (Ceribell; 20 COVID-19 positive, 6 COVID-19 negative); 2 more COVID-19 patients had routine EEGs. Overall, 26 Ceribell EEGs, 4 routine and 7 continuous EEG studies were reviewed. EEGs were interpreted by board-certified clinical neurophysiologists (n = 16). EEG findings were correlated with demographic data, clinical presentation and history, and medication usage. Fisher's exact test was used.

**Results:** We included 28 COVID-19 PUIs (30-83 years old), of whom 22 tested positive (63.6% males) and 6 tested negative (33.3% male). The most common indications for EEG, among COVID-19-positive vs COVID-19-negative patients, respectively, were new onset encephalopathy (68.2% vs 33.3%) and seizure-like events (14/22, 63.6%; 2/6, 33.3%), even among patients without prior history of seizures (11/17, 64.7%; 2/6, 33.3%). Sporadic epileptiform discharges (EDs) were present in 40.9% of COVID-19-positive and 16.7% of COVID-19-negative patients; frontal sharp waves were reported in 8/9 (88.9%) of COVID-19-positive patients with EDs and in 1/1 of COVID-19-negative patient with EDs. No electrographic seizures were captured, but 19/22 COVID-19-positive and 6/6 COVID-19-negative patients were given antiseizure medications and/or sedatives before the EEG.

This is an open access article under the terms of the Creative Commons Attribution-NonCommercial-NoDerivs License, which permits use and distribution in any medium, provided the original work is properly cited, the use is non-commercial and no modifications or adaptations are made.

© 2020 The Authors. *Epilepsia Open* published by Wiley Periodicals LLC on behalf of International League Against Epilepsy

**Funding information**

Eunice Kennedy Shriver National Institute of Child Health and Human Development, Grant/Award Number: U54HD090260; National Institute of Neurological Disorders and Stroke, Grant/Award Number: NS43209, R01 NS091519, R01 NS096144, R21 OD025320, R01 NS091170, U10 NS086531 and U54 NS100064; US Department of Defense, Grant/Award Number: W81XWH-18-1-0612

**Significance:** This is the first preliminary report of EDs in the EEG of acutely ill COVID-19-positive patients with encephalopathy or suspected clinical seizures. EDs are relatively common in this cohort and typically appear as frontal sharp waves. Further studies are needed to confirm these findings and evaluate the potential direct or indirect effects of COVID-19 on activating epileptic activity.

**KEYWORDS**

COVID-19, encephalopathy, epileptiform discharges, SARS-CoV-2, seizures

## 1 | INTRODUCTION

The global spread of severe acute respiratory syndrome coronavirus 2 (SARS-CoV-2) infections (COVID-19) and the grave prognosis in certain people who manifest more severe illness and rapid decline urges for the identification of early predictors of outcomes and progression as these predictors may lead to more effective interventions to improve chances for rapid recovery. While the initial reports of COVID-19 illness highlighted the respiratory decline, multi-system organ failure and resultant mortality, particularly in vulnerable populations, reports on neurological manifestations are currently emerging.<sup>1-7</sup> A report from China on 214 COVID-19 patients indicated that more severely affected COVID-19 patients were more likely to have neurological involvement (45.5% in severe vs 30.2% in less severe COVID-19-positive individuals), including acute cerebrovascular diseases (5.7% vs 0.8%), impaired consciousness (14.8% vs 2.4%) and skeletal muscle injury (19.3% vs 4.8%).<sup>1</sup> Additional neurological manifestations included epilepsy (0.5%), peripheral nervous system disorders and muscle injury.<sup>1</sup> In a retrospective study of 274 patients who were either deceased (n = 113) or recovered and discharged (n = 161), disorders of consciousness upon admission were far more prevalent among the deceased (22%) than the recovered patients (1%) and hypoxic encephalopathy was seen in 20% of the deceased.<sup>2</sup> Altered mental status, presenting with delirium or encephalopathy, is a recognized neurological manifestation among COVID-19 patients;<sup>8</sup> this may stem from the many metabolic derangements, cardiorespiratory disturbances, the ongoing viral infection and cytokine storm, or the coagulopathy that may be present in the acute phase of the illness. Whether and when direct transmission of the virus to the CNS and associated regional neurotropism may also contribute to this encephalopathy or other CNS neurological manifestations is unclear.

Our hospital network has been operating within the epicenter of the COVID-19 pandemic. Systematic testing for COVID-19 has been performed beginning in early March 2020 when the first cases were recognized in New York. To minimize healthcare personnel's exposure to high risk for COVID-19 transmission patients, we have utilized an 8-channel headband EEG system (8ch-EEG), Ceribell rapid response EEG that can

### Key Points

- Mental status changes prompting EEG evaluation of COVID-19-positive patients included new encephalopathy (68.2%) and poor recovery after discontinuing sedation (13.6%).
- Mental status changes prompting EEG evaluation of COVID-19-negative patients included new encephalopathy (33.3%) and altered mental status due to acute neurological insults (50%).
- Suspicion for new clinical seizures prompted EEG requests in 63.6% of COVID-19-positive and 33.3% of COVID-19-negative patients.
- Epileptiform discharges appear in 40.9% of COVID-19-positive patients who had medical indication for EEG with frontal sharp waves as the predominant pattern.
- Future studies need to establish whether COVID-19 infection increases the risk for epileptiform abnormalities and to investigate pathogenesis.

be quickly applied by personnel without having prior training as EEG technologists.<sup>9,10</sup> We report our first findings from medically indicated EEG studies, performed predominantly using 8ch-EEG, on admitted acutely ill COVID-19 PUIs. We found that a sizeable proportion of COVID-19-positive patients had suspicion for seizures and/or epileptiform discharges (EDs) in their EEG compared to COVID-19-negative patients, albeit these differences did not reach statistical significance. The findings are discussed in the context of clinical indication, respiratory status, prior medication and additional relevant history.

## 2 | METHODS

### 2.1 | Study design, inclusion and exclusion criteria

The study has been approved by the Montefiore Medical Center Institutional Review Board. This is a preliminary

retrospective case series review of EEG findings, mostly using 8ch-EEG, obtained on adult male and female patients who had been admitted to Montefiore Medical Center and its affiliated hospitals, had EEG studies performed between March 1st and April 15th of 2020 for medically indicated reasons and results were available in their electronic medical records. In addition to 8ch-EEG, a small number of other EEG studies [routine or continuous EEG (cEEG)] that were conducted on COVID-19-positive patients were also included (see Table 1). Only adults were included given that the Ceribell EEG was only utilized within adult intensive care units. We excluded EEG studies that were performed on patients who were either not tested for COVID-19 or their results were not available in the electronic medical records at the time of our data collection and analysis. These EEGs were interpreted by board-certified clinical neurophysiologists from the EEG Division of Montefiore Medical Center, using a standardized report template within the *Epic* electronic medical records system (Epic Systems Corporation, Verona, WI, USA). The results included in this study are based on these reports. For patients who had additional EEG studies (routine, cEEG), these results were also reviewed and documented. A suspicion for clinical seizure-like events was based on reports by the primary team or neurology consult of paroxysmal changes in the neurological state or behavior concerning for seizures that prompted the request for the EEG.

## 2.2 | Encephalopathy vs other mental status designations, seizure reports

Coding was done based on the impressions and diagnoses offered by the primary and consulting teams in the *Epic* reports. In Table 2, we utilized the following classification:

- “New encephalopathy” indicates report of new “confusion” or “delirium” or “encephalopathy” at time of hospitalization or prior to the EEG request.
- “Chronic encephalopathy” designation is used when the history of encephalopathy already existed with no clear change.
- “Altered mental status” designation was attributed to new neurological events, for example, intraparenchymal or subdural hematomas.
- “Poor responsiveness after sedation discontinuation” implies no appropriate improvement of mental status after sedation was stopped, per the primary team's assessment.
- “Seizure-like events” in Table 2 indicates motor seizure-like events or seizures or confusion resembling prior seizures, all of which were logged during the current admission.

## 2.3 | COVID-19 status determination

COVID-19 testing had been undertaken as clinically indicated and was due to the presence of symptoms suspicious for COVID-19. COVID-19 status was determined by SARS-CoV-2 virus real-time PCR detection in nasopharyngeal swabs, using FDA-approved assays: Abbott, Luminex Aries, Cepheid Xpert Xpress SARS-CoV-2, or Hologic Panther Fusion real-time RT-PCR SARS-CoV-2 assay.

## 2.4 | EEG studies

Ceribell rapid response EEGs (Ceribell) were done using a 10 electrode/ 8-channel system including Fp1, Fp2, F7, F8, T3, T4, T5, T6, O1, and O2 electrodes (referred to herein as “8ch-EEG”). Sampling rate was 250 Hz. EEGs were read using a bipolar montage. High pass and low pass filters were usually at 1 Hz (range 0.1-1 Hz) and 30 Hz (range 15-100 Hz), respectively. 8ch-EEGs were read using the EEG portal version 2.1.3. Routine and continuous videoEEGs were accomplished using the XLTEK EEG acquisition system (Natus Medical Inc) sampling at a 500 Hz frequency. During reading, high pass and low pass filters were usually at 1 Hz (range 0.05-5 Hz) and 70 Hz (range 5-100 Hz), respectively.

## 2.5 | Statistics

Fisher's exact test was used to evaluate statistical significance. Statistical significance was set at .05. JMP 10.0.0 software was used for statistics (SAS Institute Inc). Results of continuous variables are presented as both means or medians  $\pm$  standard deviation (SD) (Table 1).

## 3 | RESULTS

### 3.1 | Study population and COVID-19 status among inpatients evaluated with 8ch-EEGs

We identified 40 8ch-EEGs studies undertaken during this period, and 2 routine EEG studies of another two COVID-19-positive patients were added (Table 1). Seven of the patients evaluated with 8ch-EEGs also had additional EEG studies (routine or cEEG), which were also reviewed and compared with the 8ch-EEGs reports. From the 40 8ch-EEGs, 13 were excluded because there was no COVID-19 testing done (32.5%), to avoid including patients with different clinical presentation that could confound the results. From the 27 remaining studies, one study was excluded as there was no COVID-19 results yet available at the time of the study analysis. Among the 26 COVID-19 PUIs who underwent

**TABLE 1** Cohort characteristics and EEG findings in acutely ill COVID-19 PUIs

Characteristics	COVID-19 Positive	COVID-19 Negative	P value
<i>Cohort characteristics</i>			
Number of patients with EEGs (n)	22	6	
Patients with 8ch-EEG [n, (% of total 8ch-EEGs)]	20/ 26 (76.9%)	6/26 (23.1%)	
Age (y)			
Mean $\pm$ SD	63.23 $\pm$ 11.9 (30-83)	57.6 $\pm$ 21.6 (30-76)	.1951
Median	64	64	
Gender [M/total, %M]	14/22 (63.6%)	2/6 (33.3%)	.3541
Past medical history			
Prior epilepsy	4/22 (18.2%)	0/6 (0%)	.5487
On ASM	2/4 (50%)	0/0	1
Prior neurological disorders, except epilepsy	7/22 (31.8%)	2/6 (33.3%)	1
Prior psychiatric disorders history	5/22 (22.7%)	3/6 (50%)	.3107
Clinical indication for EEG			
R/o NCSE, altered mental status	20/22 (90.9%)	6/6 (100%)	1
Motor Sz-like events or Sz at presentation or confusion resembling prior seizures	12/22 (54.5%)	1/6 (16.7%)	.1727
Confusion at presentation, no prior seizures	1/22 (4.5%)	0/6 (0%)	1
Gaze deviation	2/22 (9.1%)	1/6 (16.7%)	.5299
Respiratory status (day of EEG study)			
Acute respiratory failure, hypoxic	21/22 (95.5%)	6/6 (100%)	1
Unremarkable (only sore throat)	1/22 (4.5%)	0/6 (0%)	1
Intubated	14/22 (63.6%)	6/6 (100%)	.1412
Nasal cannula/ high flow nasal cannula/ nonrebreather mask	7/22 (31.8%)	0/6 (0%)	.2883
Renal insufficiency or liver dysfunction			
Renal insufficiency (Creatinine > 1.5 mg/dL)	10/22 (45.5%)	2/6 (33.3%)	.673
Normal renal function	12/22 (54.5%)	4/6 (66.7%)	
Liver dysfunction (abnormal transaminases)	17/22 (77.3%)	4/6 (66.7%)	.6219
Normal liver function	5/22 (22.7%)	2/6 (33.3%)	
Neuroimaging: new findings			
Positive infectious workup (other than COVID-19)	5/21 (23.8%)	5/6 (83.3%)	<b>.0152</b>
Positive blood cultures	0/21 (0%)	4/6 (66.7%)	<b>.0009</b>
Positive respiratory cultures (1 patient did not have cultures)	5/21 (23.8%)	2/6 (33.3%)	.6334
Suspicion of clinical seizure-like events			
Among patients with prior epilepsy	3/4 (75%)	0/0	
Among patients without prior epilepsy (1 patient's history of epilepsy was unknown)	11/17 (64.7%)	2/6 (33.3%)	.3413
Medications in the hospital			
Sedatives	14/22 (63.6%)	5/6 (66.7%)	1
ASM	12/22 (54.5%)	4/6 (66.7%)	.673
Sedatives or ASM	19/22 (86.4%)	6/6 (100%)	1
ASM in patients with prior epilepsy	4/4 (100%)	0/0	
ASM in patients with no prior epilepsy	8/18 (44.4%)	4/6 (66.7%)	.6404

(Continues)

TABLE 1 (Continued)

Characteristics	COVID-19 Positive	COVID-19 Negative	P value
<i>EEG findings</i>			
Types of EEGs <sup>a</sup>			
8ch-EEG (n)	20	6	
Routine EEG (n)	4	0	
cEEG (n)	7	0	
Duration of 8ch-EEGs (min/study)			
Mean ± SD	190.9 ± 149.3	375.8 ± 180.6	<b>.0224</b>
Median	164.5	297.5	
Background abnormal			
Bilateral slowing	22/22 (100%)	6/6 (100%)	1
Focal slowing	5/22 (22.7%)	2/6 (33.3%)	.6219
Symmetric	18/22 (81.8%)	4/6 (66.7%)	.6452
PDR absent	18/22 (81.8%)	5/6 (83.3%)	1
PDR slow	4/22 (18.2%)	1/6 (16.7%)	1
No AP gradient	17/22 (77.3%)	5/6 (83.3%)	1
Asymmetric	3/22 (13.6%)	2/6 (33.3%)	.2855
Discontinuous or burst suppression	1/22 (4.5%)	1/6 (16.7%)	.3889
Sporadic epileptic abnormalities			
Frontal, sharp waves	8/22 (36.4%)	1/6 (16.7%)	.6296
Bilateral, symmetric or asymmetric	6/8 (75%)	1/1 (100%)	1
Focal, unilateral	2/8 (25%)	0/1 (0%)	1
Temporal or hemispheric, left sharp waves <sup>b</sup>	2/22 (9.1%)	0/6 (0%)	1
Frontal sharp waves among patients with EDs	8/9 (88.9%)	1/1 (100%)	1
Sporadic EDs present			
In patients with sedatives	6/14 (42.9%)	1/5 (20%)	.6027
In patients with ASM	6/12 (50%)	1/4 (25%)	.5846
In patients with either sedative or ASM	9/18 (50%)	1/6 (16.7%)	.3408
In patients with neither sedative or ASM	0/4 (0%)	0/0	1
Sporadic EDs present			
In patients with prior seizure history	2/4 (50%)	0/0	1
In patients without prior seizure history	7/18 (38.9%)	1/6 (16.7%)	.6214
In patients presenting with clinical suspicion/evidence of seizures	4/14 (28.6%)	0/2 (0%)	1
Sporadic EDs present			
In patients with renal insufficiency	3/10 (30%)	1/2	1
In patients without renal insufficiency	6/12 (50%) <sup>c</sup>	0/4	.2335
In patients with hepatic dysfunction	7/17 (29.2%)	0/4	.2550
In patients without hepatic dysfunction	2/5 (40%) <sup>d</sup>	1/2	1
Sporadic EDs present			
In male patients	4/14 (28.6%)	1/2 (50%)	.1870
In female patients	5/8 (62.5%) <sup>e</sup>	0/4 (0%)	.0808
Periodic, rhythmic discharges			
Generalized or frontal rhythmic delta	3/22 (13.6%)	1/6 (16.7%)	1
Bifrontal sharply contoured periodic waves	1/22 (4.5%)	0/6 (0%)	1
Lateralized rhythmic delta, Left, temporal	1/22 (4.5%)	0/6 (0%)	1

(Continues)



TABLE 1 (Continued)

Characteristics	COVID-19 Positive	COVID-19 Negative	P value
Seizures, electrographic			
Present	0/22 (0%)	0/6 (0%)	1
Suspicion of clinical seizures and/or presence of EDs	17/22 (77.3%)	3/6 (50%)	.3107
In male patients	11/14 (78.6%)	2/2 (100%)	1
In female patients	6/8 (75%)	1/4 (25%)	.2222

Note: Statistical comparisons were done with 2-tail Fisher's exact test,  $\alpha = 0.05$ . Bold *P*-values are statistically significant.

Abbreviations: 8ch-EEG, 8 channel EEG; AP gradient, anteroposterior gradient; ASM, antiseizure medication; cEEG, continuous EEG, usually 1-2 d duration; EDs, epileptiform discharges; F, female; M, male; NCSE, nonconvulsive status epilepticus; PDR, posterior dominant rhythm; SD, standard deviation; Sz, seizure.

<sup>a</sup>One patient had only routine EEG done. Four patients had more than one study done (cEEG or routine EEG) in addition to 8ch-EEG. The results were usually concordant with the 8ch-EEG. Sporadic epileptiform discharges were seen in two of these patients, detected at the 8ch-EEG study as well as the routine or cEEG study.

<sup>b</sup>One patient had frontal sharp waves in the cEEG study and left hemispheric sharp waves in the 8ch-EEG study.

<sup>c</sup>*P* = .4149, Fisher's exact test (EDs in patients with vs without renal insufficiency).

<sup>d</sup>*P* = 1, Fisher's exact test (EDs in patients with vs without hepatic dysfunction).

<sup>e</sup>*P* = .1870 Fisher's exact test (EDs in COVID-19-positive male vs female patients).

8ch-EEGs with documented results, 20/26 (76.9%) were COVID-19 positive and 6/26 (23.1%) were COVID-19 negative.

### 3.2 | Patient characteristics

Comparison of COVID-19 positive with negative cohorts did not show statistically significant differences in age (Table 1), intubation status, prior history of epilepsy or neurological or psychiatric disorders. Most of the patients had acute respiratory failure, were intubated at the time of the EEG studies (63.6% vs 100%), and were receiving sedatives and/or antiseizure medications (ASMs) (86.4% vs 100%) (COVID-19 positive vs negative, respectively). The prevalences of renal or hepatic insufficiency were similar in the two cohorts.

Among COVID-19-positive patients, 5/21 (23.8%) showed positive bacterial cultures in sputum ( $n = 5$ ), whereas in COVID-19-negative patients, 5/6 (83.3%) had positive cultures in either blood ( $n = 4$ ) and/or sputum ( $n = 2$ , bacterial) ( $P = .0152$ ). One COVID-19-positive patient did not have cultures done. A significant difference was seen in prevalence of positive blood cultures among COVID-19 negative patients (4/6, 66.7% vs COVID-19 positive (0/21, 0%) ( $P = .0009$ ). COVID-19-negative patients had bacteremia ( $n = 3$ ) or fungemia/viremia ( $n = 1$ ). Neuroimaging revealed new findings in 3/13 (23.1%) COVID-19-positive patients as opposed to 6/6 (100%) of COVID-19-negative ( $P = .2262$ ). In COVID-19-positive patients, new findings included subcortical and mild periventricular white matter signal hyperintensity (1 MRI), subarachnoid hemorrhage due to aneurysm ( $n = 1$ ), and subdural hematoma ( $n = 1$ ). In COVID-19-negative patients, new findings included subdural ( $n = 2$ ), subarachnoid ( $n = 1$ ), thalamic ( $n = 1$ ) hematomas, acute infarct at

peritrial white matter and splenium of corpus callosum ( $n = 1$ ) and evidence of subacute hypoxic ischemic encephalopathy or infectious vasculopathy ( $n = 1$ ).

### 3.3 | Clinical indication for EEG studies

EEGs were requested to evaluate for altered mental status and/or rule out nonconvulsive status epilepticus (90.9% vs 100%) (COVID-19 positive vs negative, respectively). Encephalopathy or mental status change was a leading cause of EEG requests (Table 2). Many patients were intubated or sedated, rendering mental status assessment for encephalopathy challenging. As shown in Table 2, new encephalopathy tended to be more common in COVID-19-positive (15/22, 68.2%) than in COVID-19-negative patients (2/6, 33.3%) ( $P = .1741$ , Fisher's exact test).

Clinical concern for seizure-like events was reported in 14/22 COVID-19-positive (63.6%) and 2/6 COVID-19-negative patients (2/6, 33.3%). In COVID-19-positive patients, these episodes included new gaze deviation ( $n = 2$ ), and 12 with reports of motor seizure-like events which were described as: myoclonic seizures ( $n = 3$ ), "abnormal tremulous movements concerning for seizure" ( $n = 1$ ), motor seizures ( $n = 5$ ), confusional events reminiscent of prior seizures ( $n = 1$ ), "abnormal movements," or "shaking movements" concerning for seizures ( $n = 2$ ). New events with gaze deviation concerning for seizure ( $n = 1$ ) or seizure at home ( $n = 1$ ) were described in two COVID-19-negative patients. Overall, the trend for more clinical seizure-like events in COVID-19-positive than in COVID-19-negative patients was independent of a prior history of epilepsy (see Table 1) and was also noted among COVID-19-positive patients with new onset encephalopathy (5/15, 33.3%) compared with COVID-19-negative (0/2, 0%) patients (Table 2).

**TABLE 2** Indications for EEG studies

Mental status	Total		With seizure-like events		Without seizure-like events		Other (gaze deviation)	
	Intubated (n = 14)	Not intubated (n = 8)	With seizure-like events	Without seizure-like events	With seizure-like events	Without seizure-like events	Other (gaze deviation)	Other (gaze deviation)
<b>COVID-19 positive (n = 22)</b>								
Encephalopathy, new	4 (18.2%) <sup>a</sup>	2 (9.1%)	1 (4.5%)	1 (4.5%)	4 (18.2%)	3 (13.6%)	1 (4.5%)	1 (4.5%)
Poor responsiveness after stopping sedation	1 (4.5%)	2 (9.1%)	0 (0%)	0 (0%)	0	0	0	0
Altered mental status, other	0 (0%)	0	0	0	0	0	0	0
Unclear								
Sedated	2 (13.6%)	1 (4.5%)	0	0	0	0	0	0
Chronic encephalopathy	1 (4.5%)	0 (0%)	0	0	0	0	0	0
None reported	0 (0%)	0	0	0	0	0	0	0
<b>Total</b>	<b>8 (36.4%)</b>	<b>5 (22.7%)</b>	<b>1 (4.5%)</b>	<b>1 (4.5%)</b>	<b>4 (18.2%)</b>	<b>3 (13.6%)</b>	<b>1 (4.5%)</b>	<b>1 (4.5%)</b>
<b>Intubated (n = 6)</b>								
<b>COVID-19 negative (n = 6)</b>								
Encephalopathy, new	2 (33.3%)	0	0	0	0	0	2 (33.3%)	0
Poor responsiveness after stopping sedation	0 (0%)	0	0	0	0	0	0	0
Altered mental status, other	3 (50%)	1 (16.7%)	0	0	1 (16.7%)	0	1 (16.7%)	0
Unclear	0 (0%)	0	0	0	0	0	0	0
Sedated								
Chronic encephalopathy								
None reported	1 (16.7%)	1 (16.7%)	0	0	0	0	0	0
<b>Total</b>	<b>6</b>	<b>2 (33.3%)</b>	<b>3 (50%)</b>	<b>1 (16.7%)</b>	<b>1 (16.7%)</b>	<b>0</b>	<b>3 (50%)</b>	<b>0</b>
<b>Not intubated (n = 0)</b>								

*Note:* Breakdown of reasons for EEG request by intubation status, evidence of seizure-like events during the admission is presented in this table. Total numbers and percentages per category are shown in bold font.

<sup>a</sup>Typical indication for EEG studies was “rule out nonconvulsive status epilepticus” for all studies, except for one patient who had EEG done because of abnormal movements suspicious for seizures and delirium. “Seizure-like events” indicates motor seizure-like events or seizures at presentation or confusion resembling prior seizures; such events were reported during the hospital admission. “New encephalopathy” indicates report of new confusion or delirium or “encephalopathy” at time of hospitalization or prior to EEG request. “Chronic encephalopathy” designation is used when history of encephalopathy exists with no clear change. “Altered mental status” designation was attributed to new neurological events, eg, intraparenchymal or subdural hematomas). “Poor responsiveness after stopping sedation” implies no appropriate improvement of mental status after sedation is stopped, per primary team’s assessment.

<sup>b</sup>P = .1741, report of new encephalopathy in COVID-19-positive vs COVID-19-negative patients, Fisher’s exact test.

### 3.4 | Medications during EEG study

Most patients were on either sedatives or antiseizure medications (ASMs) in both cohorts, including almost half of the patients without a prior epilepsy history (Table 1).

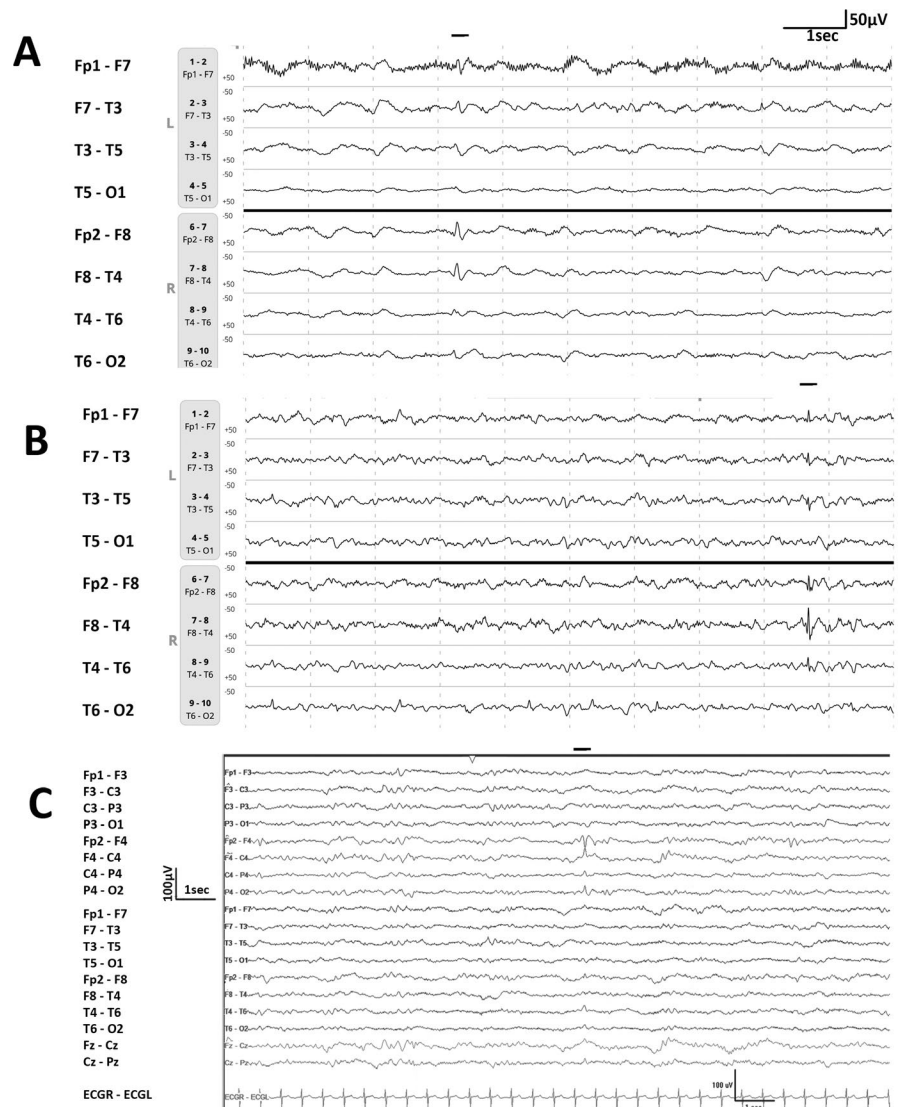
### 3.5 | EEG findings

EEGs were uniformly abnormal with a slow and disorganized background, usually symmetric but no electrographic seizures were recorded (Table 1, Figure 1). However, 9/22 (40.9%) COVID-19-positive patients had sporadic EDs, reported as frontal sharp waves in 8/9 patients (88.9%). The frontal sharp waves were bilateral and symmetric in 3/8, bilateral asymmetric in 5/8 and unilateral in 2/8. Left temporal sharp waves were seen in one COVID-19-positive patient with prior history of epilepsy. EDs were reported in only one COVID-19 negative patient with bilateral asymmetric frontal

sharp waves and triphasic waves. Generalized rhythmic delta slowing, maximal frontal, was seen in 3/22 and intermittent left temporal rhythmic delta in 1/22 COVID-19-positive patients, respectively. In COVID-19-negative patients, 1/6 had generalized rhythmic delta slowing. No electrographic seizures were captured.

Overall, COVID-19-positive patients tended to have more sporadic EDs than COVID-19-negative, even if exposure to sedatives or ASMs or prior history of epilepsy was taken into consideration (Table 1). Renal insufficiency or hepatic dysfunction was common in both patients with and without EDs. However, many patients with suspicion of clinical seizure-like events were placed on ASMs prior to EEG, which may have reduced the likelihood of detecting epileptiform discharges. The rates of patients who had either suspicion for clinical seizure-like events or EDs in their EEG were not significantly different between COVID-19-positive (77.3%) and COVID-19-negative (50%) patients ( $P = .3107$ ).

**FIGURE 1** Examples of frontal sharp waves or spikes in EEGs of COVID-19-positive patients and encephalopathy. (A,B) Examples of 8ch-EEG from a 65 y old man with no prior history of epilepsy presenting with delirium (A) and a 77 y old woman with history of epilepsy presenting with an episode of confusion, reminiscent of her old seizures (B). The prior epilepsy classification is unknown for this patient whose prior medical care was outside our hospital network. EEGs demonstrate frontal sharp waves bilateral (A) or frontal spikes right more than left (B). High pass filter 1 Hz, low pass filter 30 Hz. (C) Routine EEG of a 61 y old man with no prior history of epilepsy, who presented with fever, respiratory failure requiring intubation who manifested “20 second intervals of bilateral arm jerking with eyes rolling back” and “myoclonic seizure activity at the face and left arm” after taken off propofol. His EEG showed right frontal sharp waves. High pass filter 1 Hz, low pass filter 70 Hz. Scale bars indicate sensitivity and timescale. Horizontal bars indicate the times when epileptic activities are seen. ECGR-ECGL: electrocardiogram channel





## 4 | DISCUSSION

We present the first preliminary case series report of EEG findings in patients under investigation for COVID-19 who presented with altered mental status, encephalopathy or suspicion for seizures and demonstrates evidence of EDs. Seizure-like behaviors prompting EEG investigation were common (63.6%) in COVID-19-positive patients and sporadic epileptic abnormalities were seen in 40.9%, predominantly in the form of frontal sharp waves. The sporadic EDs did not appear to correlate with the presence of renal insufficiency or hepatic dysfunction or the use of sedatives and ASMs. We did not see electrographic seizures in this cohort, possibly because patients had already been started on ASMs before the study. A single case report of COVID-19 encephalopathy with left temporal EDs ipsilateral to an old encephalomalacia has been recently reported,<sup>11</sup> while in a group of 8 COVID-19 patients with encephalopathy, EEGs showed slowing without EDs.<sup>8</sup>

Frontal sharp waves, bilateral symmetric or asymmetric, were the predominant ED pattern, suggesting a frontal epileptogenic focus or dysfunction. It is intriguing that the frontal focus suggested in our study may be consistent with the idea of entry into the brain through the nasopharyngeal mucosa or via the olfactory nerves. The rapid clinical decline of certain COVID-19 infected patients is multifactorial. It has been recently proposed that the neuroinvasive potential of the virus may also contribute by invading the central nervous system (CNS), such as brainstem, leading to the rapid respiratory decline of certain patients.<sup>4</sup> In support of the CNS invasion potential of the virus, intranasally delivered SARS-CoV or Middle East Respiratory Viral syndrome coronavirus (MERS-CoV) viruses can enter the mouse brain possibly via transsynaptic transfer through the olfactory nerves<sup>12,13</sup> or through the hematogenous route. SARS-CoV may subsequently spread to other brain regions, including brainstem, thalamus, or limbic regions.<sup>13</sup> The olfactory or taste deficits in the early stages of COVID-19 have triggered the speculation that peripheral sensory nerves are the points of entry and subsequent transsynaptic transfer to the brain. However, ageusia or anosmia may not be necessarily followed by neurological decline. Hematogenous transmission is another route of possible viral entry into the brain that has been proposed for similar viruses, potentially rendering patients with blood brain barrier disruption more vulnerable.<sup>14</sup>

In humans, COVID-19 virus has very rarely been detected by PCR in the cerebrospinal fluid (CSF).<sup>3,15</sup> The poor availability of COVID-19 CSF testing so far and the efforts to minimize unnecessary exposure of healthcare personnel to COVID-19 has limited lumbar punctures to patients with increased clinical suspicion of meningoencephalitis. There are anecdotal reports of two patients with meningitis/encephalitis, one of whom had seizures, who tested COVID-19 positive

in their CSF.<sup>3,5</sup> Furthermore, a 24-year-old man presenting with seizures, meningoencephalitis, and abnormal hippocampal MRI signal also had COVID-19-positive CSF, even though his nasopharyngeal swab had been negative.<sup>15</sup> Yet, in 7 COVID-19-positive patients with encephalopathy, CSF was negative for COVID-19.<sup>8</sup> It is currently unclear which factors render certain COVID-19-positive patients susceptible to CNS viral transmission, and if less invasive tests than CSF studies might identify early biomarkers predicting such adverse outcomes.

CNS viral infections as well as activation of neuroinflammatory pathways are known to lower the threshold for seizures and potentially facilitate epileptogenesis in certain individuals.<sup>16,17</sup> Seizures have been reported in other viral encephalitides with variable prevalence depending on the virus.<sup>18</sup> Case reports of NCSE or seizures have been reported in MERS infections,<sup>19,20</sup> Influenza A H1N1 infection-related altered mental status,<sup>21–25</sup> and Influenza A H3N2 encephalitis.<sup>26</sup> EEG findings were predominantly background slowing occasionally with variable or unclear localization of epileptic activities. Similar to the rare case reports of CSF findings in COVID-19 infected patients with seizures,<sup>15,27,28</sup> CSF abnormalities are not always seen in patients with viral encephalitides and seizures even if the virus is detected,<sup>3,24</sup> alerting the medical community that CSF testing for COVID-19 should be considered if clinically suspected.

However, the multiple metabolic and electrolytic abnormalities and ongoing hypoxic, inflammatory/infectious processes may also contribute to the abnormal EEG background. In our study, the presence of EDs was not significantly different between patients with or without renal or hepatic dysfunction. Most of our COVID-19-positive patients had abnormalities in inflammatory markers peripherally or signs of coagulopathy and we therefore cannot exclude that these may have played a pivotal role in activating the EEG. While sharp waves are not always epileptogenic, the relatively high prevalence of clinical seizure-like events at presentation and/or epileptiform EEGs specifically in the COVID-19-positive cohort may suggest a pathogenic role of COVID-19 virus in triggering these potentially epileptiform events. Whether this is a result of direct insult of the virus within the CNS, indirect consequence of the complex systemic effects of the virus, or both needs further investigation. Our study suggests the importance of investigating patients with COVID-19 encephalopathy with EEG studies, when medically safe and indicated. However, both the potential clinical benefit as well as the increased risk of exposure of the EEG technologists to the virus need to be considered. In our center, the 8ch-EEG offered an opportunity to perform such studies while minimizing healthcare personnel's exposure to COVID-19.

We attempted a comparison with COVID-19 negative patients who would have been more likely to have similar clinical presentation and EEG indications as the COVID-19-positive

patients. Unfortunately, due to the high prevalence of COVID-19 in our region, the majority of COVID-19 PUIs tested positive, limiting the number of COVID-19 negative patients. As a result, our study was not powered to confirm statistical significance among COVID-19 PUI subcohorts in the rates of EDs or clinical seizure-like events. Larger studies are needed to confirm whether such differences are preferentially associated with COVID-19 infection or are a more general trait of encephalopathy in the setting of viral infections.

Limitations of our study include the small sample size, as discussed previously. While 8ch-EEGs provide a rapid and easy method of EEG monitoring,<sup>9,10</sup> the electrode coverage includes 8 bipolar channels (frontal, temporal, occipital), limiting the capacity to fully localize and characterize certain waveforms. In our study, two patients with EDs detected by the 8ch-EEG also had routine and/or cEEG studies that confirmed the presence of EDs. We intentionally compared COVID-positive with COVID-negative patients, because of their similar clinical presentations. COVID-19 negative tests by nasopharyngeal swab have sometimes been reported in patients who eventually tested positive in their CSF.<sup>15</sup> Furthermore, there is a concern that many RT-PCR assays for COVID-19 carry a high false negative rate.<sup>29,30</sup> Consequently, these may have created a negative bias reducing the power of detection of cohort differences in our study. However, 5/6 COVID-19 negative patients had bacteremia or viremia and/or pneumonia from other confirmed causes that could explain their course. Finally, the EEG findings were based on the reports of multiple independent board-certified EEG readers. In some – but not all – cases, COVID-19 status was already known at the time of reading and therefore assessment was unblinded. However, the fact that there has not been any prior report on EEG findings in COVID-19-positive patients, except for a single case report,<sup>11</sup> reduces the possibility of bias in the EEG interpretation. A prospective large scale study utilizing a more uniform and structured method of EEG scoring as well as subsequent follow up with the classical routine or cEEG to confirm these findings is needed.

Despite these limitations, we believe that this first case series of COVID-19-positive patients with encephalopathy investigated with EEG will be valuable in the clinical management and understanding of the pathophysiology of COVID-19 acute encephalopathy. We offer a first view on a candidate EEG biomarker of COVID-19 acute encephalopathy, frontal sharp waves, that could potentially herald the onset of new epileptic dysfunction. Long-term follow up of these patients as well as larger, powered and adequately controlled studies to validate our findings, test the specific effect of COVID-19, as well as elucidate the pathogenic mechanisms are needed.

## ACKNOWLEDGMENTS

AS Galanopoulou acknowledges grant support by NINDS RO1 NS091170, U54 NS100064, the US Department of Defense

(W81XWH-18-1-0612), NICHD U54HD090260, and research funding from the Heffer Family and the Segal Family Foundations and the Abbe Goldstein/Joshua Lurie and Laurie Marsh/Dan Levitz families. DJ Correa is supported in part by the NIH 1U54NS100064 grant. MF Mehler is the Alpern Family Foundation Chair in Developmental Neuroscience and partially funded by grants from the NIH (R01NS096144, R21OD025320, R01NS091519 and U10NS086531). SL Moshé is the Charles Frost Chair in Neurosurgery and Neurology and partially funded by grants from NIH U54 NS100064 and NS43209, US Department of Defense (W81XWH-18-1-0612), the Heffer Family and the Segal Family Foundations, and the Abbe Goldstein/Joshua Lurie and Laurie Marsh/Dan Levitz families. The authors wish to acknowledge with gratitude the staff of the EEG Department for their excellent technical expertise and dedication to patients' care in performing these studies during the COVID-19 pandemic.

## CONFLICT OF INTEREST

AS Galanopoulou is co-Editor in Chief of *Epilepsia Open* and has received royalties for publications from Elsevier and Morgan & Claypool publishers. AD Legatt serves on the editorial board of *Journal of Clinical Neurophysiology* and has received royalties for a publication from Springer Publishing. He has received consultant's fees from Brain Sentinel. SR Haut serves on the editorial board of *Epilepsy and Behavior*. SL Moshé is serving as Associate Editor of *Neurobiology of Disease* and is on the editorial board of *Brain and Development*, *Pediatric Neurology and Physiological Research*. He receives from Elsevier an annual compensation for his work as Associate Editor in *Neurobiology of Disease* and royalties from two books he co-edited. He has received consultant's fees from UCB and Pfizer. AB Boro is site PI for clinical trials sponsored clinical trials sponsored by Biogen, SK Life Science, Neurelis and UCB. He receives no salary support or other reimbursement for these projects. All funds go to the institution. None of the other authors have conflicts to disclose. We confirm that we have read the Journal's position on issues involved in ethical publication and affirm that this report is consistent with those guidelines. We confirm that we have read the Journal's position on issues involved in ethical publication and affirm that this report is consistent with those guidelines.

## ORCID

Aristea S. Galanopoulou  <https://orcid.org/0000-0002-0472-2903>

Victor Ferastraoararu  <https://orcid.org/0000-0003-4180-3558>

Daniel J. Correa  <https://orcid.org/0000-0002-6490-9331>

Jonathan Gursky  <https://orcid.org/0000-0002-1632-6107>

Isaac Molinero  <https://orcid.org/0000-0003-1595-546X>

Puja Patel  <https://orcid.org/0000-0002-5895-3926>

Elissa Yozawitz  <https://orcid.org/0000-0001-8230-8364>

Solomon L. Moshé  <https://orcid.org/0000-0001-9427-9476>

## REFERENCES

1. Mao L, Wang M, Chen S, Hu Y, Chen S, He Q, et al. Neurological manifestations of hospitalized patients with COVID-19 in Wuhan, China: a retrospective case series study. *JAMA Neurol.* 2020. in press. <https://doi.org/10.1101/2020.02.22.20026500>
2. Chen T, Wu DI, Chen H, Yan W, Yang D, Chen G, et al. Clinical characteristics of 113 deceased patients with coronavirus disease 2019: retrospective study. *BMJ.* 2020;368:m1091.
3. Li Y, Bai WZ, Hashikawa T. Response to Commentary on: "The neuroinvasive potential of SARS-CoV-2 may play a role in the respiratory failure of COVID-19 patients". *J Med Virol.* 2020. in press.
4. Li YC, Bai WZ, Hashikawa T. The neuroinvasive potential of SARS-CoV2 may play a role in the respiratory failure of COVID-19 patients. *J Med Virol.* 2020. in press.
5. Zhou L, Zhang M, Wang J, Gao J. Sars-Cov-2: Underestimated damage to nervous system. *Travel Med Infect Dis.* 2020;101642. in press.
6. Poyiadji N, Shahin G, Noujaim D, Stone M, Patel S, Griffith B. COVID-19-associated acute hemorrhagic necrotizing encephalopathy: CT and MRI features. *Radiology.* 2020;201187. in press.
7. Nataf S. An alteration of the dopamine synthetic pathway is possibly involved in the pathophysiology of COVID-19. *J Med Virol.* 2020. in press.
8. Helms J, Kremer S, Merdji H, Clere-Jehl R, Schenck M, Kummerlen C, et al. Neurologic features in severe SARS-CoV-2 infection. *N Engl J Med.* 2020. in press.
9. Yazbeck M, Sra P, Parvizi J. Rapid response electroencephalography for urgent evaluation of patients in community hospital intensive care practice. *J Neurosci Nurs.* 2019;51:308–12.
10. Kamousi B, Grant AM, Bachelder B, Yi J, Hajinorozi M, Woo R. Comparing the quality of signals recorded with a rapid response EEG and conventional clinical EEG systems. *Clin Neurophysiol Pract.* 2019;4:69–75.
11. Filatov A, Sharma P, Hindi F, Espinosa PS. Neurological Complications of Coronavirus Disease (COVID-19): encephalopathy. *Cureus.* 2020;12:e7352.
12. Li K, Wohlford-Lenane C, Perlman S, Zhao J, Jewell AK, Reznikov LR, et al. Middle east respiratory syndrome coronavirus causes multiple organ damage and lethal disease in mice transgenic for human dipeptidyl peptidase 4. *J Infect Dis.* 2016;213:712–22.
13. Netland J, Meyerholz DK, Moore S, Cassell M, Perlman S. Severe acute respiratory syndrome coronavirus infection causes neuronal death in the absence of encephalitis in mice transgenic for human ACE2. *J Virol.* 2008;82:7264–75.
14. Desforges M, Le Coupanec A, Stodola JK, Meessen-Pinard M, Talbot PJ. Human coronaviruses: viral and cellular factors involved in neuroinvasiveness and neuropathogenesis. *Virus Res.* 2014;194:145–58.
15. Moriguchi T, Harii N, Goto J, Harada D, Sugawara H, Takamino J, et al. A first case of meningitis/encephalitis associated with SARS-Coronavirus. *Int J Inf Dis.* 2020;94:55–8.
16. Wilcox KS, Vezzani A. Does brain inflammation mediate pathological outcomes in epilepsy? *Adv Exp Med Biol.* 2014;813:169–83.
17. Barker-Haliski ML, Loscher W, White HS. Neuroinflammation in epileptogenesis: Insights and translational perspectives from new models of epilepsy. *Epilepsia.* 2017;58(Suppl 3):39–47.
18. Misra UK, Tan CT, Kalita J. Viral encephalitis and epilepsy. *Epilepsia.* 2008;49(Suppl 6):13–8.
19. Mogi T, Toda H, Tatsuzawa Y, Fukutomi T, Soga S, Shinmoto H, et al. Clinically mild encephalopathy with a reversible splenial lesion and nonconvulsive status epilepticus in a schizophrenic patient with neuroleptic malignant syndrome. *Psychiatry Clin Neurosci.* 2017;71:212.
20. Chen W-X, Liu H-S, Yang S-D, Zeng S-H, Gao Y-Y, Du Z-H, et al. Reversible splenial lesion syndrome in children: retrospective study and summary of case series. *Brain Dev.* 2016;38:915–27.
21. Fujita K, Nagase H, Nakagawa T, Saji Y, Maruyama A, Uetani Y. Non-convulsive seizures in children with infection-related altered mental status. *Pediatr Int.* 2015;57:659–64.
22. Ibrahim F, Haddad N. New onset refractory status epilepticus in a young man with H1N1 infection. *Case Rep Neurol Med.* 2014;2014:585428.
23. Cunha BA, Fear GL, Chawla K. A rare case of influenza A in a hospitalized adult presenting with encephalitis and a seizure. *IDCases.* 2018;12:153–5.
24. Fuchigami T, Imai Y, Hasegawa M, Ishii W, Endo A, Arakawa C, et al. Acute encephalopathy with pandemic (H1N1) 2009 virus infection. *Pediatr Emerg Care.* 2012;28:998–1002.
25. Yeo L, Paliwal PR, Tambyah PA, Olszyna DP, Wilder-Smith E, Rathakrishnan R. Complex partial status epilepticus associated with adult H1N1 infection. *J Clin Neurosci.* 2012;19:1728–30.
26. Yuan H-T, Ho T-H, Lee J-T, Chen P-C, Wang C-W, Yang F-C. Simply influenza A (H3N2)-associated encephalitis with seizure. *Am J Emerg Med.* 2019;37(1808):1808.e1–1808.e3.
27. Li B, Shen J, Li L, Yu C. Radiographic and clinical features of children with 2019 novel coronavirus (COVID-19) Pneumonia. *Indian Pediatr.* 2020. in press.
28. Li C, Chen LJ, Chen X, Zhang M, Pang CP, Chen H. Retrospective analysis of the possibility of predicting the COVID-19 outbreak from Internet searches and social media data, China, 2020. *Euro Surveill.* 2020. <https://doi.org/10.2807/1560-7917.ES.2020.25.10.2000199>
29. Xiao AT, Tong YX, Zhang S. False-negative of RT-PCR and prolonged nucleic acid conversion in COVID-19: rather than recurrence. *J Med Virol.* 2020.
30. Li D, Wang D, Dong J, Wang N, Huang HE, Xu H. False-negative results of real-time reverse-transcriptase polymerase chain reaction for severe acute respiratory syndrome coronavirus 2: role of deep-learning-based CT diagnosis and insights from two cases. *Korean J Radiol.* 2020;21:505–8.

**How to cite this article:** Galanopoulou AS, Ferastraoaru V, Correa DJ, et al. EEG findings in acutely ill patients investigated for SARS-CoV-2/ COVID-19: A small case series preliminary report. *Epilepsia Open.* 2020;5:314–324. <https://doi.org/10.1002/epi4.12399>