

Collaborations Between Cardiology and Radiology on the Development of Clinical Programs (Cardiac Imaging)

Prashant Nagpal, MD

With increasing utilization of multimodality cardiac imaging, most cardiology and radiology groups (both academic or private practice) are undergoing structural and cultural changes. This growth in the field of cardiac imaging is the result of technological advancements and increased utilization of minimally invasive interventions.^{1,2} However, cardiac imaging is commonly regarded as a challenge among cardiologists and radiologists. The problem is evident by the fact that only a few successful and truly collaborative radiology-cardiology programs exist in the country. A review of advanced imaging training database of the American College of Cardiology³ shows that 48 institutions in the United States offer advanced cardiac imaging fellowship training. Many institutions offer more than 1 track (cardiac computed tomography, cardiac magnetic resonance imaging, echocardiography, nuclear cardiology, or research). Of these, only 24 mention having both cardiologists and radiologists as faculties under program description and only 4 enlist radiology trainees as eligible candidates.

One of the commonly perceived reasons for this failure to promote joint radiology-cardiology programs is the differences among individual personalities at their site. A few questions relevant in this context are: Is there a need for collaboration among Radiology and Cardiology for the future for advanced cardiovascular imaging?; Should cardiologists interpret the cardiac findings and radiologists report only extracardiac findings?; Should radiologists be the ones doing both cardiac and extracardiac reporting?; and Can we let

individual differences come in the way of overall improvement of the patients and patient care?

In my opinion, having trained by, having trained with, and having worked with a diverse cohort of excellent cardiac imagers (both from cardiology and radiology), there is no doubt that cardiology and radiology collaboration is needed at every step. Such partnership serves the patient, education, research, and advancement of the field. One of the biggest strengths of cardiac imaging is the diversity of physicians (radiology, cardiology, and pediatric cardiology) with pathways for advanced multimodality imaging,^{4,5} providing advanced subspecialty patient care. However, the diversity of the background and the difference of the training pathways lead to a feeling of lack of commonality among practitioners. This lack of commonality breeds a lack of cooperation, eventually leading to different members exerting control, which is commonly referred to as a “turf battle.”⁶ These turf battles harm patient care, collegiality, and job satisfaction. Although some excellent reviews have been written that highlight unique and complementary roles for radiologists and cardiologists,⁷ it is not uncommon to see social media posts by practicing cardiac imagers and hear experiences of cardiovascular imagers that highlight an underlying lack of commonality and collegiality as a group despite a similar level of advanced training.

Promoting commonality is vital for the future success of joint cardiovascular imaging. Various foundation steps can be taken at different levels—at a training level, at the level of an institution, and at the level of an individual (Figure). These foundations also constitute the ingredients of success of the programs that currently accomplish the goals of radiology and cardiology partnership. Leading organizations (like the American College of Radiology and American College of Cardiology) can play a significant role by unifying the training as well as diverse certification pathways and promoting a nationally uniform cardiac imaging fellowship with a joint curriculum. This training can be further strengthened by the Accreditation Council for Graduate Medical Education guidelines. Although the impact of Accreditation Council for Graduate Medical Education duty-hours restrictions is debated,⁸ the implementation of Accreditation Council for

The opinions expressed in this article are not necessarily those of the editors or of the American Heart Association.

From the Department of Radiology, Division of Cardiovascular and Thoracic Imaging, University of Iowa Hospitals and Clinics, Iowa City, IA.

Correspondence to: Prashant Nagpal, MD, Department of Radiology, Cardiovascular and Thoracic Imaging, University of Iowa Hospitals and Clinics, 200 Hawkins Dr, Iowa City, IA 52242. E-mail: prashant-nagpal@uiowa.edu
J Am Heart Assoc. 2019;8:e013660. DOI: 10.1161/JAHA.119.013660.

© 2019 The Author. Published on behalf of the American Heart Association, Inc., by Wiley. This is an open access article under the terms of the Creative Commons Attribution-NonCommercial License, which permits use, distribution and reproduction in any medium, provided the original work is properly cited and is not used for commercial purposes.

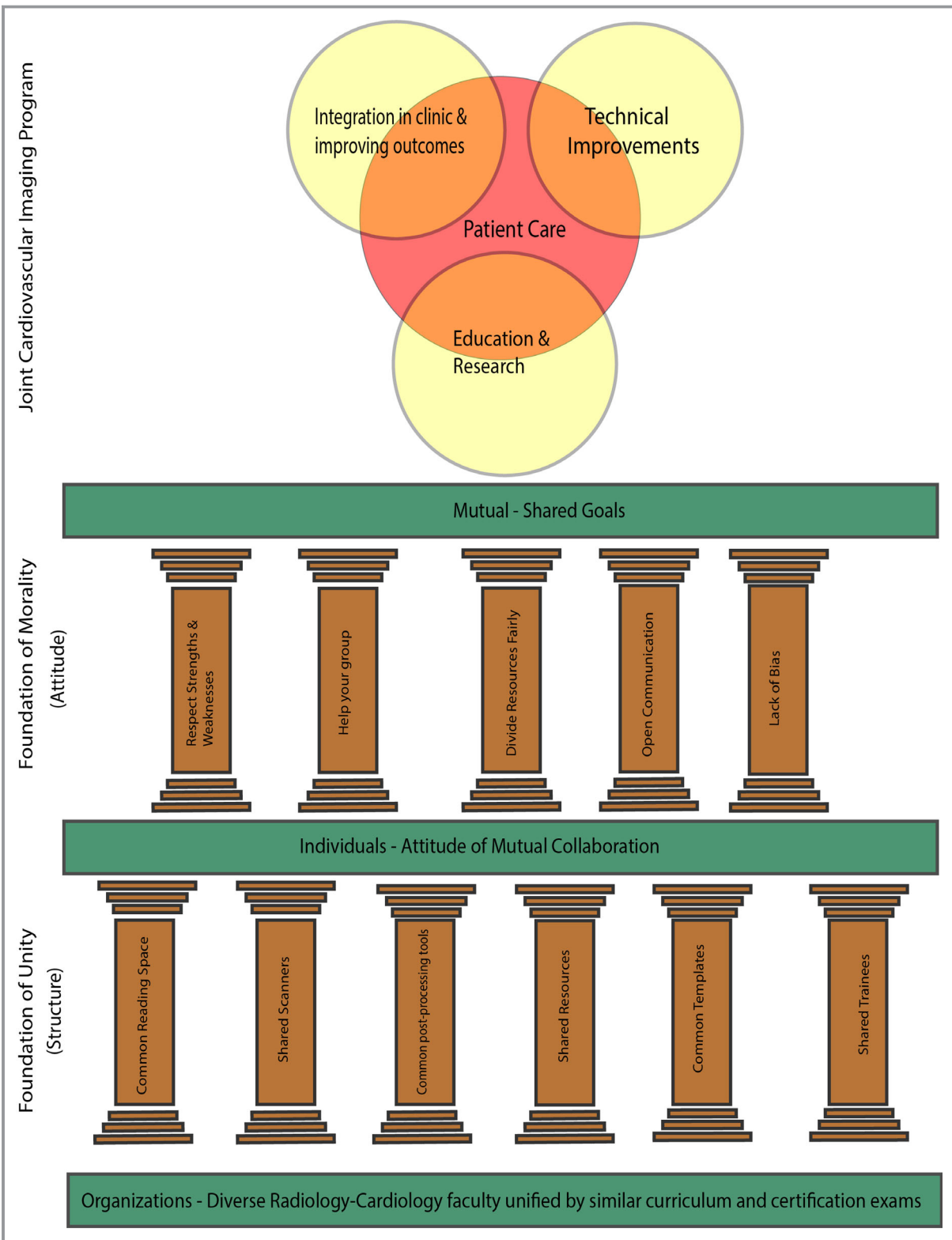


Figure. An illustration highlighting the foundations and structure of a radiology-cardiology collaborative cardiac imaging program.

Graduate Medical Education guidelines has been shown to improve the quality of the training program as well as patient care.⁹

While the overhaul of training programs, such that they foster mutual collaboration from the start, involves a current policy change, the individual patient care centers and

practicing individuals can play an important role in promoting collaborative cardiac imaging. The patient care centers (hospitals and academic institutions) need to support the alliance of cardiology and radiology by having a unified working space (cardiac/cardiovascular imaging reading room), common schedule, common administration, and shared trainees. Finally, the individuals practicing cardiac imaging should aim to be role models for collaborative work. The cultures are evolved by individuals based on their values and what they are like. Piaget, a psychologist, described “morality of cooperation” as a moral behavior that allows individuals to see the point of view of others and judge acts by intentions (and not consequences).¹⁰ Studies have shown that the practice of morality of cooperation is consistently considered good and helps promote team work.¹¹ These qualities include sharing and dividing resources fairly, helping each other, respecting the strengths and weaknesses of each other, and having open communication without any bias. Such an attitude should constitute the “foundation of morality” of a joint cardiac imaging program (Figure). Individuals with such behavior should be promoted to lead and shape the collaborative radiology-cardiology future of cardiac imaging. Any successful clinical program needs to have patient care as its primary objective. The additional goals of a radiology-cardiology partnership should be education and research, technological advances, and clinical integration of services to improve patient outcome. A radiology-cardiology partnership is unique and can complement each other beyond patient care by radiologists leading in technological improvement and cardiologists leading in clinical integration and improving patient outcomes. Collaborative programs made on these foundations are more likely to achieve their goals as a team and maximize the talents of individual members as well as organizations.

Disclosures

None.

References

1. Grapsa J, Kunadian V, Capodanno D, Vidal-Perez R, Radu M, Christia P, Efimova A, Windecker S, Lancellotti P, Cosyns B, Donal E, Alexandru Popescu B, Habib G. Joint EACVI HIT/EAPCI young survey/ESC CoT survey: training and education for ‘multimodality imaging in structural interventions’: the rise of a new sub-specialty? *Eur Heart J Cardiovasc Imaging*. 2016;17:1432–1433.
2. Cullen MW, Julien H, Weissman NJ. CV imaging for fellows in training: challenges and opportunities. *JACC Cardiovasc Imaging*. 2013;6:1225–1226.
3. Advanced Imaging Training Program Database. 2019. Available at: <https://www.acc.org/membership/sections-and-councils/imaging-section/training-resources>. Accessed Aug 15, 2019.
4. Narula J, Chandrashekar YS, Dilsizian V, Garcia MJ, Kramer CM, Malik S, Ryan T, Sen S, Wu JC. COCATS 4 task force 4: training in multimodality imaging. *J Am Coll Cardiol*. 2015;65:1778–1785.
5. ACR-NASCI-SPR Practice Parameter for Performance and Interpretation of Cardiac Computed Tomography (CT). American College of Radiology, 2017. Available at: <https://www.acr.org/-/media/ACR/Files/Practice-Parameters/CardiacCT.pdf>. Accessed March 1, 2019.
6. Dowe DA. How to win the coronary CTA turf war. *AJR Am J Roentgenol*. 2006;187:849–851.
7. Parwani P, Lopez-Mattei J, Choi AD. Building bridges in cardiology and radiology: why collaboration is the future of cardiovascular imaging. *J Am Coll Cardiol*. 2018;72:2534–2538.
8. Ahmed N, Devitt KS, Keshet I, Spicer J, Imrie K, Feldman L, Cools-Lartigue J, Kayssi A, Lipsman N, Elmi M, Kulkarni AV, Parshuram C, Mainprize T, Warren RJ, Fata P, Gorman MS, Feinberg S, Rutka J. A systematic review of the effects of resident duty hour restrictions in surgery: impact on resident wellness, training, and patient outcomes. *Ann Surg*. 2014;259:1041–1053.
9. Das SU. Impact of ACGME accreditation process on quality of program and patient care in the community. *J Grad Med Educ*. 2016;8:622.
10. Killen M, Rizzo MT. Morality, intentionality, and intergroup attitudes. *Behaviour*. 2014;151:337–359.
11. Curry OS, Mullins DA, Whitehouse H. Is it good to cooperate?: testing the theory of morality-as-cooperation in 60 societies. *Curr Anthropol*. 2019;60:47–69.

Key Words: #CardsRads • cardiac computed tomography • cardiac imaging • cardiac magnetic resonance imaging • collaborative medicine • imaging