

Morphological variations influencing the outcomes in posterior polar cataract

PR Aswin, Kandukuri Harika, Madhu Shekhar, Sankarananthan R, Amish Shah, Lakshmanan P¹, Haripriya Aravind²

Purpose: To study the intraoperative complications and postoperative clinical outcomes in different types of posterior polar cataract (PPC) following phacoemulsification, based on morphological classification. **Methods:** All consecutive patients with PPC who underwent phacoemulsification during the study period from 2016 to 2019 were included and sub-grouped based on the morphological characteristics according to Daljit Singh's classification. Intraoperative complications such as posterior capsular rupture (PCR), vitreous loss, nucleus drop, and Postoperative best-corrected visual acuity (BCVA) at day 1 and day 30 were documented. **Results:** A total of 388 eyes of 380 patients were included. Eighty nine (22.9%) eyes belonged to type 1, 135 (34.8%) belonged to type 2, 8 (2.1%) belonged to type 3, and 156 (40.2%) belonged to type 4. Thirty-five (9.3%) eyes had intraoperative PCR, with vitreous loss in 21 (60%) eyes, and nucleus/cortex drop in 5 (1.3%) eyes. Six (75%) eyes of type 3, 14 (10.04%) eyes of type 2, 12 (17.7%) eyes of type 4, and 3 (3.4%) eyes of type 1 PPC had PCR. PCR occurred more during the emulsification of the nucleus (18 cases, 51.4%). A significant correlation was seen between intraoperative PCR and type of PPC with a higher incidence in type 3 ($P < 0.001$). BCVA was found to be significantly worse on day 1 among patients with PCR compared to those who did not and improved well by day 30. **Conclusion:** PPC morphology is significantly co-related with the occurrence of PCR, emphasizing the need for careful grading of posterior polar cataracts in predicting the risk of intraoperative complications.

Key words: Complications, Daljit Singh grading, morphological classification, phacoemulsification, posterior polar cataract

Posterior polar cataract (PPC) presents a challenge to the phaco-surgeon because of its predisposition to posterior capsular rupture (PCR) and nucleus drop during cataract surgery.^[1-3] The incidence of PCR in patients with PPC undergoing cataract surgery can be as high as 36%.^[4] The extreme thinness and delicacy of the posterior capsule and the strong adhesion of the opacity to the posterior capsule are responsible for this complication.^[1] A fundamental differentiation, of determining whether the posterior capsule is intact or if there is pre-existing posterior capsule dehiscence, is necessary for the preoperative workup in patients with PPC. This differentiation helps to determine both surgical planning and the likelihood of intraoperative complications.

The size of the polar opacity was found to have a considerable impact as patients with posterior polar cataracts larger than 4 mm had a significantly higher risk of PCR during phacoemulsification.^[5] Anterior segment optical coherence tomography (AS-OCT) has also been used to determine the risk of PCR in these patients with a sensitivity of 87.5% and specificity of 62.1%.^[6] However, in day-to-day

practice, we come across many cases of PPC associated with morphological features such as nuclear sclerosis (NS) and posterior subcapsular cataract (PSCC), and an AS-OCT may not be available to all.^[6] Daljit Singh had classified PPC into four types depending on the appearance of the polar opacity and the presence of associated NS or PSCC.^[7] This study was done to determine the risk of intraoperative complications and postoperative clinical outcomes in different morphological variations of PPC using slit-lamp examination as per Daljit Singh's grading.^[7]

Methods

After obtaining approval from the Institutional Ethics Committee, all consenting patients presenting with PPC with or without nuclear sclerosis, undergoing phacoemulsification for a period of 4 years from 2016 to 2019 were included in this study. All patients were prospectively analyzed and underwent comprehensive ophthalmologic examination including visual acuity assessment, slit-lamp biomicroscopy, intraocular pressure measurement, and posterior segment examination. The diagnosis of PCR was made based on its

Departments of Intraocular Lens and Cataract Services and ¹Biostatistics, Aravind Eye Hospital and Postgraduate Institute of Ophthalmology, Madurai, Tamil Nadu, ²Department of Intraocular Lens and Cataract Services, Aravind Eye Hospital and Postgraduate Institute of Ophthalmology, Chennai, Tamil Nadu, India

Correspondence to: Dr. Madhu Shekhar, Department of Cataract and IOL Services, Aravind Eye Hospital, Anna Nagar, Madurai, Tamil Nadu - 625 020, India. E-mail: madhushekhhar93@gmail.com

Received: 29-Oct-2021
Accepted: 31-Jan-2022

Revision: 21-Dec-2021
Published: 30-Jun-2022

Access this article online

Website:

www.ijo.in

DOI:

10.4103/ijo.IJO_2764_21

Quick Response Code:



This is an open access journal, and articles are distributed under the terms of the Creative Commons Attribution-NonCommercial-ShareAlike 4.0 License, which allows others to remix, tweak, and build upon the work non-commercially, as long as appropriate credit is given and the new creations are licensed under the identical terms.

For reprints contact: WKHLRPMedknow_reprints@wolterskluwer.com

Cite this article as: Aswin PR, Harika K, Shekhar M, Sankarananthan R, Shah A, Lakshmanan P, *et al.* Morphological variations influencing the outcomes in posterior polar cataract. Indian J Ophthalmol 2022;70:2426-31.

characteristic appearance and classified according to Daljit Singh's classification.^[7]

- Type 1: The posterior opacity is associated with a subcapsular cataract [Fig. 1a].
- Type 2: Sharply defined round or oval opacity with the ringed appearance like an onion with or without grayish spots at the edge [Fig. 1b].
- Type 3: Sharply defined round or oval white opacity with dense white spots (Daljit Singh's sign) at the edge, often associated with thin or absent posterior capsule [Fig. 1c].
- Type 4: Combination of the above three types with nuclear sclerosis [Fig. 1d].

Grading of PPC was done by slit-lamp examination and confirmed by a slit-lamp photograph. In advanced cataracts with dense nuclear sclerosis, only cases where PPC could be confirmed on slit-lamp bio-microscopy were included in the study. Slit-lamp photo evaluation was done by two masked surgeons and categorized in their respective types. Written informed consent was taken from all patients before surgery. Patients were explained and counseled about the risk of posterior capsule tear or nucleus drop and the possibility of a retinal intervention as well as prolonged surgical duration. Only surgeons with experience in performing >2,000 phacoemulsification procedures were included in the study. The intraoperative complications, steps at which PCR occurred, preoperative and postoperative visual acuities (standard Snellen chart), and the causes of impaired visual acuity after surgery were analyzed. Patients with a minimum follow-up of 1 month after surgery were included in the

analysis. Decimal visual acuity was assessed at each visit and converted to the logarithm of the minimum angle of resolution (logMAR) scale for statistical analysis.

Any combined procedure, traumatic and complicated cataracts, eyes with corneal pathology, and pediatric cataracts were excluded from the study.

Surgical technique

All patients underwent clear corneal phacoemulsification with a standard surgical technique under retrobulbar or sub-Tenon's block. The surgeons were masked to the type of PPC. After making a side-port and clear corneal main incision, the anterior chamber was formed with viscoelastic material. The size of continuous curvilinear capsulorhexis was kept approximately 5 to 5.5 mm and hydrodelineation was done instead of hydrodissection. Nucleus rotation was avoided. After hydrodelineation, phacoemulsification of the nucleus was performed using the Infiniti Phaco System (Alcon Inc., USA). Cortex aspiration was performed initially in the periphery, and the central opacity was gently separated from the posterior capsule and removed, at last, using co-axial irrigation and aspiration system. In patients without PCR, IOL was placed in the bag. In the case of PCR, the second instrument was taken out and replaced with dispersive viscoelastic (Viscoat, Alcon Laboratories, USA) and then the phaco probe was withdrawn. If there was a vitreous disturbance, bimanual automated anterior vitrectomy was done through two paracenteses with low bottle height and high cut-rate. A three-piece foldable acrylic IOL was implanted in the sulcus with optic capture done for proper centration. In the presence of nucleus or cortex drop, a retina

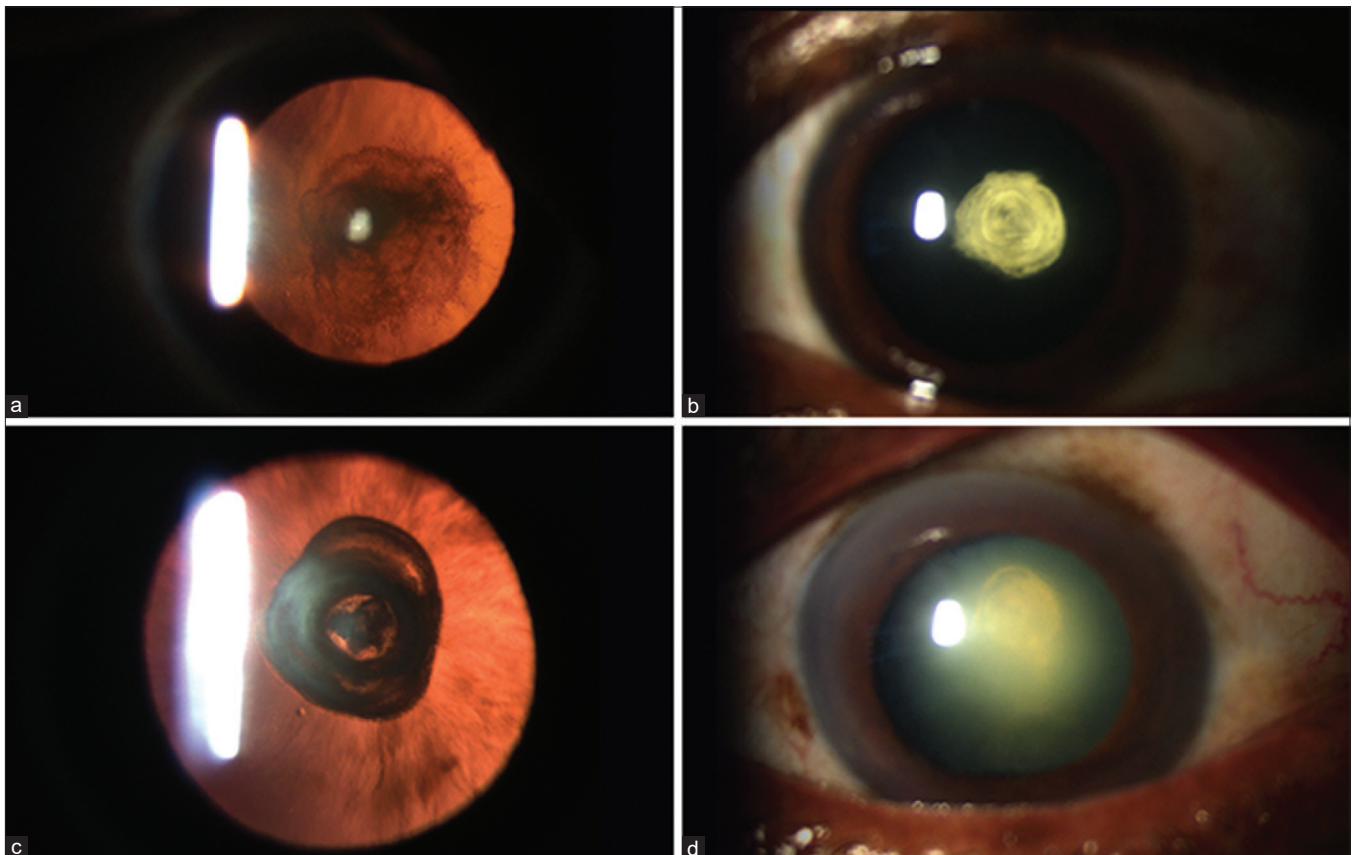


Figure 1: Anterior segment slit-lamp photography showing Type 1 (a), Type 2 (b), Type 3 (c) and Type 4 (d) PPC as per Daljit Singh's classification

consult was taken on the same day and pars plana vitrectomy with lensectomy or cortex removal was done the same day or the following day. At the end of the surgery, all patients received 0.1 mL of 0.5% intracameral moxifloxacin.

In type 1 PPC and type 2 PPC, the parameters were set as torsional power 40–70% in the linear mode, a linear vacuum of 370 mmHg, fixed aspiration of 35 to 40 mL/min, and irrigation of 100 cm H₂O. In type 3 PPC, phaco parameters were the same but irrigation was reduced to 90 cm of H₂O. Viscodissection was performed after hydrodelineation. Nucleus rotation was avoided and the nucleus was managed with direct chop technique. The second instrument was replaced with viscoelastic at the end of surgery to avoid anterior chamber collapse. In type 4 PPC with up to grade 2 nuclear sclerosis, the above parameters were used. In type 4 PPC for nuclear sclerosis of grade 3 and above, the parameters were set as linear torsional power 70–100%, a fixed vacuum of 400–450 mm Hg, aspiration of 35–40 mL/min in the fixed mode, and irrigation of 100 cm H₂O. Care was taken in hard cataracts to chop the endonucleus into small pieces rather than extending the crack from one pole of the equator to the other.

Postoperatively, all patients were given a combination of gatifloxacin 0.3% and prednisolone 1% six times a day and tapered over 6 weeks. Topical non-steroidal anti-inflammatory drug (NSAID) nepafenac 0.1% three times a day for 1 month to prevent the occurrence of cystoid macular edema. In case of any intraoperative complication, IOL stability was assessed postoperatively and centration was confirmed with slit-lamp biomicroscopy.

Statistical analysis

Mean (SD) and frequency (percentage) were given for continuous and categorical variables. Shapiro–Wilk test was used to test the normality of the data. The Chi-square test or Fisher's exact test was used to compare proportions. Kruskal–Wallis test/Mann–Whitney *U* test was used to compare between the groups. Wilcoxon signed-rank test was used for paired data set. A *P* value <0.05 was considered statistically significant. All analyses were done using the statistical software STATA version 14.0.

Results

Demographic profile and grading

A total of 388 eyes of 380 patients were included in the study, among which 177 (46.6%) were males and 203 (53.4%) were females. The mean age of the patients was 53.8 ± 12.4 years (range: 16–87 years). Of the 388 eyes, 181 (46.7%) belonged to the right eye, 207 (53.3%) belonged to the left eye, and 16 (4.12%) had bilateral PPC. Of the 388 eyes, 89 (22.9%) belonged to type 1, 135 (34.8%) belonged to type 2, 8 (2.1) belonged to type 3, and 156 (40.2%) belonged to type 4 [Table 1]. The mean age of the patients with type 1, type 2, type 3, and type 4 was 50.70 ± 10.68 years, 47.96 ± 11.77 years, 42.75 ± 12.01 years, and 61.38 ± 9.3 years, respectively. The mean age of presentation of patients with type 4 PPC was significantly higher compared to patients with other types of PPC (*P* < 0.0001).

Complications

The most common intraoperative complication was PCR in 35 (9%) eyes. A statistically significant correlation was seen between the grading and PCR (*P* < 0.001) with 3 (3.4%) eyes with type 1 PPC, 14 (10.4%) with type 2 PPC and 6 (75%) with type 3 PPC and 12 (7.7%) in Type 4 [Table 2]. PCR was accompanied by a vitreous loss in 21 eyes and automated anterior vitrectomy was performed. The vitreous loss was present in eight patients (66.7%) with type 4 PPC and four patients (66.7%) with Type 3 PPC, and seven patients (50%) with type 2 PPC. There was no statistically significant association between vitreous loss and grading (*P* = 0.839). Most of the PCR occurred during nucleus emulsification in 18 eyes (51%), followed by cortex wash in 13 eyes (37%) [Table 3]. Lens matter drop into vitreous was seen in five (1.3%) eyes that required further retinal surgical intervention. Among the five eyes with lens matter drop, one eye had type 2 PPC, two eyes had type 3 PPC, and two eyes had type 4 PPC.

Visual acuity

The mean Best Corrected Visual Acuity (BCVA) improved significantly from a preoperative value of 0.50 ± 0.4 logMAR to 0.09 ± 0.2 logMAR on the first postoperative day and 0.02 ± 0.1 logMAR at 1 month, postoperatively (*P* < 0.001,

Table 1: Patient demographics and intraoperative data

| Patient demographics | | | | | |
|----------------------|-------------|-------------|-------------|------------|-------------------------------|
| Age group | Mean 53.8 | | SD 12.4 | | Range 16-87 |
| Gender | Male | | Female | | Total |
| | 177 (46.6) | | 203 (53.4) | | 380 (100) |
| Eye | Total | | Unilateral | | Bilateral |
| Right eye | 181 (46.7) | | 173 (46.5) | | 16 |
| Left eye | 207 (53.3) | | 199 (53.5) | | |
| Total | 388 | | 372 | | 16 |
| PPC grading | Grade 1 | Grade 2 | Grade 3 | Grade 4 | <i>P</i> |
| Number | 89 (22.9) | 135 (34.8) | 8 (2.1) | 156 (40.2) | |
| Age group | 50.70±10.68 | 47.96±11.77 | 42.75±12.01 | 61.38±9.3 | <i>P</i> <0.0001 ^C |
| PCR incidence | 3 (3.4) | 14 (10.4) | 6 (75) | 12 (17.7) | <i>P</i> <0.001 ^C |
| Vitreous disturbance | 2 (66.7) | 7 (50.0) | 4 (66.7) | 8 (66.7) | <i>P</i> =0.839 ^F |
| Nucleus drop | | 1 (20) | 2 (40) | 2 (40) | |

C - Chi-square test, PPC - Posterior polar cataract, PCR - Posterior capsular rent, F - Fisher's exact test

Wilcoxon-signed ranks test). The BCVA of 6/9 or better was achieved in 92% of eyes (82 of 89) with type 1 PPC, 93% of eyes (126 of 135) with type 2 PPC, 62.5% of eyes (5 of 8) with type 3 PPC, and 94.9% of eyes (148 of 156) with type 4 PPC at 1 month postoperatively [Table 4]. The BCVA of 6/9 or better was achieved in 342 eyes (88%) on the first postoperative day and in 361 eyes (93%) at 1 month postoperatively. Among 35 eyes with PCR, a BCVA of 6/9 or better was achieved in 30 eyes (85.7%) at 1 month postoperatively. Patients with PCR had significantly poor mean BCVA (0.33) compared to those who did not (0.07) at day 1 postoperatively ($P < 0.05$), and there was no significant difference in mean BCVA at 1 month postoperatively ($P = 0.261$) [Table 5].

Discussion

Posterior polar cataracts are challenging entities and are known to predispose to PCR and vitreous loss during cataract surgery.^[1] The incidence of PCR during PPC surgery was variable, with older studies that reported an incidence as high as 26% and 36%.^[1,4] With better surgical techniques, improving technology, and increasing surgical experience, the incidence of this complication has been reduced to 6%–7% and even as low as 4%.^[2,8] In our study, the rate of PCR in PPC was 9%, with a statistically significant correlation between the type of PPC as per Daljit Singh’s grading and the occurrence of PCR. In eyes with type 1 PPC, the incidence of PCR was much lesser as compared with that in type 2 and type 4 PPC. The greater force required during chopping to separate the pieces in a higher grade of nuclear opalescence associated with PPC could lead to increase the risk of PCR during surgery. Das *et al.* found a higher rate of PCR in younger patients (< 40 years), whereas Osher *et al.* did not find a relation between the capsular rupture and age, sex, or family history.^[1,13] In our study, PCR in PPC cases had no relation between the age or sex of the patient with the grading of PPC. We did however note that type 4 PPC had a significantly higher mean age at presentation ($P < 0.0001$).

Different clinical classification schemes have been proposed in the literature depending on the phenotypic appearance and clinical course. Chan *et al.* used OCT imaging to grade PPCs and determine the presence or absence of PCR. Similarly, Kymionis *et al.* reported a series of three cases with PPCs, where the OCT helped to determine the status of the posterior capsule before surgery.^[6,10] Pujari *et al.* used newer generation AS-OCT (CASIA-2) to classify the morphology deficient posterior capsule in patients with PPC.^[11] In another recent study conducted by Pujari *et al.*, intraoperative OCT (i OCT) provided a good understanding of real-time changes in different layers of the lens during PPC surgery.^[12] However, the cost of the machine limits its availability to every clinical setup. In our study, PPC was classified based on morphology using slit-lamp examination as proposed by Daljit Singh, and a significant correlation was seen between the occurrence of PCR and the grading ($P < 0.001$), which highlights the need for careful preoperative grading in PPC. The advantage of this grading is, this can be done even in the absence of expensive AS-OCT machines.

Various techniques and precautions have been described to minimize the risk of PCR during surgery.^[9] Das *et al.* had described a new technique for PPCs with dense nuclear sclerosis, wherein the nucleus is partially cracked in the periphery avoiding the posterior polar opacity and then chopped into quadrants without rotating the nucleus.^[13] Haripriya *et al.* have recommended bimanual phacoemulsification with low infusion and low vacuum to maintain a stable chamber during phacoemulsification and thus reduce complications.^[14] Malhotra *et al.*^[15] used a combination of careful methods of V groove nucleotomy for type 2 and type 3 PPC and the lambda technique for type 4 PPC to reduce the risk of PCR.

In our study, hydrodelineation was performed instead of hydrodissection as posterior polar opacities attach firmly to the posterior capsule and strong hydrodissection may tear the posterior capsule around the opacity. Along with hydrodelineation, Fine *et al.* also performed hydrodissection in multiple quadrants injecting small quantities of fluid gently, such that the fluid wave is not allowed to spread across the entire posterior capsule.^[16] Any effort to rotate the nucleus can lead to PCR and should be avoided.^[4] Allen and Wood reported using viscodissection to gently dissect the peripheral cortex and epinucleus from the capsule.^[17] Secondly, care was taken to prevent the collapse of the anterior chamber with the injection of viscoelastic material before withdrawing the handpiece out of the anterior chamber. However, Fine *et al.* warned against over-injection of OVD because increasing the pressure in the anterior chamber could cause rupture of the posterior capsule.^[16]

Table 2: Incidence of PCR in different PPC gradings

| Grading | PCR n (%) | | Total n (%) | P |
|---------|-----------|------------|-------------|---------------------|
| | Yes | No | | |
| 1 | 3 (3.4) | 86 (96.6) | 89 (100) | <0.001 ^c |
| 2 | 14 (10.4) | 121 (89.6) | 135 (100) | |
| 3 | 6 (75.0) | 2 (25.0) | 8 (100) | |
| 4 | 12 (7.7) | 144 (92.3) | 156 (100) | |
| Total | 35 (9.0) | 353 (91.0) | 388 (100) | |

C - Chi-square test, n - number of eyes, PCR - posterior capsular rent, PPC - posterior capsular rent

Table 3: Occurrence of PCR with different steps of phacoemulsification

| Grading | PCR step | | | | | Total n (%) | P |
|---------|----------------|------------|-------------|---------|----------|-------------|--------------------|
| | Emulsification | Epinucleus | Cortex wash | Closure | Pre-op | | |
| 1 | 1 (33.3) | - | 2 (66.7) | - | - | 3 (100) | 0.268 ^f |
| 2 | 5 (35.7) | 1 (7.1) | 7 (50.0) | 1 (7.1) | - | 14 (100) | |
| 3 | 3 (50.0) | 1 (16.7) | 1 (16.7) | - | 1 (16.7) | 6 (100) | |
| 4 | 9 (75.0) | - | 3 (25.0) | - | - | 12 (100) | |
| Total | 18 (51.4) | 2 (5.7) | 13 (37.1) | 1 (2.9) | 1 (2.9) | 35 (100) | |

F - Fisher’s exact test, n - number of eyes, PCR - posterior capsular rent

Table 4: Visual outcomes in different types of PPC at POD 1 and POD 30

| Grading | No. of eyes (%) | POST op 1 day BCVA 6/9 and better | POD 1 month BCVA 6/9 and better |
|---------|-----------------|-----------------------------------|---------------------------------|
| 1 | 89 | 81 (91.0) | 82 (92.1) |
| 2 | 135 | 128 (94.8) | 126 (93.3) |
| 3 | 8 | 4 (50.0) | 5 (62.5) |
| 4 | 156 | 129 (82.7) | 148 (94.9) |
| Total | 388 | 342 (88.1) | 361 (93.0) |

n - number, POD - postoperative day, BCVA - best-corrected visual acuity, PPC - posterior polar cataract

Table 5: Correlation between intraoperative PCR and BCVA

| BCVA LogMAR | PCR | | <i>P</i> ^M |
|--------------|----------------|----------------|-----------------------|
| | Present | Absent | |
| Pre | | | 0.763 |
| Mean (SD) | 0.53 (0.5) | 0.5 (0.4) | |
| Median (IQR) | 0.48 (0.3-0.6) | 0.3 (0.18-0.6) | |
| Day 1 | | | 0.0004 |
| Mean (SD) | 0.31 (0.5) | 0.07 (0.2) | |
| Median (IQR) | 0.09 (0-0.3) | 0 (0-0) | |
| Month 1 | | | 0.261 |
| Mean (SD) | 0.05 (0.1) | 0.02 (0.07) | |
| Median (IQR) | 0 (0-0) | 0 (0-0) | |

M - Mann-Whitney test; IQR - interquartile range

The peripheral cortex was aspirated before the central polar opacity was pulled out. Low-energy phacoemulsification is postulated to cause less trauma to the ocular structure. Torsional phacoemulsification has been associated with less ultrasound time and energy. It has also been found to have less repulsion of the nuclear fragments, better anterior chamber stability due to the greater vacuum limit accuracy, less occlusive break surge, and improved followability.^[18-20] Bimanual irrigation aspiration (I/A) is generally recommended as it gives better control, maintains the chamber, and allows for complete removal of the cortex. Alternatively, a coaxial system with the assistance of OVDs can also be used.

In most patients, the opacity spontaneously came off the posterior capsule, probably as a result of the infusion pressure during the removal of the peripheral cortex. However, in some cases, portions of the opacity adhered strongly to the posterior capsule and could not be easily separated. In these cases, we usually leave the residual plaque in place during the surgery and plan later removal by Nd: YAG laser capsulotomy.

Vasavada *et al.* and Hayashi *et al.* reported a 4% incidence of nucleus drop.^[2,4] Ho *et al.* had previously reported unilateral spontaneous rupture with posterior dislocation of the crystalline lens in the vitreous cavity without a history of trauma or other systemic diseases.^[21] They proposed that a rise in the size of the lens from nuclear sclerosis can cause increased pressure on the posterior capsule with subsequent rupture. In a study conducted by Malhotra *et al.*, there was no case of nucleus drop.^[15] The incidence of nucleus/cortex drop in the present study was 1.3%, which was present in 5 out of the 388 eyes, among which 3 eyes had nucleus drop

during emulsification, 1 eye during chopping of the nucleus, and 1 eye had cortex drop during I/A. Among those five patients, two patients who had nucleus drop were managed with three-port pars plana vitrectomy and pars plana lensectomy in the same sitting, and IOL was placed in the ciliary sulcus. Postoperatively, the first patient had BCVA 6/18 and the second patient had 6/6. Two patients had small epinucleus drop during emulsification for which pars plana vitrectomy was done later and both the patients had BCVA of 6/9 postoperatively. One patient had cortex drop during I/A, which was managed by automated anterior vitrectomy, and IOL was placed in the sulcus. No further vitreoretinal intervention was required and the postoperative visual outcome was 6/6. Only one patient with PCR had developed pupillary block on the 15th postoperative day due to pupillary capture of the flipped three-piece intraocular lens and the vision dropped to 6/18, which was managed by performing laser peripheral iridectomy to relieve the pupillary block, followed by repositioning of the IOL. Postoperatively, the patient had a BCVA of 6/6. Even though retinal detachment has been reported in prior studies, none of our cases were complicated by retinal detachment.^[4,11]

While all cases were managed appropriately, in terms of visual outcomes after surgery, five patients with PCR were found to have poor visual acuity at 1 month postoperatively. The reduced visual acuity was due to pre-existing retinal pathology in two patients, postoperative cystoid macular edema in two patients, and amblyopia in one patient. Identifying and grading PPC, allotting them to experienced surgeons, and using the various techniques and precautions can help in anticipating and reducing the complications. Limitations of the study include the short follow-up period, data from multiple surgeons, and the variation in the number of patients in each group.

Careful preoperative planning and taking necessary precautions during surgery are of utmost importance and while complications are inevitable, managing them appropriately is crucial in achieving good outcomes after surgery.

Conclusion

Careful preoperative assessment and grading of the PPC can help predict the possibility of PCR during surgery. Grade 3 PPCs were associated with a higher incidence of PCR and patients with intraoperative PCR had a significantly poor postoperative visual outcome on the first postoperative day that improved well by postoperative day 30. Advanced and expensive imaging techniques such as AS-OCT may not be accessible at every clinical setup. Grading of PPC using slit-lamp examination as per Daljit Singh's classification will be helpful in both proper planning of surgery as well as preoperative counseling of patients regarding the additional risk of PCR and nucleus drop during surgery. In the presence of intraoperative complications, optimum and timely management is crucial in achieving good visual outcomes.

Financial support and sponsorship

Nil.

Conflicts of interest

There are no conflicts of interest.

References

1. Osher RH, Yu BC, Koch DD. Posterior polar cataracts: A predisposition to intraoperative posterior capsular rupture. *J Cataract Refract Surg* 1990;16:157-62.
2. Hayashi K, Hayashi H, Nakao F, Hayashi F. Outcomes of surgery for posterior polar cataract. *J Cataract Refract Surg* 2003;29:45-9.
3. Lee MW, Lee YC. Phacoemulsification of posterior polar cataracts--A surgical challenge. *Br J Ophthalmol* 2003;87:1426-7.
4. Vasavada A, Singh R. Phacoemulsification in eyes with posterior polar cataract. *J Cataract Refract Surg* 1999;25:238-245.
5. Kumar S, Ram J, Sukhija J, Severia S. Phacoemulsification in posterior polar cataract: Does size of lens opacity affect surgical outcome? *Clin Exp Ophthalmol* 2010;38:857-61.
6. Chan TC, Li EY, Yau JC. Application of anterior segment optical coherence tomography to identify eyes with posterior polar cataract at high risk for posterior capsule rupture. *J Cataract Refract Surg* 2014;40:2076-81.
7. Masket S. Consultation section: Cataract surgical problem. *J Cataract Refract Surg* 1997;23:819-24.
8. Vasavada AR, Vasavada V, Vasavada S, Srivastava S, Vasavada V, Raj S. Femtodelineation to enhance safety in posterior polar cataracts. *J Cataract Refract Surg* 2015;41:702-7.
9. Vasavada AR, Raj SM, Vasavada V, Shrivastav S. Surgical approaches to posterior polar cataract: A review. *Eye (Lond)* 2012;26:761-70.
10. Kymionis GD, Diakonis VF, Liakopoulos DA, Tsoulnaras KI, Klados NE, Pallikaris IG. Anterior segment optical coherence tomography for demonstrating posterior capsular rent in posterior polar cataract. *Clin Ophthalmol* 2014;8:215-7.
11. Pujari A, Yadav S, Sharma N, Khokhar S, Sinha R, Agarwal T, *et al.* Study 1: Evaluation of the signs of deficient posterior capsule in posterior polar cataracts using anterior segment optical coherence tomography. *J Cataract Refract Surg* 2020;46:1260-5.
12. Pujari A, Sharma N, Bafna RK, Agarwal D. Study 3: Assessment of events during surgery on posterior polar cataracts using intraoperative optical coherence tomography. *Indian J Ophthalmol* 2021;69:594-7.
13. Das S, Khanna R, Mohiuddin SM, Ramamurthy B. Surgical and visual outcomes for posterior polar cataract. *Br J Ophthalmol* 2008;92:1476-8.
14. HariPriya A, Aravind S, Vadi K, Natchiar G. Bimanual microphaco for posterior polar cataracts. *J Cataract Refract Surg* 2006;32:914-7.
15. Malhotra C, Dhingra D, Nawani N, Chakma P, Jain AK. Phacoemulsification in posterior polar cataract: Experience from a tertiary eye care Centre in North India. *Indian J Ophthalmol* 2020;68:589-94.
16. Fine IH, Packer M, Hoffman RS. Management of posterior polar cataract. *J Cataract Refract Surg* 2003;29:16-9.
17. Allen D, Wood C. Minimizing risk to the capsule during surgery for posterior polar cataract. *J Cataract Refract Surg* 2002;28:742-4.
18. Rekas M, Montés-Micó R, Krix-Jachym K, Kluś A, Stankiewicz A, Ferrer-Blasco T. Comparison of torsional and longitudinal modes using phacoemulsification parameters. *J Cataract Refract Surg* 2009;35:1719-24.
19. Bozkurt E, Bayraktar S, Yazgan S, Cakir M, Cekic O, Erdogan H, *et al.* Comparison of conventional and torsional mode (OZil) phacoemulsification: Randomized prospective clinical study. *Eur J Ophthalmol* 2009;19:984-9.
20. Christakis PG, Braga-Mele RM. Intraoperative performance and postoperative outcome comparison of longitudinal, torsional, and transversal phacoemulsification machines. *J Cataract Refract Surg* 2012;38:234-41.
21. Ho SF, Ahmed S, Zaman AG. Spontaneous dislocation of posterior polar cataract. *J Cataract Refract Surg* 2007;33:1471-3.