

CASE REPORT

An elderly female with rib osteolytic lesion after recovery from fulminant liver failure induced by acute-onset autoimmune hepatitis

Hiroto Tanaka, Hideyuki Sasaki & Mikio Arita

The Department of Internal Medicine, Kihoku Hospital Wakayama Medical University, Japan

Correspondence

Hiroto Tanaka, The Department of Internal Medicine, Kihoku Hospital Wakayama Medical University, Myouji 219, Katsuragi, Ito-gun, Wakayama, 649-7113 Japan.
Tel: +81-736-22-0066;
Fax: +81-736-22-8223;
E-mail: hiro10@wakayama-med.ac.jp

Funding Information

No sources of funding were declared for this study.

Received: 29 September 2014; Revised: 4 October 2015; Accepted: 22 October 2015

Clinical Case Reports 2016; **4**(2): 186–191

doi: 10.1002/ccr3.452

Key Clinical Message

This report highlights an interesting case of an osteolytic lesion (actinomycosis) after fulminant liver failure induced by autoimmune hepatitis (AIH). When treating patients with fulminant liver failure due to AIH using immunosuppressive drugs, such as steroids, the possibility of such rare occurrences should be kept in mind.

Keywords

Actinomycosis, autoimmune hepatitis, fulminant liver failure, osteolytic tumor.

Introduction

Autoimmune hepatitis (AIH) is a chronic progressive hepatitis characterized by positive antinuclear antibody (ANA) and hypergammaglobulinemia, portal inflammatory cell infiltration with plasmacyte dominance, and piecemeal necrosis [1]. Acute-onset cases of AIH account for up to 25% of all cases, some of which present as fulminant liver failure [2]. The diagnosis of AIH is established by the criteria defined by the International Autoimmune Hepatitis Group and by the exclusion of other causes [3]. However, acute-onset AIH is not typical, and this diagnosis is difficult [4–6]. There are few reports of complications after recovery from fulminant liver failure secondary to AIH.

On the other hand, actinomycosis is an uncommon chronic suppurative infection caused by anaerobic bacteria. Risk factors of actinomycosis are poor oral hygiene resulting in tooth decay, chronic lung disease, alcoholism, and other disorders resulting in reduced immunocompetence [7].

The present report describes an interesting case of an osteolytic lesion (actinomycosis) after recovery from fulminant liver failure induced by AIH.

Case Report

The patient was a 77-year-old woman whose chief complaints were jaundice, general fatigue, and brown urine. The patient was seeing a local doctor for chronic gastritis and was given lansoprazole 15 mg once a day, mosapride citrate hydrate 5 mg three times a day, etizolam 0.5 mg once a day, and an unknown herbal medicine, without signs of hepatic injury. On 15 May 2009, she had general fatigue, but no laboratory dysfunction was shown. On 23 June 2009, she had jaundice and brown urine, and laboratory data showed liver dysfunction. She was referred and admitted to our hospital the same day. While she had eaten raw foods within the previous month, she had not eaten raw oysters.

On admission, her consciousness was clear, and although yellowing of the bulbar conjunctiva was noted, no other abnormalities were identified.

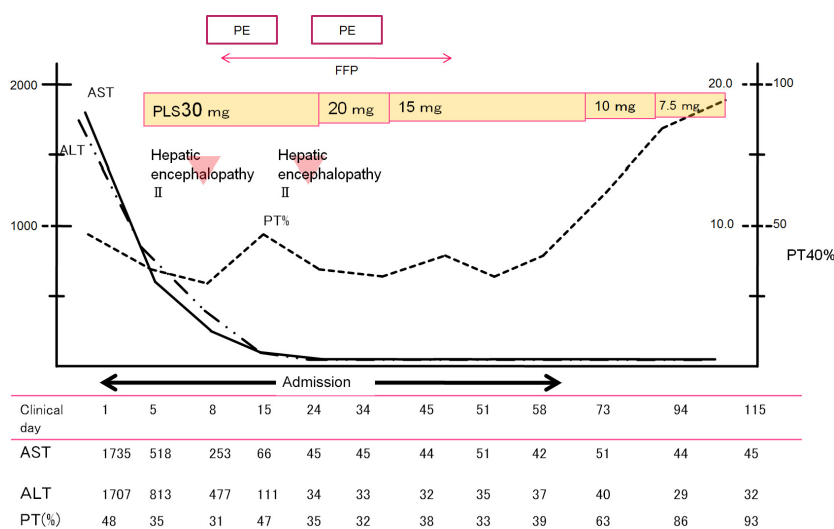
Laboratory findings on admission (Table 1) included aspartate aminotransferase (AST), 1735 IU/L; alanine aminotransferase (ALT), 1707 IU/L; total bilirubin (TB),

Table 1. Laboratory data on admission

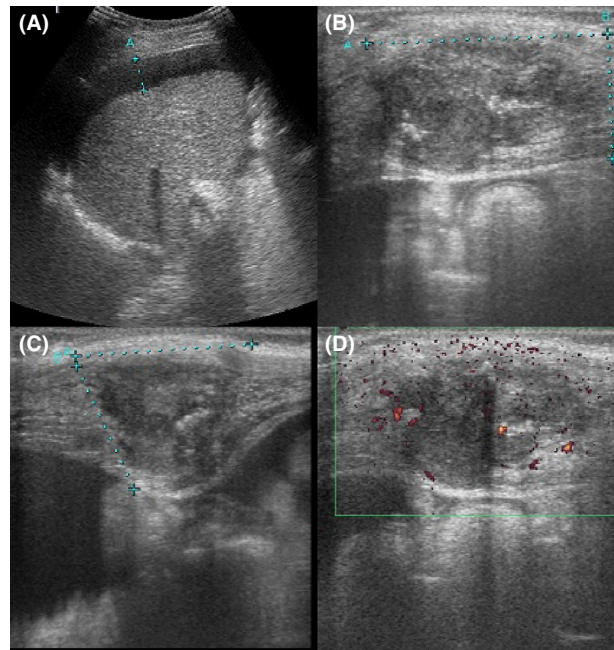
Complete blood count		Serum chemistry and immunological test			
WBC	$32 \times 10^2/\text{mm}^3$	Na	141 mEq/L	NH ₃	25 $\mu\text{g/dL}$
	Neutro 57.5%	K	3.7 mEq/L	Amy	115 IU/L
	Lym 27.6%	Cl	104 mEq/L	TB	7.13 mg/dL
	Eosino 1.3%	Alb	3.6 g/dL	DB	4.56 mg/dL
	Mono 13.0%	UN	12.5 mg/dL	IgG	1793 mg/dL
RBC	$396 \times 10^4/\text{mm}^3$	Cr	0.76 mg/dL	IgA	377 mg/dL
Hb	12.1 g/dL	TC	177 mg/dL	IgM	55 mg/dL
Ht	35.7%	TG	120 mg/dL	ANA	$\times 320$
Plt	$8.2 \times 10^4/\text{mm}^3$	Glu	123 mg/dL	AMA	(-)
		γ -GTP	150 U/L	LKM-1	(-)
		ALP	350 IU/L		
Blood coagulation test		AST	1735 IU/L		
PT (45% INR 1.50)	18.1s	ALT	1707 IU/L	Virus marker	
		CK	269 IU/L	CMV IgM	(-)
		CRP	0.41 mg/dL	EBV IgM	(-)
				IgM-HA	(-)
				HBs Ag	(-)
				IgM-HB	(-)
				HCVAb	(-)
				HCV RNA	(-)

7.13 mg/dL; prothrombin time rate (PT%, international normalized ratio [INR]), 45%, 1.5; hepatitis B surface antigen (HBsAg) negative; hepatitis C virus (HCV) RNA negative; anti-liver/kidney microsome type 1 antibody (LKM-1) negative, and other virus antibodies negative. Furthermore, as levels of ANA ($\times 320$) and immunoglobulin G (IgG) (1793 mg/dL) were elevated, AIH was suspected. Abdominal ultrasound showed the thickened gallbladder wall, suggesting acute hepatitis.

The clinical course following admission is illustrated in Figure 1. Although AST and ALT levels began to improve after the injection of glycyrrhizin, TB and PT% deteriorated to 17 mg/dL and 35%, respectively. While we wanted to perform liver biopsy for the diagnosis of AIH, it was deemed too dangerous due to severe liver failure, especially with regard to the abnormal PT%. AIH was suspected and oral steroids (prednisolone 30 mg) were administered. However, the patient developed fulminant

**Figure 1.** Clinical course of the patient.

Abdominal echo finding



Dynamic CT scan

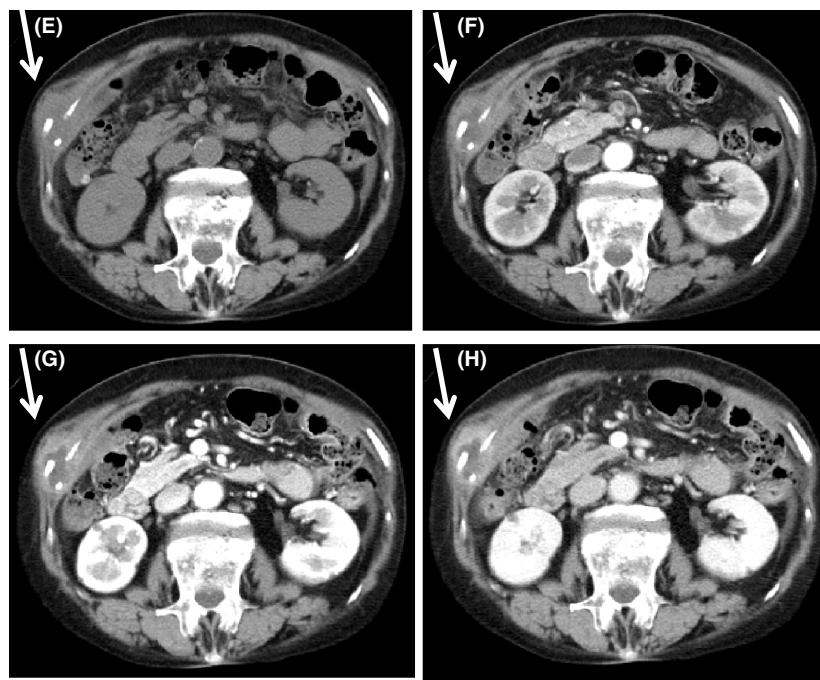


Figure 2. (A–D) Abdominal ultrasound findings at 78 days after first admission. (B–D) A 4-cm tumor is seen at the right rib. (A) Abdominal ultrasound shows a moderate amount of ascites. (B, C) Ultrasound finding of tumor in the 10th right rib is heterogeneous. (D) Doppler ultrasound finding of tumor in the 10th right rib is hypovascular. (E–H) Abdominal unenhanced and enhanced computed tomography (CT) scan findings at 78 days after first admission. (E) Plane, (F) arterial phase, (G) equilibrium phase, and (H) venous phase. Tumor in the 10th right rib is showed by an arrow. In addition, the surroundings of the tumor are enhanced in the venous phase.

liver failure with stage 2 hepatic encephalopathy on the eighth clinical day, and plasma exchange was performed for 3 days. Levels of AST, ALT, TB, and the symptoma-

tology of hepatic encephalopathy improved, but fresh-frozen plasma (FFP) was transfused every day from 12th clinical day due to a lack of response in PT%. On the

19th clinical day, general fatigue and stage 2 hepatic encephalopathy developed, and plasma exchange was again performed for 3 days from the 24th clinical day. The symptomatology of hepatic encephalopathy improved, but daily FFP transfusion was still required.

The AST and ALT levels subsequently normalized, and the prednisolone dose was decreased to 20 mg/day on the 28th clinical day. The dose was decreased to 15 mg/day 1 week later, as AST and ALT remained normal. On the 60th clinical day, she was discharged, and the prednisolone dose was decreased to 7.5 mg/day.

At the outpatient examination on the 78th clinical day, abdominal ultrasound and helical dynamic CT scan were performed, showing a 4-cm osteolytic tumor of the 10th right rib (Fig. 2). The suspicion of metastasis was raised, but gastrointestinal endoscopy and colon endoscopy did not reveal evidence of any malignant tumor.

An increase in serum cancer antigen 125 (CA125) level was noted, but gynecologic evaluation failed to detect any malignant tumor. On the 125th clinical day, the patient presented with severe pain of the right hip joint and was readmitted with suspicion of the osteonecrosis of the femoral head. However, she was subsequently diagnosed with suppurative inflammation of the hip joint due to methicillin-sensitive *Staphylococcus aureus* (MSSA) and was

treated by an orthopedist. Her hip joint pain improved by the 146th clinical day, and a biopsy of the liver and the 10th right rib tumor was performed. Examination of the liver specimen showed that the portal tract was infiltrated with inflammatory cells (including plasma cells), the parenchymal architecture had been partially disrupted, and surviving hepatocytes had formed gland-like rosettes. Examination of the 10th right rib specimen showed infiltration of lymphocytes and plasma cells, fibrosis, and the Druse (arrow) with abscess formation (Fig. 3).

In conclusion, during recovery from fulminant liver failure induced by acute onset AIH, the patient was diagnosed with actinomycosis of the 10th right rib. This patient had been treated with amoxicillin. However, due to the development of amoxicillin allergy, the treatment was discontinued immediately, and treatment with levofloxacin hydrate was initiated. Her right rib lesion improved several months later.

Discussion

On admission, the present patient was suspected of having acute-onset AIH, because ANA was $\times 320$, eight times the normal value, and IgG was 1793 mg/dL, 1.1 times the normal value. However, since she had a history

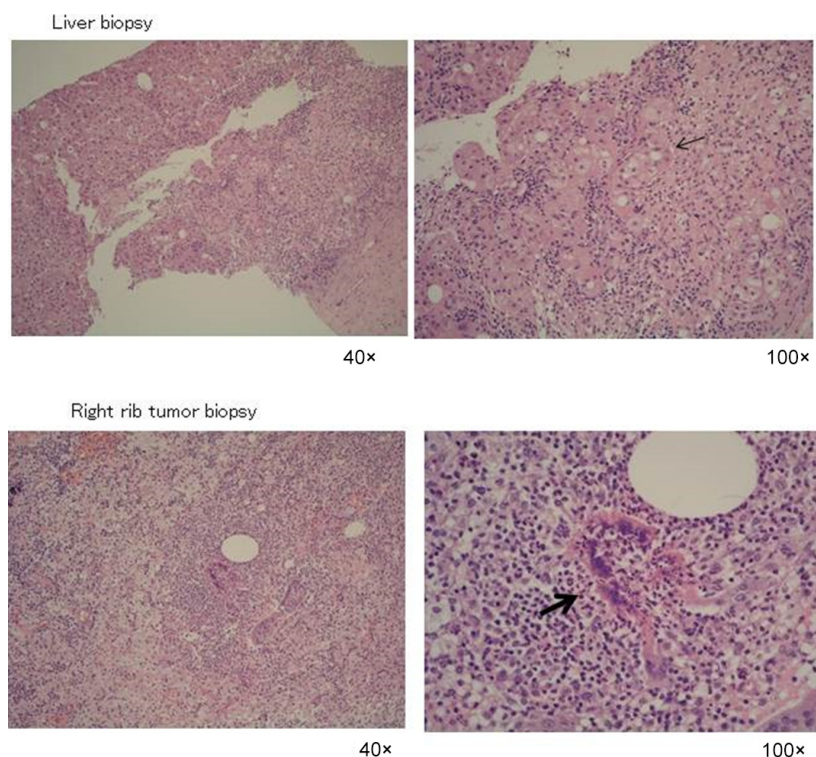


Figure 3. Liver biopsy finding: the portal tract is infiltrated with inflammatory cells, including plasma cells. The parenchymal architecture is partially disrupted. Surviving hepatocytes form gland-like rosettes (arrow). Right rib tumor biopsy finding: infiltration of lymphocytes and plasma cells and fibrosis are seen. Druse (arrow) with abscess formation is seen.

of taking various medicines, the possibility of drug-induced hepatic injury could not be excluded. As the patient scored <2 points on the diagnostic criteria scale for acute drug-induced hepatic injury established by Digestive Disease Week–Japan (DDW-J) [8], we believed that drug-induced hepatic injury seemed unlikely. According to her clinical course and the international diagnostic criteria for AIH [1], she was finally diagnosed with recovery from fulminant liver failure induced by acute-onset AIH, likely type 1 AIH. A nationwide survey of patients with fulminant hepatitis and late-onset hepatic failure in Japan revealed that outcomes were especially poor in AIH patients (the survival rate was 17.1% without liver transplantation) [9]. As this patient was older than 75 years and repeatedly developed stage 2 hepatic encephalopathy, we believed that she had poor prognosis. Regardless, she recovered from fulminant liver failure. Although this patient might have benefitted from corticosteroids and plasma exchange at the early stage of fulminant AIH, there is a little evidence for the efficacy of these treatments [6, 10].

Although this patient recovered from fulminant liver failure due to AIH, she developed suppurative inflammation of the hip joint due to MSSA and developed a right rib tumor due to actinomycosis. Actinomycosis is an uncommon chronic suppurative infection caused by anaerobic bacteria. Actinomycosis occurs in the cervicofacial (60–70%), abdominal (20–40%), and thoracic (9–20%) areas. Thus, the chest is a rare site for actinomycosis infection [11, 12]. Risk factors of actinomycosis are poor oral hygiene resulting in tooth decay, chronic lung disease, alcoholism, and other disorders resulting in reduced immunocompetence [7]. In the present case, immunosuppression due to corticosteroids might have contributed to the development of the right rib actinomycosis. An immunosuppressed status is a risk factor for invasive actinomycosis. However, the frequency of actinomycosis development secondary to the use of corticosteroid is unclear.

Actinomyces are part of the normal oral flora and colonize the human digestive tract [7, 13, 14]. Although the aspiration of saliva containing actinomyces is considered to be responsible for cases of pulmonary actinomycosis, the right rib actinomycosis in this patient might have occurred via hematogenous spread, as there was no invasion from the right lung. The hematogenous route of actinomyces spread is relatively rare [15]. This immunocompromised patient might have also developed hip infection due to hematogenous spread of MSSA. The diagnosis of thoracic actinomycosis is difficult, and the differential diagnosis includes pulmonary malignancy [7, 13, 14]. Thus, the diagnosis of actinomycosis depends on growth of the bacteria in culture and the discovery of sulfur granules in the pathologic specimen. In this

patient, observation of Druse with abscess formation in the pathologic specimen facilitated diagnosis. When treating patients with fulminant liver failure due to AIH, the possibility of such rare occurrences should be kept in mind.

In conclusion, this report described an interesting case of an osteolytic lesion secondary to actinomycosis after fulminant liver failure induced by AIH.

Conflict of Interest

None declared.

References

- Alvarez, F., P. A. Berg, F. B. Bianchi, L. Bianchi, A. K. Burroughs, E. L. Caucado, et al. 1999. International Autoimmune Hepatitis Group Report: review of criteria for diagnosis of autoimmune hepatitis. *J. Hepatol.* 31:929–938.
- Czaja, A. J., and H. A. Carpenter. 1993. Sensitivity, specificity and predictability of biopsy interpretations in chronic hepatitis. *Gastroenterology* 105:1824–1832.
- Crappier, R. M., P. S. Bhathal, I. R. Mackay and I. H. Frazer. 1986. 'Acute' Autoimmune Hepatitis. *Digestion* 34:216–225.
- Abe, M., T. Mashiba, M. Zeniya, K. Yamamoto, M. Onji, and H. Tsubouchi. 2011. Present status of autoimmune hepatitis in Japan: a nationwide survey. *J. Gastroenterol.* 46:1136–1141.
- Stravitz, R. T., J. H. Lefkowitz, R. J. Fontana, M. E. Gershwin, P. S. Leung, R. K. Sterling, et al. 2011. Autoimmune acute liver failure: proposed clinical and histological criteria. *Hepatology* 53:517–526.
- Miyake, Y., Y. Iwasaki, R. Terada, T. Onishi, R. Okamoto, N. Sakai, et al. 2006. Clinical characteristics of fulminant-type autoimmune hepatitis: an analysis of eleven cases. *Aliment. Pharmacol. Ther.* 23:1347–1353.
- Gadkowski, L. B., and J. E. Stout. 2008. Cavitory pulmonary disease. *Clin. Microbiol. Rev.* 21:305–325.
- Watanabe, M., and A. Shibuya. 2004. Validity study of a new diagnostic scale for drug-induced liver injury in Japan-comparison with two previous scales. *Hepathol. Res.* 30:148–154.
- Fujiwara, K., S. Mochida, A. Matsui, N. Nakayama, S. Nagoshi, and G. Toda. 2008. Intractable Liver Diseases Study Group of Japan. Fulminant hepatitis and late onset hepatic failure in Japan. Summary of 698 patients between 1998 and 2003 analyzed by the annual nationwide survey. *Hepatol Res* 38:646–657.
- Ichai, P., J. C. Duclos-Vallee, C. Guettier, S. B. Hamida, T. Antonini, V. Delvart, et al. 2007. Usefulness of corticosteroids for the treatment of severe and fulminant forms of autoimmune hepatitis. *Liver Transpl.* 13:996–1003.

11. Kim, S. R., L. Y. Jung, I. J. Oh, Y. C. Kim, K. C. Shin, M. K. Lee, et al. 2013. Pulmonary actinomycosis during the first decade of 21st century: cases of 94 patients. *BMC Infect. Dis.* 13:216.
12. Hachitanada, Y., A. Nakagawara, and K. Ikeda. 1989. An unusual wall tumor due to actinomycosis in child. *Pediatr. Radiol.* 20:96.
13. Mandell, G. L., J. E. Bennett, R. Dolin editors. 2010. Mandell, Douglas, And Bennett's Principles and Practice of Infectious Diseases. 7th ed. Philadelphia, PA, Churchill Livingstone Elsevier.
14. Valour, F., A. Senechal, C. Dupieux, J. Karsenty, S. Lustig, Breton, et al. 2014. Actinomycosis: etiology, clinical features, diagnosis, treatment, and management. *Infect. Drug Resist.* 7:183–197.
15. Smego, R. A. Jr, and G. Foglia. 1998. Actinomycosis. *Clin. Infect. Dis.* 26:1255–1261.