



Focal transitional mastitis in MR-Mammography: Preliminary findings



Clemens G. Kaiser^{a,*}, Matthias Dietzel^{b,c,1}, Pascal Baltzer^d, Anna K. Kaiser^e,
Thomas Henzler^a, Werner A. Kaiser^c, Julia Knautd^a

^a Institute of Clinical Radiology and Nuclear Medicine, University Medical Centre Mannheim, Medical Faculty Mannheim-University of Heidelberg, Germany

^b Institute of Diagnostic Radiology, University of Erlangen-Nuremberg, Erlangen, Germany

^c Institute of Diagnostic and Interventional Radiology, University Hospital Jena, Jena, Germany

^d Department of Biomedical Imaging and Image-Guided Therapy, Medical University Vienna, Austria

^e School of Social Science, University of Mannheim, Germany

ARTICLE INFO

Article history:

Received 28 April 2016

Accepted 3 May 2016

Available online 6 June 2016

ABSTRACT

Purpose: During clinical routine, we retrospectively discovered diagnostic criteria for “focal mastitis” in MR-Mammography (MRM). The aim of this study was to prospectively evaluate these criteria.

Methods: 1975 consecutive patients were examined between 01/2010 and 12/2011. 29 patients fit the diagnostic criteria of focal mastitis.

Results: In follow-up scans, 28 patients showed a complete remission of the previous findings. One patient was followed-up with persisting findings, which could histologically be correlated to an area of DCIS after biopsy.

Conclusion: The morphologic, kinetic and follow-up criteria we discovered seem to be a reliable diagnostic indicator for focal mastitis.

© 2016 The Author(s). Published by Elsevier Ltd. This is an open access article under the CC BY-NC-ND license (<http://creativecommons.org/licenses/by-nc-nd/4.0/>).

1. Introduction

The role of MRI as an imaging modality of the breast (MR-Mammography: MRM) has evolved to be increasingly important over the last 20 years. So far current guidelines of the ACR list among the specific indications for breast MR mainly the following [1,2]:

- 1) patients after operation or radiation
- 2) preoperative staging
- 3) cancer of unknown primary (CUP Syndrome)
- 4) genetic disposition (BRCA1 or 2, etc.)

The increasing use of MR-mammography (MRM) has ever since been accompanied by the discussion about its appropriate technique and optimal accuracy, especially its specificity. For a long time MRM has been attributed a high sensitivity, yet a low specificity.

The enhancement of a lesion strongly depends on the tumor biology (benign vs. malignant), the type and dose of contrast as well as the acquisition technique [3]. In order to reduce the number of

false positive and false negative cases, more and more morphological and kinetic signs have been evaluated in the past (including e.g. the Blooming sign, the Dark-T2w-TSE-Signal in the T2w-Turbo-Spin Echo sequences, the Hook sign, the perifocal edema sign, etc.) and need to be considered forming a diagnosis [4].

An additional finding in clinical routine over the last years was patients displaying a focal, non-malignant, non-mass enhancement in some areas, which had been included in the differential diagnosis of DCIS and often resulted in a benign histology, mostly including lymphocytic infiltration as a “side effect” (personal observations).

This report describes the finding of “MR-only-Mastitis”, in which by use of follow-ups as reference standards and sometimes histology an accompanying area of transitional focal enhancement was discovered. These findings are described and the differential diagnostic aspects for the differentiation between mastitis and DCIS and other malignant findings are listed.

2. Material and methods

All patients gave their written informed consent for the examination in this IRB approved study. As an additional indication we included “dense breasts” to the list of general MRM indication in an agreement with one of the major German insurance companies.

The first patient to be discovered with focal mastitis was a high-risk patient and had a history of two previous operations,

* Corresponding author at: University Medical Centre Mannheim, Medical Faculty Mannheim – University of Heidelberg, Theodor-Kutzer-Ufer 1-3, 68167 Mannheim, Germany.

E-mail address: clemens.kaiser@umm.de (C.G. Kaiser).

¹ Clemens G. Kaiser and Matthias Dietzel contributed equally to this work.

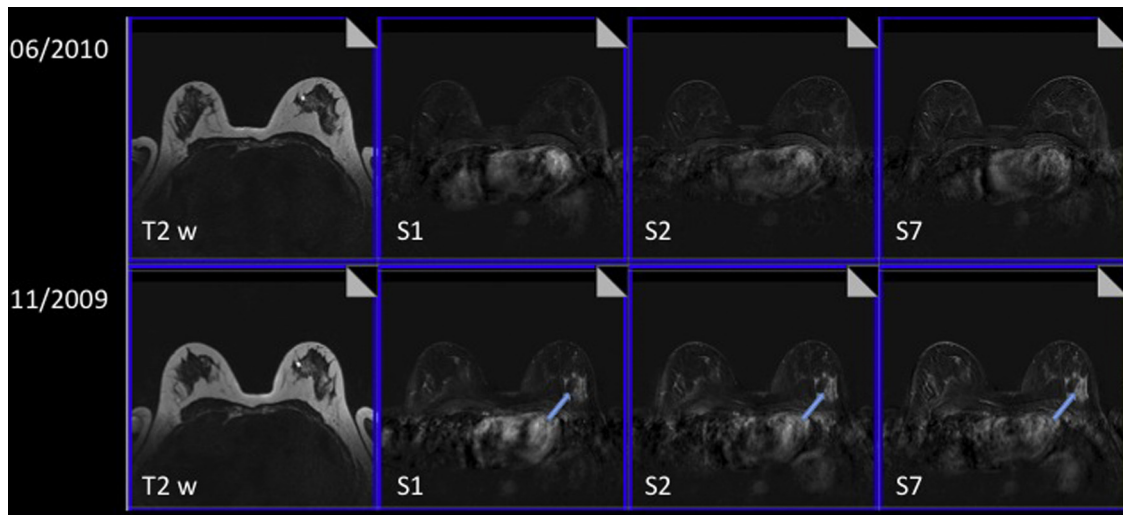


Fig. 1. From left to right: T2w TSE, subtractions 1, 2 and 7 min post the injection of 0.1 mmol/kg contrast medium. 51-year old patient with fibrocystic disease, presenting with a unilateral, patchy, non-focal area of benign enhancement in the outer aspect of the left breast in 11/2009 (blue arrows). Upon inquiry the patient reported an otitis of the right ear 3 months prior to the scan. In a follow-up examination after 6 months (06/2010) the area of enhancement could no longer be detected. (For interpretation of the references to colour in this figure legend, the reader is referred to the web version of this article.)

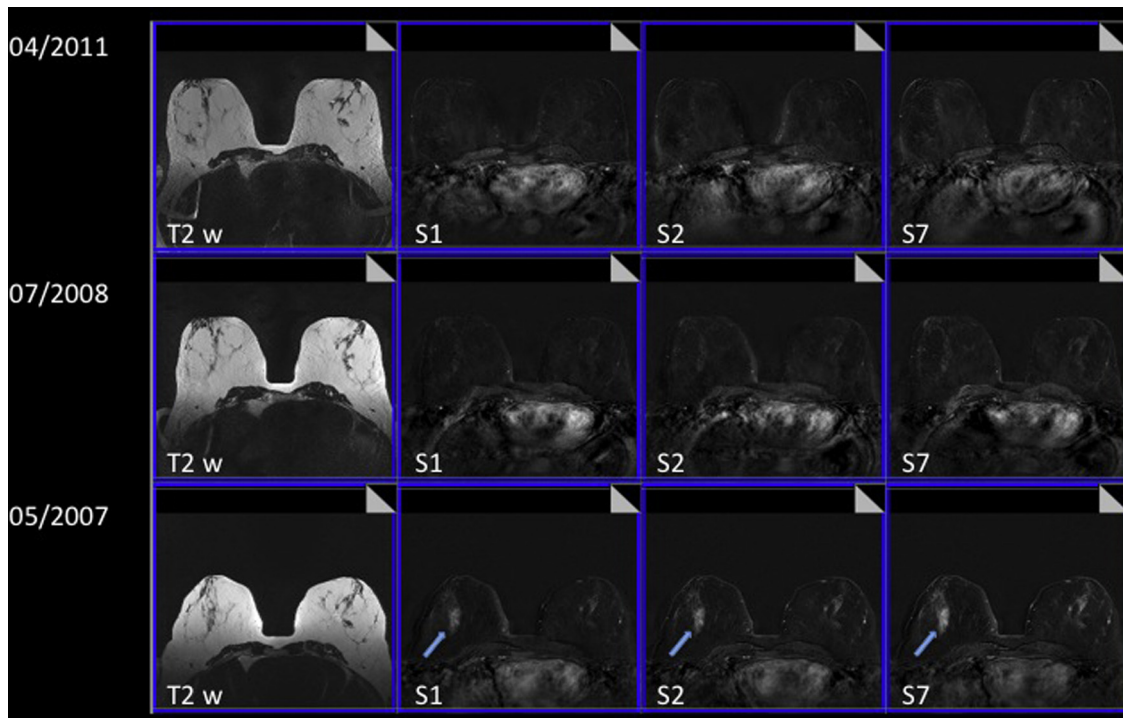


Fig. 2. From left to right: T2w TSE, subtractions 1, 2 and 7 min post the injection of 0.1 mmol/kg contrast medium. 54-year old patient, presenting with an area of unilateral, patchy, non-focal area of enhancement in the right breast in 05/2007 (blue arrows). The patient reported a laryngitis in the close history. In a follow-up examination after 12 months (07/2008) the findings had dissolved completely and did not reappear in further follow-up examinations (04/2011). (For interpretation of the references to colour in this figure legend, the reader is referred to the web version of this article.)

respectively 26 and 19 years before. In a follow-up study this patient displayed an area of focal enhancement with diffuse borders and continuously rising, benign curves. By chance we discovered that the patient also suffered from conjunctivitis of the eye at the same time. Due to the high-risk circumstances of this patient, she was followed-up on 4 weeks later (same time in her menstrual cycle) and by that time her conjunctivitis had declined. In the re-examination the focal area of enhancement had disappeared; the idea came up, that an inflammation in other areas of the body apart from the breast (ear, throat, bronchitis, arthritis, etc.) could be

responsible for transitional, focal, non-mass areas of enhancement in the breast. As this sign was further seen in a continuous number of 5 other patients, we conducted a prospective study in order to evaluate focal mastitis as a new sign.

Our finding is "accidental" and does not describe clinically manifest "classical" mastitis of the breast (reddish coloring of the skin in one breast, painful palpation, abscess etc.).

Summarizing, the study was retrospective for 5 patients in order to study early effects as well as morphology and kinetics of focal mastitis and prospective for a total of 29 patients between 01/2010

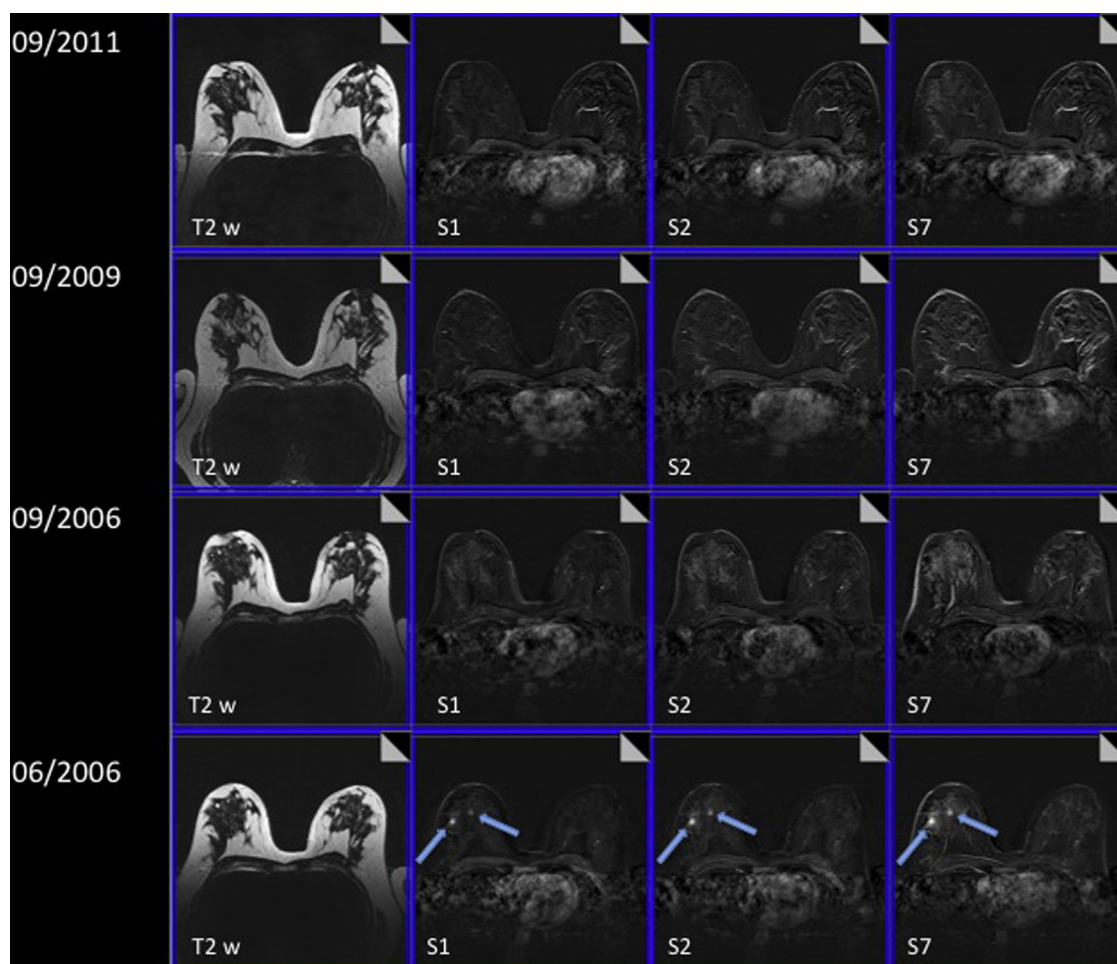


Fig. 3. From left to right: T2w TSE, subtractions 1, 2 and 7 min post the injection of 0.1 mmol/kg contrast medium.

55-year old patient with fibrocystic disease, presenting with two small unilateral, patchy, non-focal areas of enhancement in the right breast in 06/2006 (blue arrows). Upon inquiry, the patient reported she had suffered from viral respiratory tract infection (common flu) a few weeks before the MR-mammogram. In a follow-up examination after 3 months (09/2006) the findings had dissolved completely and did not reappear in further follow-up examinations (09/2009 and 09/2011). (For interpretation of the references to colour in this figure legend, the reader is referred to the web version of this article.)

Table 1
Examination protocol.

Sequence (Nr.)	1. Nat cor	2. Dynamic ^a tra	3. CM cor	4. T2-TSE	5. STIR
Weighting	T1	T1	T1	T2	T2 (T1, 150 ms)
Puls sequence	FLASH	FLASH	FLASH	TSE	TSE
Orientation	cor	transv	cor	transv	transv
TR (ms)	113	113	113	8900	8420
TE (ms)	4,6	4,6	4,6	207	70
Flip angle (°)	80	80	80	191	180
Slice thickness (mm)	3	3	3	3	3
Gap (mm)	0	0	0	0	0
Field of view (mm)	350	350	350	350	350
Nr. of slices	44	44	44	44	44
Matrix (Pixels)	230 × 256	307 × 384	230 × 256	435 × 512	326 × 384

^a Connotation: dynamic study before and after the i.v. application of 0,1 mmol Gd-DTPA per kg body weight within 10 s, followed by the injection of 30 ml saline via an automatic injector (Medrad, Spectris, Pittsburgh) with 3 ml/s.

and 12/2011. These patients would usually not have a history of clinical mastitis, yet displayed the following findings:

1. A slight, focal, unilateral non-mass and area of progredient enhancement without cancer corner or washout sign (see Figs. 1–6).
2. When inquired about a recent history of inflammation or infection, patients would report about otitis, arthritis, sinusitis, inflammatory processes of the skin, etc.

3. They would also describe a subtle discomfort they had registered in the affected breast upon forceful palpation.
4. Dissolving or at least decline after a waiting period of at least 3 months.

Since serological parameters (CRP) occurred to be unspecific in the retrospectively analyzed patients, CRP was therefore not included into the evaluation of the prospective study cases.

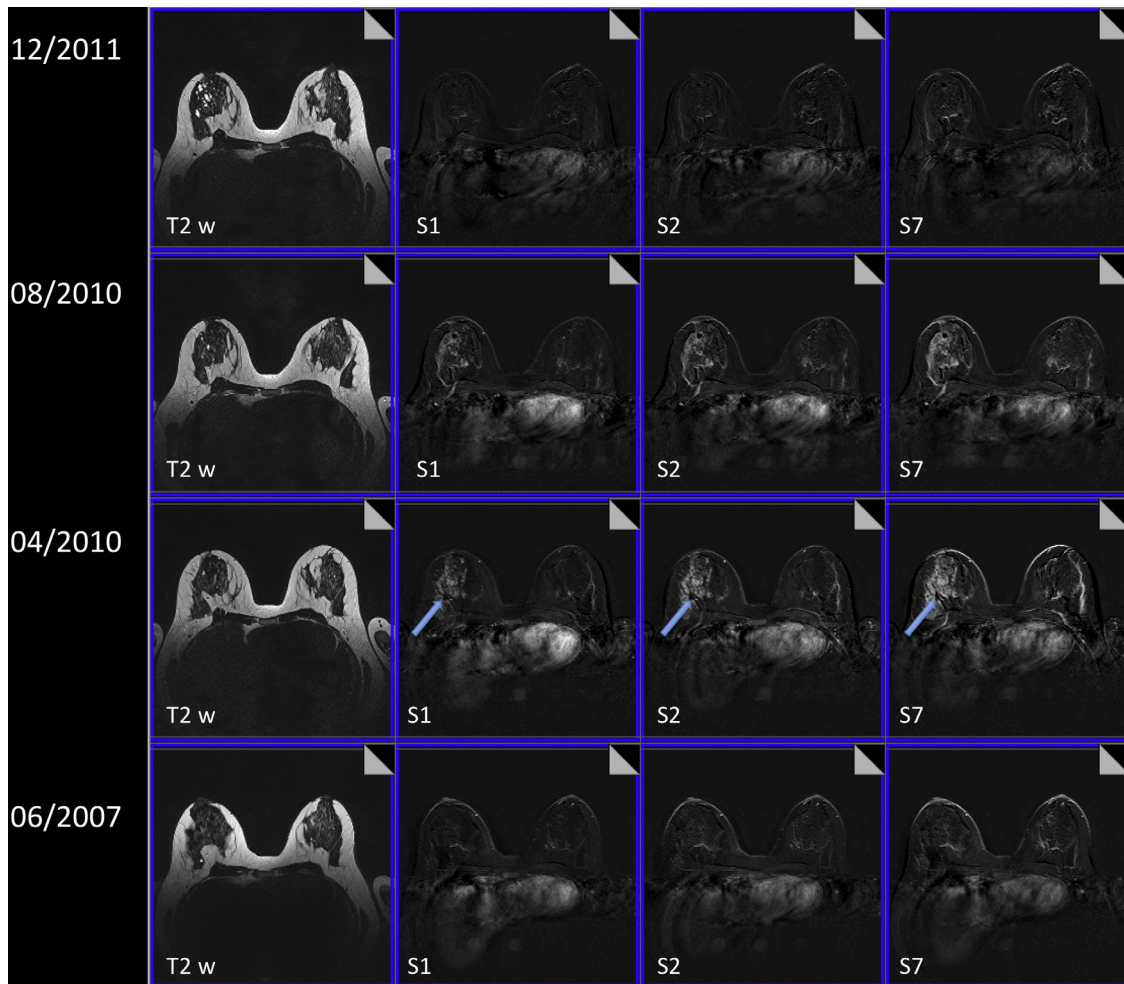


Fig. 4. From left to right: T2w TSE, subtractions 1, 2 and 7 min post the injection of 0.1 mmol/kg contrast medium. 44-year old patient with fibrocystic disease, presenting with a large unilateral, patchy, non-focal area of enhancement in the right breast in April 2010 (blue arrows) after an inconspicuous MR-mammogram in 06/2007. Upon inquiry, the patient reported she had suffered from a Hordeolum of the right eye two months prior to the examination. In a follow-up examination after 4 months (08/2010) the findings were regredient. In a further follow-up after 14 months (12/2011), the previous findings had dissolved. (For interpretation of the references to colour in this figure legend, the reader is referred to the web version of this article.)

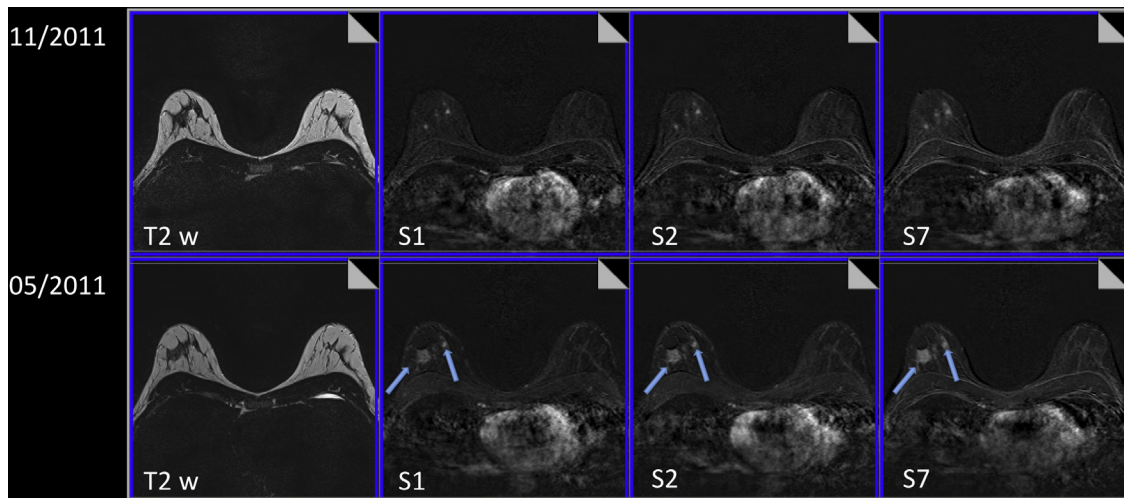


Fig. 5. From left to right: T2w TSE, subtractions 1, 2 and 7 min post the injection of 0.1 mmol/kg contrast medium. 44-year old patient, presenting with two areas of unilateral, patchy, benign enhancement in the lower aspects of the right breast in 05/2011 (blue arrows). With a patient history of tonsillitis 2 months prior to the MR-Mammogram, a follow-up examination after 6 months in 11/2011 was conducted. See Fig. 6 for a magnification of the right breast. (For interpretation of the references to colour in this figure legend, the reader is referred to the web version of this article.)

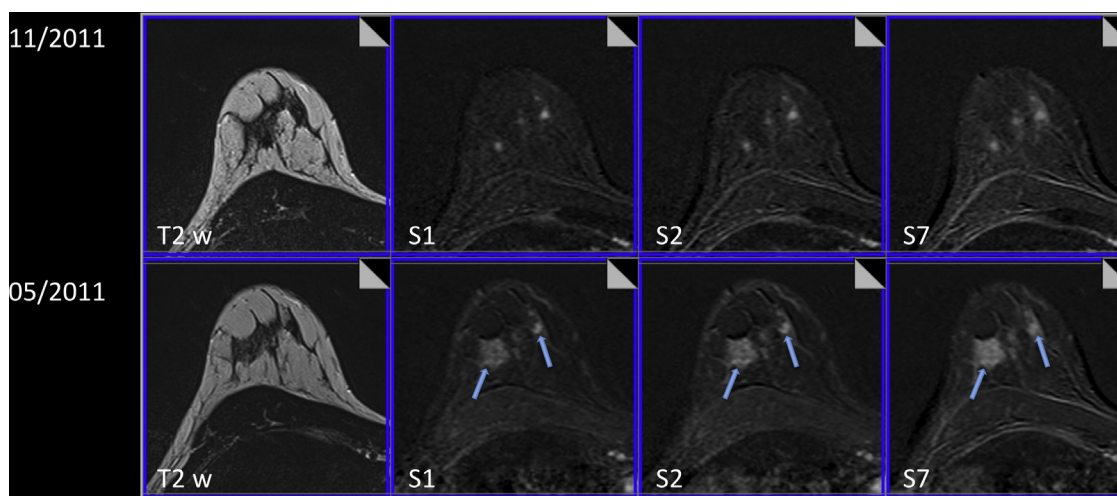


Fig. 6. Magnification of the right breast (Fig. 5). From left to right: T2w TSE, subtractions 1, 2 and 7 min post the injection of 0.1 mmol/kg contrast medium. 44-year old patient, presenting with two areas of unilateral, patchy, benign enhancement in the lower aspects of the right breast in 05/2011 (blue arrows). With a patient history of tonsillitis 2 months prior to the MR-Mammogram, a follow-up examination after 6 months in 11/2011 was conducted. The larger area of enhancement in the outer aspect of the right breast was regredient in size, while the small focus in the inner aspect of the right breast stayed constant in morphology and kinetics. (For interpretation of the references to colour in this figure legend, the reader is referred to the web version of this article.)

The standard reference was a follow-up MRM-evaluation after a waiting period of 3–6 months: these diagnostic focal, non-mass areas of enhancements as well the discomfort during palpation dissolved or declined in the follow-up MRM examination after successful treatment or self-healing of the reported inflammatory process. In case of these MRM findings a “focal mastitis” was diagnosed (Fig. 1). In none of the cases of this study an accompanying inflammatory cancer was found; no patient showed an increase (1 case of consistent enhancement) of either the MRM- or the clinical symptoms.

2.1. MR-Scanner

All MRM exams were performed with a 1.5T-MR Scanner (Siemens, Avanto) using the following standard protocol (Table 1), as described in other publications [5].

3. Results

Between 07/2010 and 12/2011, 1975 breast patients have been examined in our University Hospital. Among these 1975 patients the total amount of 29 patients showed signs of a distinct focal mastitis (unilateral enhancement, progredient enhancement, patchy-confluent enhancement, no corner sign, reversible after antibiotic treatment or waiting period, slight unilateral discomfort during forceful palpation). These patients were recommended MRM follow-up examination after 6 months in order to evaluate, whether or not the “lesion” had dissolved. In the follow-up the following results were received.

28 patients showed a complete or nearly complete dissolving of the previous findings. 1 patient was found to display a progredient area of enhancement, which histologically proved to be a small focus of DCIS after biopsy.

4. Discussion

MRM is a highly sensitive technique to detect changes in the breast, induced by vascularization. Among these changes are malignant lesions, but also changed vascularization due to inflammatory processes. To our knowledge, this study was the first to describe this

accompanying phenomenon, which are slight and distinct, but have to be considered in the differential diagnosis of non-mass lesions.

In the literature the morphological and kinetic signs of non-puerperal mastitis have been known for some time, however most of these reports have been severe granulomatous mastitis-cases and abscesses [6]. As a hallmark of “focal transitional mastitis”, we assessed a unilateral area of slight, non-mass and continuous enhancement without border sign (i.e. no separation between segments of the breast – an indication of DCIS), an inflammatory anamnesis as well as slight discomfort upon palpation of the affected breast in contrast to the contralateral breast; in addition, the patient had reported about an infection in other parts of the body upon questioning. Since this type of enhancement appeared to dissolve in follow-up studies it was considered the result of focal inflammation.

In our experience accompanying hormone- or menstrual effects are furthermore unlikely to cause such enhancement, as they rather tend to affect both breasts and therefore are not relevant for the differential diagnosis of lesions imaged with our technique.

The detection of focal transitional mastitis in MR-Mammography is probably only possible due to the very high contrast and sensitivity towards changes after contrast injection of the MR-technique. It is also an example how a medical diagnosis is made by a combination of imaging findings, clinical examination, the evaluation of the patients history and results of follow-up examinations. Only when these effects are not regredient in follow-up examinations, a biopsy should be recommended to test for a malignant finding. The knowledge of this diagnosis (focal transitional mastitis) seems to be important in order to reduce the number of unnecessary biopsies in the future.

5. Conclusion

Among the differential diagnosis of enhancing breast lesions, a focal area of transitional inflammation needs to be added to the list of differential diagnosis. Typical signs are: continuous unilateral enhancement, lack of border signs, inflammatory anamnesis, accompanying discomfort upon palpation of the affected breast. The patient should be followed-up on for correlation of focal inflammation after a time period of not longer than 6 months (eventually applying antibiotic treatment), in order to rule out DCIS or a

growing malignant lesion. Further studies are necessary to clarify whether these findings are dependent on different technical aspects or varying patient groups.

Conflict of interest

The authors declare that they have no conflict of interest.

Acknowledgment

Published in part (only abstract) during the “6th International Congress on MR-Mammography” in Jena, Germany (27–29 September, 2012) [7].

References

- [1] E.S. Burnside, E.A. Sickles, L.W. Bassett, et al., The ACR BI-RADS® experience: learning from history, *J. Am. Coll. Radiol. JACR* 6 (12) (2009) 851–860.

- [2] S.D. Edwards, J.A. Lipson, D.M. Ikeda, J.M. Lee, Updates and revisions to the BI-RADS magnetic resonance imaging lexicon, *Magn. Reson. Imag. Clin. N. Am.* 21 (3) (2013) 483–493.
- [3] T. Pabst, W. Kenn, W.A. Kaiser, D. Hahn, Understanding why contrast enhancement in dynamic MRI is not reproducible: illustration with a simple phantom, *Breast J.* 7 (3) (2001) 166–170.
- [4] W.A. Kaiser, *Signs in MR-Mammography*, 1st ed., Springer, 2009, 2008. Corr. 2nd printing, 400 p.
- [5] C. Kuhl, The current status of breast MR imaging Part I. Choice of technique, image interpretation, diagnostic accuracy, and transfer to clinical practice, *Radiology* 244 (2) (2007) 356–378.
- [6] H.A.T. Al-Khawari, H.A. Al-Manfouhi, J.P. Mada, et al., Radiologic features of granulomatous mastitis, *Breast J.* 17 (6) (2011) 645–650.
- [7] C.G. Kaiser, J. Krammer, S.O. Schönberg, W.A. Kaiser, K. Wasser, Focal transitional mastitis in MR-mammography: preliminary findings, *Eur. J. Radiol.* 81 (Suppl. 1) (2012) S72–73.