

Received: 2014.05.19
Accepted: 2014.06.16
Published: 2014.10.13

Bamboo Joint-Like Appearance of the Stomach: A Stable Endoscopic Landmark for Crohn's Disease Regardless of Anti-Tumor Necrosis Factor alpha Treatment

Authors' Contribution:

Study Design A
Data Collection B
Statistical Analysis C
Data Interpretation D
Manuscript Preparation E
Literature Search F
Funds Collection G

BCEF Keiichi Hashiguchi
ABCEF Fuminao Takeshima
DE Yuko Akazawa
BD Kayoko Matsushima
B Hitomi Minami
B Naoyuki Yamaguchi
D Ken Shiozawa
C Ken Ohnita
CD Tatsuki Ichikawa
DE Hajime Isomoto
EG Kazuhiko Nakao

Department of Gastroenterology and Hepatology, Graduate School of Biomedical Sciences, Nagasaki University, Nagasaki, Japan

Corresponding Author: Fuminao Takeshima, e-mail: ftake@nagasaki-u.ac.jp
Source of support: Departmental sources

Background: Bamboo joint-like appearance is a common yet easy-to-miss endoscopic finding in the stomach of patients with Crohn's disease (CD). Bamboo joint-like appearance (BJA) is characterized by swollen longitudinal folds transversed by erosive fissures or linear furrows. However, whether BJA is observed during the remission stage of CD and during the active stage is unclear. In particular, the relationship between the course of BJA and anti-tumor necrosis factor (TNF) α therapy has not been studied. We aimed to evaluate the course of BJA in CD patients treated with anti-TNF α therapy.


Material/Methods: We examined 22 CD patients who underwent esophagogastroduodenal endoscopy before undergoing anti-TNF α treatment. We evaluated the changes in BJA, clinical activity using the CD activity index (CDAI), and endoscopic activity using the simple endoscopic score for CD (SES-CD) from 6 months to 1 year after anti-TNF α therapy.

Results: Fifteen of 22 patients (68.1%) presented with BJA in the stomach, 13 of whom received follow-up esophagogastroduodenal endoscopy after anti-TNF α therapy. The mean CDAI and SES-CD scores significantly improved after anti-TNF α therapy ($P < 0.01$). Despite the marked improvements in clinical and endoscopic findings, the BJA of the stomach remained unchanged in all the patients.

Conclusions: The findings indicate that BJA is frequently observed in the stomach of CD patients, regardless of whether the patient has active disease or is in remission, even after anti-TNF α therapy. Thus, BJA may be a stable endoscopic landmark in CD.

MeSH Keywords: **Crohn's Disease • Diagnosis • Endoscopy, Gastrointestinal**

Full-text PDF: <http://www.medscimonit.com/abstract/index/idArt/891060>

 2485

 1

 5

 27



Background

Crohn's disease (CD) is a chronic inflammatory bowel disease, with an unknown etiology, that can affect any part of the gastrointestinal tract. Although CD findings are typically observed in the lower gastrointestinal tract, it has recently been reported that the upper gastrointestinal tract can be affected in these patients as well. Aphthous erosions, polypoid lesions, and notched appearance are representative findings of duodenal involvement in CD [1–4]. With regard to gastric involvement, Yokota et al. [5] first indicated that the presence of “bamboo joint-like erosions” was indicative of CD. After further study, they reported that “bamboo joint-like erosions” and “bamboo joint-like furrows” are subtypes of “bamboo joint-like appearance” (BJA) [6]. The BJA is characterized by swollen longitudinal folds transversed by erosive fissures or linear furrows, which are most frequently found at the gastric body and cardia. BJA is reportedly detected on the lesser curvature of the gastric body and cardia in 39.1–65.2% of CD patients [6–11]. An image of representative BJA of the stomach is shown in Figure 1. Since the BJA is a characteristic finding of CD, gastroduodenal lesions – such as BJA and notches in the Kerckring's folds in the duodenum – are considered to be subfindings for the diagnosis of CD in Japan [12]. Thus, for evaluating the location and status of CD, esophagogastroduodenal endoscopy (EGD) and colonoscopy (CS) are recommended at diagnosis and during follow-up. However, these diagnostic subfindings are not used at all in Western countries. In addition, little is known about the presence and characteristics of BJA during the remission stage of CD as compared to during the active stage.

Anti-tumor necrosis factor (TNF) α therapy has recently changed the CD treatment paradigm, and may be able to change the natural history of CD. Reports have shown that anti-TNF α therapy can induce rapid healing of mucosal lesions in CD [13,14]. Other studies have indicated that mucosal healing can be considered a clinically relevant end-point, and have demonstrated the importance and impact of top-down therapy [15]. Nevertheless, the relationship between the course of BJA and anti-TNF α therapy has not been described. In the present study, we aimed to evaluate the course of the BJA in CD patients treated with anti-TNF α therapy.

Material and Methods

Study design

A retrospective analysis and partially prospective analysis were performed. As noted above, we performed EGD and CS before the initiation of anti-TNF α therapy. From 6 months to 1 year after anti-TNF α therapy, we performed EGD and CS for a second time to evaluate the efficacy of anti-TNF α therapy. EGD

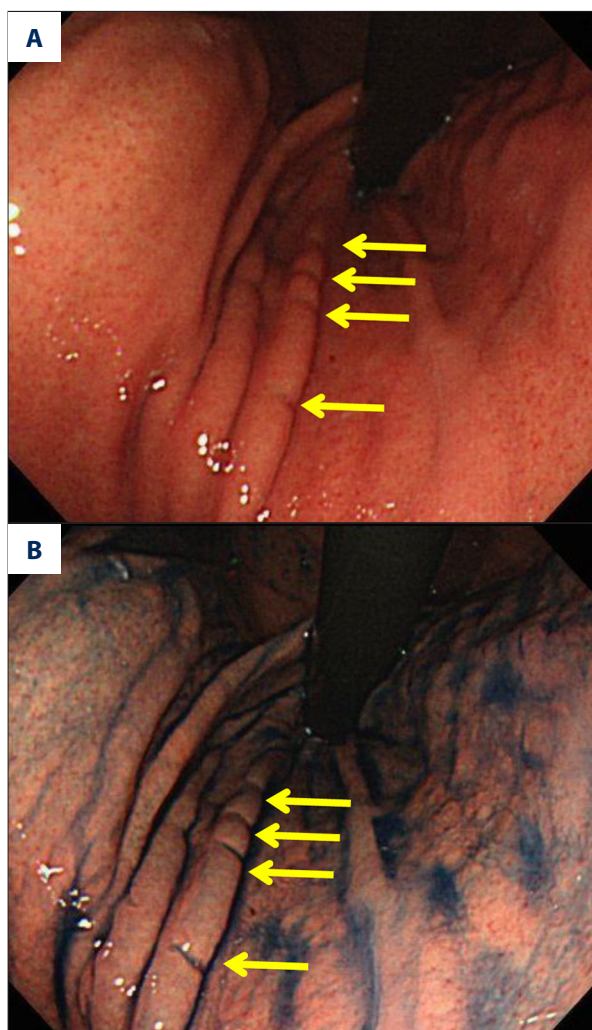


Figure 1. Representative bamboo joint-like appearance (BJA) of the stomach. The BJA is characterized by swollen longitudinal folds transversed by erosive fissures or linear furrows, which are most frequently found at the gastric body and cardia (arrow). BJA is easier to visualize when the dye-spraying technique with 0.1% indigo carmine is used (B), rather than when assessing a white-light image (A).

was performed with a direct-viewing endoscope. The presence of BJA in the gastric body and cardia was carefully assessed using the dye-spraying technique with 0.1% indigo carmine.

Patients

All CD patients had been diagnosed on the basis of clinical, endoscopic, radiographic, and histologic findings. Twenty-two CD patients who were scheduled to undergo anti-TNF α therapy and who underwent EGD between September 2008 and April 2013 were included in the study. Patients were included regardless of the duration of CD, a history of anti-TNF α use, and whether they underwent other therapies.

Treatment

Infliximab or adalimumab was initiated due to flares or penetrating complications. Infliximab was administered at a dose of 5 mg/kg at 0, 2, and 6 weeks, and then every 8 weeks. In patients with a recurrent flare or continued lack of response, the dosage of infliximab was increased to 10 mg/kg. Adalimumab was administered at a dose of 160 mg in week 0, 80 mg in week 2, and then 40 mg every other week. Other medications, such as immunosuppressants and mesalamine, were continued during anti-TNF α therapy.

Outcome measurement

The efficacy of anti-TNF α therapy was evaluated clinically using the CD activity index (CDAI) and endoscopically using the simple endoscopic score for CD (SES-CD) before and after anti-TNF α therapy [16]. Changes in BJA were also evaluated by EGD using the dye-spraying technique with 0.1% indigo carmine. The follow-up period was 6 months to 1 year after the initiation of anti-TNF α therapy. We defined mucosal healing as the observation of complete or partial reduction of ulcerations upon endoscopic examination [17].

Statistical analysis

JMP Pro version 10.0.2 software (SAS Institute, Cary, NC, USA) was used for all analyses. Wilcoxon signed-ranks tests were used for comparison of CDAI and SES-CD scores between the pre-treatment and post-treatment periods. *P* values of <0.05 were considered significant.

Ethical considerations

Written informed consent was obtained from all patients before EGD and CS. The study was approved by the ethics committee of the Nagasaki University Hospital (Office for Human Research Protection Number: IORG 0007678).

Results

Patient characteristics

Of the 22 included CD patients, 15 (68.1%) presented with BJA in the stomach, 13 of whom received follow-up EGD after anti-TNF α therapy. The clinical features of these 13 CD patients are shown in Table 1. They comprised 10 men and 3 women (age range, 20–57 years). The duration of CD ranged from 1.5 to 26 years. The disease location was the intestine in 3 patients and the intestine and colon in the remaining 10 patients. The disease activity grade, according to the European Crohn's and Colitis Organization's criteria, was moderate in 4 patients

Table 1. Baseline patient characteristics.

Gender (male/female)	10/3
Age in years, mean \pm SD	36.0 \pm 10.1
Duration of Crohn's disease in years, median \pm SE	13.5 \pm 2.1
Location of disease	
Intestine	3 (23.0%)
Intestine and colon	10 (76.9%)
Steroid	
No	13 (100.0%)
Yes	0 (0.0%)
Immunosuppressant	
No	8 (61.5%)
Yes	5 (38.4%)
Previous anti-TNF alpha use	
No	10 (76.9%)
Yes	3 (23.0%)
Anti-TNF alpha therapy	
Infliximab	4 (30.7%)
Adalimumab	9 (69.2%)

SD – standard deviation; SE – standard error; TNF – tumor necrosis factor.

and mild in 9 patients [18]. None of the patients had epigastric symptoms before anti-TNF α therapy. Four patients received infliximab therapy, and the other 9 patients were treated with adalimumab. In 4 patients, biopsy specimens were obtained from the BJA portion, and histological evaluations were performed. Histological examination of the BJA portion showed mild lymphoid aggregates, mild edema in the superficial portion of the surrounding lamina propria, and blood vessel dilatation. Granulomas were not detected in any of the cases.

Changes in the BJA, CDAI, and SES-CD after anti-TNF α therapy

The median CDAI score significantly decreased from 186 \pm 19.1 to 82.4 \pm 13.3 (*P*=0.0002) after anti-TNF α therapy (Figure 2). Twelve cases (92.3%) achieved and maintained remission (CDAI score <150). The median SES-CD score also improved significantly, from 15 \pm 2.7 to 8 \pm 1.6 (*P*=0.001, Figure 3). Mucosal healing in the intestine and colon was observed in 7 cases (53.8%); 5 had been treated with adalimumab and 2 had been treated with infliximab. Only 1 case had moderate disease activity,

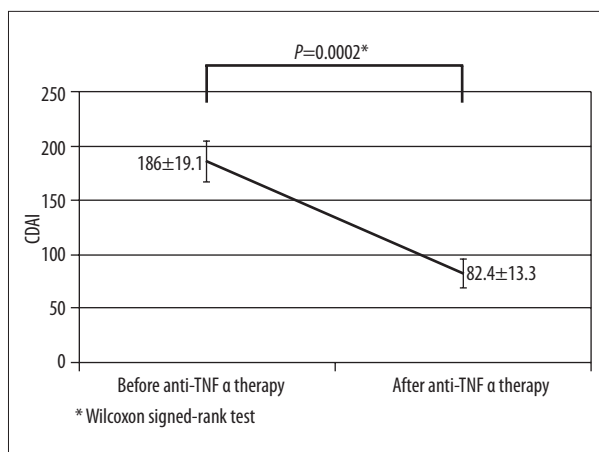


Figure 2. Changes of Crohn's disease activity index (CDAI) after anti-tumor necrosis factor (TNF) α therapy. The median CDAI score significantly decreased from 186 ± 19.1 to 82.4 ± 13.3 ($P=0.0002$) after anti-TNF α therapy.

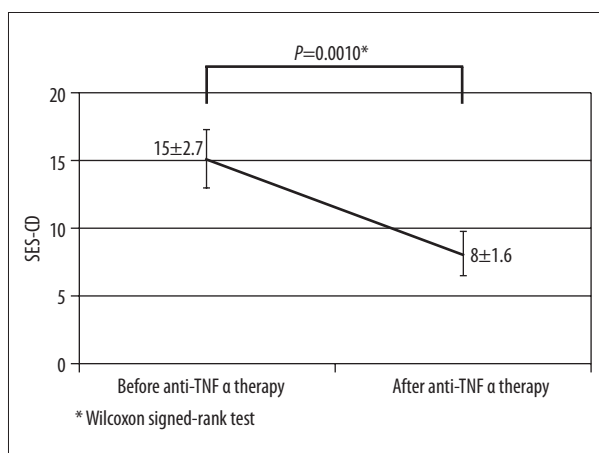


Figure 3. Changes in simple endoscopic score for CD (SES-CD) after anti-tumor necrosis factor (TNF) α therapy. The median SES-CD score significantly decreased from 15 ± 2.7 to 8 ± 1.6 ($P=0.001$) after anti-TNF α therapy.

whereas the other 6 cases had mild disease activity. Two of the 7 cases had received previous anti-TNF α therapy.

Notably, despite the marked improvements detected during clinical and endoscopic evaluation, the BJA of the stomach remained unchanged in all the cases (Figure 4). Representative images of the BJA before and after successful anti-TNF α treatment are shown in Figure 5. The case illustrated in Figure 5 is of a 20-year-old man with an 8-year history of CD. Before anti-TNF α treatment, he had severe abdominal pain and frequent diarrhea (3 times a day). His serum C-reactive protein (CRP) level was 11.24 mg/dL. Colonoscopy indicated extensive longitudinal ulcers throughout the entire colon. EGD showed a BJA on the lesser curvature of the gastric body and cardia. He received adalimumab therapy. One year after the initiation

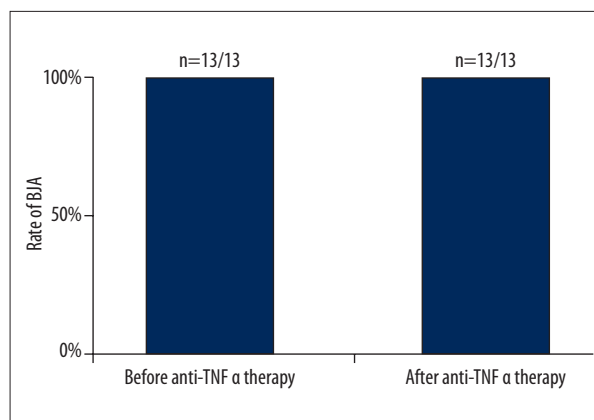


Figure 4. Changes in bamboo joint-like appearance (BJA) after anti-tumor necrosis factor (TNF) α therapy. BJA of the stomach remained unchanged in all the cases.

of adalimumab treatment, his symptoms had significantly improved – he reported having normal stools once per day and no abdominal pain. In addition, his serum CRP level had decreased to 0.03 mg/dL, and his CDAI score markedly decreased from 321.8 to 19 after adalimumab therapy. Follow-up CS showed multiple scars in his colon and no ulcers; thus, mucosal healing of the colon had been achieved. His SES-CD score also improved remarkably, from 34 to 2. Although anti-TNF α treatment was considered successful in the colon for this patient, his EGD findings of BJA in the stomach remained unchanged.

Discussion

BJA was first reported as the most representative gastroduodenal endoscopic finding of CD by Yokota et al. [6]. They defined BJA as swollen longitudinal folds transversed by erosive fissures or linear furrows, which are most frequently found at the gastric body and cardia. Although BJA is relatively unrecognized in Western countries, gastroduodenal lesions – such as BJA and notches in the Kerckring's folds in the duodenum – are included as subfindings for the diagnosis of CD in Japan [12]. BJA is reportedly observed on the lesser curvature of the gastric body and cardia in 39.1–65.2% of CD patients [6–11]. In contrast, BJA has been found in only 1.1% of patients without CD,⁷ 5% of ulcerative colitis patients, and 0% of gastroesophageal reflux disease patients [9]. These data indicate that BJA is a characteristic endoscopic finding in CD patients. Although there are few existing reports, previous studies have shown that BJA is found not only in the stomach but also in the descending duodenum in some CD patients [19].

Since BJA is a subtle change, and the lesser curvature of the gastric body and cardia is difficult to examine, previous studies have suggested using a side-viewing endoscope or an oblique-viewing endoscope while adjusting the intragastric air, and

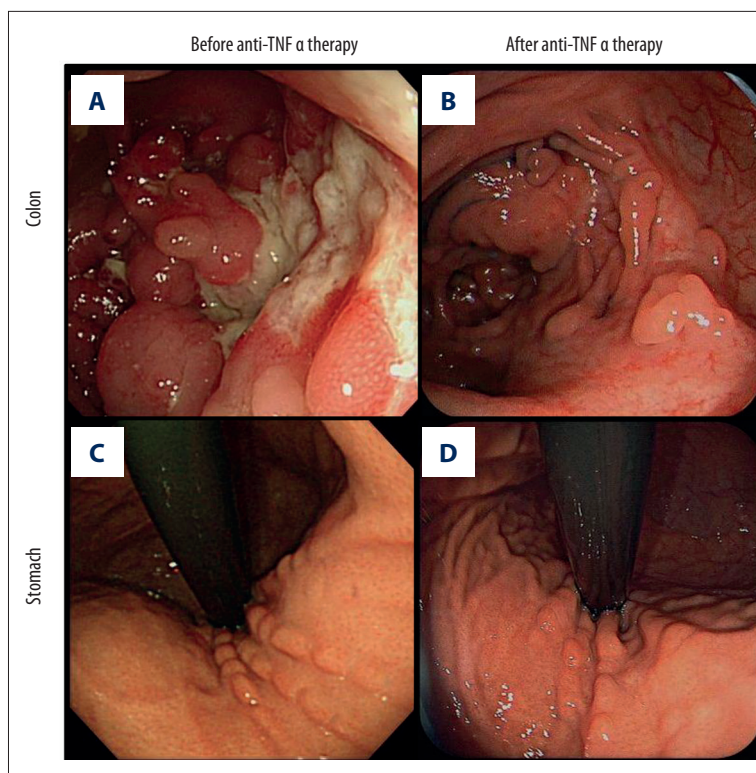


Figure 5. Representative endoscopic findings before and after anti-tumor necrosis factor (TNF) α therapy. Colonoscopy findings showed mucosal healing of the colon after successful anti-TNF α treatment (**A, B**). Nevertheless, the bamboo joint-like appearance (BJA) of the stomach remained unchanged (**C, D**).

using the dye-spraying technique with 0.06% indigo carmine [6,11]. However, it is critical that particular attention be given to this region. Indeed, in the present study, we were able to identify the BJA with a direct-viewing endoscope using the dye-spraying technique with 0.1% indigo carmine.

Yokota et al. [6] reported that histological examination of BJA can reveal lymphoid aggregates, severe edema in the superficial portion of the surrounding lamina propria, lymphoid ductal dilatation, lymphangioma, and the fundic gland hyperplasia. Hirokawa et al. [7] reported that histological examination of the BJA showed sharp, fissure-like erosions or mucosal clefts in 50% of 14 CD patients, and epithelioid granuloma was noted at the base of fissure-like erosions in certain patients. The detection rate for granulomas based on biopsy from BJA reportedly varies from 9.1% to 45.5% [6–8,10]. In our 4 cases, no granulomas were detected on examination of BJA biopsy samples, which may be due to the small numbers of samples included. As stated earlier, the BJA portion consists of longitudinal folds and erosive fissures or linear furrows, together with mucosal swelling. Previous reports in Japan have indicated that longitudinal folds transversed by linear furrows without swelling are observed in 10% of healthy individuals. This implies that the BJA may originate from pre-existing non-specific longitudinal folds transversed by linear furrows, which may be exacerbated by the occurrence of edema in CD [6].

Previous studies have demonstrated that the occurrence of the BJA does not correlate with sex, age, age at onset of CD,

the site of CD in the small and/or large bowel, *Helicobacter pylori* infection, or medications being taken at the time of EGD [6,20]. However, the course of BJA has not been analyzed in detail. Kuwaki et al. [21] showed that the BJA in the stomach of a CD patient remained unchanged in remission and active stages. In addition, Iizuka et al. [22] identified BJA during the remission stage in the stomach of a CD patient receiving an elemental diet. Moreover, Watari et al. [8] observed 24 CD patients who underwent EGD, and found that 7 patients did not show BJA during their initial EGD, but that 2 of the patients exhibited BJA during their second EGD examination. The BJA did not disappear in any of the patients, and no significant relationship has been reported between the changes in BJA and the CDAI score. Hirata et al. [10] reported that linear furrows and longitudinal folds become gradually clear during the natural course of CD. In agreement with these studies, our study showed that the BJA is frequently noted in the stomach of CD patients, regardless of whether the patient has active disease or is in remission after anti-TNF α therapy.

Anti-TNF α therapy can induce rapid and sustained mucosal healing, and may contribute to fistula closure in certain CD patients [13]. At present, mucosal healing is considered to be a clinically relevant end-point [15]. The magnitude of the effect of inducing and maintaining mucosal healing with anti-TNF α therapy is difficult to assess because of the different definitions of mucosal healing used, differences in study designs, and differences in the timing of endoscopic evaluations [14].

The rates of mucosal healing in studies of anti-TNF α therapy are reported to range from 24.2% to 73.1% [17,23–26]. The frequency of mucosal healing in the present study was similar to that observed in previous studies. Nevertheless, the BJA of the stomach remained unchanged in all patients after anti-TNF α therapy, even when mucosal healing was achieved.

To the best of our knowledge, we are the first to publish data indicating that BJA persists even after successful anti-TNF α therapy. Thus, BJA may be a stable endoscopic mark of CD, regardless of treatment and status. In fact, Moriyama et al. [11] compared mucosal proinflammatory cytokine and chemokine expression (interleukin [IL]-1 β , IL-8, and RANTES) between CD patients with BJA of the stomach and those with duodenal erosion. Interestingly, although duodenal mucosal IL-1 β and IL-8 expression levels were significantly higher in patients with duodenal erosion than in those without duodenal erosion, there were no such differences noted in terms of BJA of the stomach. Furthermore, Moriyama's study reported that gastroduodenal lesions remained unchanged after the administration of famotidine. Thus, they suggested that BJA and other gastroduodenal abnormalities in CD have distinct pathogenic mechanisms. In fact, a previous case report showed that aphthous lesions in the antrum of the stomach in a CD patient disappeared after infliximab therapy [27]. The BJA might be an irreversible change, and may represent a landmark, not for disease activity, but for disease development. It is possible that the presence of BJA may not cause clinical problems, because the BJA itself does not cause any symptoms. Thus, BJA may not be suitable as a marker to evaluate the effectiveness of anti-TNF α therapy.

We consider that the presence of the BJA in the stomach is a useful indicator for early diagnosis of CD. Actually, prior reports in Japan have presented a few cases in which CD had been diagnosed based on the presence of BJA. Thus, BJA may also be beneficial for early diagnosis of CD, particularly for patients lacking typical findings in the intestine and colon.

This was a retrospective and partially prospective study and had a small sample size. One of the limitations of the current study is that some patients who did not receive EGD before anti-TNF α therapy were excluded, which may have resulted in selection bias. Nevertheless, the frequency of the BJA observed in the present study was similar to that of previous studies [6–11]. However, further studies including larger numbers of CD patients are required.

Conclusions

The results of this study suggest that the BJA is frequently found in the stomach of CD patients, regardless of whether CD is active or in remission. BJA may be a stable endoscopic landmark in CD patients, even after successful anti-TNF α therapy. However, further prospective studies are required to confirm the clinical significance of these findings.

Conflict of interest

The authors report no conflict of interest regarding this manuscript.

References:

1. Nugent FW, Roy MA: Duodenal Crohn's disease: an analysis of 89 cases. *Am J Gastroenterol*, 1989; 84: 249–54
2. Cameron DJ: Upper and lower gastrointestinal endoscopy in children and adolescents with Crohn's disease: a prospective study. *J Gastroenterol Hepatol*, 1991; 6: 355–58
3. Lenaerts C, Roy CC, Vaillancourt M, Weber AM et al: High incidence of upper gastrointestinal tract involvement in children with Crohn disease. *Pediatrics*, 1989; 83: 777–81
4. Wagtmans MJ, van Hogezaand RA, Griffioen G et al: Crohn's disease of the upper gastrointestinal tract. *Neth J Med*, 1997; 50: S2–7
5. Yokota K, Yuki M, Ohta T et al: "Bamboo-joint like erosions" of the gastric body and cardia: A novel sign as a clue of having Crohn's disease. *Gastroenterology*, 1995; 108: A947
6. Yokota K, Saito Y, Einami K et al: A bamboo joint-like appearance of the gastric body and cardia: possible association with Crohn's disease. *Gastrointest Endosc*, 1997; 46: 268–72
7. Hirokawa M, Shimizu M, Terayama K et al: Bamboo-joint-like appearance of the stomach: a histopathological study. *APMIS*, 1999; 107: 951–56
8. Watari J, Sato R, Tanabe H et al: Clinical Features and Course of Gastroduodenal Lesions in Patients with Crohn's Disease. *Stomach and Intestine*, 2007; 42: 417–28. [Japanese, abstract in English]
9. Kuriyama M, Kato J, Morimoto N et al: Specific gastroduodenoscopic findings in Crohn's disease: Comparison with findings in patients with ulcerative colitis and gastroesophageal reflux disease. *Dig Liver Dis*, 2008; 40: 468–75
10. Hirata I, Nishikawa T, Nagasaka M et al: Clinical Analysis of an Upper Gastrointestinal Tract Lesion of Crohn's Disease – Including Clinical Course of the Lesion. *Stomach and Intestine*, 2007; 42: 429–40 [Japanese, abstract in English]
11. Moriyama T, Matsumoto T, Jo Y et al: Mucosal proinflammatory cytokine and chemokine expression of gastroduodenal lesions in Crohn's disease. *Aliment Pharmacol Ther*, 2005; 21(Suppl.2): 85–91
12. Hisabe T, Hirai F, Matsui T, Watanabe M: Evaluation of diagnostic criteria for Crohn's disease in Japan. *J Gastroenterol*, 2014; 49: 93–99
13. van Dullemen HM, van Deventer SJ, Hommes DW et al: Treatment of Crohn's disease with anti-tumor necrosis factor chimeric monoclonal antibody (cA2). *Gastroenterology*, 1995; 109: 129–35
14. Papi C, Fasci-Spurio F, Rogai F et al: Mucosal healing in inflammatory bowel disease: Treatment efficacy and predictive factors. *Dig Liver Dis*, 2013; 45(12): 978–85
15. Froslie KF, Jahnsen J, Moum BA, Vatn MH: Mucosal healing in inflammatory bowel disease: results from a Norwegian population-based cohort. *Gastroenterology*, 2007; 133: 412–22
16. Daperno M, D'Haens G, Van Assche G et al: Development and validation of a new, simplified endoscopic activity score for Crohn's disease: the SES-CD. *Gastrointest Endosc*, 2004; 60: 505–12
17. Schnitzler F, Fidder H, Ferrante M et al: Mucosal healing predicts long-term outcome of maintenance therapy with infliximab in Crohn's disease. *Inflamm Bowel Dis*, 2009; 15: 1295–301
18. Van Assche G, Dignass A, Panes J et al: The second European evidence-based Consensus on the diagnosis and management of Crohn's disease: Definitions and diagnosis. *J Crohns Colitis*, 2010; 4: 7–27

19. Hokama A, Nakamura M, Ihama Y et al: Notched sign and bamboo-joint-like appearance in duodenal Crohn's disease. *Endoscopy*, 2008; 40(Suppl.2): E151
20. Matsumura M, Matsui T, Hatakeyama S et al: Prevalence of *Helicobacter pylori* infection and correlation between severity of upper gastrointestinal lesions and *H. pylori* infection in Japanese patients with Crohn's disease. *J Gastroenterol*, 2001; 36: 740-47
21. Kuwaki K, Mitsuyama K, Tomiyasu N et al: Crohn's Disease with Bamboo Joint like Appearance, Report of a Case. *Stomach and Intestine*, 2007; 42: 493-97. [in Japanese, abstract in English]
22. Iizuka M, Harada T, Yamano HO et al: Typical gastroduodenal endoscopic findings in a Crohn's disease patient in remission stage. *World J Gastrointest Endosc*, 2012; 4: 96-98
23. Rutgeerts P, Diamond RH, Bala M et al: Scheduled maintenance treatment with infliximab is superior to episodic treatment for the healing of mucosal ulceration associated with Crohn's disease. *Gastrointest Endosc*, 2006; 63: 433-42; quiz 64
24. D'Haens G, Baert F, van Assche G et al: Early combined immunosuppression or conventional management in patients with newly diagnosed Crohn's disease: an open randomised trial. *Lancet*, 2008; 371: 660-67
25. Colombel JF, Sandborn WJ, Reinisch W et al: Infliximab, azathioprine, or combination therapy for Crohn's disease. *N Engl J Med*, 2010; 362: 1383-95
26. Rutgeerts P, Van Assche G, Sandborn WJ et al: Adalimumab induces and maintains mucosal healing in patients with Crohn's disease: data from the EXTEND trial. *Gastroenterology*, 2012; 142: 1102-11.e2
27. Koga H, Shimizu K, Tarumi K: Anti Tumor Necrosis Factor Alpha Antibody Markedly Improved Aphthous Lesions of the Stomach in a Patient with Crohn's Disease, Report of a Case. *Stomach and Intestine*, 2004; 39: 221-27 [in Japanese, abstract in English]