

MINI-FOCUS ISSUE: ELECTROPHYSIOLOGY

ADVANCED

CASE REPORT: TECHNICAL CORNER

Successful Noninvasive 12-Lead ECG Mapping-Guided Radiotherapy of Inaccessible Ventricular Tachycardia Substrate Due to Mechanical Valves



Lucas K. Keyt, MD,^a Todd Atwood, PhD, DABR,^b Andrew Bruggeman, MD,^b Arno J. Mundt, MD,^b Gregory K. Feld, MD,^a David E. Krummen, MD,^a Gordon Ho, MD^a

ABSTRACT

In patients presenting with refractory ventricular tachycardia (VT) and aortic and mitral mechanical prosthetic valves, traditional catheter ablation is challenging. We describe a case in which a novel noninvasive computational electrocardiogram mapping algorithm localized VT sources originating from substrate near the mechanical valves, in which stereotactic ablative radiotherapy eliminated VT in 1.5-year follow-up. (**Level of Difficulty: Advanced.**) (J Am Coll Cardiol Case Rep 2023;15:101870) Published by Elsevier on behalf of the American College of Cardiology Foundation. This is an open access article under the CC BY-NC-ND license (<http://creativecommons.org/licenses/by-nc-nd/4.0/>).

Drug-refractory ventricular tachycardia (VT) presents a clinical challenge resulting in repeated implantable cardioverter-defibrillator (ICD) shocks, progressive systolic dysfunction, and death. Catheter ablation is a standard of care treatment modality in patients with scar-based VT not responsive to medical management. However, catheter ablation requires direct access into the ventricular space. In patients with mechanical valves at

both the mitral and aortic valve positions, few options exist to obtain ventricular access due to inability to cross the mechanical valves with a catheter. Noninvasive stereotactic ablative radiotherapy (SABR) is an attractive treatment modality for these patients because it avoids the need to obtain catheter access. However, without the ability to use catheters to map the VT, noninvasive electrical mapping techniques are desirable to accurately define VT sources. We have recently developed a 12-lead electrocardiogram (ECG) mapping algorithm based on forward-solution computational simulation libraries that can localize VT origination sites in patients with structural heart disease within 1.1-cm accuracy in blinded clinical trial.

We present a case of successful noninvasive treatment of refractory VT using SABR guided by novel computational ECG mapping in a patient with

LEARNING OBJECTIVES

- To understand the potential role of computational 12-lead ECG mapping in planning noninvasive radiotherapy of VT.
- To recognize the potential indications for SABR to treat VT in patients with inaccessible substrate.

From the ^aDepartment of Medicine, Division of Cardiology, University of California-San Diego, La Jolla, California, USA; and the ^bDepartment of Radiation Medicine and Applied Sciences, University of California-San Diego, La Jolla, California, USA.

The authors attest they are in compliance with human studies committees and animal welfare regulations of the authors' institutions and Food and Drug Administration guidelines, including patient consent where appropriate. For more information, visit the [Author Center](#).

Manuscript received January 2, 2023; revised manuscript received March 21, 2023, accepted April 13, 2023.

**ABBREVIATIONS
AND ACRONYMS****CT** = computed tomography**ECG** = electrocardiogram**ICD** = implantable
cardioverter-defibrillator**LV** = left ventricle/ventricular**LVOT** = left ventricular outflow
tract**PTV** = planning target volume**PVC** = premature ventricular
contraction**SABr** = stereotactic ablative
radiotherapy**VF** = ventricular fibrillation**VT** = ventricular tachycardia

both aortic and mitral mechanical valve replacements with no VT in 15-month follow-up.

CASE PRESENTATION

The patient was a 75-year-old man with a history of monomorphic VT on amiodarone and propranolol with a single-chamber ICD. About 30 years prior to presentation, the patient had undergone repeat sternotomy for mechanical replacement of both aortic and mitral valves due to bacterial endocarditis. The patient's remaining past medical history is notable for concomitant nonischemic heart failure with reduced ejection fraction (ejection fraction 46%) and ascending aortic aneurysm, which was surgically repaired via sternotomy 5 years prior.

The patient presented with ICD shocks for monomorphic VT. Interrogation of the patient's ICD demonstrated 2 shocks and 12 episodes of anti-tachycardia pacing delivered in the prior 18 months prior for 2 monomorphic VT morphologies (VT1: inferior axis left bundle branch block at 360 ms localized to the basal anteroseptal left ventricle [LV] at the left ventricular outflow tract [LVOT] under the mechanical aortic valve; VT2: inferior axis right bundle branch block at 370 ms localized to the aortomitral continuity) as shown in [Figure 1](#). Additionally, the patient had numerous episodes consistent with nonsustained VT. Twelve-lead ECGs of premature ventricular contractions (PVCs) obtained on the day of his emergency room presentation and admission for VT storm showed identical morphologies with his induced VT1 and VT2 and are provided in [Supplemental Figures 1 and 2](#).

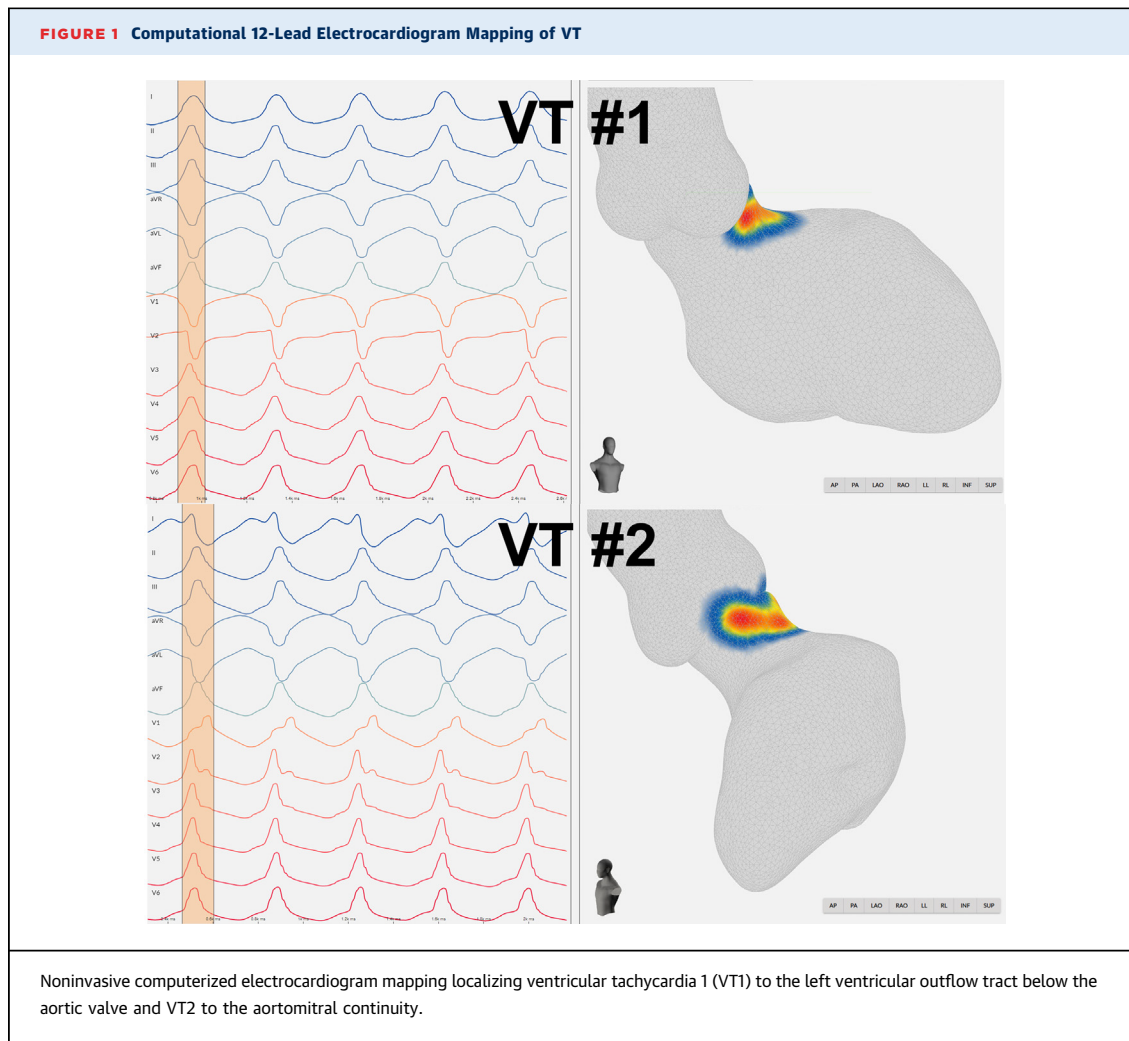
TECHNIQUE

Due to the combined aortic and mitral mechanical valves, radiofrequency catheter ablation via retrograde aortic or antegrade transmitral routes was contraindicated. Furthermore, due to the patient's prior 2 sternotomies and subsequent adhesions, surgical epicardial access for epicardial ablation was less feasible. Therefore, the decision was made to pursue SABr for noninvasive treatment of recurrent VT.

This patient was enrolled into an approved Institution Review Board protocol at the University of California-San Diego and provided informed consent. Noninvasive programmed stimulation using the

patient's ICD was performed prior to ablation. Analysis of subsequent ECG data using a forward-solution computational simulation-based ECG mapping algorithm (written in Python Version 3.9; Python Software Foundation) with virtual representation on a 3-dimensional heart model (Blender Version 3.1.6; Blender Foundation) localized both VT episodes to the LVOT under the mechanical aortic valve and the aortomitral continuity near the mechanical mitral valve ([Figure 1](#)). High-resolution cardiac computed tomography (CT) (SOMATOM Force with 0.5-mm resolution, Siemens) was obtained and reviewed with a cardiothoracic radiologist to assess for wall thinning as previously described.^{1,2} A small area of wall thinning (2.1 mm) was identified at the basal anteroseptum near the LVOT. This area correlated with the VT1 origin and was included in the VT target. No other areas of wall thinning <1 cm were identified. Representative cross-sectional imaging of the 17 American Heart Association cardiac segments are shown in [Supplemental Figure 3](#). Myocardial single-photon emission CT nuclear imaging did not show any fixed perfusion defects. On echocardiography, there were no wall motion abnormalities, and this patient had a normal LV ejection fraction.

Given that the VT originated near both mechanical valves, the valves were used to facilitate target contouring on the cardiac CT and the simulation 4-dimensional CT in the maximal intensity projection ([Figure 2](#)). The clinical target volume incorporated a transmural, contiguous area encompassing the 2 VT origins with the small area of wall thinning at the basal anteroseptal LV. An internal target volume (33.3 cm³) was expanded from the clinical target volume to incorporate cardiac and respiratory motion within the respiratory gating window (average 40-60 phase). A planning target volume (PTV) (85 cm³) was then created with a standard isotropic 5-mm margin to account for registration uncertainties. Treatment coverage (PTV V95%) was 100% and PTV D95% was 25Gy, with total treatment time 12.1 minutes. Due to proximity of the VT target to adjacent pulmonary and gastrointestinal structures, respiratory gating was performed to more precisely deliver radiation in sync with the patient's respiratory cycle. Prior to ablation, the degree of respiratory motion was assessed using simulation 4-dimensional CT and noninvasive programmed stimulation fluoroscopy. Additionally, an external optical surface tracking system (AlignRT, Vision RT) was used to monitor thoracic motion during the procedure, allowing for delivery of radiation



at end expiration. Radiotherapy was delivered via linear accelerator (TrueBeam, Varian) in a single fraction (6 MV, 25 Gy) to the mitral annulus (see [Video 1](#) of respiratory-gated delivery of radiotherapy).

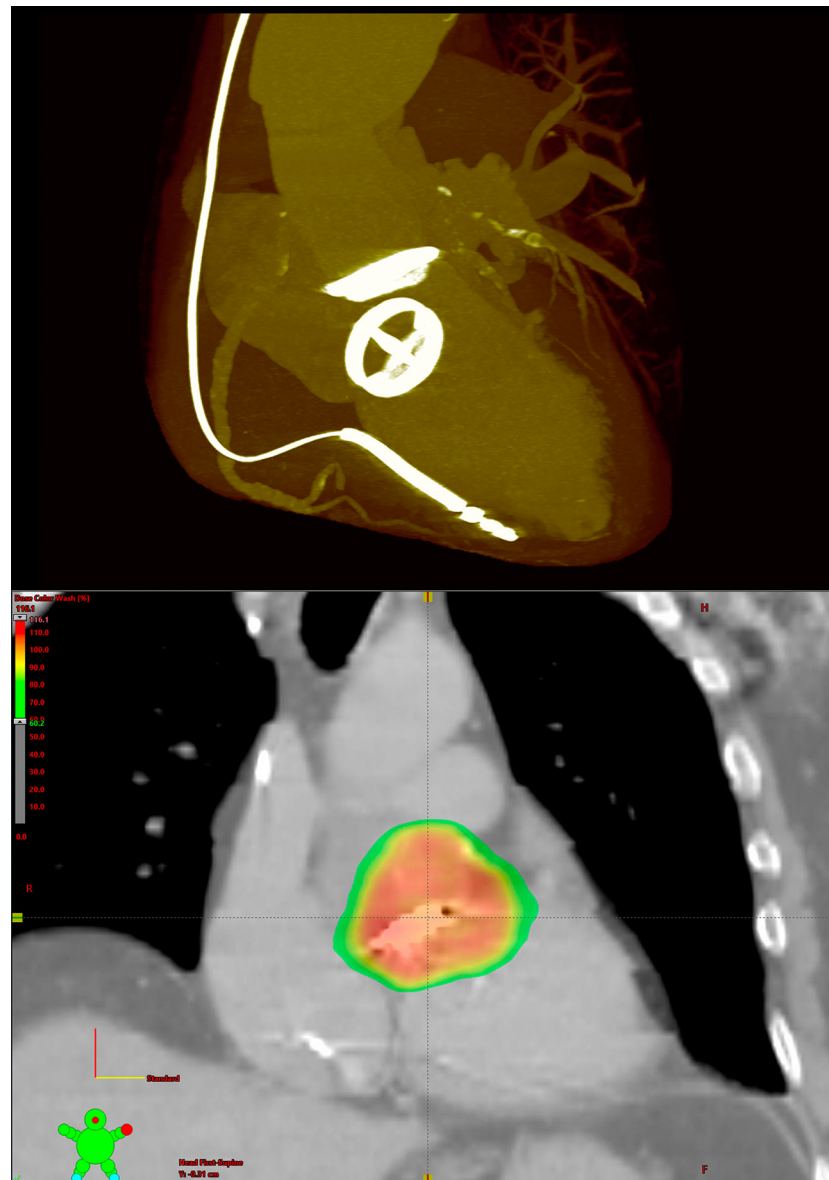
OUTCOME

There were no acute complications during the procedure, and it was well tolerated by the patient. The patient did not have any exacerbation of his heart failure with reduced ejection fraction, and his ICD maintained appropriate function upon interrogation. He was monitored while an inpatient for an additional day after the procedure and was then discharged home in the absence of complications. During outpatient clinic follow-up at 1 month, at 3 months, and every 6 months following the radiotherapy, the patient did not have any arrhythmias or pericardial effusions on repeat echocardiograms and surveillance thoracic CT angiography scan performed at 1 year (for

aortic aneurysm surveillance). The patient had no further episodes of VT during the 18-month follow-up period with active remote monitoring.

DISCUSSION

Management of stable VT refractory to medical management typically involves catheter radiofrequency ablation. However, the use of catheter ablation requires invasive access to the ventricular myocardium, which may not be possible in patients with combined mechanical aortic and mitral valve replacements. Patients with combined left heart mechanical valves have posed a unique challenge among electrophysiologists, historically requiring a direct transthoracic apical approach,³ and more recently, there are reports of interventricular transseptal approach via posterosuperior process in patients when epicardial access is not an option.⁴ These techniques, however, require a relatively high degree

FIGURE 2 3-Dimensional Reconstruction of Mechanical Valves and Final VT Target

(Top) A 3-dimensional reconstruction of the patient's cardiac computed tomography in maximal intensity projection shows clear delineation of the radiopaque mechanical aortic and mitral valves, from which the 2 ventricular tachycardias (VTs) originated. **(Bottom)** Final radiotherapy targeting the 2 VT originating sites at the left ventricular outflow tract and aortomitral continuity in a coronal view of the simulation computed tomography.

of technical skill and may be associated with complications, including bleeding, pneumothorax, and hypotension⁵; therefore, the use of noninvasive SABR is particularly attractive in such scenarios. This case demonstrates the use of noninvasive 12-lead ECG mapping and application of SABR for VT ablation in the rare setting of dual left heart mechanical valves.

Noninvasive localization of VT origin prior to ablation remains a distinct challenge in the treatment of VT, with limited reliable methods available. This case highlights the use and clinical potential of a noninvasive 12-lead ECG mapping system to rapidly localize VT origin. Manual interpretation of the ECG has previously been reported to have poor correlation

with invasive, intraprocedural mapping.⁶ Advancements in computational analysis and 3-dimensional mapping over the past 10 years have made noninvasive characterization of VT origin more feasible. Recent use of electrode vests with up to several hundred leads for high-fidelity VT mapping has demonstrated early promise, though they may be associated with separate barriers including complexity of mapping, required training of personnel, dependence on patient body habitus, requirement of CT imaging, and financial cost⁷; these barriers are mitigated in the use of the presented computerized 12-lead ECG mapping system. The fidelity of the computerized 12-lead ECG mapping method applied in the presented case is sufficiently accurate for the purpose of guiding SABR. In a small series of 6 patients with refractory VT undergoing SABR, the ECG algorithm demonstrated 100% accuracy in colocalizing VT origins in a subset of VT morphologies with available invasive mapping, resulting in a total 97% relative reduction in ICD shocks.¹ A recent blinded clinical trial evaluated the accuracy of this ECG-based forward-solution mapping algorithm in localizing VT and PVCs in patients with structural heart disease adjudicated with standard invasive catheter-based mapping.⁸ Regional accuracy in localizing PVCs and VT was 97% with a mean spatial accuracy of 11 mm (PVCs) and 14 mm (VT) in 95 cases.⁸ Though further clinical testing is needed, VT localization via the presented computerized 12-lead ECG mapping method may represent an effective and reproducible approach for noninvasive VT localization to facilitate targeting of SABR.

Respiratory gating is important for the mitigation of excess radiation to adjacent tissues due to each individual patient's variable respiratory motion. Though not yet a standard in the application of SABR, the benefit of respiratory gating and visualization of real-time position of the target has been demonstrated in external beam radiation of solid tumors with reduction in complication rates.⁹ This case features the application of a respiratory gating technique, which has been largely absent in cardiac radioablation, with previous reliance on abdominal binders to mitigate respiratory movement.

Early case series have suggested the use of SABR is efficacious and relatively safe, though notably limited by both study size and relative follow-up period.^{1,10} In a recent meta-analysis involving case reports, case series, and cohort studies, 96% of patients had a reduction in VT/ventricular fibrillation (VF) burden; however, 75% of patients still experienced at least 1 recurrent episode of VT/VF during the follow-up

period (median of 365 days).¹¹ Mortality reached an overall rate of 26% during the median follow-up period, with 16% of patients dying due to cardiovascular causes.¹¹ Additionally, postradiation electrical storm occurred in several patients (7%), representing a rare increase in VT/VF during the period immediately following SABR.¹¹ Of note, there does not appear to be any published literature demonstrating adverse interaction of tungsten alloys used in mechanical valves with ionizing radiation. Given that current outcomes are limited to a follow-up period of a maximum of 2 years, it is important to recognize that thoracic radiation is known to be associated with long-term cardiovascular, pulmonary, and malignant complications as seen in survivors of pediatric Hodgkin's lymphoma. Thus, these inherent risks of radiotherapy should be considered prior to SABR therapy, particularly in younger patients.

STUDY LIMITATIONS. Given that this is a single case, larger studies are needed to determine the generalizability of this technique in the general population. With regard to the characterization of VT substrate, automated substrate delineation software of the cardiac CT was not available at our institution. The patient was claustrophobic and refused cardiac magnetic resonance, and the potential metallic artifact from dual mechanical valves would likely limit ability to visualize gadolinium enhancement in close proximity. Furthermore, his dual mechanical valves and repeat sternotomies made patient a poor candidate for invasive substrate mapping. However, a small area of wall thinning was identified near the origin of VT1 and supports the presence of arrhythmogenic substrate that correlates with the electrical source of VT as mapped by computational ECG mapping. Finally, given the close proximity of the coronaries to the VT target, dose delivery to the coronaries was unavoidable. Of note, this is a common area treated with radiotherapy, but no case reports of short-term coronary arterial damage have yet been reported. Long-term studies are needed to guide the optimal approach to radiotherapy of the LV summit for effective and safe treatment.

CONCLUSIONS

This case demonstrates the ideal use of ECG mapping for arrhythmia localization and noninvasive radiotherapy with respiratory gating for the treatment of VT originating from substrate near dual mechanical valves resulting in VT suppression at 1.5 years in a patient with limited intracardiac access.

FUNDING SUPPORT AND AUTHOR DISCLOSURES

Dr Krummen was supported by a grant from the University of California San Diego Galvanizing Engineering in Medicine Foundation. Dr Ho was supported by grants from the American Heart Association (19CDA34760021) and National Institutes of Health (1KL2TR001444). Dr Krummen owns equity in Vektor Medical Inc. Dr Ho has received grant support from Abbott Laboratories; and has received fellowship support from Abbott, Boston Scientific, Biotronik, and Medtronic; and

owns equity in Vektor Inc. All other authors have reported that they have no relationships relevant to the contents of this paper to disclose.

ADDRESS FOR CORRESPONDENCE: Dr Gordon Ho, University of California-San Diego, Cardiology Section 111A, 3350 La Jolla Village Drive, San Diego, California 92161, USA. E-mail: goho@ucsd.edu.

REFERENCES

1. Ho G, Atwood TF, Bruggeman AR, et al. Computational ECG mapping and respiratory gating to optimize stereotactic ablative radiotherapy workflow for refractory ventricular tachycardia. *Heart Rhythm O2*. 2021;2:511-520.
2. Komatsu Y, Cochet H, Jadidi A, et al. Regional myocardial wall thinning at multidetector computed tomography correlates to arrhythmogenic substrate in postinfarction ventricular tachycardia: assessment of structural and electrical substrate. *Circ Arrhythm Electrophysiol*. 2013;3:342-350.
3. Hsieh CH, Thomas SP, Ross DL. Direct trans-thoracic access to the left ventricle for catheter ablation of ventricular tachycardia. *Circ Arrhythm Electrophysiol*. 2010;3:178-185. <https://doi.org/10.1161/circep.109.906628>
4. Santangeli P, Hyman MC, Muser D, Callans DJ, Shivkumar K, Marchlinski FE. Outcomes of percutaneous trans-right atrial access to the left ventricle for catheter ablation of ventricular tachycardia in patients with mechanical aortic and mitral valves. *JAMA Cardiol*. 2021;6:326-331.
5. Pitta SR, Cabalka AK, Rihal CS. Complications associated with left ventricular puncture. *Catheter Cardiovasc Interv*. 2010;76:993-997.
6. Graham AJ, Orini M, Zaccaro E, et al. Evaluation of ECG imaging to map hemodynamically stable and unstable ventricular arrhythmias. *Circ Arrhythm Electrophysiol*. 2020;13:e007377.
7. Pereira H, Niederer S, Rinaldi CA. Electrocardiographic imaging for cardiac arrhythmias and resynchronization therapy. *EP Europace*. 2020;22:1447-1462.
8. Krummen DE, Villongco CT, Ho G, et al. Forward-solution noninvasive computational arrhythmia mapping: the VMAP study. *Circ Arrhythm Electrophysiol*. 2022;15:e010857.
9. Underberg RW, Lagerwaard FJ, Slotman BJ, Cuijpers JP, Senan S. Benefit of respiration-gated stereotactic radiotherapy for stage I lung cancer: an analysis of 4DCT datasets. *Int J Radiat Oncol Biol Phys*. 2005;62:554-560.
10. Cuculich PS, Schill MR, Kashani R, et al. Noninvasive cardiac radiation for ablation of ventricular tachycardia. *N Engl J Med*. 2017;377:2325-2336.
11. Kovacs B, Mayinger M, Schindler M, Steffel J, Andratschke N, Saguner AM. Stereotactic radioablation of ventricular arrhythmias in patients with structural heart disease - a systematic review. *Radiother Oncol*. 2021;162:132-139.

KEY WORDS emerging technologies and innovations, ventricular arrhythmia

APPENDIX For supplemental figures and a video, please see the online version of this paper.