

Longitudinal CT evaluation of transdermal scopolamine for aspiration pneumonia with sialorrhea in severe chronic brain injury: A case series

SAGE Open Medical Case Reports
Volume 10: 1–5
© The Author(s) 2022
Article reuse guidelines:
sagepub.com/journals-permissions
DOI: 10.1177/2050313X221096227
journals.sagepub.com/home/sco



Tomohiro Yamaki¹ , Kyoko Takahashi², Osamu Azuhata²,
Daisuke Itou¹, Madinum Yakufujiang¹, Nobuo Oka¹,
Masaru Odaki¹ and Shigeki Kobayashi¹

Abstract

Sialorrhea is a major cause of recurrent aspiration pneumonia in severe chronic brain injury. Previous reports have shown that transdermal scopolamine can decrease saliva production. We present four patients with severe chronic brain injury who experienced repeat aspiration pneumonia with sialorrhea. Longitudinal computed tomography examinations to assess the therapeutic effect were performed in all four cases before and after transdermal scopolamine. Transdermal scopolamine was applied as a patch (0.1 g/2.5 cm²) behind the earlobe every 24 h after confirming the absence of glaucoma. Patches were formulated as an in-hospital preparation (scopolamine butylbromide 0.25 g and hydrophilic cream 4.75 g) under the approval of our institutional review board. Longitudinal computed tomography after transdermal scopolamine use showed a decrease in pleural effusions associated with continuous aspiration pneumonia in all four cases. The data from repeat computed tomography suggest that long-term transdermal scopolamine for reducing saliva production may be a reasonable option for appropriate palliative care in severe chronic brain injury patients.

Keywords

Scopolamine, sialorrhea, brain injuries, prolonged post-traumatic unawareness

Date received: 4 February 2022; accepted: 6 April 2022

Introduction

Severe chronic traumatic brain injury (scTBI), including minimally conscious state or unresponsive wakefulness syndrome (UWS), is often accompanied by functional dysphagia, which can trigger repeat aspiration pneumonia associated with sialorrhea. In particular, UWS is a disorder of consciousness in which some people awaken from their comas (open their eyes) but remain unresponsive (i.e. they display only reflex movements without responding to commands).¹ Aspiration pneumonia is observed in nearly 10% of these patients during the course of treatment, and the condition is a common cause of death in scTBI.² Although protective endotracheal intubation or tracheostomy is recommended for long-term care, sialorrhea-induced pneumonia is not always preventable and interferes with rehabilitation.

Scopolamine butylbromide is a competitive inhibitor of the muscarinic receptors of acetylcholine and is commonly used for the prevention of motion-induced nausea in the

form of transdermal scopolamine.³ Recently, transdermal scopolamine has drawn attention for its effects in reducing saliva production, and it has been used for treating sialorrhea in patients with amyotrophic lateral sclerosis and stroke.^{4,5}

We present a case series in which longitudinal computed tomography (CT) was used to assess the therapeutic effect of

¹Division of Neurosurgery and PET imaging, Rehabilitation Center for Traumatic Apallics Chiba, National Agency for Automotive Safety and Victims' Aid, Chiba, Japan

²Division of Pharmacy, Rehabilitation Center for Traumatic Apallics Chiba, National Agency for Automotive Safety and Victims' Aid, Chiba, Japan

Corresponding Author:

Tomohiro Yamaki, Division of Neurosurgery and PET imaging, Rehabilitation Center for Traumatic Apallics Chiba, National Agency for Automotive Safety and Victims' Aid, 3-30-1 Isobe, Mihama-ku, Chiba-shi, Chiba 261-0012, Japan.

Email: t-yamaki@chiba-ryougo.jp



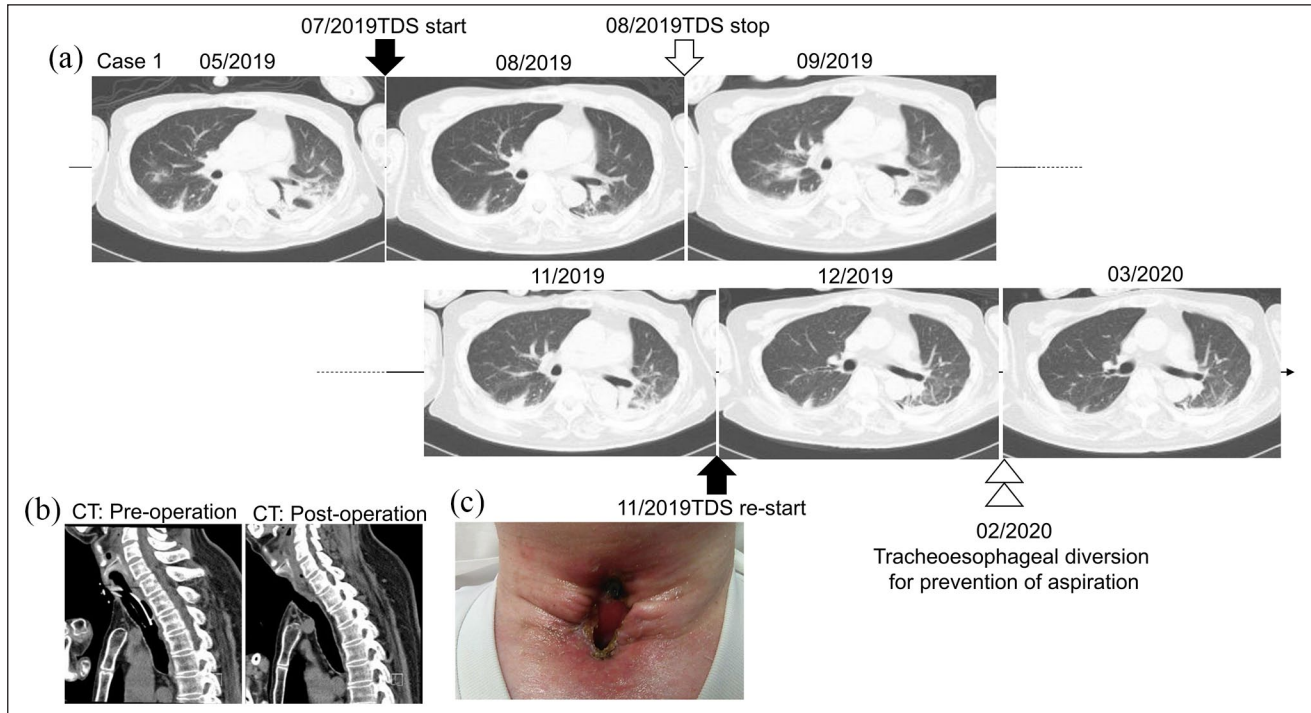


Figure 1. Longitudinal imaging of case 1. (a) Longitudinal CT images. CT scan before transdermal scopolamine patches 1st use: 3.8 cm pleural effusion. CT scan 1 month after 1st use: 1.9 cm pleural effusion. CT scan before 2nd use: 2.0 cm pleural effusion. CT scan 1 month after 2nd use: 0.9 cm pleural effusion. (b) Neck CT images before and after tracheoesophageal diversion for the prevention of aspiration. (c) Representative image after tracheoesophageal diversion. CT: computed tomography; TDS: transdermal scopolamine.

transdermal scopolamine treatment in four UWS patients with scTBI.

Case 1

Case presentation. A 51-year-old man had an accident involving a car while riding a bicycle. He sustained traumatic subarachnoid hemorrhage, diffuse brain injury, and fractures to the mandible, left clavicle, and C6 vertebra. He was admitted to our hospital 7 months after the injury. The Coma Recovery Scale-Revised (CRS-R) score at admission was 5 (3-0-1-0-0-1), which is classified as UWS.⁶ A tracheostomy tube was placed at admission. The patient experienced seven episodes of aspiration pneumonia in 9 months after admission.

Case management and outcome. When transdermal scopolamine was started in July 2019, the left pleural effusion decreased. Furthermore, right pulmonary consolidation decreased, and bilateral dorsal ground-glass opacities and atelectasis improved (Figure 1(a) and Table 1).⁷ Transdermal scopolamine was discontinued after 1 month of continuous use. However, because the left pleural effusion gradually increased again over 2 months, transdermal scopolamine was restarted in November 2019. Thereafter, a decrease in pleural effusion was again observed on CT, and bilateral

dorsal pulmonary consolidation, ground-glass opacities, and atelectasis also improved. No obvious side effects were observed during the use of transdermal scopolamine. Ultimately, in February 2020, the man's family chose tracheoesophageal diversion after consulting with an otolaryngologist for the prevention of aspiration at home after discharge because the use of transdermal scopolamine was off-label (Figure 1(b)).

Case 2

Case presentation. A 41 year-old man had an accident involving a car while walking and presented in cardiogenic shock. He was treated for brain stem contusion and left putaminal hemorrhage, and he had sustained fractures to the right clavicle, right rib, left tibia, fibula, and pelvis. He was admitted to our hospital 5 months after the accident. The CRS-R score at admission was 7 (2-3-1-0-0-1), which was classified as UWS.

Case management and outcome. During the first 22 months after admission, he experienced six episodes of aspiration pneumonia before transdermal scopolamine was started. Thereafter, CT showed decreased pleural effusion, resolution of the right lung atelectasis, and improved bilateral dorsal pulmonary consolidation, and ground-glass opacities

Table 1. Summary of the CT findings.

CT findings	Case 1-1 st		Case 1-2 nd		Case 2		Case 3		Case 4	
	Before	After 1 month	Before	After 1 month	Before	After 7 months	Before	After 2 months	Before	After 7 months
Bronchiectasis (Yes/No)	Yes	Yes	No	No	No	No	No	No	No	No
Bronchial wall thickening (Yes/No)	Yes	Yes	Yes	Yes	No	No	Yes	Yes	Yes	Yes
Pulmonary nodules	No	No	No	No	No	No	No	No	No	No
Consolidations	Yes	No	Yes	Yes (improve)	Yes	Yes (improve)	No	No	No	No
Ground-glass opacity	Yes	Yes (improve)	Yes	Yes (improve)	Yes	Yes (improve)	No	No	Yes	Yes (improve)
Atelectasis	Yes	Yes (improve)	Yes	Yes (improve)	Yes	No	Yes	Yes	Yes	Yes
Interlobular septal thickening	Yes	Yes	Yes	Yes	No	No	Yes	Yes	No	No
Fibrosis	No	No	No	No	No	No	No	No	No	No
Air trapping	No	No	No	No	No	No	Yes	Yes	Yes	Yes
Pleural effusion category (small/moderate/large) ^a	moderate	small	small	small	small	small	moderate	small	moderate	moderate
Maximum anteroposterior depth of pleural effusion (cm) ^a	3.8	1.9	2	0.9	2	0.7	3	0.7	3.4	1.8

CT: computed tomography.

^aRefer to Chest 2013;143: 1054–1059.

(Figure 2(a) and Table 1). Fourteen months after starting transdermal scopolamine, he continued rehabilitation without pneumonia and was discharged from the hospital. The CRS-R at discharge was 14 (2-3-5-1-0-3). After using transdermal scopolamine, there were no obvious side effects until discharge.

Case 3

Case presentation. A 76-year-old man was involved in a car accident during his job working in security. He was diagnosed with traumatic subarachnoid hemorrhage, diffuse brain injury, left iliac wing/left central pelvic fracture, and right femoral fracture. On admission, he had a CRS-R score of 4 (1-0-2-0-0-1), which was classified as UWS.

Case management and outcome. During the first 12 months after admission, he experienced three episodes of aspiration pneumonia. Transdermal scopolamine was administered after April 2020, and pneumonia did not occur for 10 months thereafter. CT showed decreased right pleural effusion after transdermal scopolamine use (Figure 2(b) and Table 1). During transdermal scopolamine use, there were no evident negative effects. Because of the off-label use of transdermal scopolamine, the family selected tracheoesophageal separation after consulting with an otolaryngologist, for patient management at home after discharge in January 2021.

Case 4

Case presentation. A 58-year-old man was involved in a car accident in March 1984. He sustained cerebral contusions and a right lower leg fracture. He developed pneumonia once every 6 months and frequently used continuous oxygen because of low blood oxygen levels. On admission, he had a CRS-R score of 11 (1-4-2-1-0-3), which was classified as UWS.

Case management and outcome. On longitudinal CT, the right pleural effusion decreased, and bilateral dorsal pulmonary ground-glass opacities improved after transdermal scopolamine use (Figure 2(c) and Table 1). Continuous oxygen use was not required after transdermal scopolamine, and pneumonia did not recur until 17 months later with continuous use of scopolamine.

Discussion

Saliva—normally produced at a rate of 0.5–1.5 L per day—helps maintain a hygienic environment in the oral cavity, contributing to oral health, and mouth lubrication and swallowing, and preventing bacterial overgrowth and tooth decay.⁸ However, in patients with scTBI, including UWS and minimally conscious state, sialorrhea can cause drooling, external skin irritation, choking, poor oxygenation, and life-threatening pneumonia.⁹ Although transdermal

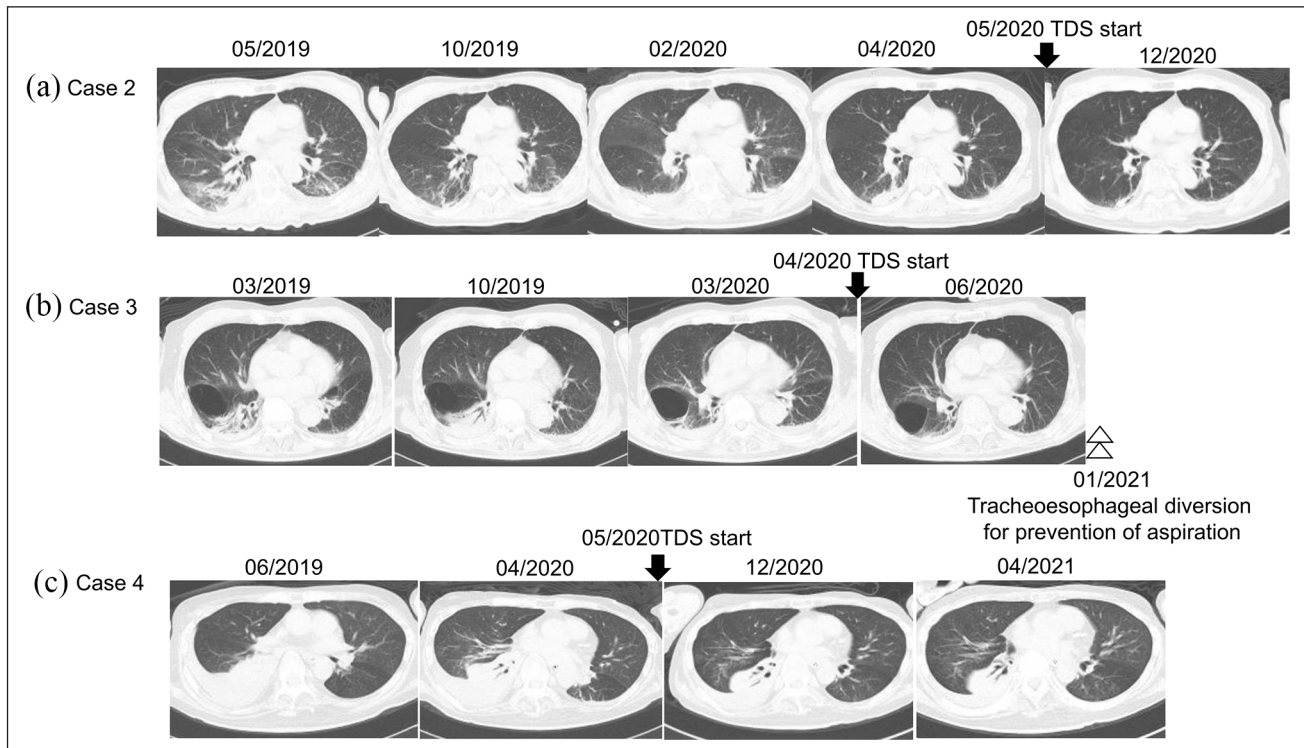


Figure 2. Longitudinal CT examinations of (a) case 2 (CT scan pre scopolamine patches: 2.0 cm pleural effusion. CT scan 7 months after: 0.7 cm pleural effusion) (b) case 3 (CT scan pre scopolamine patches: 3.0 cm pleural effusion. CT scan 2 months after: 0.7 cm pleural effusion), and (c) case 4 (CT scan pre scopolamine patches: 3.4 cm pleural effusion. CT scan 7 months after: 1.8 cm pleural effusion). CT: computed tomography; TDS: transdermal scopolamine.

scopolamine is currently used as a treatment for motion sickness, using this drug and formulation for reducing saliva production is an off-label use. In accordance with previous reports, we used an in-hospital preparation of transdermal scopolamine (scopolamine butylbromide 0.25 g and hydrophilic cream 4.75 g) based on previous reports under the approval of the Rehabilitation Center for Traumatic Apallies Chiba Review Board (2019-26).¹⁰ Transdermal scopolamine was used as a 0.1 g/2.5 cm² patch behind the earlobe every 24 h after confirming the absence of glaucoma because the anticholinergic effect might increase intraocular pressure. Our scopolamine patch was based on the previous article because commercialized scopolamine skin patches (Scopoderm TTS, Novartis Consumer Healthcare, UK) are off-label in Japan.¹⁰ However, a phase I clinical study will be required in the future to examine the safety, side effects, appropriate dose, and timing of the medication for other patients.

In our four cases, Table 1 shows the detailed changes on longitudinal CT with reference to previous reports.⁷ Long-term repeat CT showed a decrease in pleural effusion associated with continuous aspiration pneumonia in all four cases. The average number and standard deviation of aspiration suction per day was calculated before, after 1, 2, and 3 months of transdermal scopolamine use, however no tendency was seen (Supplementary Table 1). The number of aspiration suction may vary depending on the severity of pneumonia. It may be necessary to measure the amount of

salivation to accurately indicate the therapeutic effect of transdermal scopolamine, in future.

In two of our four cases, tracheoesophageal diversion was selected after the family consulted with an otolaryngologist regarding quality-of-life after discharge. As sialorrhea treatments, oral anticholinergic agents, botulinum toxin A injection into the salivary glands, surgery, and radiation therapy have been reported, and each has advantages and disadvantages.¹¹ Recently, the usefulness of submandibular gland excision or two-duct ligation has also been reported.¹² If the use of transdermal scopolamine in our patients had not been off-label, it could have been used for a longer period at a lower cost, offering an option for less invasive palliative care. The treatment aims in our patients were to reduce cough caused by saliva aspiration, have the family perform odor and taste rehabilitation, and reduce saliva-induced skin disorders following discharge.

Scopolamine suppresses the autonomic reflex via its anti-acetylcholine action, resulting in improvement in nausea and dizziness.³ In 1985, Gordon et al.¹³ showed that dry mouth with scopolamine patches was because of a significant decrease in saliva production in healthy individuals, suggesting the potential for therapeutic use for persistent drooling. Of note, scopolamine discontinuation can result in overstimulation of the vestibular nuclei and the vomiting center in the reticular formation and hence the sensation of motion sickness. This phenomenon—known as scopolamine patch

withdrawal syndrome—has been reported, however, the incidence is unknown.¹⁴ Owing to the inability to communicate with the patients in our four cases, we were unable to obtain information about the patients' subjective reactions to the transdermal scopolamine patch, such as sleepiness, blurred vision, or dry mouth. However, during our observation period, no objective side effects such as pupillary dilatation, urinary retention, constipation, or tachycardia were observed.

Case reports describe the use as a therapeutic agent for aspiration pneumonia in otorhinolaryngology surgery, cerebral palsy, neurodevelopmental disorder, amyotrophic lateral sclerosis, and stroke. However, there are no reports using longitudinal radiological imaging following long-term transdermal scopolamine use for aspiration pneumonia in patients with severe head trauma.^{4,5,9} Mato et al.¹⁵ reported the effectiveness of transdermal scopolamine for drooling control in a prospective, randomized, placebo-controlled clinical trial. In our report, detailed endoscopic examinations would have been ideal, but this was impossible owing to trismus, clenching, and non-cooperative behaviors. The information presented in this case series shows the possibility that repeat CT could be an index for accurate evaluation of the efficacy of transdermal scopolamine in future multicenter, controlled studies investigating the expansion of the indications.

Conclusion

After transdermal scopolamine administration in all four of our patients, longitudinal CT revealed pulmonary improvement comprising a reduction in pleural effusion associated with repeat aspiration pneumonia. For similar patients to those in this report, long-term transdermal scopolamine to lower saliva production could be a viable alternative for appropriate palliative treatment.

Acknowledgements

We thank for Prof. Mieko Ogino at the International University of Health & Welfare, School of Medicine for cooperation regarding the patients' medical information and for her advice. We thank Dr Gota Tsuda at the Seirei Sakura Citizen Hospital for cooperation regarding the patients' treatment. We thank Helen Robertson and Jane Charbonneau, DVM from Edanz (<https://jp.edanz.com/ac>) for editing a draft of this manuscript.

Declaration of conflicting interests

The author(s) declared no potential conflicts of interest with respect to the research, authorship, and/or publication of this article.

Funding

The author(s) received no financial support for the research, authorship, and/or publication of this article.


Ethical approval

Ethical approval to report this case series was obtained from Rehabilitation Center for Traumatic Apallics Chiba review board (2019-26).

Informed consent

Written informed consent was obtained from a legally authorized representative for anonymized patient information to be published in this article.

ORCID iD

Tomohiro Yamaki  <https://orcid.org/0000-0002-3528-3229>

Supplemental material

Supplemental material for this article is available online.

References

1. Laureys S, Celesia GG, Cohadon F, et al. Unresponsive wakefulness syndrome: a new name for the vegetative state or apallic syndrome. *BMC Med* 2010; 8: 68.
2. Harrison-Felix C, Pretz C, Hammond FM, et al. Life expectancy after inpatient rehabilitation for traumatic brain injury in the United States. *J Neurotrauma* 2015; 32: 1893–1901.
3. Spinks A and Wasiak J. Scopolamine (hyoscine) for preventing and treating motion sickness. *Cochrane Database Syst Rev* 2011; 2011: CD002851.
4. Banfi P, Ticozzi N, Lax A, et al. A review of options for treating sialorrhea in amyotrophic lateral sclerosis. *Respir Care* 2015; 60(3): 446–454.
5. Talmi YP, Finkelstein Y and Zohar Y. Reduction of salivary flow with transdermal scopolamine: a four-year experience. *Otolaryngol Head Neck Surg* 1990; 103(4): 615–618.
6. Giacino JT, Kalmar K and Whyte J. The JFK Coma Recovery Scale-Revised: measurement characteristics and diagnostic utility. *Arch Phys Med Rehabil* 2004; 85(12): 2020–2029.
7. Moy MP, Levsky JM, Berko NS, et al. A new, simple method for estimating pleural effusion size on CT scans. *Chest* 2013; 143(4): 1054–1059.
8. Llena-Puy C. The role of saliva in maintaining oral health and as an aid to diagnosis. *Med Oral Patol Oral Cir Bucal* 2006; 11: E449–E455.
9. Paine CC 2nd and Snider JW 3rd. When saliva becomes a problem: the challenges and palliative care for patients with sialorrhea. *Ann Palliat Med* 2020; 9(3): 1333–1339.
10. Shimoda K, Hoshino T, Sugiyama R, et al. The effect of 5% scopolamine ointment to suppress salivation in patients with neurodegenerative diseases and adverse effects associated with the treatment. *J Jpn Soc Hosp Pharm* 2011; 47: 1157–1160.
11. Hockstein NG, Samadi DS, Gendron K, et al. Sialorrhea: a management challenge. *Am Fam Physician* 2004; 69: 2628–2634.
12. Delsing CP, Bekkers S, Erasmus CE, et al. Posterior drooling in children with cerebral palsy and other neurodevelopmental disorders. *Dev Med Child Neurol* 2021; 63(9): 1093–1098.
13. Gordon C, Ben-Aryeh H, Attias J, et al. Effect of transdermal scopolamine on salivation. *J Clin Pharmacol* 1985; 25(6): 407–412.
14. Saxena K and Saxena S. Scopolamine withdrawal syndrome. *Postgrad Med* 1990; 87: 63–66.
15. Mato A, Limeres J, Tomás I, et al. Management of drooling in disabled patients with scopolamine patches. *Br J Clin Pharmacol* 2010; 69(6): 684–688.