

—Original—

Thioacetamide-induced hepatic fibrosis in the common marmoset

Takashi INOUE¹⁾, Yukihiro ISHIZAKA²⁾, Emi SASAKI¹⁾, Jun LU²⁾, Takayuki MINESHIGE¹⁾, Mikio YANASE³⁾, Erika SASAKI^{1,4)}, and Masayuki SHIMODA⁵⁾

¹⁾Department of Marmoset Research, Central Institute for Experimental Animals, 3-25-12 Tonomachi, Kawasaki-ku, Kawasaki-shi, Kanagawa 210-0821, Japan

²⁾Department of Intractable Diseases, National Center for Global Health and Medicine, 1-21-1 Toyama, Shinjuku-ku, Tokyo 162-8655, Japan

³⁾Department of Gastroenterology, National Center for Global Health and Medicine, 1-21-1 Toyama, Shinjuku-ku, Tokyo 162-8655, Japan

⁴⁾Keio Advanced Research Center, Keio University, 35 Shinanomachi, Shinjuku-ku, Tokyo 160-8582, Japan

⁵⁾Islet Cell Transplantation Project, Diabetes Research Center, National Center for Global Health and Medicine, 1-21-1 Toyama, Shinjuku-ku, Tokyo 162-8655, Japan

Abstract: The common marmoset (*Callithrix jacchus*) is a nonhuman primate that is used for preclinical research on stem cell transplantation therapies due to its similarity to human beings as well as its small size, enabling researchers to perform experiments without preparing a large number of cells. In this study, we developed a marmoset hepatic fibrosis model for regenerative medicine research. Six female marmosets aged 4–6 years were administered thioacetamide (TAA) at a dose of 2.5–40 mg/kg two or three times a week. Hepatic fibrosis was assessed by liver biopsy when blood chemistry indicated liver damage. Administration of TAA increased total bile acid, aspartate aminotransferase, and total bilirubin and decreased serum albumin levels. Following more than 11 weeks of continuous injection of TAA, histological analyses detected hepatic fibrosis in all animals. Type IV collagen 7S serum levels in animals with hepatic fibrosis were significantly higher than in normal animals as a possible marker of hepatic fibrosis in marmosets. Serial liver biopsies following the last administration of TAA revealed that induced fibrosis remained up to 11 weeks. The results suggest that continuous TAA administration induces persistent hepatic fibrosis in the common marmoset and this nonhuman primate hepatic fibrosis model have the possibility to evaluate the therapeutic effects of test samples to ameliorate hepatic fibrosis.

Key words: liver fibrosis, marmoset, nonhuman primate, thioacetamide

Introduction

Hepatic fibrosis has emerged as a global public health problem, and numerous cell therapies have been developed [5, 6]. For human clinical research of the novel

therapies, testing with animal models is essential and various hepatic fibrosis models using mice and rats have been established [21]. However, positive results in rodent models have not always translated through to successful clinical therapies and more realistic preclinical models

(Received 11 December 2017 / Accepted 30 January 2018 / Published online in J-STAGE 22 February 2018)

Addresses corresponding: T. Inoue, Department of Marmoset Research, Central Institute for Experimental Animals, 3-25-12 Tonomachi, Kawasaki-ku, Kawasaki-shi, Kanagawa 210-0821, Japan

Y. Ishizaka, Department of Intractable Diseases, National Center for Global Health and Medicine, 1-21-1 Toyama, Shinjuku-ku, Tokyo 162-8655, Japan



This is an open-access article distributed under the terms of the Creative Commons Attribution Non-Commercial No Derivatives (by-nc-nd) License <<http://creativecommons.org/licenses/by-nc-nd/4.0/>>.

need to be developed [6]. Nonhuman primates have the potential to bridge the gap between rodents and humans due to their physiological similarity with humans [1, 2].

A common marmoset, a small New World monkey, has recently drawn attention as a preclinical animal model. Marmosets have several favorable features for biomedical research including small size (300–500 g), good availability, and relatively rapid generational turnover [17, 18, 22]. They are also highly useful in preclinical studies in regenerative medicine [3, 9, 11]. One of the advantages of using marmoset animal model is that it can evaluate the effectiveness and safety of cell transplantation therapy with a small number of cells. Furthermore, it was reported that marmosets recapitulate human liver diseases in studies of GB virus B infection, a surrogate model of hepatitis C virus infection [15], and spontaneous pathologic findings associated with nonalcoholic fatty liver disease and nonalcoholic steatohepatitis [12]. However, there are no reports of experimental hepatic fibrosis models of marmosets. Therefore, we investigated the induction of a marmoset hepatic fibrosis model by administering TAA, a hepatic fibrosis-inducing compound used for other animal models [14].

In this study, TAA was administered subcutaneously 2–3 times a week at 2.5–40.0 mg/kg to common marmosets. Weight measurement, blood biochemical tests, and histological examination by liver biopsy were performed to evaluate the presence of any liver disorder and the optimal administration dose and interval were examined.

Materials and Methods

Animals

This study was performed in strict accordance with the Regulation for Animal Experiments of the Central Institute for Experimental Animals (CIEA) based on the Guidelines for Proper Conduct of Animal Experiments (Science Council of Japan, 2006). The animal experiment protocol was approved by the CIEA Institutional Animal Care and Use Committee (approval no. 16002A).

Seven female common marmosets obtained from CLEA Japan (Tokyo, Japan), were used in this study. Six animals (A–F) were used for TAA-induced liver fibrosis models, and one (G) was used as an intact control for serum tests. The animals were 4–7 years old and weighed 303–421 g at the start of TAA administration (A–F) or serum collection (G). They were housed singly in stainless steel cages (409 × 610 × 728 mm) in a conditioned

animal room at 26–28°C and 40–60% humidity with a 12:12 h light/dark cycle. The cages included wooden perches and a wooden resting place and positioned facing each other to allow the animals to communicate visually and vocally. The animals were fed a commercial New World primate diet (CMS-1M, CLEA Japan) with added vitamins and tap water *ad libitum*, and the food was moistened with hot water to vary the texture. The marmosets were also fed supplemental foods, such as sponge cake, apple jelly, or biscuits.

TAA administration and evaluation of liver fibrosis

TAA (Sigma-Aldrich, St. Louis, MO, USA) dissolved in saline (Otsuka Pharmaceutical, Tokyo, Japan) was subcutaneously administered to each marmoset 2–3 times a week at a dose of 2.5–40 mg/kg in a volume of 1–2 ml/kg. Dose and frequency of TAA administration were changed depending on the blood test and liver biopsy results to examine the optimal protocol. Blood samples (0.5 ml) were drawn from the femoral vein once a week, and the collected serum was shipped to a commercial laboratory (Nagahama Institute for Biochemical Science, Oriental Yeast Co., Ltd., Nagahama, Japan) for albumin (ALB), aspartate aminotransferase (AST), alanine aminotransferase (ALT), lactate dehydrogenase (LDH), total bilirubin (TBIL), total bile acid (TBA), blood urea nitrogen (BUN), and creatinine (CRE) measurements. Hepatic fibrosis was assessed by liver biopsy at 3–9-week intervals when blood chemistry indicated liver disorder. Liver tissue was collected via a small abdominal incision with the animal under anesthesia with 0.04 mg/kg medetomidine, 0.40 mg/kg midazolam, 0.40 mg/kg butorphanol, and 1–3% isoflurane. Postoperative analgesia and infection control following biopsy included 1.2 mg/kg ketoprofen and 15 mg/kg ampicillin administered once daily for 3 consecutive days.

Liver tissue samples were fixed with 10% neutral buffered formalin and embedded in paraffin. Sections of the samples were stained with hematoxylin and eosin (HE), Masson trichrome, and Sirius Red, and the specimens were examined microscopically. Areas stained with Sirius Red were measured for quantitative analysis of fibrosis using a digital slide scanner (NanoZoomer S60, Hamamatsu Photonics, Hamamatsu, Japan) and ImageJ software (National Institute of Health, Bethesda, MD, USA). Blood serum samples were collected for type IV collagen 7S measurement in five marmosets when liver fibrosis was observed on liver biopsy in each animal.

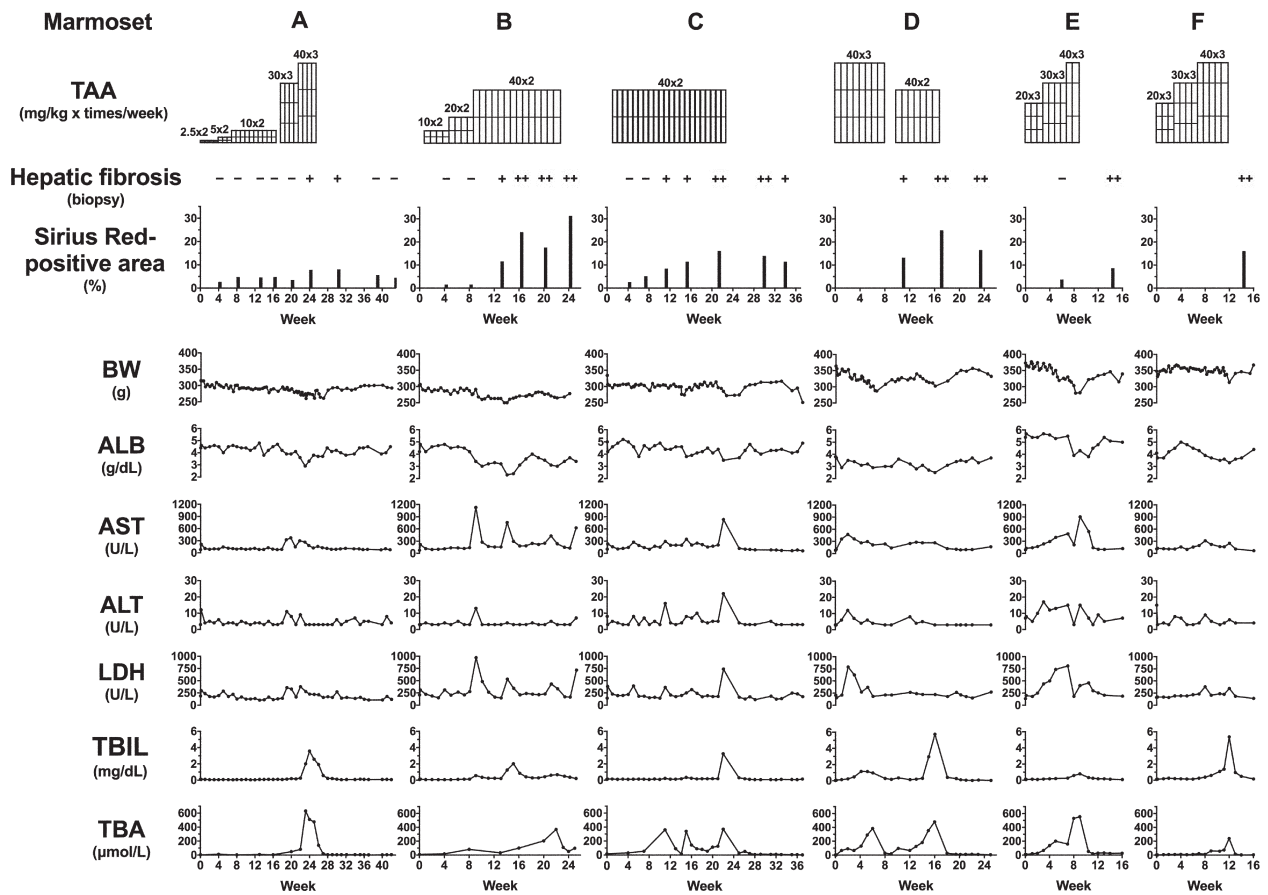


Fig. 1. Subcutaneous injection of TAA reproducibly induces hepatic fibrosis in 6 marmosets (A–E). Upper) Doses and frequencies of TAA administration, hepatic fibrosis observed in biopsy specimens, and percentages of Sirius Red staining-positive areas in these specimens; hepatic fibrosis was assessed to evaluate the severity of histopathological changes as follows: no (–), mild (+), and severe (++) . Lower) Changes of body weight (BW) and blood chemistry: albumin (ALB), aspartate aminotransferase (AST), alanine aminotransferase (ALT), lactate dehydrogenase (LDH), total bilirubin (TBIL), total bile acid (TBA).

Measurements in marmosets A, C, D, E, and F were performed after 33, 24, 18, 22, and 22 weeks of initial TAA administration, respectively. This measurement was performed 2 weeks after liver biopsy for reducing the effect of surgery. Serum samples from intact three marmosets (E and F before TAA administration and G) were also used for the measurement. Type IV collagen 7S assay was performed in a commercial laboratory (SRL Tokyo Laboratories, Tokyo, Japan).

Statistical analysis

Student unpaired, two-tailed t test was used to compare type IV collagen levels using Prism 7 (GraphPad Software, San Diego, CA, USA).

Results

Subcutaneous injection of TAA reproducibly induces hepatic fibrosis in marmosets

Due to the lack of information regarding an effective dose of TAA, we had modified the doses and frequencies of TAA administration in four trials (Fig. 1). In the first trial, we gradually increased the dose from 2.5 to 10 mg/kg twice a week in marmoset A (Fig. 1), but neither blood examinations nor liver biopsies indicated hepatic fibrosis even at 16 weeks after initial treatment. Next, TAA was increased up to 30 mg/kg three times a week after an interval of 2 weeks. A dose of TAA was further escalated to 40 mg/kg three times a week at the next 2 weeks as liver biopsy did not detected hepatic fibrosis. Then, hepatic fibrosis was detected at 24 weeks after initial treatment coupled with slight changes in blood examina-

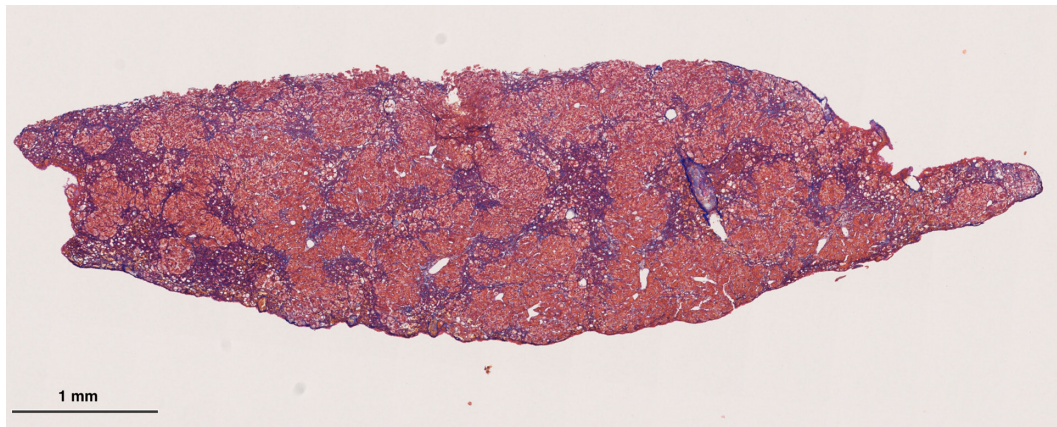


Fig. 2. Hepatic fibrosis induced by TAA in a marmoset. Tissue section with Masson trichrome staining ($\times 2.5$) was collected from marmoset D that had been subcutaneously injected with TAA at 40 mg/kg 2–3 times a week for 16 weeks (Fig. 1). Collagen fiber (blue-colored) increased in the pericentral and periportal areas with bridging among areas.

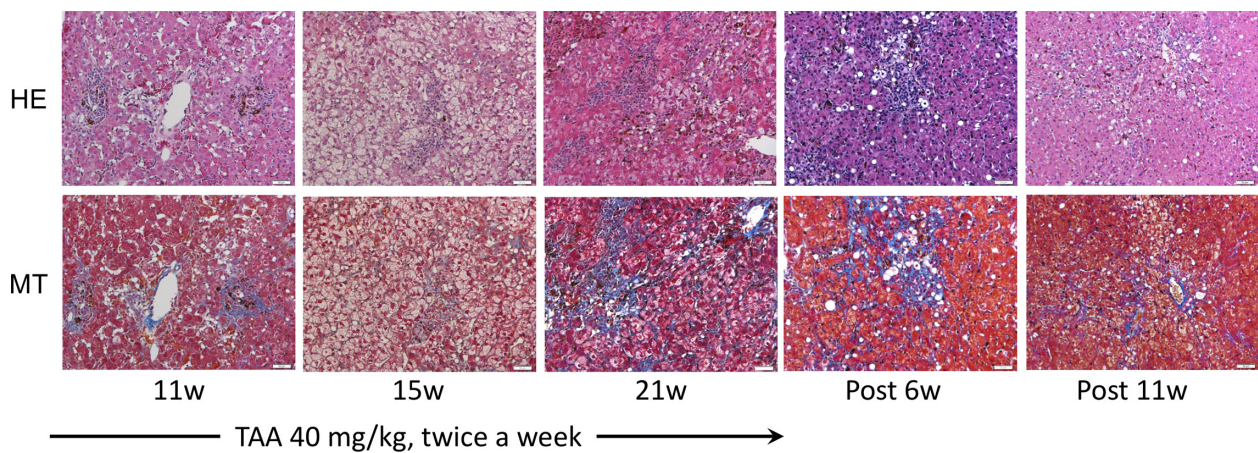


Fig. 3. Progress and recovery of hepatic fibrosis in the liver tissue of a marmoset administered TAA. Biopsy specimens with hematoxylin and eosin (HE) and Masson trichrome stain (MT) of marmoset C ($\times 200$) at each time point (w: week) are shown. Marmoset C was subcutaneously injected with TAA at a dose of 40 mg/kg twice a week for 23 weeks (Fig. 1). Collagen fiber increased with the TAA administration period, and fibrosis was observed until 11 weeks after withdrawal.

tions for AST, LDH, TBIL, and TBA levels. Biopsy specimens with Masson trichrome and Sirius Red stains showed that collagen fiber increased in pericentral regions and peritoneal areas (Fig. 1).

In the second trial, we started 10 mg/kg of TAA twice a week for 4 weeks, then increased to 20 mg/kg twice a week and continued for the next 3 weeks in marmoset B (Fig. 1). Next, we escalated TAA up to 40 mg/kg as we observed no hepatic fibrosis and then detected hepatic fibrosis 6 weeks after increasing dose to 40 mg/kg (Fig. 1). Hepatic fibrosis was persistently observed for 9 weeks with continuous TAA injections.

In the third trial, we started 40 mg/kg as an initial dose

of TAA in marmosets C and D (Fig. 1). We observed hepatic fibrosis in both the marmosets at 11 weeks after the initial treatment (Figs. 1–3). However, high-dose TAA administration resulted in temporary withdrawal due to weakening by suspected hepatic dysfunction. The marmoset D that had been administered TAA (40 mg/kg) three times a week showed anorexia and nearly 20% loss of body weight 7 weeks after initial administration. Then, we stopped TAA administration for recovery and resumed TAA injection after an interval of 2 weeks, reducing the frequency to twice a week.

In the fourth trial, TAA was injected 20, 30, and 40 mg/kg three times a week in marmosets E and F (Fig.

1). Liver biopsy detected hepatic fibrosis in the both animals 14 weeks after initial administration. However, the both animals were weakened during TAA administration period (40 mg/kg three times a week) and were withdrawn from TAA; the marmoset E showed anorexia, hypoactivity and marked body weight loss 8 weeks after initial administration, and the marmoset F showed anorexia, hypoactivity and hypothermia 11 weeks after initial administration, respectively.

Quantitative assay of hepatic fibrosis with Sirius Red staining was performed using all 28 liver biopsy specimens in which the average area (\pm SD) was 6.46 ± 2.66 mm². The rate of appearance of Sirius Red-positive area was gradually increased after 40 mg/kg of TAA administration up to 31% in marmoset B (Fig. 1).

Recovery from hepatic fibrosis after TAA cessation

Serial liver biopsies were performed to examine spontaneous recovery from hepatic fibrosis. The typical case marmoset C to which 40 mg/kg TAA was administered twice a week is shown in Fig. 3. Masson trichrome staining detected definite fibrosis at week 21 following the initiation of TAA. Notably, fibrosis was continuously observed at 6 weeks after the last injection (Fig. 3). At week 11, mild fibrosis was still observed, suggesting that TAA-induced hepatic fibrosis persists for approximately 3 months after discontinuation of TAA treatment.

Blood examinations

Mean values \pm SD of blood chemistry in 7 normal marmosets (marmosets A–F before TAA administration and marmoset G) were ALB 4.6 ± 0.6 g/dl, AST 125 ± 97 U/l, ALT 7.8 ± 4.7 U/l, LDH 184 ± 41 U/l, TBIL 0.09 ± 0.02 mg/dl, TBA 8 ± 7 μ mol/l, BUN 30.4 ± 5.7 mg/dl and CRE 0.19 ± 0.04 mg/dl. As an early response to TAA administration, AST, ALT, and LDH were increased (Fig. 1). Conversely, TBIL and TBA levels increased after relatively long-term TAA administration, possibly due to altered structure of the hepatic organs. Additionally, serum ALB level coupled with body weight tends to decrease, which could reflect chronic liver dysfunction. The marmosets that showed severe clinical signs had either high TBIL (>1 mg/dl), high TBA (>300 μ mol/l) or low ALB (<3.5 g/dl). Following TAA cessation, TBIL and TBA levels rapidly recovered in most cases. BUN and CRE levels that represent renal function slightly changed during the experimental period.

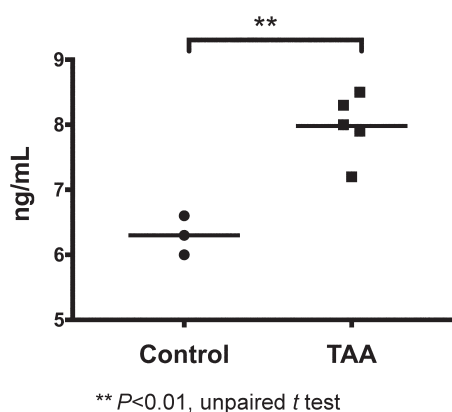


Fig. 4. Comparison of serum type IV collagen 7S between intact animals and TAA-induced hepatic fibrosis animals.

Measurement results of blood type IV collagen 7S

We measured the serum level of type IV collagen 7S, which is known as a marker for hepatic fibrosis, in TAA-treated marmosets. As shown in Fig. 4, serum levels of type IV collagen 7S in TAA-treated marmosets with hepatic fibrosis observed on liver biopsy were 7.98 ± 0.50 ng/ml (mean \pm SD, $n=5$) and were significantly higher than those in the control group (6.30 ± 0.50 ng/ml, $n=3$).

Discussion

Hepatic fibrosis is defined as the deposition of excess extracellular matrix and is based on complex interactions between matrix-producing hepatic stellate cells and abundant hepatic and infiltrating cells. Researching these pathologies and production processes requires *in vitro* and *in vivo* experimental work in animals. Although hepatic fibrosis in humans can be caused by various stimuli (congenital, metabolic, inflammatory, parasitic, vascular, toxin, or drug), the molecular mechanisms underlying fibrosis are basically the same [8]. A highly regulated program of molecular changes occurs following any kind of liver injury [7]. In fibrosis research, experimental animal models are currently the gold standard to confirm a proposed disease-associated mechanism, and these models should at least partially mimic a clinical situation. The most commonly used approach for inducing toxin-mediated experimental liver fibrosis is the periodic administration of CCl₄ or TAA in mice or rats [4]. However, there have been few reports of hepatic fibrosis models using nonhuman primates which

have advantages for preclinical translational research. This study succeeded in reproducible induction of hepatic fibrosis using TAA in common marmosets. That is the first report of a potential liver fibrosis model using the small nonhuman primate species.

As it has been reported that intraperitoneal or oral administration of TAA reproducibly induced hepatic fibrosis in rodents, we first attempted to administer TAA in drinking water [10, 20]. However, marmosets did not drink water with TAA administration; hence, we selected subcutaneous injection as an alternative route of administration. Increased dosages could reduce modeling time but greatly increase the mortality rate. Our preliminary data demonstrated that a safe dosage for subcutaneous injection of TAA is <50 mg/kg (unpublished data). This study adopted the method of administering TAA subcutaneously at 40 mg/kg 2 or 3 times a week to establish a hepatic fibrosis model in common marmosets, which showed morphological and pathophysiological similarity to human hepatic fibrosis. Furthermore, fibrosis sustained for up to 11 weeks after withdrawal of TAA. Therefore, 40 mg/kg should be an appropriate initial dose for subcutaneous injection of TAA for hepatic fibrosis in marmosets. In addition, it is considered appropriate to temporarily stop TAA administration when hepatic dysfunction occurs, and resume administration following hepatic function recovery until hepatic fibrosis occurs.

Histological examination by liver biopsy is the most accurate for estimating hepatic fibrosis but it is invasive. We found that blood levels of TBA, ALB, TBIL, and blood type IV collagen 7S could be useful markers for evaluating hepatic fibrosis. Simultaneous elevation of serum TBIL and TBA levels is a sign of acute hepatic failure. Serum TBIL and TBA levels could be good markers for determining whether we should administer TAA. It is considered appropriate to temporarily stop TAA administration when these serum markers indicate hepatic dysfunction occurs, and resume administration following hepatic function recovery until hepatic fibrosis occurs.

Type IV collagen is a main collagenous component of the basement membrane and the serum concentration of the 7S fragment of the N-terminal domain of type IV collagen (type IV collagen 7S) has been identified as a marker for assessing hepatic fibrogenesis and fibrosis [16, 19]. Serum type IV collagen 7S levels in the TAA-induced hepatic fibrosis marmosets were higher than control marmosets. This indicates monitoring this mark-

er could aid in the diagnosis of hepatic fibrosis in marmosets as in humans. The human cutoff value is 6.0 ng/ml [13] but 7.0 ng/ml could be a good cutoff value for marmosets; however, further evaluation is necessary.

The study suggests that continuous TAA administration induces progressive and persistent hepatic fibrosis in the common marmoset. A hepatic fibrosis model of common marmosets with TAA could be widely used, and established models are promising for research on preventing and treating chronic liver diseases.

Acknowledgments

This study was mainly supported by the Program for Basic and Clinical Research on Hepatitis, “Differentiation of Mesenchymal Stem Cells to Hepatic Cells by Artificial Transcriptional Factors” from the Japan Agency for Medical Research and Development (AMED) and was partially supported by the Strategic Research Program for Brain Science, “Maintenance of Systems for Creation and Spread of Primate Model Animals” from AMED. We wish to thank Dr. Kenji Kawai, Dr. Masahiko Yasuda, and Ms. Mika Yagoto for their helpful support in preparing sections of this manuscript as well as all members of the CIEA marmoset research group in Kawasaki, Japan, for the warm support.

References

1. Anderson, D.J. and Kirk, A.D. 2013. Primate models in organ transplantation. *Cold Spring Harb. Perspect. Med.* 3: a015503. [Medline] [CrossRef]
2. Brennan, F.R., Shaw, L., Wing, M.G., and Robinson, C. 2004. Preclinical safety testing of biotechnology-derived pharmaceuticals: understanding the issues and addressing the challenges. *Mol. Biotechnol.* 27: 59–74. [Medline] [CrossRef]
3. Chen, H., Hattori, F., Murata, M., Li, W., Yuasa, S., Onizuka, T., Shimoji, K., Ohno, Y., Sasaki, E., Kimura, K., Hakuno, D., Sano, M., Makino, S., Ogawa, S., and Fukuda, K. 2008. Common marmoset embryonic stem cell can differentiate into cardiomyocytes. *Biochem. Biophys. Res. Commun.* 369: 801–806. [Medline] [CrossRef]
4. Delire, B., Stärkel, P., and Leclercq, I. 2015. Animal Models for Fibrotic Liver Diseases: What We Have, What We Need, and What Is under Development. *J Clin Transl Hepatol* 3: 53–66. [Medline] [CrossRef]
5. Eom, Y.W., Kim, G., and Baik, S.K. 2015. Mesenchymal stem cell therapy for cirrhosis: Present and future perspectives. *World J. Gastroenterol.* 21: 10253–10261. [Medline] [CrossRef]
6. Forbes, S.J., Gupta, S., and Dhawan, A. 2015. Cell therapy

- for liver disease: From liver transplantation to cell factory. *J. Hepatol.* 62:(Suppl): S157–S169. [Medline] [CrossRef]
7. Gressner, A.M. and Weiskirchen, R. 2006. Modern pathogenetic concepts of liver fibrosis suggest stellate cells and TGF-beta as major players and therapeutic targets. *J. Cell. Mol. Med.* 10: 76–99. [Medline] [CrossRef]
 8. Hernandez-Gea, V. and Friedman, S.L. 2011. Pathogenesis of liver fibrosis. *Annu. Rev. Pathol.* 6: 425–456. [Medline] [CrossRef]
 9. Iwai, H., Shimada, H., Nishimura, S., Kobayashi, Y., Itakura, G., Hori, K., Hikishima, K., Ebise, H., Negishi, N., Shibata, S., Habu, S., Toyama, Y., Nakamura, M., and Okano, H. 2015. Allogeneic Neural Stem/Progenitor Cells Derived From Embryonic Stem Cells Promote Functional Recovery After Transplantation Into Injured Spinal Cord of Nonhuman Primates. *Stem Cells Transl. Med.* 4: 708–719. [Medline] [CrossRef]
 10. Kim, Y.O., Popov, Y., and Schuppan, D. 2017. Optimized Mouse Models for Liver Fibrosis. *Methods Mol. Biol.* 1559: 279–296. [Medline] [CrossRef]
 11. Kobayashi, Y., Okada, Y., Itakura, G., Iwai, H., Nishimura, S., Yasuda, A., Nori, S., Hikishima, K., Konomi, T., Fujiyoshi, K., Tsuji, O., Toyama, Y., Yamanaka, S., Nakamura, M., and Okano, H. 2012. Pre-evaluated safe human iPSC-derived neural stem cells promote functional recovery after spinal cord injury in common marmoset without tumorigenicity. *PLoS One* 7: e52787. [Medline] [CrossRef]
 12. Kramer, J.A., Grindley, J., Crowell, A.M., Makaron, L., Kohli, R., Kirby, M., Mansfield, K.G., and Wachtman, L.M. 2015. The common marmoset as a model for the study of nonalcoholic fatty liver disease and nonalcoholic steatohepatitis. *Vet. Pathol.* 52: 404–413. [Medline] [CrossRef]
 13. Kubo, S., Tsukamoto, T., Hirohashi, K., Tanaka, H., Shuto, T., Takemura, S., Yamamoto, T., Uenishi, T., Ogawa, M., and Kinoshita, H. 2004. Correlation between preoperative serum concentration of type IV collagen 7s domain and hepatic failure following resection of hepatocellular carcinoma. *Ann. Surg.* 239: 186–193. [Medline] [CrossRef]
 14. Liedtke, C., Luedde, T., Sauerbruch, T., Scholten, D., Streetz, K., Tacke, F., Tolba, R., Trautwein, C., Trebicka, J., and Weiskirchen, R. 2013. Experimental liver fibrosis research: update on animal models, legal issues and translational aspects. *Fibrogenesis Tissue Repair* 6: 19. [Medline] [CrossRef]
 15. Manickam, C. and Reeves, R.K. 2014. Modeling HCV disease in animals: virology, immunology and pathogenesis of HCV and GBV-B infections. *Front. Microbiol.* 5: 690. [Medline] [CrossRef]
 16. Murawaki, Y., Ikuta, Y., Koda, M., and Kawasaki, H. 1994. Serum type III procollagen peptide, type IV collagen 7S domain, central triple-helix of type IV collagen and tissue inhibitor of metalloproteinases in patients with chronic viral liver disease: relationship to liver histology. *Hepatology* 20: 780–787. [Medline] [CrossRef]
 17. Orsi, A., Rees, D., Andreini, I., Venturella, S., Cinelli, S., and Oberto, G. 2011. Overview of the marmoset as a model in nonclinical development of pharmaceutical products. *Regul. Toxicol. Pharmacol.* 59: 19–27. [Medline] [CrossRef]
 18. Sasaki, E. 2015. Prospects for genetically modified non-human primate models, including the common marmoset. *Neurosci. Res.* 93: 110–115. [Medline] [CrossRef]
 19. Suou, T., Yamada, S., Hosho, K., Yoshikawa, N., and Kawasaki, H. 1996. Relationship between serum and hepatic 7S fragments of type IV collagen in chronic liver disease. *Hepatology* 23: 1154–1158. [Medline] [CrossRef]
 20. Wallace, M.C., Hamesch, K., Lunova, M., Kim, Y., Weiskirchen, R., Strnad, P., and Friedman, S.L. 2015. Standard operating procedures in experimental liver research: thioacetamide model in mice and rats. *Lab. Anim.* 49:(Suppl): 21–29. [Medline] [CrossRef]
 21. Yanguas, S.C., Cogliati, B., Willebrords, J., Maes, M., Colle, I., van den Bossche, B., de Oliveira, C.P.M.S., Andraus, W., Alves, V.A.F., Leclercq, I., and Vinken, M. 2016. Experimental models of liver fibrosis. *Arch. Toxicol.* 90: 1025–1048. [Medline] [CrossRef]
 22. Zühlke, U. and Weinbauer, G. 2003. The common marmoset (*Callithrix jacchus*) as a model in toxicology. *Toxicol. Pathol.* 31:(Suppl): 123–127. [Medline] [CrossRef]