

CASE REPORT

Endoneural abscess of common popliteal nerve as first clinical manifestation of leprosy: the first reported case in history in a low-incidence country

A. BALESTRINO¹, N. RICCARDI^{2,3}, P. FIASCHI^{1,4}, P. ANANIA¹, C. MARTINOLI^{4,5}, S. GENNARO^{1,4}

¹Division of Neurosurgery, Department of Neuroscience, Ospedale Policlinico San Martino-IST, University of Genoa, Genoa, Italy;

²Department of Infectious-Tropical Diseases and Microbiology, IRCCS Sacro Cuore Don Calabria Hospital, Negrar di Valpolicella, Verona, Italy; ³Stop TB Italia Onlus, Milan, Italy; ⁴Dipartimento di Neuroscienze, Riabilitazione, Oftalmologia, Genetica e Scienze materne infantili (DINOEMI), IRCCS Ospedale Policlinico San Martino, Università di Genova, Genoa, Italy;

⁵Department of Radiology, Department of Health Sciences, Ospedale Policlinico San Martino-IST, University of Genoa, Genoa, Italy

Keywords

History • Leprosy • Neuropathy • Nerve abscess • Epineurotomy

Summary

*A migrant from Palestine came to our attention for weakness of dorsiflexion of the left foot and hypoesthesia of the homolateral common peroneal nerve territory. Skin biopsies from skin lesions in the hypoesthetic area were not diagnostic. Radiological investigation showed focal nerve enlargement with a possible focal lesion. At this time, and given the uncertainty of the diagnosis, we had to choose between medical therapy with steroid and a surgical exploration of the nerve. We decided for the latter option. Intraoperatively, we found a focal round enlargement of the nerve. Epineurotomy was performed at that level, revealing a round caseous granulomatous mass that was excised. Microbiological examination revealed presence of *Mycobacterium Leprae**

allowing diagnosis of leprosy. Medical therapy was then started, leading to resolution of clinical symptoms. Endoneural leprous abscesses are uncommon lesions that should be suspected in patients presenting with peripheral nerve dysfunction with anamnesis of travel in leprosy endemic regions or contacts with people from endemic regions with or even without skin lesions. Detection of endoneural abscesses is of critical importance because prompt surgical excision in conjunction with medical therapy leads to improvement of symptoms and permits correct diagnosis. In times of large human migrations from leprosy endemic areas, knowledge of this uncommon presentation of leprosy and its management will help lead to the best management of these patients.

Introduction

Although leprosy is one of the oldest infectious diseases in human history, it is still responsible for great morbidity and mortality [1]. In fact, more than 175,000 patients were on treatment for leprosy in 2015 [2].

In 2016, the World Health Organization (WHO) reported more than 200 000 new cases of leprosy worldwide [3]. In Italy, a low-endemic country for leprosy, only 20 cases occurred between 2016 and 2017 [4]. Most of patients acquired leprosy outside Italy with main risk factors being long stay or coming from endemic areas [5].

Due to patient's genetic variations and *Mycobacterium leprae* different tropism for skin and peripheral nerve tissue, leprosy clinical manifestations can be insidious and hard to diagnose [6].

Moreover, in European countries, where the incidence of leprosy is low and mainly due to migrants from endemic Regions, the lack of disease's awareness can delay the diagnosis [7].

Entrapment neuropathy is a common manifestation of leprosy and may benefit from decompressive surgery by means of neurolysis and epineurotomy [8]. The Neurosurgery Unit of Policlinico San Martino Hospital

in Genoa, Italy refers to one of the three 'National Hansen Disease centers' and to the only Italian third level diagnostic laboratory for Hansen Disease. At our Institution, we have performed neurosurgical decompression procedures for leprosy peripheral neuropathy in 22 patients in the last 10 years (2,2 cases per year), 14 of these in the last 5 years thus revealing a moderate increase tendency. All of these were 'imported' cases, defined by a positive anamnesis for travelling to or from endemic areas.

The aim of this case-report is to communicate a rare first clinical manifestation of leprosy, naming endoneural abscess of a peripheral (common popliteal) nerve.

Materials and methods

We are presenting the case of a patient that was treated for a leprosy abscess of a peripheral nerve at the Unit of Neurosurgery of Policlinico San Martino Hospital, Ligurian region, Italy. We have retrospectively reviewed and reported clinical data, radiological exams, anatomopathology records and subsequent follow-up documentation.

CASE REPORT

A 24 years old male Palestinian immigrant came to medical attention for dorsiflexion weakness of the left foot (graded 2 according to the Medical Research Council Manual Muscle Testing scale) [9] and hypoesthesia of the ipsilateral common peroneal nerve territory. No other strength deficits and no other hypoesthetic lesions were present. Skin lesions were present at first admission.

Biopsies were performed on the skin lesions, but histologic exam was not diagnostic, showing only non-specific chronic granulomatous dermatitis with focal neurotropism. Skin-smear examination was not performed because leprosy was initially not suspected. Blood tests revealed only unspecific inflammation without other anomalies able to help the diagnosis.

Electroneurography (ENG) was then performed on lower limb nerves, showing reduction of evoked response amplitude in the right deep peroneal nerve (DPN) and absence of response in the left DPN. This result was consistent with a bilateral asymmetric peripheral neuropathy, more severe on the left lower limb, where clinical symptoms could be observed.

In suspicion of a neural entrapment, echography of the ischiatic nerve was then performed revealing on the left side a predominantly focal large dimensional increase of the left common peroneal nerve ($67,6 \text{ mm}^2$) from the lateral femoral condyle to the peroneal neck (Fig. 1).

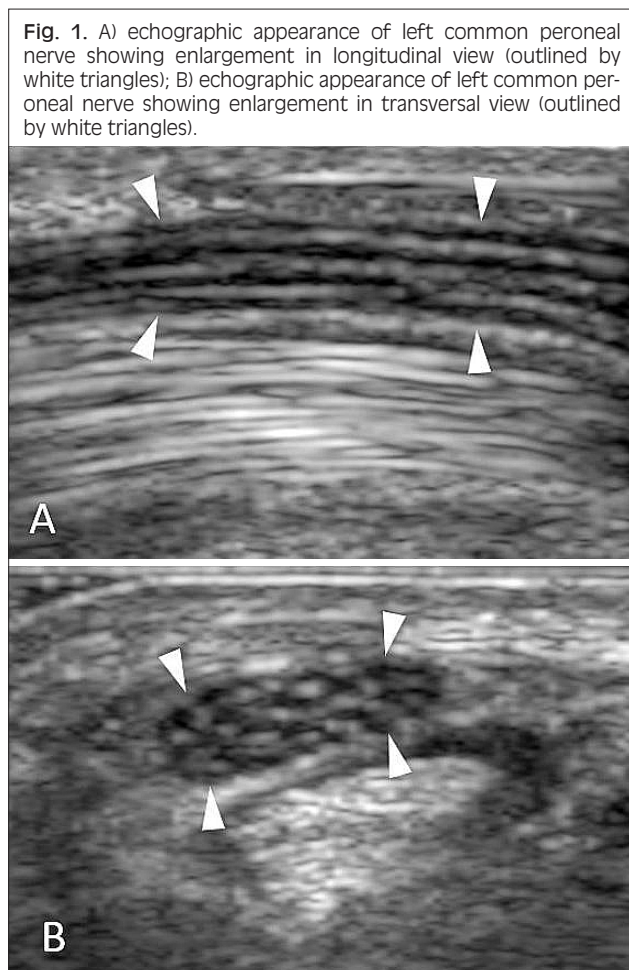


Fig. 1. A) echographic appearance of left common peroneal nerve showing enlargement in longitudinal view (outlined by white triangles); B) echographic appearance of left common peroneal nerve showing enlargement in transversal view (outlined by white triangles).

Echographic structure in that nerve tract was subverted and inhomogeneous and Doppler appearance was hypovascular. Ischiatic nerve on right side showed a normal echographic appearance.

Magnetic Resonance Imaging (MRI) was then performed to better investigate the focal nerve enlargement seen at echography. It showed enlargement and inhomogeneity of the common peroneal nerve, all the way from its origin from the ischiatic nerve until its bifurcation into superficial and deep peroneal nerves. At the level of this bifurcation the MRI showed a focal area of signal alteration with a liquid core and a thin wall.

Electromyography (EMG) showed a severe peripheral neurogenic lesion at tibialis anterior muscle, possible signs of peripheral neurogenic lesion at left gastrocnemius muscle and no involvement of other muscles. This finding was consistent with the presence of the liquid-core lesion seen at the MRI.

We repeated echography that did not show variations from the previous exam and was not able to clearly detect the lesion seen at MRI.

Thus, while the clinical picture and the echography could not rule out an entrapment neuropathy at the peroneal capitol, the MRI clearly showed a focal lesion. We had to choose between aspecific conservative medical treatment with steroids and explorative surgery. We decided for the latter option.

After isolation of the common peroneal nerve, just before its bifurcation we observed a focal round enlargement (Fig. 2). Epineurotomy was performed at that level, revealing a round caseous granulomatous mass that was excised (Fig. 2). Microbiological examination revealed presence of *Mycobacterium Leprae* allowing diagnosis of leprosy. Appropriate medical therapy was then started. Follow up echography was repeated 18 months after treatment, showing significant volume reduction of common peroneal nerve ($29,3 \text{ mm}^2$, down from the initial $67,6 \text{ mm}^2$). Clinical symptoms resolved after surgery.

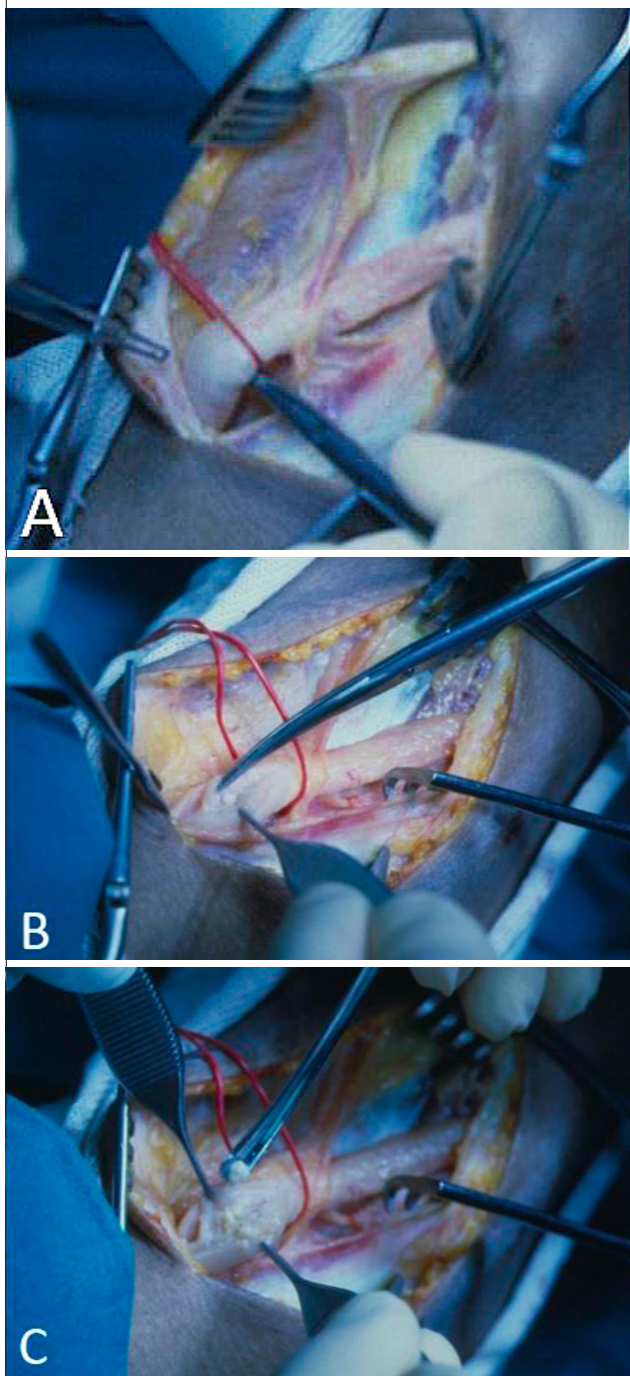
Discussion

Neuropathy is a trivial manifestation of leprosy disease that needs prompt diagnosis and treatment to allow relief of symptoms [10]. Leprosy neuropathy may present as an entrapment neuropathy that, even lacking high-level evidence, may benefit from surgery and concomitant corticosteroid therapy [11].

Less frequently than entrapment neuropathy, peripheral lepromatous nerve abscesses can occur. While these lesions have been described in endemic countries [12], to the best of our knowledge this is the first case reported from a non-endemic country.

It is useful to notice how a surgical operation may represent not only a therapeutic procedure but also an important diagnostic tool when the diagnosis is not clearly defined, and when the correct diagnosis is initially mistaken [6].

Fig. 2. A) exposition of common peroneal nerve with evidence of focal round enlargement; B) epineurotomy and exposition of endoneural abscess; C) excision of endoneural abscess.



A precise diagnosis is of critical importance to plan the correct surgical procedure. External neurolysis, which is viable in cases of entrapment neuropathy [4] may not lead to symptoms relief if there is an underlying endoneural abscess that conversely will be best treated with epineurotomy and surgical excision. Echography, MRI and neurophysiological investigations are useful tools that permit to achieve the correct diagnosis of the underlying lesion [13].

Echographic appearance of endoneural leprosy abscesses is usually characterized by focal hypoechogenicity,

fascicular pattern disorganization, marked focal thickening with sometimes a predominantly anechoic roundish lesion inside the nerve [14].

MRI is useful in detecting leprosy nerve abscesses. MRI appearance is characterized by a peripherally enhancing lesion, T1 hypointense and T2 hyperintense, inside a T2 hyperintense nerve, expression of inflammation [15].

Lack of knowledge of such a leprosy neuropathy presentation may lead to delay in diagnosis and treatment, with subsequent loss of chance of clinical improvement. Delay in diagnosis has been reported in developed western countries that account for a very small number of cases per year [16].

Conclusions

Knowledge of this uncommon presentation of leprosy will gain increasing importance in the near future. In times of large human migrations from leprosy endemic countries, this condition that physicians from leprosy low incidence countries may have only anecdotically seen, will be more and more frequently encountered.

Acknowledgements

Funding sources: this research did not receive any specific grant from funding agencies in the public, commercial, or not-for-profit sectors.

Conflict of interest statement

The authors declare no conflict of interest.

Authors' contributions

SG and AB conceived the study, AB and NR drafted the manuscript; SG, PA and PF revised the manuscript. AB and NR reviewed the literature. CM provided radiological images. All authors critically revised the manuscript. All authors have read and approved the latest version of the manuscript.

References

- [1] Fischer M. Leprosy - an overview of clinical features, diagnosis, and treatment. *J Dtsch Dermatol Ges* 2017;15:801-27. <https://doi.org/10.1111/ddg.13301>
- [2] WHO Global leprosy update, 2015: time for action, accountability and inclusion. 2018. Available at: https://www.who.int/lep/resources/who_wer9135/en
- [3] Regional Office for South-East Asia. Guidelines for the Diagnosis, Treatment and Prevention of Leprosy. 2018. Available at: <https://apps.who.int/iris/bitstream/handle/10665/274127/9789290226383-literature-review-eng.pdf>
- [4] Italian Health Ministry. Giornata mondiale dei malati di lebbra. 2019. Available at: http://www.salute.gov.it/portale/news/p3_2_1_1_1.jsp?lingua=italiano&menu=notizie&p=dalministero&id=3587 (accessed 18 Apr 2020).

- [5] Riccò M, Vezzosi L, Balzarini F, Mezzoiuso AG, Ranzieri S, Vaccaro FG, Odone A, Signorelli C. Epidemiology of leprosy in Italy (1920-2019): a comprehensive review on existing data. *Acta Biomed* 2019;90:7-14. <https://doi.org/10.23750/abm.v90i9-S.8695>
- [6] Simeoni S, Puccetti A, Tinazzi E, Codella OM, Sorleto M, Patuzzo G, Colato C, Tessari G, Lunardi C. Leprosy initially misdiagnosed as sarcoidosis, adult-onset still disease, or auto-inflammatory disease. *J Clin Rheumatol* 2011;17:432-5. <https://doi.org/10.1097/RHU.0b013e31823a55e5>
- [7] Balestrino A, Fiaschi P, Riccardi N, Camera M, Anania P, Martinoli C, Gennaro S. Neurosurgical treatment of leprosy neuropathy in a low-incidence, European country. *Neurol Sci* 2019;40:1371-5. <https://doi.org/10.1007/s10072-019-03835-1>
- [8] Wan EL, Rivadeneira AF, Jouvin RM, Dellon AL. Treatment of peripheral neuropathy in leprosy: the case for nerve decompression. *Plast Reconstr Surg Glob Open* 2016;4:e637. <https://doi.org/10.1097/GOX.0000000000000641>
- [9] Aids to the examination of the peripheral nervous system. London: her Majesty's stationery office. 1976. Available at: <https://mrc.ukri.org/documents/pdf/aids-to-the-examination-of-the-peripheral-nervous-system-mrc-memorandum-no-45-superseding-war-memorandum-no-7>
- [10] Gennaro S, Secci F, Fiaschi P, Meriadri P. Supraorbital nerve entrapment neuropathy in Hansen's disease. *Neurol Sci* 2013;34:2243-4. <https://doi.org/10.1007/s10072-013-1482-x>
- [11] Husain S. Decompression of peripheral nerve trunks in leprosy prevents the development and progression of deformities? *Indian J Lepr* 2013;85:163-9. <https://doi.org/10.4103/0019-5413.38586>
- [12] Salafia A, Chauhan G. Nerve abscess in children and adults leprosy patients: analysis of 145 cases and review of the literature. *Acta Leprol* 1996;10:45-50.
- [13] Martinoli C, Derchi LE, Bertolotto M, Gandolfo N, Bianchi S, Fiallo P, Nunzi E. US and MR imaging of peripheral nerves in leprosy. *Skeletal Radiol* 2000;29:142-50. <https://doi.org/10.1007/s002560050584>
- [14] Lugão HB, Andrey M, Frade C, Mazzer N, Foss NT, Nogueira-Barbosa MH. Leprosy with ulnar nerve abscess: ultrasound findings in a child. *Skeletal Radiol* 2017. <https://doi.org/10.1007/s00256-016-2517-1>
- [15] Bagga B, Das CJ. MRI of radial cutaneous nerve abscess in recurrent neural leprosy Images in recurrent neural leprosy. *BMJ Case Rep* 2018;11:e228704. <https://doi.org/10.1136/bcr-2018-228704>
- [16] Turner D, Mcguiness S, Leder K. Leprosy: Diagnosis and management in a developed setting. *Intern Med J* 2015;45:109-12. <https://doi.org/10.1111/imj.12638>

Received on March 1, 2020. Accepted on April 20, 2020.

Correspondence: Alberto Balestrino, Division of Neurosurgery, Department of Neuroscience, Ospedale Policlinico San Martino-IST, University of Genoa, largo Rosanna Benzi 10, 16132 Genoa, Italy - Tel.:+39 3405836354 - E-mail: alberto.balestrino@gmail.com

How to cite this article: Balestrino A, Riccardi N, Fiaschi P, Anania P, Martinoli C, Gennaro S. Endoneural abscess of common popliteal nerve as first clinical manifestation of leprosy: the first reported case in history in a low-incidence country. *J Prev Med Hyg* 2020;61:E148-E151. <https://doi.org/10.15167/2421-4248/jpmh2020.61.2.1492>

© Copyright by Pacini Editore Srl, Pisa, Italy

This is an open access article distributed in accordance with the CC-BY-NC-ND (Creative Commons Attribution-NonCommercial-NoDerivatives 4.0 International) license. The article can be used by giving appropriate credit and mentioning the license, but only for non-commercial purposes and only in the original version. For further information: <https://creativecommons.org/licenses/by-nc-nd/4.0/deed.en>