



Case Report

Stent-assisted coil embolization of unruptured vertebral artery dissecting aneurysms with the low-profile visualized intraluminal support stent, with five techniques: Technical note and case report

Ryosuke Maeoka¹, Ichiro Nakagawa¹, Koji Omoto¹, Takeshi Wada², Kimihiko Kichikawa², Hiroyuki Nakase¹

¹Department of Neurosurgery, ²Department of Radiology, Nara Medical University, Nara Prefecture, Japan.

E-mail: Ryosuke Maeoka - r.maeoka@narmed-u.ac.jp; *Ichiro Nakagawa - nakagawa@nmu-gw.narmed-u.ac.jp; Koji Omoto - koujiplain128@gmail.com; Takeshi Wada - twneuro@m5.kcn.ne.jp; Kimihiko Kichikawa - kichika@narmed-u.ac.jp; Hiroyuki Nakase - nakasehi@narmed-u.ac.jp



***Corresponding author:**

Ichiro Nakagawa,
Department of Neurosurgery,
Nara Medical University,
840 Shijo-cho, Kashihara,
Nara 634-8522, Japan.

nakagawa@nmu-gw.narmed-u.ac.jp

Received : 11 May 19
Accepted : 16 May 19
Published : 19 June 19

DOI
10.25259/SNI-293-2019

Quick Response Code:



ABSTRACT

Background: Intracranial vertebral artery dissecting aneurysm (VADA) is rare and shows high morbidity and mortality rates when the aneurysm ruptures. Endovascular treatment for VADA is one of the optimal treatments, but the dominant side VA and its branches or perforators need to be preserved. We report a novel and successful stent-assisted coil embolization technique using the low-profile visualized intraluminal support (LVIS) stent, with five technical notes in three consecutive cases of unruptured vertebral artery dissecting aneurysm (VADA).

Case Description: We report three consecutive cases of unruptured VADA which involved a posterior inferior cerebellar artery (PICA), an anterior spinal artery, and perforators. Stent-assisted coil embolization with the LVIS stent was performed in all patients. The stent was carefully placed to obtain parent artery wall apposition at distal portion and with moderate pushing at aneurysm portion. The LVIS stent was placed with tailor-made wall apposition at perforating arterial side in the barrel view, and coil embolization was performed avoiding doughnut-like stent form to prevent perforator infarcts. All cases showed complete occlusion of the aneurysms with preservation of both parent artery and its branches and perforators patency. In three cases, clinical presentations were improved without ischemic complications. The median follow-up period was 1 year. At present, no recurrence and no complication have been observed.

Conclusion: We demonstrate the coil embolization of VADA using LVIS stent with five techniques. Our techniques for the treatment of VADA using LVIS stent are safe and can minimize ischemic complications by creating suitable wall apposition to the orifices of branches or perforators.

Keywords: Intracranial vertebral artery dissecting aneurysm, Ischemic complications, Low-profile visualized intraluminal support stent, Stent-assisted coil embolization

INTRODUCTION

Intracranial vertebral artery dissecting aneurysm (VADA) has been known as a cause of subarachnoid hemorrhage and infarcts of the posterior circulation. Various surgical techniques have been reported for the treatment of these lesions, but endovascular treatment could be one of the optimal treatments, obviating the need for complex skull base approaches.

Endovascular treatment modalities include reconstructive techniques using stents with or without coil embolization and deconstructive techniques such as proximal occlusion or internal trapping.^[8] However, the V4 segment of VA has the orifices of the posterior inferior cerebellar artery (PICA), anterior spinal artery (ASA), and perforators feeding brainstem. Since occlusion of these branches and perforators leads to neurological deterioration, preservation of these branches and perforators is mandatory in the endovascular treatment strategy.^[7,9] Furthermore, the parent circulation in the dominant side VA needs to be preserved because occlusion of the dominant VA parent artery could result in ischemic complications or hemodynamic alterations causing contralateral VADA.^[8] Several studies have reported the Pipeline embolization device as safe and effective, but delayed complications such as perforator infarcts and ruptured aneurysms have remained unresolved.^[3,4]

We report our technical tips of the low-profile visualized intraluminal support (LVIS) stent-assisted coil embolization for intracranial VADA.

MATERIALS AND METHODS

We report three consecutive cases of unruptured VADA which involved a PICA, an ASA, and perforators. Stent-assisted coil embolization with the LVIS stent was performed in all patients. All procedures were performed at Nara

Medical University. Informed consent was obtained from all patients included in this study. Information relating to the patients was collected from their medical record.

All procedures were performed under general anesthesia. All patients were pretreated with dual antiplatelet therapy (100 mg/day of aspirin and 75 mg/day of clopidogrel) for at least 7 days before the procedure. During the procedure, heparin was intravenously infused with the goal of achieving an activated clotting time of >250 s. Dual antiplatelet therapy was continued for 3 months after the procedure.

RESULTS

Case 1

A 59-year-old man suffered from the right Wallenberg syndrome due to the right VA dissection. Magnetic resonance angiography (MRA) showed a left unruptured VADA located on the dominant side. Follow-up MRA demonstrated that the VADA was getting bigger and stent-assisted coil embolization was planned for the preservation of the parent circulation. 3D rotational angiography (3DRA) revealed no remarkable perforating arteries involved in the VADA [Figure 1a]. Before treatment, a “true barrel viewed position and working position” was confirmed on 3DRA [Figure 1b and c]. A jailed Excelsior SL-10 microcatheter (Stryker, Kalamazoo, MI) was introduced to the VADA sac. A Headway 21 microcatheter (MicroVention-Terumo,

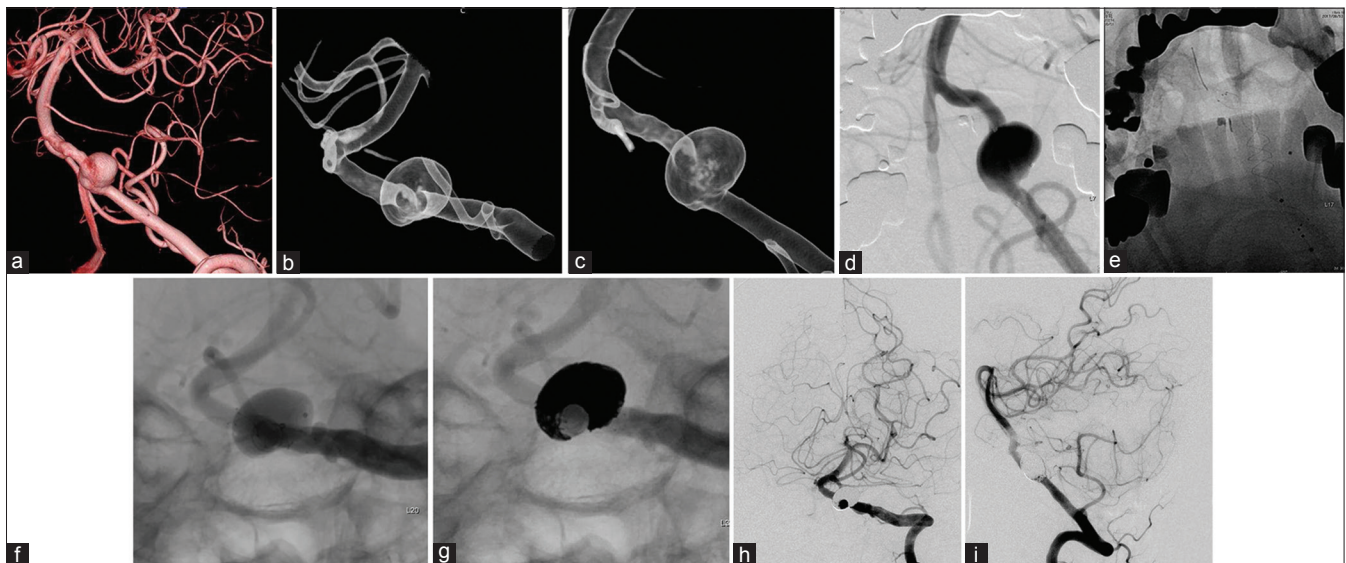


Figure 1: (a) 3D rotational angiography and digital subtraction angiography demonstrated a left vertebral artery dissecting aneurysm (10×13 mm in diameter). On 3D rotational angiography, a left vertebral artery dissecting aneurysm is located on the dominant side with no involvement of perforating arteries. (b) A 3D translucent road map view of the true barrel viewed position (B) and of the working position (C). (c) A 3D translucent road map view of the true barrel viewed position (B) and of the working position (C). (d and e) Deployment of the LVIS stent with “natural wire pushing.” (f and g) The LVIS stent was placed with “tailor-made wall apposition at perforating arterial side” and coil embolization with “escaping doughnut-like form” in the true barrel viewed position. (h and i) Digital subtraction angiography after 3 months shows complete occlusion and maintenance of the parent circulation.

Tustin, California, USA) was placed across the VADA neck and used to deploy a 4.5 × 32-mm LVIS stent. The LVIS stent was back-loaded and deployed by unsheathing while withdrawing the microcatheter. The microcatheter was then pushed inside the LVIS stent through the inner delivery wire of the stent to expand the distal struts while being careful of “parent artery wall apposition at distal portion” and with moderate pushing, called, “natural wire pushing” [Figure 1d and e]. Finally, the LVIS stent was completely deployed by pushing on the pusher wire of the stent. The LVIS stent was placed with “tailor-made wall apposition at perforating arterial side” in the barrel view, and coil embolization was performed with “escaping doughnut-like form” to prevent perforator infarcts [Figure 1f and g]. We used small 3D coils to prevent doughnut-like coil embolization in the barrel view because large coils could invade any gap between the orifice of the perforator and the stent wall. A thrombus between the orifice of a perforator and the stent wall would cause perforator infarcts. We attributed the lack of perioperative complications to these five techniques for adhering to the orifice. Glasgow outcome scale (GOS) is 5 at discharge. Follow-up MRA a day later and digital subtraction angiography (DSA) 3 months later showed complete occlusion of the aneurysms while the parent circulation remained intact [Figure 1h and i].

Case 2

A 52-year-old man presented with headache and MRA showed a left unruptured VADA. He was introduced to our institute after enlargement of the aneurysm. DSA revealed a VADA on the dominant side with involvement of the orifice of the ASA [Figure 2a and b]. We planned stent-assisted coil embolization preserving the ASA circulation using our five techniques, as described above. Postoperative course was uneventful, and the patient was discharged with GOS 5. Follow-up MRA after 1 day, 1 week, and 1 year and DSA after 3 months all showed complete occlusion of the aneurysm with maintenance of both parent artery and ASA patency [Figure 2c and d].

Case 3

A 66-year-old man showed enlarged left VADA involving the orifice of the PICA [Figure 3a and b]. We successfully performed endovascular treatment with the techniques described above [Figure 3c and d]. Follow-up MRA 1 year later showed complete occlusion of the aneurysm with PICA patency.

DISCUSSION

Standard endovascular treatment for VADA had been proximal occlusion or internal trapping of the VA, but

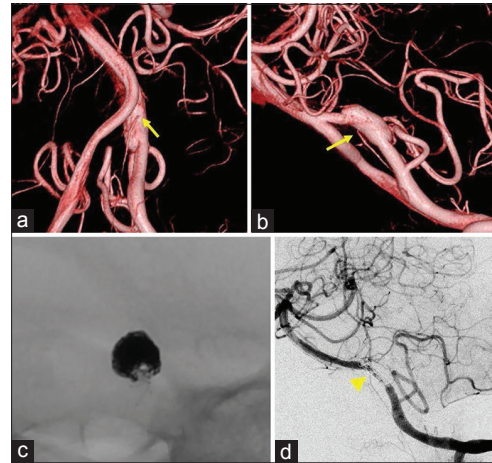


Figure 2: (a and b) 3D rotational angiography and digital subtraction angiography demonstrated a left vertebral artery dissecting aneurysm (5.6×5.2 mm in diameter). On 3D rotational angiography, a left vertebral artery dissecting aneurysm located on the dominant side with involving the orifice of anterior spinal artery (arrow). (c) The LVIS stent was placed with “tailor-made wall apposition at perforating arterial side.” Coil embolization was performed with “escaping doughnut-like form” in the true barrel viewed position. (d) Digital subtraction angiography after 3 months shows complete occlusion and maintenance of parent artery and anterior spinal artery circulation (arrowhead).

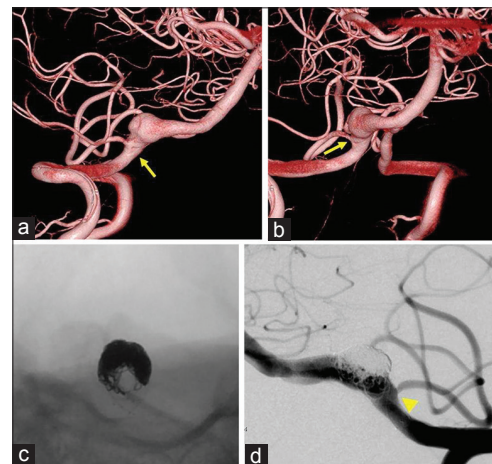


Figure 3: (a and b) 3D rotational angiography and digital subtraction angiography demonstrated a right vertebral artery dissecting aneurysm (9.1×8.4 mm in diameter). On 3D rotational angiography, a right vertebral artery dissecting aneurysm located on the dominant side with involving the orifice of the posterior inferior cerebellar artery (arrow). (c) The LVIS stent was placed with “tailor-made wall apposition at perforating arterial side.” Coil embolization was performed with “escaping doughnut-like form” in the true barrel viewed position. (d) Angiogram in the working position. Posterior inferior cerebellar artery patency is maintained (arrowhead).

occlusion of the dominant VA parent artery could result in ischemic complications or hemodynamic alterations,

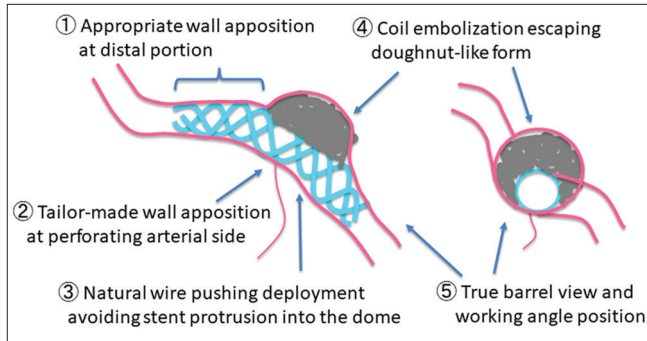


Figure 4: Illustration of five techniques for vertebral artery dissecting aneurysms.

risking contralateral VADA.^[8] The recent development of the neck-bridged stent enables preservation of the parent artery patency during the treatment of VADA. However, stent-assisted coil embolization with a standard stent deploying technique for an intracranial saccular aneurysm may cause branch and perforator occlusion when gaps are present between the stent and orifice of these branches.^[7,9] The efficacy of reconstructive techniques with flow diverters for VADA has recently been reported, but delayed complications such as perforator infarcts and ruptured aneurysms remain unresolved.^[3,4] We consider that our five techniques can resolve these problems and obtain appropriate wall apposition of the LVIS stent [Figure 4].

However, some limitations of our techniques should be noted. First, it is difficult to treat when the perforator is on the aneurysm wall. There is no feasible way to protect the orifice of the perforator. Second, due to the low porosity of the LVIS stent, it is difficult to treat the recurrence of the aneurysms with trans-cell approach. Third, we report only three cases, the small number of cases in a single institution, and the short-term follow-up period. It is very scant to prove the efficacy of these techniques.

Many studies have reported the LVIS stent as safe and effective in the treatment of ruptured and unruptured intracranial saccular aneurysms.^[2,5,6,10] Since the LVIS stent is braided with a single nickel-titanium (nitinol) wire, the stents are visible under fluoroscopy. This characteristic allows easy confirmation of complete stent opening and wall apposition of the stent.^[6] Furthermore, the LVIS is resheathable and repositionable, and retrievable up to 80% of its length.^[1,5] However, in deploying an LVIS stent for VADA using the same technique applied for saccular aneurysms, excessive wire pushing could create a gap between the orifice of a branch or perforator and the stent, and coils could invade this gap and result in perforator or branch occlusion. In the case of stent-assisted coil embolization for VADA, our five techniques may minimize ischemic complications by creating suitable wall apposition to the orifices of branches or

perforators. In the future, a clinical study accumulating more cases and long-term follow-up data will be required.

CONCLUSION

We report a novel stent-assisted coil embolization technique using the LVIS stent, with five techniques in three consecutive cases of unruptured VADA. These five techniques may minimize ischemic complications by creating suitable wall apposition to the orifices of branches or perforators. Our small case series demonstrates the coil embolization with LVIS stent with five techniques is safe and good clinical outcomes and suggests that it could improve the outcomes of endovascular treatment of the VADA.

Declaration of patient consent

The authors certify that they have obtained all appropriate patient consent forms. In the form, the patients have given their consent for their images and other clinical information to be reported in the journal. The patients understand that their names and initials will not be published and due efforts will be made to conceal their identity.

Financial support and sponsorship

Nil.

Conflicts of interest

There are no conflicts of interest.

REFERENCES

1. Grossberg JA, Hanel RA, Dabus G, Keigher K, Haussen DC, Sauvageau E, *et al.* Treatment of wide-necked aneurysms with the low-profile visualized intraluminal support (LVIS jr) device: A multicenter experience. *J Neurointerv Surg* 2017; 9:1098-102.
2. Iosif C, Piotin M, Saleme S, Barreau X, Sedat J, Chau Y, *et al.* Safety and effectiveness of the low profile visualized intraluminal support (LVIS and LVIS jr) devices in the endovascular treatment of intracranial aneurysms: Results of the TRAIL multicenter observational study. *J Neurointerv Surg* 2018;10:675-81.
3. Kühn AL, Kan P, Massari F, Lozano JD, Hou SY, Howk M, *et al.* Endovascular reconstruction of unruptured intradural vertebral artery dissecting aneurysms with the pipeline embolization device. *J Neurointerv Surg* 2016;8:1048-51.
4. Natarajan SK, Lin N, Sonig A, Rai AT, Carpenter JS, Levy EI, *et al.* The safety of pipeline flow diversion in fusiform vertebrobasilar aneurysms: A consecutive case series with longer-term follow-up from a single US center. *J Neurosurg* 2016;125:111-9.
5. Poncyjusz W, Biliński P, Safranow K, Baron J, Zbrozczyk M, Jaworski M, *et al.* The LVIS/LVIS jr. Stents in the treatment of wide-neck intracranial aneurysms: Multicentre registry.

- J Neurointerv Surg 2015;7:524-9.
6. Shankar JJ, Quateen A, Weill A, Tampieri D, Cortes MD, Fahed R, *et al.* Canadian registry of LVIS jr for treatment of intracranial aneurysms (CaRLA). J Neurointerv Surg 2017;9:849-53.
 7. Siddiqui AH, Abla AA, Kan B, Dumont TM, Jahshan S, Britz GW, *et al.* Panacea or problem: Flow diverters in the treatment of symptomatic large or giant fusiform vertebrobasilar aneurysms. J Neurosurg 2012;116:1258-66.
 8. Sönmez Ö, Brinjikji W, Murad MH, Lanzino G. Deconstructive and reconstructive techniques in treatment of vertebrobasilar dissecting aneurysms: A systematic review and meta-analysis. AJNR Am J Neuroradiol 2015;36:1293-8.
 9. van Rooij WJ, Sluzewski M. Perforator infarction after placement of a pipeline flow-diverting stent for an unruptured A1 aneurysm. AJNR Am J Neuroradiol 2010;31:E43-4.
 10. Zhang X, Zhong J, Gao H, Xu F, Bambakidis NC. Endovascular treatment of intracranial aneurysms with the LVIS device: A systematic review. J Neurointerv Surg 2017;9:553-7.

How to cite this article: Maeoka R, Nakagawa I, Omoto K, Wada T, Kichikawa K, Nakase H. Stent-assisted coil embolization of unruptured vertebral artery dissecting aneurysms with the low-profile visualized intraluminal support stent, with five techniques: Technical note and case report. Surg Neurol Int 2019;10:105.