



Central nervous system tuberculoma with miliary tuberculosis in the elderly

Syuichi Tetsuka*, Tomohiro Suzuki, Tomoko Ogawa, Ritsuo Hashimoto, Hiroyuki Kato

Department of Neurology, International University of Health and Welfare Hospital, 537-3, Iguchi, Nasushiobara, Tochigi, 329-2763, Japan

ARTICLE INFO

Article history:

Received 21 November 2019

Received in revised form 27 January 2020

Accepted 27 January 2020

Keywords:

Central nervous system
Elderly
Miliary tuberculosis
Tuberculoma

ABSTRACT

The aging phenomenon of tuberculosis (TB) patients is recognized all over the world, but no country is as prominent as Japan. Central nervous system (CNS) TB includes clinical entities: tuberculous meningitis, intracranial tuberculoma, and clinical features of CNS TB in the elderly may be atypical, non-specific, and confused with concomitant age-related diseases. Atypical clinical manifestations of TB in older persons can result in delay in diagnosis and initiation of treatment. A 91-year-old woman was brought to our emergency department after her family noted her altered mental status. Chest computed tomography confirmed miliary opacities. The cerebrospinal fluid (CSF) analysis showed elevated protein level, low glucose level, and a lymphocytic pleocytosis. Brain magnetic resonance imaging (MRI) showed multiple well-defined enhancing lesions in the cerebral and cerebellar hemispheres and the pons, suggestive of tuberculomas. Smear, culture, and polymerase chain reaction (PCR) tests confirmed *Mycobacterium tuberculosis* in the sputum and aspirate. Based on the CSF and brain MRI findings and the sputum microbiology results indicating the presence of *M. tuberculosis* in the sputum and gastric aspirate, the patient was diagnosed with CNS tuberculoma. The onset of TB is mainly associated with decreased immunity; however, several other factors such as comorbidities, decreased activity, dysphagia, and malnutrition, which influence one another, also influence the development of TB in the elderly. Because the mortality rate of TB increases rapidly with age, reaching approximately 30 % among the elderly, early diagnosis is critical.

© 2020 The Author(s). Published by Elsevier Ltd. This is an open access article under the CC BY-NC-ND license (<http://creativecommons.org/licenses/by-nc-nd/4.0/>).

Introduction

The most common manifestation of tuberculosis (TB) is pulmonary. Central nervous system (CNS) TB is rare and often due to hematogenous spread from the lung and most devastating forms of human mycobacterial infection [1]. CNS TB accounts for 1 % of all TB cases and 5 % of extrapulmonary TB cases [2]. Diagnosis of TB can be more difficult and consequently overlooked. If treatment is delayed especially, CNS TB has a worse outcome than pulmonary TB [3]. Neuroimaging supports diagnosis, assessment for complications, and monitoring of the clinical course for CNS TB. In the elderly, clinical features of TB may be atypical, non-specific, and confused with concomitant age-related diseases and the immune system undergoes a gradual weakening with age, a condition known as immunosenescence. Atypical clinical manifestations of TB in older persons can result in delay in diagnosis and initiation of treatment. Early and adequate access to health care through their primary care physicians is therefore crucial for the

elderly. Here, we present a case of miliary TB that subsequently seem to have evolved into CNS TB (tuberculous meningitis and intracranial tuberculomas) in the elderly.

Case report

We report the case of a 91-year-old woman with a history of chronic obstructive pulmonary disease, lumbar compression fracture, and moderate Alzheimer's disease who was admitted to our emergency department following the development of altered mental status. She had no history of treatment with immunosuppressants or steroids. Over the three weeks before admission, her appetite waned; she progressively became more lethargic and did not eat or communicate for over 24 h. Upon arrival, she opened her eyes in response to verbal stimulation and responded to painful stimulation but could not follow verbal instructions. Her initial vital signs were as follows: heart rate, 70 beats/min; respiratory rate, 14 breaths/min; blood pressure, 107/69 mmHg; body temperature, 36.9 °C; and oxygen saturation, 96 % in room air. Clinical examination confirmed decreased bilateral air entry with bibasal crackles in lungs. Examination of the abdomen, extremities, and skin was insignificant. Neurological examination

* Corresponding author.

E-mail address: syuichi@jichi.ac.jp (S. Tetsuka).

revealed neck stiffness but no other gross focal neurological deficits. Her white blood cell count and C-reactive protein concentration were 4990/ μ l (neutrophils, 79.8 %; lymphocytes, 17.4 %; monocytes, 2.8 %) and 4.21 mg/L, respectively. Serum creatinine and electrolyte concentrations were normal. Based on the presence of diffuse ground-glass opacities in bilateral lung fields by chest X-ray at admission, chest computed tomography (CT) was performed. Chest CT confirmed miliary opacities without mediastinal or hilar lymphadenopathy (Fig. 1). Cerebrospinal fluid (CSF) analysis showed increased protein concentration (374 mg/dL) and low glucose concentration (12 mg/dL, with a serum glucose concentration of 113 mg/dL) with 180 nuclear cells/ mm^3 (129 mononuclear cells/ mm^3 and 51 polynuclear cells/ mm^3). T1-weighted gadolinium-enhanced brain magnetic resonance imaging (MRI) showed multiple well-defined enhancing lesions in the cerebral and cerebellar hemispheres and pons, which were suggestive of tuberculomas (Fig. 2). The smears of the sputum and gastric aspirate containing acid-fast bacilli (AFB) were graded as Gaffky 5 and 1, respectively. Culture, and polymerase chain reaction (PCR) evaluations confirmed the presence of *Mycobacterium tuberculosis*. Thus, she was transferred to a nearby hospital specializing in TB treatment. *M. tuberculosis* cultures of the sputum and gastric aspirate showed sensitivity for all anti-TB drugs including rifampicin, whereas the CSF culture was negative. The patient was started on tuberculostatic treatment with rifampicin (450 mg/day, 13.6 mg/kg/day), isoniazid (300 mg/day, 9.1 mg/kg/day), pyrazinamide (1,500 mg/day, 45.5 mg/kg/day), ethambutol (450 mg/day, 13.6 mg/kg/day), and vitamin B6, which were administered using a nasogastric tube together with the intravenous administration of adjunctive corticosteroids (Dexamethasone Sodium Phosphate, 13.2 mg/day, 0.4 mg/kg/day). However, the patient died three months after being transferred from our hospital without improving her general condition.

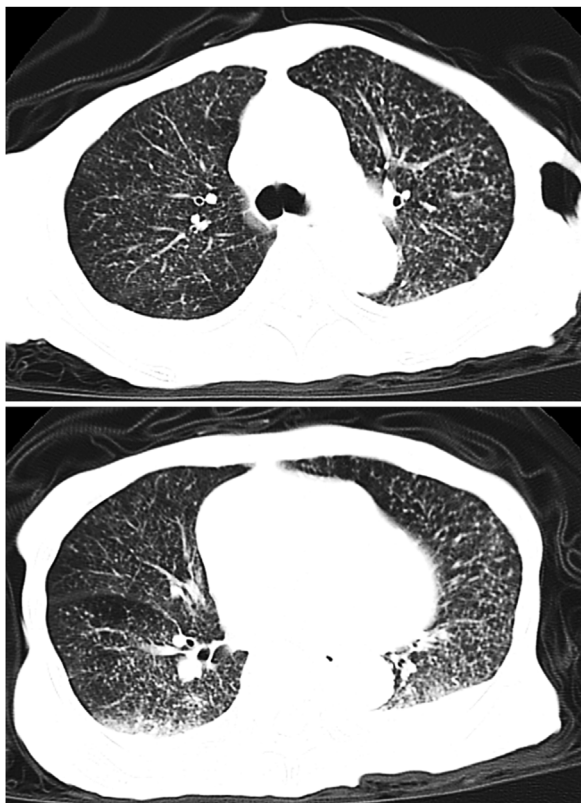


Fig. 1. Chest computed tomography showing diffuse, bilateral, widespread miliary opacification.

Discussion

CNS TB, occurring in patients with active TB, is associated with immunodeficiency, malnutrition, alcoholism, and malignancies [2]. Tuberculomas are atypical manifestations of TB and are characterized by conglomerate caseous foci in the brain developing from coalescing tubercles acquired during previous hematogenous bacillemia. Silent, multiple nodular enhancing lesions, albeit observed more commonly in meningitis, can also develop in patients with miliary TB [4]. In our case, the smear, culture, and PCR evaluations were negative for *M. tuberculosis* in the CSF samples. The sensitivity of PCR for *M. tuberculosis* in the CSF is reported to be as low as 30 % [5]. The CNS tuberculoma diagnosis in the present case was based on the detection of *M. tuberculosis* in the sputum and gastric aspirate, along with specific CSF and brain MRI findings. Miliary TB results from the lymphatic and hematologic spread from a TB focus and is potentially lethal without treatment [6]. The human immunodeficiency virus/acquired immunodeficiency syndrome pandemic and the use of immunosuppressive drugs have led to an increase in the incidence of miliary TB [6].

In the elderly, the respiratory symptoms become worse as they age. In fact, as many as 34.6 % of elderly patients do not complain of fever or respiratory symptoms, and other symptoms often appear in the foreground [7]. The clinical symptoms of TB in the elderly might be nonspecific and can include the lack of energy and decreased appetite, which can be confused with age-related diseases [8]. Elderly patients with TB often visit an emergency department in Japan only after developing a poor general condition such as that occurred with the present case [9]. Although studies have demonstrated that fever, cough, and hemoptysis are less frequent, dyspnea is frequently observed in elderly patients with TB [10,11]. In addition, many patients are diagnosed during evaluation or hospitalization for other diseases and the diagnostic duration tends to be shorter than that in symptomatic patients, likely because the elderly patients during consultation for other diseases or hospitalization are given more priority as patients. TB can involve almost any organ in the body, including the brain as observed in the present case; thus, TB should be included in the differential diagnosis of diseases with unusual presentation especially in the elderly. The mortality rate in older patients with TB was higher than that in younger patients with TB in the United States in a study from 1993 to 2008 (21 % vs. 7 %, $p < 0.001$) [12]. However, early TB treatment can reduce TB-related mortality, and TB in the elderly is a treatable and curable disease [13,14]. Older adults successfully completed therapy similar to younger adults after adjusting for greater overall mortality in older adults based on a study in the United States [12].

Because the elderly comprises the majority of the Japanese population and were born when TB was prevalent, the prevalence rate remains high. Along with the elderly population's growth in numbers, there has been an increase in the number of TB cases among seniors all over the world. The aging phenomenon of TB patients is recognized all over the world, but no country is as prominent as Japan [10,15]. Although the number and incidence of TB are steadily decreasing in Japan, the prevalence is 13.3 cases per 100,000 individuals in 2017 which is higher than that in other high-income countries, and the number of new cases remains above 15,000 and approximately 2000 people die annually in Japan; thus, TB is a major infectious disease in Japan [7]. Japan has epidemiological features of TB, which is that 59 % of all TB patients are elderly (≥ 70 -year-old) and the incidence in 80–89 and ≥ 90 age groups is 55.5 and 92.7 cases per 100,000 individuals, respectively [7]. Accordingly, in Japan the following measures are implemented for TB surveillance in the elderly. Elderly patients who have been hospitalized for other diseases for a long period of time as well as

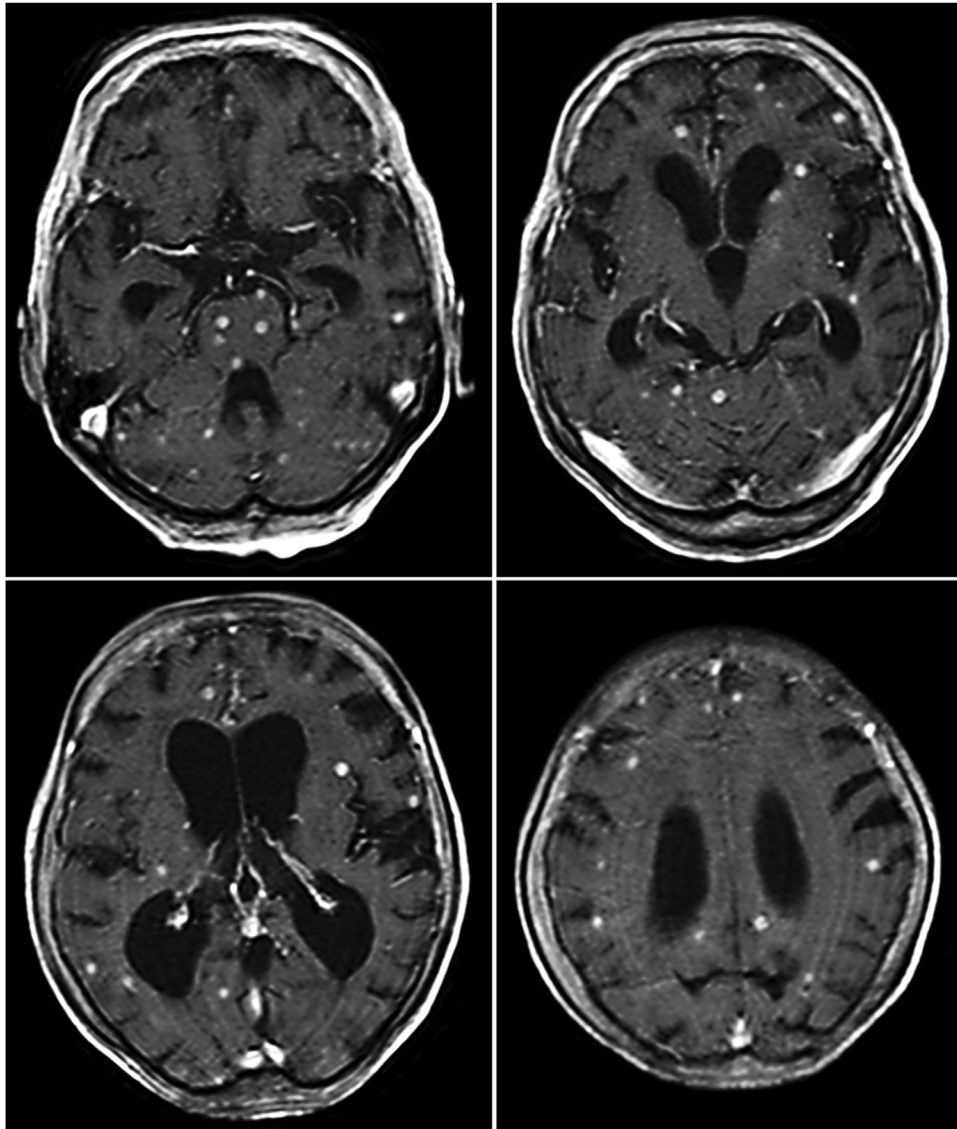


Fig. 2. Axial view of T1-weighted gadolinium-enhanced magnetic resonance images showing multiple enhancing lesions in both the cerebral and cerebellar hemispheres and pons, suggestive of tuberculomas.

elderly residents should have regular chest X-ray examinations. Patients should undergo rehabilitation to prevent a decrease in activities of daily living during hospitalization. The Ministry of Health, Labor and Welfare, with the cooperation of local governments and related organizations, raises awareness on TB prevention from September 24 to September 30 every year as the “TB Prevention Week”. Regarding Japan’s guidelines on the management of latent TB infection, in determining patients for LTBI treatment, the following should be considered: 1) risk of TB infection/development; 2) infection diagnosis; 3) chest image diagnosis; 4) the impact of TB development; 5) the possible manifestation of side effects; and 6) the prospects of treatment completion [16]. Treatment for latent TB infection is strongly recommended when risk is higher, including risk factors such as the following: HIV/AIDS, organ transplants (immunosuppressant use), silicosis, dialysis due to chronic renal failure, recent TB infection (within 2 years), fibronodular shadows in chest radiographs (untreated old TB), the use of biologics, and large doses of corticosteroids [16]. Isoniazid as treatment for latent TB infection is

administered for a period of 6 or 9 months in Japan [16]. However, a recent study has reported that the treatment completion rate was 71.9 %, not achieving the national target [17].

The onset of TB is mainly associated with decreased immunity; however, several other factors such as comorbidities, decreased activity, dysphagia, and malnutrition, which influence one another, also influence the development of TB in the elderly. Because the mortality rate of TB increases rapidly with age, reaching approximately 30 % among the elderly [15], early diagnosis is critical in the elderly.

Funding

This work was supported by research funding for medical faculty from International University of Health and Welfare.

Ethical approval

N/A.

Declaration of Competing Interest

All authors have no conflict of interest.

References

- [1] Schaller MA, Wicke F, Foerch C, Weidauer S. Central nervous system tuberculosis: etiology, clinical manifestations and neuroradiological features. *Clin Neuroradiol* 2019;29(1):3–18.
- [2] Phypers M, Harris T, Power C. CNS tuberculosis: a longitudinal analysis of epidemiological and clinical features. *Int J Tuberc Lung Dis* 2006;10(1):99–103.
- [3] Wilkinson RJ, Rohlwink U, Misra UK, van Crevel R, Mai NTH, Dooley KE, et al. Tuberculous Meningitis International Research Consortium Tuberculous meningitis. *Nat Rev Neurol* 2017;13(10):581–98.
- [4] Weisberg LA. Granulomatous diseases of the CNS as demonstrated by computerized tomography. *Comput Radiol* 1984;8(5):309–17.
- [5] de Almeida SM, Borges CM, Santana LB, Golin G, Correa L, Kussen GB, et al. Validation of Mycobacterium tuberculosis real-time polymerase chain reaction for diagnosis of tuberculous meningitis using cerebrospinal fluid samples: a pilot study. *Clin Chem Lab Med* 2019;57(4):556–64.
- [6] Sharma SK, Mohan A, Sharma A, Mitra DK. Miliary tuberculosis: new insights into an old disease. *Lancet Infect Dis* 2005;5(7):415–30.
- [7] Hikone M, Ainoda Y, Sakamoto N, Ohnishi K. Clinical characteristics of elderly pulmonary tuberculosis in an acute-care general hospital in Tokyo, Japan: a 12-year retrospective study. *J Infect Chemother* 2019(December) pii: S1341-321X(19)30281-8.
- [8] Rajagopalan S. Tuberculosis in older adults. *Clin Geriatr Med* 2016;32(3):479–91.
- [9] Okada T, Shibuya Y, Saito H, Enomoto T, Nakamura S. Clinical analysis of patients with tuberculosis admitted on an emergency cases. *Nihon Kokyuki Gakkai Zasshi* 2008;46:620–6.
- [10] Lee JH, Han DH, Song JW, Chung HS. Diagnostic and therapeutic problems of pulmonary tuberculosis in elderly patients. *J Korean Med Sci* 2005;20(5):784–9.
- [11] Kwon YS, Chi SY, Oh IJ, Kim KS, Kim YI, Lim SC, et al. Clinical characteristics and treatment outcomes of tuberculosis in the elderly: a case control study. *BMC Infect Dis* 2013;13:121.
- [12] Pratt RH, Winston CA, Kammerer JS, Armstrong LR. Tuberculosis in older adults in the United States, 1993–2008. *J Am Geriatr Soc* 2011;59(May (5)):851–7.
- [13] Stead WW. Tuberculosis among elderly persons, as observed among nursing home residents. *Int J Tuberc Lung Dis* 1998;2(9 Suppl. 1):S64–70.
- [14] Rajagopalan S, Yoshikawa TT. Tuberculosis in long-term-care facilities. *Infect Control Hosp Epidemiol* 2000;21(9):611–5.
- [15] Davies PD. TB in the elderly in industrialised countries. *Int J Tuberc Lung Dis* 2007;11(11):1157–9.
- [16] The Prevention Committee and the Treatment Committee of the Japanese Society for Tuberculosis. Treatment guidelines for latent tuberculosis infection. *Kekkaku* 2014;89(1):21–37.
- [17] Kawatsu L, Uchimura K, Ohkado A. Trend and treatment status of latent tuberculosis infection patients in Japan—analysis of Japan TB Surveillance data. *PLoS One* 2017;12(11):e0186588.